



Volume III

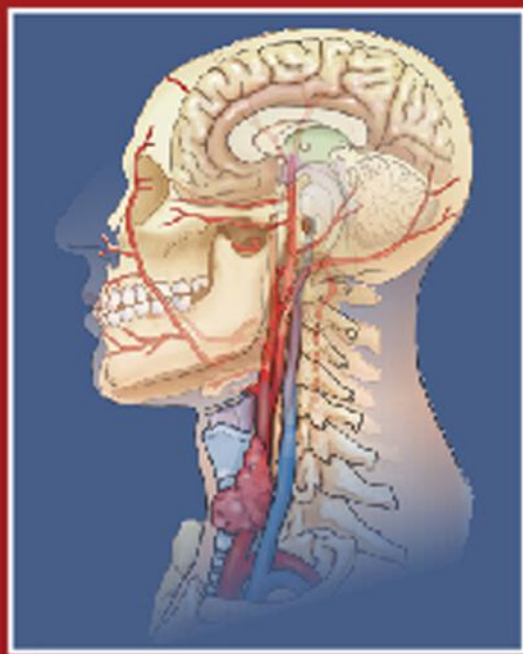
**Fully
Revised
and
Updated**

Textbook of

Anatomy

HEAD, NECK AND BRAIN

Second Edition



Vishram Singh

TEXTBOOK OF ANATOMY
HEAD, NECK AND BRAIN

This page intentionally left blank

TEXTBOOK OF ANATOMY

HEAD, NECK AND BRAIN

Volume III

Second Edition

Vishram Singh, MS, PhD

Professor and Head, Department of Anatomy
Professor-in-Charge, Medical Education Unit
Santosh Medical College, Ghaziabad

Editor-in-Chief, Journal of the Anatomical Society of India

Member, Academic Council and Core Committee PhD Course, Santosh University

Member, Editorial Board, Indian Journal of Otolaryngology

Medicolegal Advisor, ICPS, India

Consulting Editor, ABI, North Carolina, USA

Formerly at: GSVM Medical College, Kanpur

King George's Medical College, Lucknow

Al-Arab Medical University, Benghazi (Libya)

All India Institute of Medical Sciences, New Delhi



ELSEVIER

A division of

Reed Elsevier India Private Limited

Textbook of Anatomy: Head, Neck and Brain, Volume III, 2e

Vishram Singh

© 2014 Reed Elsevier India Private Limited

First edition 2009

Second edition 2014

All rights reserved. No part of this publication may be reproduced or transmitted in any form or by any means, electronic or mechanical, including photocopying, recording, or any information storage and retrieval system, without permission in writing from the Publisher.

This book and the individual contributions contained in it are protected under copyright by the Publisher (other than as may be noted herein).

ISBN: 978-81-312-3727-4

e-book ISBN: 978-81-312-3627-7

Notices

Knowledge and best practice in this field are constantly changing. As new research and experience broaden our understanding, changes in research methods, professional practices, or medical treatment may become necessary.

Practitioners and researchers must always rely on their own experience and knowledge in evaluating and using any information, methods, compounds, or experiments described herein. In using such information or methods they should be mindful of their own safety and the safety of others, including parties for whom they have a professional responsibility.

With respect to any drug or pharmaceutical products identified, readers are advised to check the most current information provided (i) on procedures featured or (ii) by the manufacturer of each product to be administered, to verify the recommended dose or formula, the method and duration of administration, and contraindications. It is the responsibility of practitioners, relying on their own experience and knowledge of their patients, to make diagnoses, to determine dosages and the best treatment for each individual patient, and to take all appropriate safety precautions.

To the fullest extent of the law, neither the Publisher nor the authors, contributors, or editors, assume any liability for any injury and/or damage to persons or property as a matter of products liability, negligence or otherwise, or from any use or operation of any methods, products, instructions, or ideas contained in the material herein.

Please consult full prescribing information before issuing prescription for any product mentioned in this publication.

The Publisher

Published by Reed Elsevier India Private Limited

Registered Office: 305, Rohit House, 3 Tolstoy Marg, New Delhi-110 001

Corporate Office: 14th Floor, Building No. 10B, DLF Cyber City, Phase II, Gurgaon-122 002, Haryana, India

Senior Project Manager-Education Solutions: Shabina Nasim

Content Strategist: Dr Renu Rawat

Project Coordinator: Goldy Bhatnagar

Copy Editor: Shrayosee Dutta

Senior Operations Manager: Sunil Kumar

Production Manager: NC Pant

Production Executive: Ravinder Sharma

Graphic Designer: Milind Majgaonkar

Typeset by Chitra Computers, New Delhi

Printed and bound at Thomson Press India Ltd., Faridabad, Haryana

Dedicated to

My Mother

Late Smt Ganga Devi Singh Rajput

an ever guiding force in my life for achieving knowledge through education

My Wife

Mrs Manorama Rani Singh

for tolerating my preoccupation happily during the preparation of this book

My Children

Dr Rashi Singh and Dr Gaurav Singh

for helping me in preparing the manuscript

My Teachers

Late Professor (Dr) AC Das

for inspiring me to be multifaceted and innovative in life

Professor (Dr) A Halim

for imparting to me the art of good teaching

My Students, Past and Present

for appreciating my approach to teaching anatomy and
transmitting the knowledge through this book

This page intentionally left blank



Preface to the Second Edition

It is with great pleasure that I express my gratitude to all students and teachers who appreciated, used, and recommended the first edition of this book. It is because of their support that the book was reprinted three times since its first publication in 2009.

The huge success of this book reflects appeal of its clear, unclustered presentation of the anatomical text supplemented by perfect simple line diagrams, which could be easily drawn by students in the exam and clinical correlations providing the anatomical, embryological, and genetic basis of clinical conditions seen in day-to-day life in clinical practice.

Based on a large number of suggestions from students and fellow academicians, the text has been extensively revised. Many new line diagrams and halftone figures have been added and earlier diagrams have been updated.

I greatly appreciate the constructive suggestions that I received from past and present students and colleagues for improvement of the content of this book. I do not claim to absolute originality of the text and figures other than the new mode of presentation and expression.

Once again, I whole heartedly thank students, teachers, and fellow anatomists for inspiring me to carry out the revision. I sincerely hope that they will find this edition more interesting and useful than the previous one. I would highly appreciate comments and suggestions from students and teachers for further improvement of this book.

*“To learn from previous experience and change
accordingly, makes you a successful man.”*

Vishram Singh

This page intentionally left blank

Preface to the First Edition

This textbook on head, neck and brain has been carefully planned for the first year MBBS and Dental students. It follows the revised anatomy curriculum of the Medical Council of India. It also meets the standards of dental curriculum of the Dental Council of India. Following the current trends of clinically-oriented study of Anatomy, I have adopted a parallel approach – that of imparting basic anatomical knowledge to students and simultaneously providing them its applied aspects.

To help students score high in examinations the text is written in simple language. It is arranged in easily understandable small sections. Conforming to the anatomy curriculum and pattern of examination, major portion of the book has been devoted to head and neck anatomy while for brain only essential aspects are included; for detailed description of brain students can refer to the author's *Textbook of Clinical Neuroanatomy*. While anatomical details of little clinical relevance, phylogenetic discussions and comparative analogies have been omitted, all clinically important topics are described in detail. Brief accounts of histological features and developmental aspects have been given only where they aid in understanding of gross form and function of organs and appearance of common congenital anomalies. The tables and flowcharts summarize important and complex information into digestible knowledge capsules. Multiple choice questions have been given chapter-by-chapter at the end of the book to test the level of understanding and memory recall of the students. The numerous simple 4-color illustrations further assist in fast comprehension and retention of complicated information. All the illustrations are drawn by the author himself to ensure accuracy.

Throughout the preparation of this book one thing I have kept in mind is that anatomical knowledge is required by clinicians and surgeons for physical examination, diagnostic tests, and surgical procedures. Therefore, topographical anatomy relevant to diagnostic and surgical procedures is clinically correlated throughout the text. Further, Clinical Case Study is provided at the end of each chapter for problem-based learning (PBL) so that the students could use their anatomical knowledge in clinical situations. Moreover, the information is arranged regionally since while assessing lesions and performing surgical procedures, the clinicians encounter region-based anatomical features. Due to propensity of lesions of oral cavity and cranial nerves there is in-depth discussion on oral cavity and cranial nerves.

As a teacher, I have tried my best to make the book easy to understand and interesting to read. For further improvement of this book I would greatly welcome comments and suggestions from the readers.

Vishram Singh

This page intentionally left blank

Acknowledgments

At the outset, I express my gratitude to Dr P Mahalingam, CMD; Dr Sharmila Anand, DMD; and Dr Ashwyn Anand, CEO, Santosh University, Ghaziabad, for providing an appropriate academic atmosphere in the university and encouragement which helped me in preparing this book.

I am also thankful to Dr Usha Dhar, Dean Santosh Medical College for her cooperation. I highly appreciate the good gesture shown by Dr Ruchira Sethi, Dr Deepa Singh, and Dr Preeti Srivastava for checking the final proofs.

I sincerely thank my colleagues in the Department, especially Professor Nisha Kaul and Dr Ruchira Sethi for their assistance.

I gratefully acknowledge the feedback and support of fellow colleagues in Anatomy, particularly,

- Professors AK Srivastava (Head of the Department) and PK Sharma, and Dr Punita Manik, King George's Medical College, Lucknow.
- Professor NC Goel (Head of the Department), Hind Institute of Medical Sciences, Barabanki, Lucknow.
- Professor Kuldeep Singh Sood (Head of the Department), SGT Medical College, Budhera, Gurgaon, Haryana.
- Professor Poonam Kharb, Sharda Medical College, Greater Noida, UP.
- Professor TC Singel (Head of the Department), MP Shah Medical College, Jamnagar, Gujarat.
- Professor TS Roy (Head of the Department), AIIMS, New Delhi.
- Professors RK Suri (Head of the Department), Gayatri Rath, and Dr Hitendra Loh, Vardhman Mahavir Medical College and Safdarjang Hospital, New Delhi.
- Professor Veena Bharihoke (Head of the Department), Rama Medical College, Hapur, Ghaziabad.
- Professors SL Jethani (Dean and Head of the Department), and RK Rohtagi, Dr Deepa Singh and Dr Akshya Dubey, Himalayan Institute of Medical Sciences, Jolly Grant, Dehradun.
- Professors Anita Tuli (Head of the Department), Shipra Paul, and Shashi Raheja, Lady Harding Medical College, New Delhi.
- Professor SD Joshi (Dean and Head of the Department), Sri Aurobindo Institute of Medical Sciences, Indore, MP.

Lastly, I eulogize the patience of my wife Mrs Manorama Rani Singh, daughter Dr Rashi Singh, and son Dr Gaurav Singh for helping me in the preparation of this manuscript.

I would also like to acknowledge with gratitude and pay my regards to my teachers Prof AC Das and Prof A Halim and other renowned anatomists of India, viz. Prof Shamer Singh, Prof Inderbir Singh, Prof Mahdi Hasan, Prof AK Dutta, Prof Inder Bhargava, etc. who inspired me during my student life.

I gratefully acknowledge the help and cooperation received from the staff of Elsevier, a division of Reed Elsevier India Pvt. Ltd., especially Ganesh Venkatesan (Director Editorial and Publishing Operations), Shabina Nasim (Senior Project Manager-Education Solutions), Goldy Bhatnagar (Project Coordinator), and Shrayosee Dutta (Copy Editor).

Vishram Singh

This page intentionally left blank

Contents

	<i>Preface to the Second Edition</i>	<i>vii</i>
	<i>Preface to the First Edition</i>	<i>ix</i>
	<i>Acknowledgments</i>	<i>xi</i>
Chapter 1	Living Anatomy of the Head and Neck	1
Chapter 2	Osteology of the Head and Neck	12
Chapter 3	Scalp, Temple, and Face	46
Chapter 4	Skin, Superficial Fascia, and Deep Fascia of the Neck	68
Chapter 5	Side of the Neck	77
Chapter 6	Anterior Region of the Neck	86
Chapter 7	Back of the Neck and Cervical Spinal Column	96
Chapter 8	Parotid Region	111
Chapter 9	Submandibular Region	119
Chapter 10	Infratemporal Fossa, Temporomandibular Joint, and Pterygopalatine Fossa	133
Chapter 11	Thyroid and Parathyroid Glands, Trachea, and Esophagus	156
Chapter 12	Pre- and Paravertebral Regions and Root of the Neck	168
Chapter 13	Oral Cavity	180
Chapter 14	Pharynx and Palate	199
Chapter 15	Larynx	218
Chapter 16	Blood Supply and Lymphatic Drainage of the Head and Neck	231
Chapter 17	Nose and Paranasal Air Sinuses	251
Chapter 18	Ear	265

Chapter 19	Orbit and Eyeball	282
Chapter 20	Vertebral Canal and Its Contents	302
Chapter 21	Cranial Cavity	315
Chapter 22	Cranial Nerves	333
Chapter 23	General Plan and Membranes of the Brain	353
Chapter 24	Brainstem	363
Chapter 25	Cerebellum and Fourth Ventricle	375
Chapter 26	Diencephalon and Third Ventricle	382
Chapter 27	Cerebrum	389
Chapter 28	Basal Nuclei and Limbic System	399
Chapter 29	Blood Supply of the Brain	405
	<i>Multiple Choice Questions</i>	413
	<i>Index</i>	435

Living Anatomy of the Head and Neck

HEAD

The head is the globular cranial end of the body, which contains brain and special sense organs, *viz.* eyes for vision, ears for hearing and equilibrium, nose for smell, and tongue for taste. It also provides openings for the respiratory and digestive systems. Structurally and developmentally, the head is divided into two parts: cranium and face.

The cranium (also known as *braincase*) contains the brain. The face possesses openings of eyes, nose, and mouth.

A little description of comparative anatomy makes the distinction between the size of cranium and face easier to understand.

The sense of smell is one of the oldest sensibilities. The pronograde canines (e.g., dog) are guided predominantly by smell for searching food and sex. The other senses, such as touch, hearing, and vision play an accessory role. Therefore, they have well-developed snout, and, their face is located in front of the cranium (Fig. 1.1).

The arboreal mode of life of apes and monkeys favored the higher development of visual, acoustic, tactile, kinesthetic, and motor functions with improvement in their intelligence. In these animals, usefulness of the nose was lost and sense of smell became an accessory sense. Consequently in orthograde monkeys, it resulted in the loss of the projecting snout, and their face is located below and in front of the cranium.

The supremacy of man in animal kingdom is due to his large well-developed brain, which provides him the unlimited power of thinking, reasoning, and judgement. To accommodate large brain, the size of cranium has also increased proportionately. Consequently, in plantigrade man the forehead is prominent and the face is located below the anterior part of the cranium.

It is important to note that size of jaws is inversely proportional to the size of cranium. Thus the pronograde canine has larger jaws; an orthograde monkey has smaller jaws whereas plantigrade man has smallest jaws. The

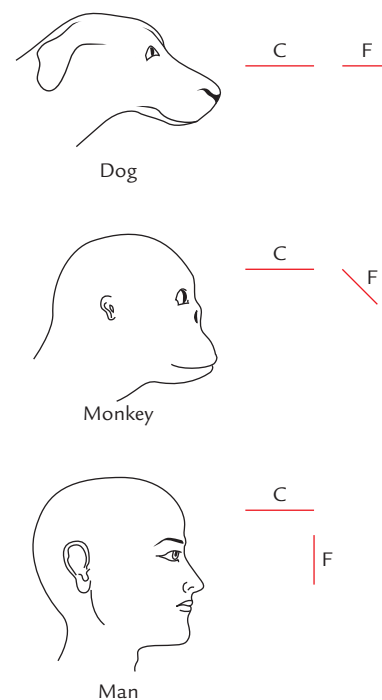


Fig. 1.1 Change in position of face in relation to cranium during evolution. The face is located in front of cranium in dog, below and in front of cranium in monkey and below the anterior part of cranium in man. Note that the size of jaws is inversely proportional to the size of cranium (C = cranium, F = face).

reduction in the size of jaws occurred due to change in eating habits of these animals. The jaws are smallest in man because he prefers to eat soft cooked food. The size of jaws is larger in canines because they use it for holding, breaking, biting, tearing, and chewing the food. With receding jaws, the mouth is proportionately reduced in size.

In man, eyes are placed in more frontal plane to enable stereoscopic vision. To permit freedom of mobility to the tongue for a well-articulated speech in man, the alveolar arches are broadened and the chin is pushed forward, making

the mouth cavity more roomy. The **prominent chin** is a characteristic feature of human beings. The distinctive external nose with prominent dorsum, tip, and alae is characteristic of a man, although it has nothing to do with the sense of smell. Probably it serves to protect the eyes from injuries. The brow ridges are markedly reduced in man as compared to other primates due to their prominent forehead.

LIVING ANATOMY

The living anatomy deals with the examination of surface features by visualization (inspection) and palpation of the living individuals to get information about the deeper structures. It is of immense importance in clinical examination of the patients. The study of living anatomy (also called *living* or *surface anatomy*) of head and neck begins with the division of the surface into regions and examining surface landmarks in each region. The students are advised to practice finding these landmarks in each region on themselves or on their colleagues to develop the skill of examination.

REGIONS OF THE HEAD

The head is divided into the following regions: frontal, parietal, occipital, temporal, auricular, parotid, orbital, nasal, zygomatic, buccal, oral, and mental (Fig. 1.2).

FRONTAL REGION (FOREHEAD)

The frontal region of the head is an area superior to the eyes and below the hair line. Eyebrows are the raised arches of skin with short, thick hairs above the supraorbital margins. Just deep to eyebrow is the curved bony ridge or superciliary

arch. It is more prominent in adult males. The smooth non-hairy elevated area between the eyebrows is called **glabella**, which tends to be flat in children and adult females, and forms a rounded prominence in adult males. Indian married Hindu females apply *bindi* at this site to enhance their beauty. It is important to note that the pineal gland lies about 7 cm behind the glabella. The prominence of forehead, the frontal eminence is evident on either side above the eyebrow. The frontal prominence is typically more pronounced in children and adult females.

PARIETAL REGION

It is an area limited anteriorly by hair line and posteriorly by a coronal plane behind the parietal eminences and on either side by the temporal line. The parietal eminence can be felt on either side in this region about 2 inches above the auricle. The parietal prominences are evident on or just in front of the interauricular line.

OCCIPITAL REGION

The occipital region is an area of cranium behind the parietal eminences, and above the external occipital protuberance and superior nuchal lines.

The most prominent point in the occipital region is called **opisthocranium** or **occiput**. The external occipital protuberance can be felt in the median line just above the nuchal furrow. The superior nuchal line, one on either side of external occipital protuberance, runs laterally with its convexity facing upwards.

The soft tissue covering frontal, parietal, and occipital regions forms the scalp.

Clinical correlation

The large area of scalp over the vault of skull is thickly covered by terminal hair. Due to presence of hair, many lesions in this area remain unnoticed by both clinicians and patients. Hence, this area should be carefully examined by the clinicians.

TEMPORAL REGION (TEMPLE)

The temporal region is the area on the side of skull between the temporal line and zygomatic arch (Fig. 1.3). It is the site of attachment of temporalis muscle, which can be palpated when the teeth are clenched repeatedly. Try on yourself. Soft tissue in the temporal region includes skin, subcutaneous tissue, temporal fascia, and temporalis muscle. In the anterior part of temporal region, deep to soft tissues is a small area where four bones meet the **pterion** (Fig. 1.3). This region is clinically important because it is the site of entrance to cranial cavity in craniotomy to remove the extradural

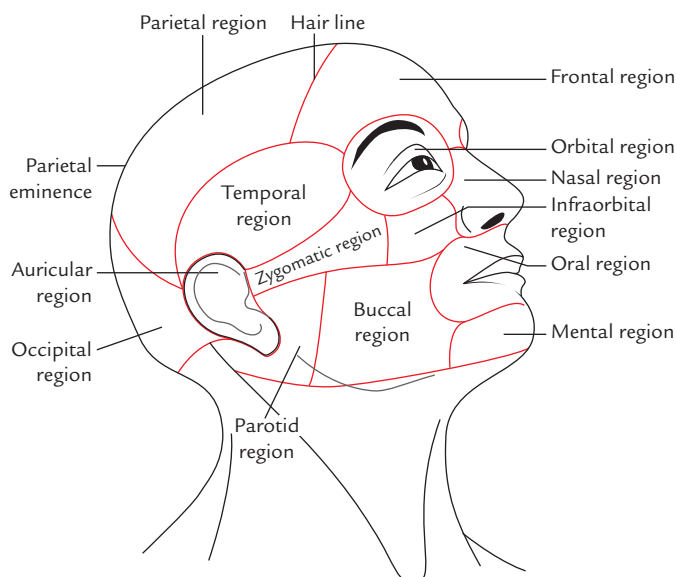


Fig. 1.2 Regions of the head.

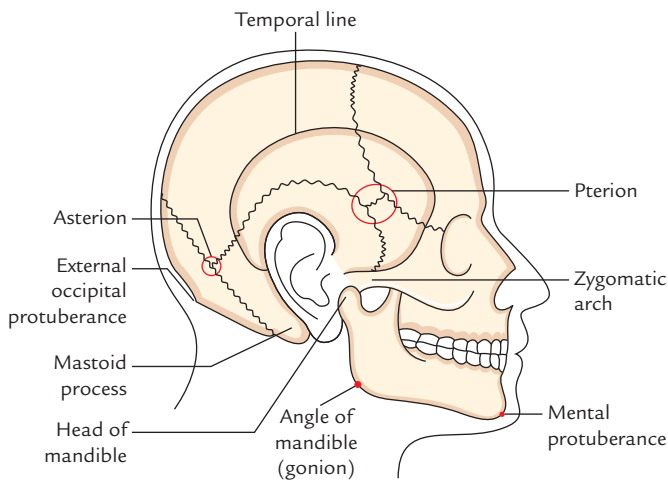


Fig. 1.3 Surface landmarks on the lateral aspect of the head.

hematoma. Pterion is described in detail on page 18. The temporal region (temple) is described in detail on page 50.

AURICULAR REGION

The auricular region includes fleshy oval flap of the ear (auricle) and external acoustic meatus.

The auricle collects the sound waves. The external auditory meatus is a tube through which sound waves are transmitted to the middle ear within the skull. Observe the following surface features of the auricle (Fig. 1.4).

The superior and posterior free margins of the auricle forming a kind of rim are called *helix*, which ends inferiorly at the fleshy protuberance of the ear called *ear lobule*.

The upper end of the helix is typically at the level of the eyebrows and the glabella.

The lobule is approximately at the level of the apex of the nose.

The portion of the auricle anterior to the external auditory meatus is a small nodular flap of tissue called **tragus**. It projects posteriorly, partially covering and protecting the external auditory meatus. The condyle of mandible can be palpated by putting the tip of finger just in front of tragus and then opening and closing the mouth.

Another flap of tissue opposite the tragus is the **antitragus**. Between the **tragus** and **antitragus** is a deep notch called **intertragic notch**.

A semicircular ridge anterior to the helix is called **antihelix**.

The upper end of antihelix divides into two crura enclosing a triangular depression called **triangular fossa**. The depressed hollow of the auricle is called **concha**.

The upper end of the helix which extends backwards to some extent into concha is called **crux of helix**.

Clinical correlation

The external auditory meatus and tragus are important landmarks to use when taking extraoral radiographs and administering local anesthesia on a patient. The **pulsations of superficial temporal artery** can be felt by putting the fingertip just in front and above the tragus on the root of zygoma.

PAROTID REGION

As the name implies, it is region around the ear (para = around; otic = ear). It is limited in front by anterior border

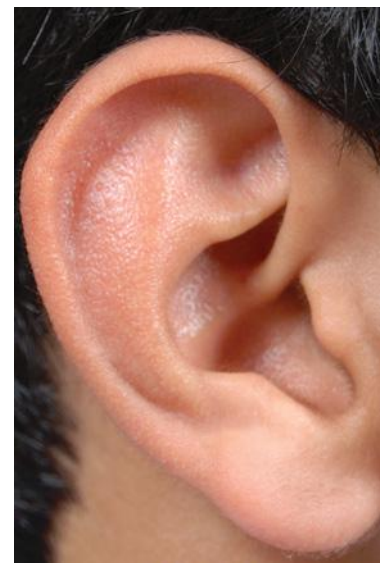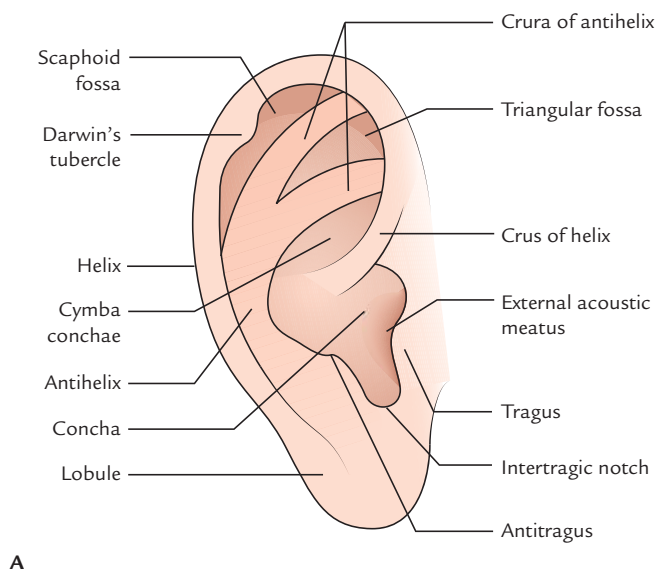


Fig. 1.4 Lateral view of right auricle: A, schematic figure; B, actual picture.

of masseter, behind by mastoid process and below by line extending from angle of mandible to the tip of mastoid process. This region is occupied by parotid gland. The *mastoid process* lies behind the lower part of the ear. Its anterior border, tip and posterior border can be easily felt.

The *masseter* overlies the ramus of the mandible. It can be felt when the teeth are clenched.

Clinical correlation

The parotid gland is often enlarged following infection by mumps virus. This produces a painful swelling in the parotid region elevating the ear lobule. The parotid gland is also the site of slow growing painless tumor called *mixed parotid tumor*.

ORBITAL (OCULAR) REGION

The ocular region includes the eyeball and associated structures. Most of the surface features of the ocular region protect the eye (Fig. 1.5). Eyebrow is a ridge of hair along the superciliary arch above the orbit, which protects the eyes against sunlight and mechanical blow. The two movable eyelids reflexly close to protect eyes from foreign particles and bright sunlight (for details on eyelids see Chapter 3). The eyelashes are a row of hair at the margins of eyelids. The eyelashes prevent airborne objects from contacting the eyeball. Behind the lateral part of the upper eyelid and within the orbit is the **lacrimal gland**, which produces lacrimal fluid or tears. The tears wash away chemical and foreign particles and lubricate the front of the eye to prevent the surface of the eyeball, particularly the all-important cornea from drying.

The conjunctiva is a delicate thin mucous membrane which lines the inner surface of the eyelids and the front of the eyeball. It aids in reducing friction during blinking.

The sclera, the 'white' of the eye is seen on either side of cornea.

The cornea is the circular transparent anterior portion of the eyeball.

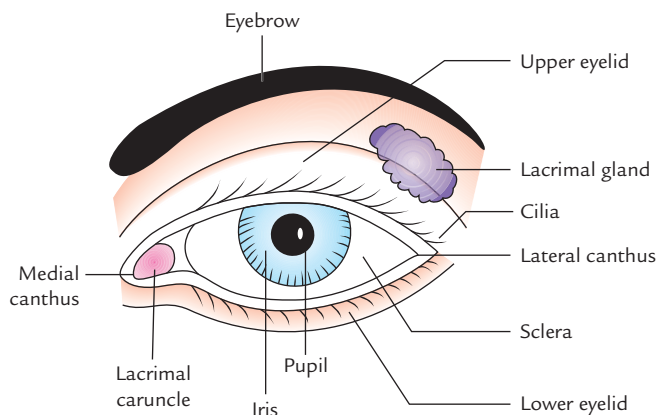


Fig. 1.5 Frontal view of the left eye.

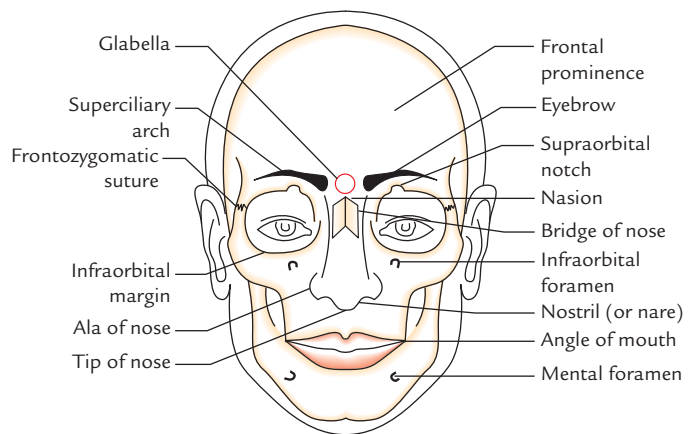


Fig. 1.6 Surface landmarks on frontal aspect of the head.

The outer corner where the upper and lower eyelids meet is called *lateral (outer) canthus*. The inner corner where the two eyelids meet is called *medial canthus*. A fleshy pinkish elevation in the medial angle of the eye is called *lacrimal caruncle*.

Palpate the following landmarks in this region (Fig. 1.6) in yourself:

1. Supraorbital notch on the highest point of supraorbital margin about 2.5 cm from the midline.
2. Frontozygomatic suture, which is marked by a slight irregular depression on the lateral orbital margin.

Clinical correlation

The condition of the eyes profoundly affects the facial appearance. **Lesions affecting the eye and its associated structures** are enormous. A few easily recognizable and surgically relevant conditions are as follows:

- *Arcus senilis*, a white rim around the outer edge of the iris, is commonly seen in elderly people. It occurs due to sclerosis and deposition of cholesterol in the edge of the cornea.
- *Xanthelasma* are fatty plaques in the skin of the eyelids. They look like masses of yellow opaque fat. If multiple and growing, they indicate underlying abnormality of cholesterol metabolism, diabetes, or arterial disease.
- *Exophthalmos* is a forward protrusion of the eyeball from its normal position in the orbit. The commonest cause of both bilateral and unilateral exophthalmos is thyrotoxicosis (hyperthyroidism).
- *Ectropion* is the eversion of the lower eyelid.

NASAL REGION

The main feature of nasal region is the external nose. It is a pyramidal projection in the middle third of the face with its root up and base downwards (Fig. 1.6). The root of the nose is located between the eyes inferior to glabella. The firm

narrow bony portion below the nasion is the bridge of the nose. The nose below this level has pliable cartilaginous framework that maintains the openings of the nose. The tip of the nose is called *apex*. It is flexible when palpated because it is made up of cartilage. Inferolateral to the apex on either side is a nostril (or nare). The nostrils are separated from each other by a midline nasal septum. The nares are bounded laterally by wing-like alae of the nose. The alae of nose forms the flared outer margin of each nostril.

The distinctive external nose with exuberant growth of cartilages forming prominent dorsum, tip, and alae is a characteristic feature of human beings.

A well-marked depression at the root of the nose is called **nasion**.

Clinical correlation

- **Saddle nose:** A nose whose bridge is depressed and widened.
- **Rhinophyma:** The nasal skin covering the alar cartilages is thick and adherent, and contains many sebaceous glands. The hypertrophy and adenomatous changes of these glands gives rise to a lobulated tumor called rhinophyma.

INFRAORBITAL REGION

The infraorbital region of head is located below the orbital region and corresponds to the upper part of the anterior surface of the maxilla. The **infraorbital foramen** is located in this region about 1 cm below the infraorbital margin in line with the supraorbital notch or foramen (Fig. 1.6). The knowledge of its location is important for giving **infraorbital nerve block**.

ZYGOMATIC REGION

The zygomatic region overlies the zygomatic (cheek) bone and zygomatic arch.

The zygomatic arch extends from just inferior to lateral margin of the eye towards the upper portion of the auricle. Inferior to the zygomatic arch and just anterior to the tragus of the ear is the **temporomandibular joint**. The zygomatic arch is bony bridge that spans the interval between the ear and the eye. The zygomatic bone forms the bony prominence of the cheek below and lateral to the orbit.

The movements of the temporomandibular joint can be felt by opening and closing the mouth or moving the lower jaw from side to side. One way to feel the movements of head of mandible is to gently place a finger into the outer portion of the external auditory meatus.

BUCCAL REGION

The buccal region of face is a broad area of the face between the nose, mouth, and parotid region. It overlies the buccinator muscle. It is made of soft tissues of the cheek.

The **pulsations of facial artery** can be felt about 1.25 cm lateral to the angle of the mouth.

ORAL REGION

The structures of the oral region include fleshy upper and lower lips, and the structures of oral cavity that can be observed when the mouth is widely open.

The lips are chiefly composed of muscles covered externally by skin and internally by mucous membrane. Each lip has a pinkish zone called *vermillion zone*. The lips are outlined from the surrounding skin by a transition zone called *vermillion border*. The small triangular median depression in the upper lip is called *philtrum*. The apex of philtrum is towards the nasal septum and the base downwards where it terminates in a thicker area called *tubercle of the upper lip*.

The corners of mouth where upper and lower lips meet are called *labial commissure*. The groove running upward between the labial commissure and the alae of nose is called *nasolabial sulcus*. The lower lip is separated from the chin by a horizontal groove called *labiomental groove* (Fig. 1.7).

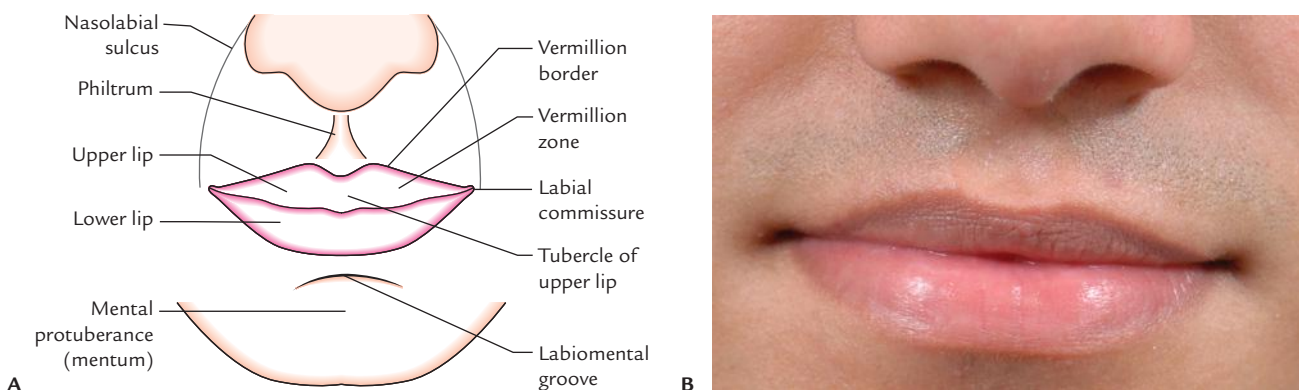


Fig. 1.7 Frontal view of the lips: A, schematic figure; B, actual picture.

Clinical correlation

The color of the lips and the mucus membrane of the oral cavity are clinically important; lips may appear pale in patients with severe *anemia* or bluish in people suffering from lack of oxygenation of blood (*cyanosis*). A lemon yellow tint of lips may indicate *jaundice*.

The lips are a common site for carcinoma, mostly affecting individuals above 60 years of age. Carcinoma of the lip usually occurs in lower lip (93%) as compared to the upper lip (5%).

The bone underlying the upper lip is the alveolar process of the maxilla, whereas the bone underlying the lower lip is the alveolar process of the mandible. The alveolar processes contain teeth and are called maxillary and mandibular teeth.

MENTAL REGION

The mental region is an area of face below the lower lip and is characterized by the presence of mental protuberance or mentum, a privileged feature of human beings (Fig. 1.7).

Important bony landmarks in the region of the head are summarized in Table 1.1.

Examine the following structures of oral cavity by asking your friend to open his mouth widely (Fig. 1.8).

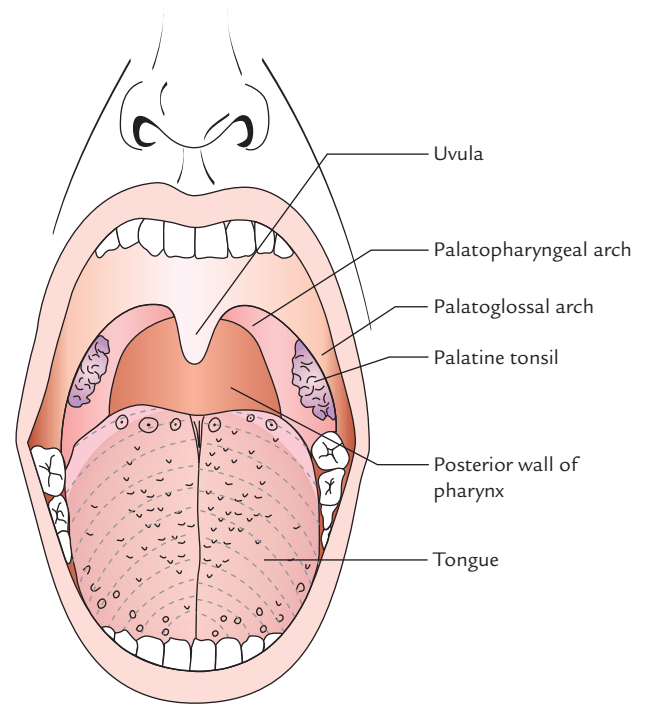


Fig. 1.8 Features of the oral cavity and oropharynx.

- The part of oral cavity inside the alveolar arches is called *oral cavity proper*. It contains a mobile muscular organ, the **tongue**.

Table 1.1 Bony landmarks in the region of head

Landmark	Location
Mental protuberance/mentum	Protuberance of the chin
Nasion	Depression at the root of nose at the junction of frontonasal and internasal sutures
Glabella	Smooth non-hairy area between the eyebrows above nasion
Vertex	Highest point on the top of head in the midline
External occipital protuberance	Knob-like bony projection at the upper end of nuchal furrow
Inion	Apex of external occipital protuberance
Gonion	Angle of mandible
Head of mandible	In front of lower part of the tragus
Preauricular point	In front of upper part of the tragus
Mastoid process	Behind the lower part of the auricle
Pterion	4 cm above the midpoint of zygomatic arch/3.5 cm behind and 1.5 cm above the frontozygomatic suture
Asterion	Depression—2.5 cm behind the upper part of the root of ear
Supraorbital notch/foramen	On the supraorbital margin 2.5 cm from midline
Infraorbital foramen	1 cm below infraorbital margin and 1.25 cm lateral to the side of nose
Mental foramen	2.5 cm lateral to symphysis menti and 1.25 cm above the lower border of mandible
Frontal prominence	Area of maximum convexity on either side of forehead where top, front and side of head meet
Parietal prominence	Area of maximum convexity on either side in the parietal region where back, top and side of head meet (Area of maximum transverse diameter of the skull)

- The oral cavity is lined by a mucus membrane or mucosa. The inner aspects of the lips are lined by pink and thick labial mucosa. The labial mucosa is continuous with the equally pink and thick buccal mucosa that lines the inner cheek.
- The space between cheek/lip and gum is called *vestibule*.
- On the inner aspect of buccal mucosa opposite the upper second molar tooth is a small elevation called *parotid papilla* on which opens the parotid duct.
- The gingiva is a part of oral mucosa that covers the alveolar processes of the jaws.
- The roof of oral cavity which presents two portions: (a) a firm anterior portion is called *hard palate* and a flexible posterior portion is called *soft palate*. A cone-shaped projection hanging down from the middle of the posterior free margin is called *uvula of the palate*, which is continuous with palatopharyngeal arch on each side.
- A dense pad of soft tissue behind the last molar tooth is called *retromolar pad*.
- The floor of mouth is located inferior to the ventral surface of the tongue.

N.B. The oral cavity provides entrance into the throat or the pharynx.

One can easily examine the following features in the oropharynx (Fig. 1.8):

1. A curved, leaf-like flap of cartilage is located behind the base of tongue and in front of oropharynx. It is epiglottis, the cartilage of the larynx.
2. Mass of lymphoid tissue projecting on either side into the lateral wall of the oropharynx is called *palatine tonsil* (Fig. 1.8). The palatine tonsils are generally called *tonsils* by the patients. The tonsil lies in triangular fossa called tonsillar fossa located between the palatoglossal and palatopharyngeal arches. Note that the tonsils lie opposite the angle of mandible between the back of tongue and soft palate.

NECK

The neck is approximately a cylindrical region of the body that connects the head to the trunk. It supports and permit the movements of the head.

TOPOGRAPHICAL ORGANIZATION OF THE NECK

The neck is flexible and provides passage to several structures such as spinal cord, trachea, esophagus, blood vessels supplying the brain, the last four cranial nerves, etc. All these structures are essential for the sustenance of life.

The **investing layer of deep cervical fascia** encloses the neck like a collar. It splits to enclose sternocleidomastoid and

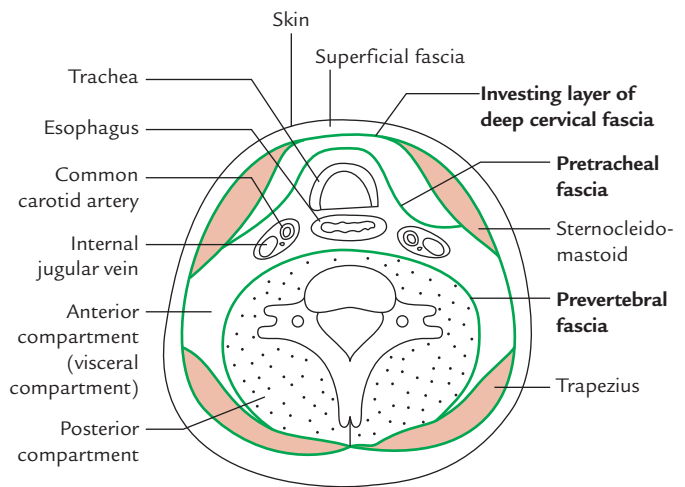


Fig. 1.9 The basic plan of the neck in cross section. Note the location of anterior and posterior compartments.

trapezius muscles in its course around the neck. The two fascial layers (called pretracheal and prevertebral fasciae) extending from the investing layer of deep fascia across the structures within the neck divide the neck into anterior and posterior compartments (Fig. 1.9).

Topographically, the structures of the neck are organized into anterior and posterior compartments.

ANTERIOR COMPARTMENT

The basic topography of the anterior compartment is simple (Fig. 1.10). In the midline there are two tubes: the respiratory tract (larynx and trachea) in front and digestive tract (pharynx and esophagus) behind. The thyroid gland clasps the front and sides of the larynx and trachea and overlaps the carotid tree on either side. These structures are bounded anteriorly by pretracheal fascia, which extends on either side to merge with the investing layer of deep cervical fascia deep to sternocleidomastoid.

On either side of the midline tubes are several ascending and descending neurovascular structures, such as carotid tree consisting of common carotid, internal carotid and external carotid arteries, internal jugular vein and last four cranial nerves. At the upper end these structures enter or leave the skull through various foramina in the base of the skull, *viz.* foramen ovale, foramen spinosum, carotid canal, and jugular foramen.

POSTERIOR COMPARTMENT

The posterior compartment of neck consists of cervical part of vertebral column and its surrounding musculature (Fig. 1.10). This musculoskeletal block is bounded by prevertebral fascia, which merges behind on either side with the deep fascia enclosing the trapezius muscle. The

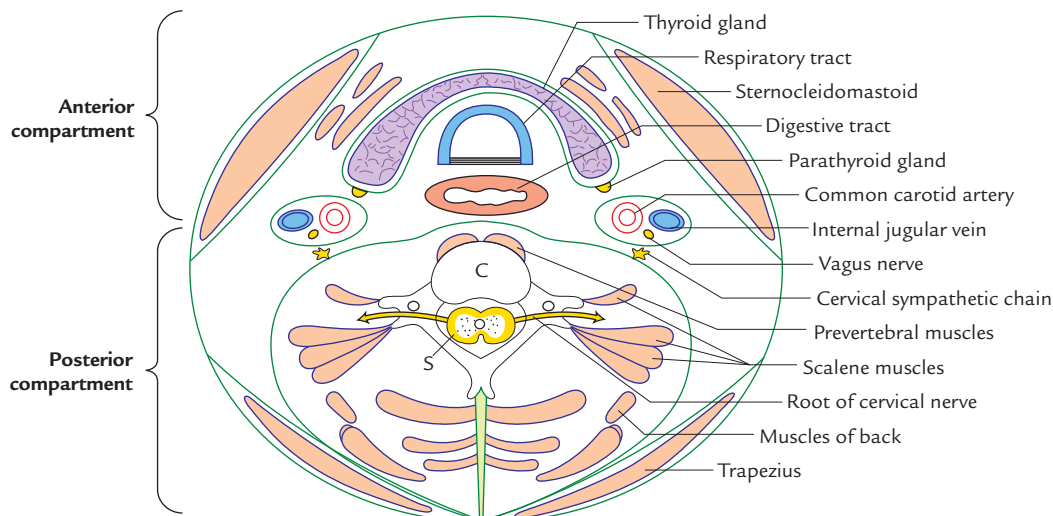


Fig. 1.10 Cross section of the neck showing anatomical details (S = spinal cord, C = cervical vertebra).

musculature includes: (a) prevertebral muscles located in front of the cervical column, (b) scalene muscles extending between the neck and upper two ribs, and (c) muscles of the back of the neck.

The vertebral canal within the cervical vertebral column provides passage to the spinal cord. The roots of cervical spinal nerves come out through intervertebral foramina in this region. The ventral rami of the first four cervical nerves form the cervical plexus and ventral rami of the lower four cervical nerves along with ventral ramus of T1 form the brachial plexus.

The neck, therefore, is a complex region of the body. The spinal cord, digestive and respiratory tracts, and major blood vessels traverse this highly flexible area. The neural structures present in the region include: last four cranial nerves and cervical and brachial plexuses. Several organs are also located here. The musculature of neck produces an array of movements in this area. The layout of these structures is depicted in Figure 1.11 to understand the topography of the neck.

N.B. A newborn baby has no visible neck because his or her lower jaw and chin touches the shoulders and thorax.

REGIONS OF THE NECK

The neck is divided into the four regions:

1. Anterior region.
2. Right lateral region.
3. Left lateral region.
4. Posterior region (nucha).

ANTERIOR REGION (CERVIX)

The anterior region of the neck contains strap muscles, digestive (pharynx and esophagus) and respiratory (larynx

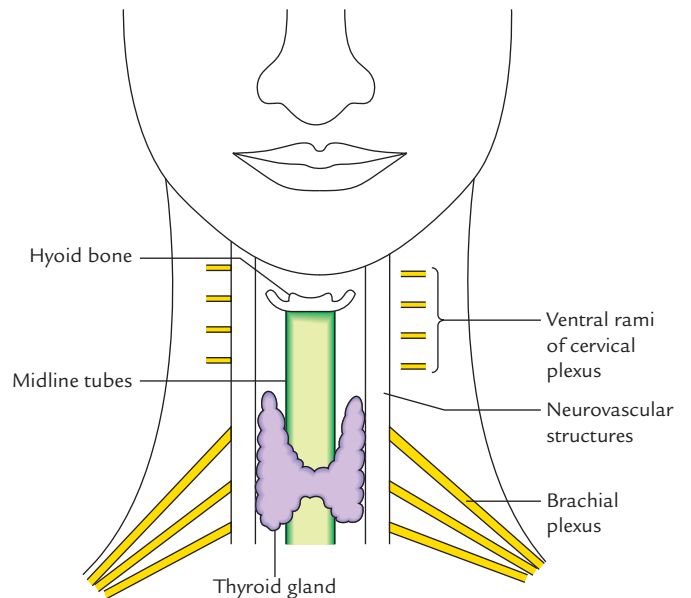


Fig. 1.11 Basic layout of structures of the neck.

and trachea) tracts, vessels to and from the head, last four cranial nerves, and thyroid and parathyroid glands.

The following structures can be easily palpated in the anterior region of the neck.

In the midline (Fig. 1.12):

1. **Hyoid bone:** It is situated in a depression behind and slightly below the chin and can be easily felt if the neck is slightly extended. The hyoid bone can be gripped between the thumb and index finger and moved from side to side.
2. **Thyroid cartilage:** It is the most prominent feature in the anterior region of the neck, particularly the anterior angle formed by the fusion of its two laminae which

form the laryngeal prominence. It is prominent in males and called *Adam's apple* whereas in females it is not usually apparent. The thyroid notch, the curved upper border of the thyroid cartilage can be easily palpated.

3. **Cricoid cartilage:** It can be easily palpated below the thyroid cartilage.
4. **Tracheal rings:** These can be palpated below the cricoid cartilage by pressing gently backwards above the jugular notch.
5. **Isthmus of the thyroid gland:** It lies on the front of the 2nd, 3rd, and 4th tracheal rings and can be palpated.
6. **Suprasternal (jugular) notch:** It is a depression just superior to sternum between the medial expanded ends of the clavicle and can be easily palpated.

The vertebral levels of some of the structures that can be palpated in the anterior midline of the neck are given in Table 1.2.

Table 1.2 Vertebral levels of structures in the anterior midline of the neck

Structure	Vertebral level
Hyoid bone	C3
Upper border and notch of thyroid cartilage	C3/C4
Thyroid cartilage	C4–C5
Cricoid cartilage	C6
Suprasternal notch	T2/T3

On either side of the midline (Fig. 1.12):

1. **Thyroid lobe:** It can be palpated on either side just below the level of cricoid cartilage.
2. **Common carotid artery:** It can be observed and palpated on either side at the level of junction between the larynx and trachea along the anterior border of sternocleido-mastoid muscle.

The common carotid artery can be compressed against the prominent anterior tubercle of transverse process of the 6th cervical vertebra called *carotid tubercle* (*Chassaignac's tubercle*).

RIGHT AND LEFT LATERAL REGIONS (RIGHT AND LEFT SIDES OF THE NECK)

The lateral regions on either side are composed of two large superficial muscles of the neck and cervical lymph nodes.

The following structures can be palpated in the lateral region:

1. **Mastoid process:** It can be easily felt behind the lower part of the auricle.

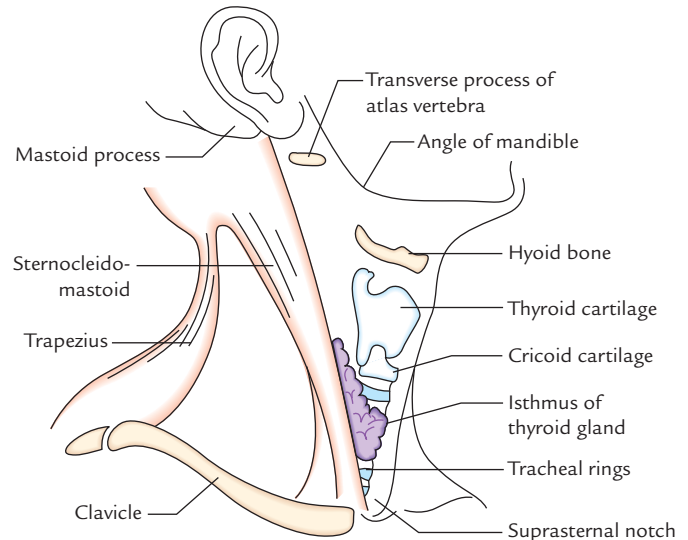


Fig. 1.12 Surface landmarks in the anterior median and lateral regions of the neck.

2. **Clavicle:** It is easily visible in thin people and palpable along its entire extent except in morbidly obese persons because it is subcutaneous throughout.
3. **Sternocleidomastoid:** It can be palpated along its entire length. When the head is turned to the opposite side it forms a prominent raised ridge that extends diagonally from mastoid process to sternum. The tendon of this muscle becomes especially prominent to the side of the jugular notch.
4. **Trapezius:** The anterior border of trapezius becomes prominent when the person is asked to shrug his shoulder against the resistance.
5. **External jugular vein:** It can be seen as it crosses obliquely across the sternocleidomastoid muscle, particularly if a person is angry or if the collar of his shirt is too tight.
6. **Transverse process of the atlas vertebra:** It can be felt on deep pressure midway between the angle of the mandible and the mastoid process.

Clinical correlation

Cervical lymph nodes in the lateral region of the neck often become swollen and painful from infections of the oral and pharyngeal regions.

POSTERIOR REGION (OR NUCHA)

The posterior region of neck includes cervical vertebral column, spinal cord, and associated structures.

The following structures can be palpated in the posterior region of the neck (Fig. 1.13).

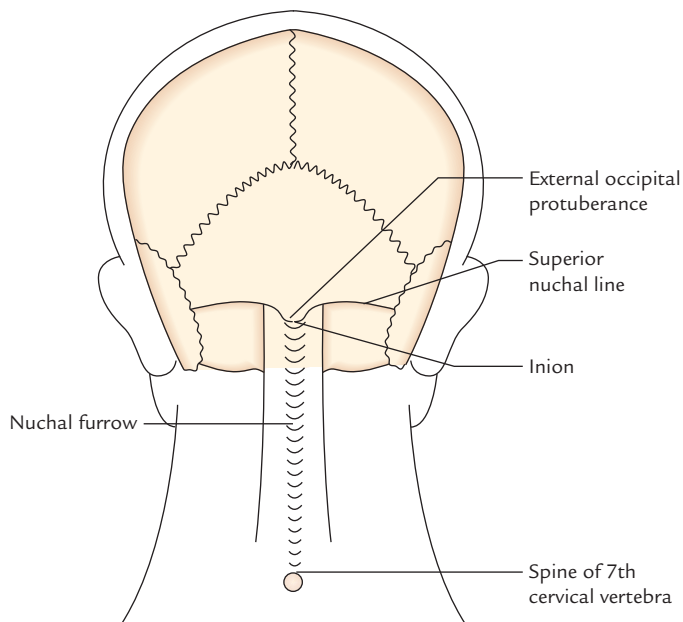


Fig. 1.13 Surface landmarks in the posterior region of the neck.

1. **External occipital protuberance:** It can be easily palpated with inion at its summit at the upper end of nuchal furrow in the posterior midline of the neck.
2. **Superior nuchal line:** It can sometimes be palpated as a curved bony line with concavity below extending from external occipital protuberance to the mastoid process.
3. **Spine of 7th cervical vertebra (vertebra prominens):** It can be felt at the lower end of nuchal furrow especially when the neck is flexed.

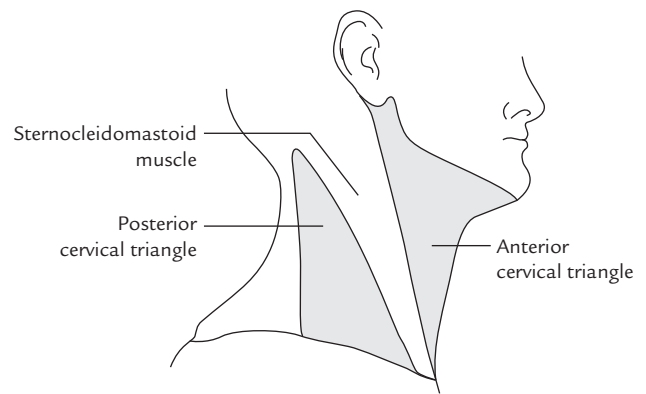


Fig. 1.14 Location of the anterior and posterior cervical triangles of the neck.

4. **Ligamentum nuchae:** It is raised when the neck is flexed and extends from spine of C7 vertebra below to the external occipital protuberance above.

Clinical correlation

Clinically, the posterior region of neck is extremely important because of the debilitating damage it sustains from whiplash injury or a broken neck.

TRIANGLES OF THE NECK

The neck is conventionally divided into various triangles. The sternocleidomastoid muscle transects the side of neck obliquely on each side and divides it into anterior and posterior cervical triangles (Fig. 1.14).

Golden Facts to Remember

- | | |
|--|---|
| ▶ Most expressive feature of the face | Eyes |
| ▶ Most projecting part of the face | Nose |
| ▶ Most important surface landmark of head which can neither be seen nor palpated | Pterion |
| ▶ Stiles' method of locating pterion | Place the thumb behind the frontal process of zygomatic bone and two fingers above the zygomatic arch. The angle between the thumb and upper finger lies on pterion |
| ▶ Most important surface landmark in the region of neck | Cricoid cartilage |
| ▶ Most prominent feature on the front of neck in the midline | Laryngeal prominence/Adam's apple |
| ▶ Chief characterizing facial feature of man | Nose |

Clinical Case Study



A 20-year-old medical student went to a hill station on his motorbike to enjoy his summer vacation. After enjoying his holidays, while returning home his bike hit a rock and overturned. He became unconscious. He was rescued and taken to a nearby hospital by some tourists. The attending physician first assessed the level of his consciousness using Glasgow coma scale. He regained consciousness by the time he was examined in the hospital. He had superficial wounds in the temporal region of his head but had no other obvious injuries. Radiographs of his skull were taken, which did not reveal any fracture or hematoma. He was discharged from the hospital one hour after being given first-aid.

Questions

1. Enumerate any four regions in cranial part of the head?
2. What is 'Glasgow coma scale'?
3. What are the boundaries of temporal region?

Answers

1. (a) Frontal region, (b) parietal region, (c) temporal region, and (d) occipital region.
2. It is a scale used to record the level of consciousness by testing certain functions and seeing their response. The baseline observation of this sort form an important first step in the assessment of

every case of head injury, and gives a good initial indication of the degree of brain damage.

Table C1 Glasgow coma scale (GCS)

Function tested	Response	Score
Eye opening	Spontaneous	4
	To verbal command	3
	To pain	2
	No response	1
Best verbal response	Oriented and converses	5
	Disoriented and converses	4
	Inappropriate words	3
	Incomprehensible sounds	2
	No response	1
Best motor response	Obeys verbal commands	6
	Localizes pain	5
	Flexes normally	4
	Flexes abnormally	3
	Extends	2
	No response	1

Total score ranges from 3 to 15 when the full scale is used.

3. The temporal region is bounded above by temporal line and below by zygomatic arch.

Osteology of the Head and Neck

The study of osteology (bony skeleton) of head and neck forms the basis to understand this region. *The skeleton of head and neck consists of skull, cervical vertebrae, and hyoid bone.* The students should study the skull and cervical vertebrae thoroughly relating their main features to the bony points which can be felt in a living individual. The prominences and depressions on the bony surface are landmarks for attachments of the muscles, tendons, and ligaments. The openings in the bone are also landmarks where various nerves and blood vessels enter or exit.

SKULL

The bony skeleton of the head is termed **skull**. It consists of 22 bones excluding ear ossicles. Except mandible (bone of lower jaw), all the bones of skull, joined together by sutures, are immobile and form the **cranium**. However, the two terms skull and cranium are generally used synonymously.

Parts of the Skull (Fig. 2.1)

The skull is subdivided into two parts:

- 1 An upper dome-shaped part which covers the cranial cavity containing brain is called *cranial vault/calvaria/brain box*. It is attached to the skull base below. The calvaria along with skull base is called **cranial skeleton/cranium**.
2. A lower anterior part is called **facial skeleton**, which includes mandible.

The cranium (cranial skeleton) is a strong and rigid container for the brain, while the facial skeleton is a rather fragile and light basis for face. The facial skeleton lies below the anterior part of the cranium in human beings.

Many anatomists use alternative terms, **neurocranium** for the cranial skeleton and **viscerocranium** for the facial skeleton.

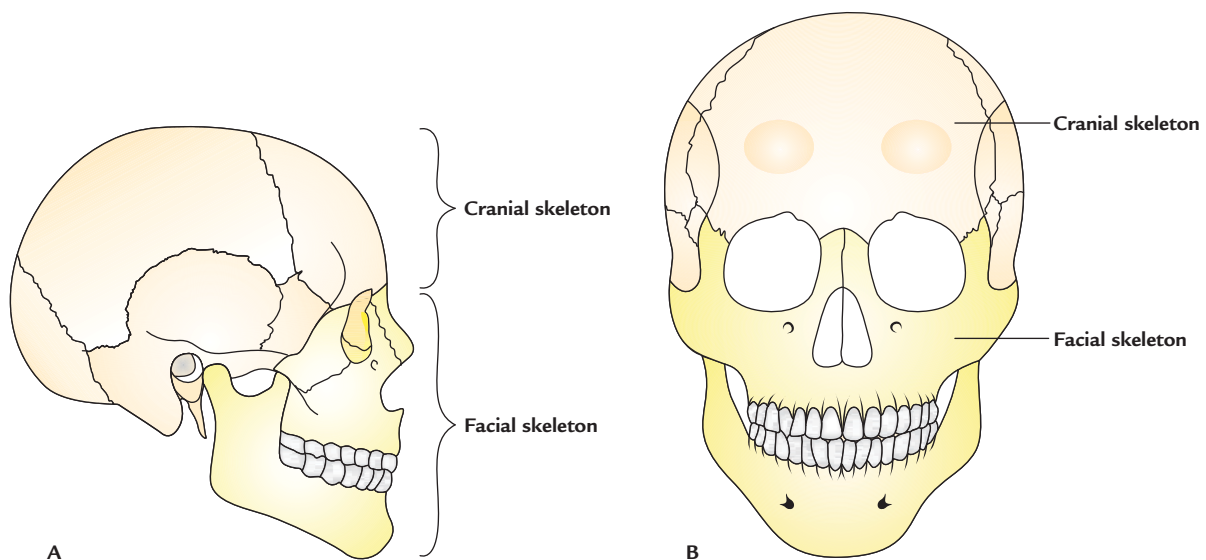


Fig. 2.1 Skull showing cranial skeleton (orange color) and facial skeleton (yellow color): A, lateral view; B, frontal view.

Functions of the Skull

The functions of the skull are:

1. Provides case for protection of the brain and its coverings (meninges).
2. Provides cavities for accommodation of organs of special senses such as sight, hearing, equilibration, smell, and taste.
3. Provides openings for the passage of air and food.
4. Accommodates teeth and jaws for mastication.

N.B. The term cranium (Gk. *cranium* = skull) is sometimes used to mean the skull without mandible.

BONES OF THE SKULL

The skull is made up of 22 bones, excluding ear ossicles.

1. **Cranial skeleton**, consisting of **8 bones**, out of which two are paired and four unpaired

Paired bones

- Parietal
- Temporal

Unpaired bones

- Frontal
- Occipital
- Sphenoid
- Ethmoid

2. **Facial skeleton**, consisting of **14 bones**, out of which six are paired and two unpaired:

Paired bones

- Maxilla
- Zygomatic
- Nasal
- Lacrimal
- Palatine
- Inferior nasal concha

Unpaired bones

- Mandible
- Vomer

JOINTS OF THE SKULL

The bones of the skull are united at immovable joints called **sutures**. The connective tissue uniting the bones is called **sutural ligament**. Exception to this rule is mandible for it is connected to the cranium by synovial temporomandibular joints, which are freely movable joints.

N.B. All the bones of the skull are immovable except for the mandible which permits free movements. The ear ossicles within the middle ear are also mobile, but conventionally they are not included in the skeleton of the head.

ANATOMICAL POSITION OF THE SKULL

It is the position of skull (Fig. 2.2) in which the orbital cavities are directed forwards, and lower margins (infraorbital margins) of the orbits and upper margins of external acoustic

meatuses lie in the same horizontal plane (**Frankfurt's plane**).

N.B. A horizontal line formed by joining the infraorbital margin and the center of external auditory meatus is called **Reid's baseline**.

STUDY OF SKULL AS A WHOLE

The study of skull as a whole is of greater importance to most health professionals than the study of unnecessary details of the individual bones.

The skull can be studied from outside or from inside (after removing the calvaria or skull cap).

EXTERIOR OF THE SKULL

The external features of the skull are studied from five different aspects, *viz.*

1. Superior aspect (*norma verticalis*).
2. Posterior aspect (*norma occipitalis*).
3. Anterior aspect (*norma frontalis*).
4. Lateral aspect (*norma lateralis*).
5. Inferior aspect (*norma basalis*).

When the skull is viewed from superior aspect it is called *norma verticalis*; when from posterior view, *norma occipitalis*; when from anterior aspect, *norma frontalis*; when from lateral aspect, *norma lateralis*; and when from inferior aspect, *norma basalis*.

Norma Verticalis (Fig. 2.3)

When the skull is viewed from above, it appears oval, being wider posteriorly than anteriorly.

It presents the following features:

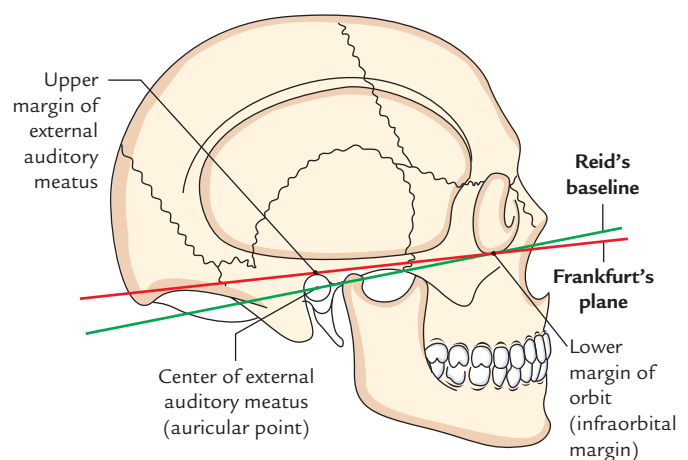


Fig. 2.2 Anatomical position of the skull.

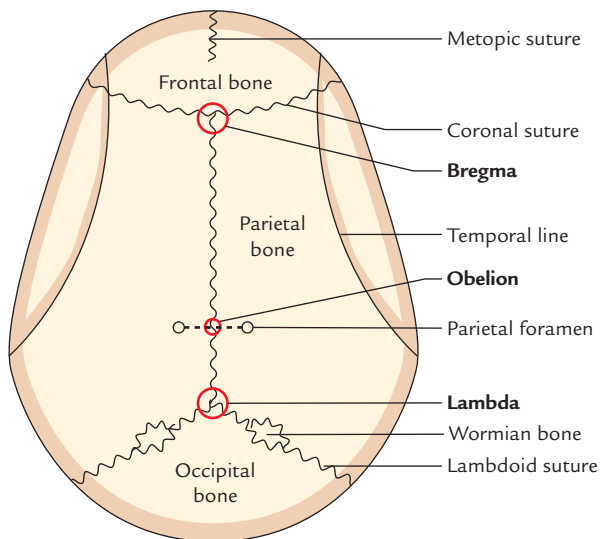


Fig. 2.3 Norma verticalis.

Bones and Sutures

The bones are frontal, parietal, and occipital. They are located as follows:

1. **Frontal bone** (squamous part) anteriorly.
2. **Parietal bones** (paired) on each side of midline.
3. **Occipital bone** (squamous part) posteriorly.

These bones are united by the following three sutures.

1. **Coronal suture** (L. = a crown), between frontal and two parietal bones. It crosses the cranial vault from side-to-side.
2. **Sagittal suture** (L. = an arrow), between two parietal bones. It lies in the median plane.
3. **Lambdoid suture**, between occipital and two parietal bones. It is shaped like the letter lambda, hence its name.

N.B.

- The **metopic suture** is occasionally present in the median plane of the frontal bone in 3–8% cases. It represents the remnants of suture between the two halves of the frontal bone in fetal skull, which develops by separate centres of ossification.
- Isolated **sutural bones**, ossified from separate centres are often seen along the lambdoidal suture.

Other Features

These are as follows:

1. **Bregma**: It is a point at which coronal and sagittal sutures meet.
2. **Parietal eminence/tuber**: It is an area of maximum convexity of parietal bone.
3. **Vertex**: It is the highest point on the skull. It lies on the sagittal suture near its middle and is situated a few centimeters behind the bregma.
4. **Parietal foramen**: It is a small foramen in parietal bone near sagittal suture, 2.5–4 cm in front of lambda.
5. **Obelion**: It is a point on sagittal suture between the two parietal foramina.

Norma Occipitalis (Fig. 2.4)

When the skull is viewed from behind, it appears convex upwards and on sides but flattened below.

It presents the following features:

Bones and Sutures

The bones seen in this view are posterior portions of parietal bones, the upper part of occipital bone, and mastoid parts of temporal bones. They are located as follows:

1. **Parietal bones**, superiorly one on each side.
2. **Occipital bone** (squamous part), inferiorly.
3. **Mastoid part of temporal bone**, inferolaterally on each side.

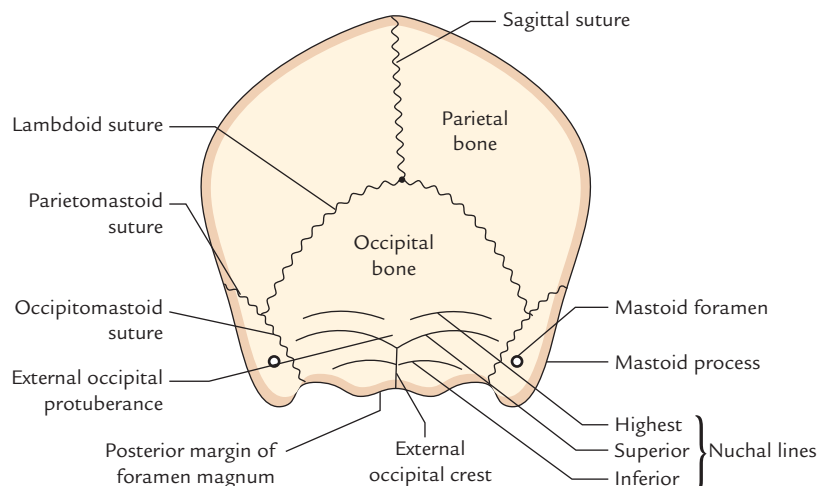


Fig. 2.4 Norma occipitalis.

The sutures which unite these bones are as follows:

1. **Lambdoid suture**, between occipital and two parietal bones.
2. **Occipitomastoid suture**, between occipital and mastoid part of temporal bone.
3. **Parietomastoid suture**, between parietal and mastoid part of temporal bone.

Other Features

The other features to be noted on the posterior aspect of the skull are:

1. **Lambda**: It is the point at which sagittal and lambdoid sutures meet.
2. **External occipital protuberance**: It is a median bony projection about midway between the lambda and the foramen magnum. The most prominent point of the external occipital protuberance is called **inion**.
3. **Superior nuchal lines**: These are curved bony ridges passing laterally on each side from external occipital protuberance. In some cases curved faint bony ridges are seen 1 cm above the superior nuchal lines. They are called **highest nuchal lines**.
4. **External occipital crest**: It is a vertical ridge between the external occipital protuberance and posterior margin of the foramen magnum.
5. **Inferior nuchal lines**: These are curved bony ridges passing laterally on each side from middle of the external occipital crest.
6. **Mastoid foramen**: It is present near the occipitomastoid suture.

Norma Frontalis (Fig. 2.5)

In frontal view, the skull appears oval, being wider above and narrower below.

The anterior aspect of the skull presents the following features:

1. Frontal region formed by frontal bone.
2. Orbital openings.
3. Prominences of the cheek formed by zygomatic bones.
4. Bony external nose and anterior nasal aperture.
5. Upper and lower jaws bearing teeth.

Frontal region formed by frontal bone: The frontal region or the forehead is formed by the squamous part of the frontal bone. Below on each side of median plane, it articulates with the nasal bones. Frontal region presents the following features: superciliary arches, glabella, and frontal eminences. They are already described in Chapter 1.

Orbital openings: These are the openings of two orbital cavities on the face. Each opening is present above and lateral to the anterior nasal aperture. It is quadrangular in shape and presents four margins, *viz.* supraorbital, lateral, infraorbital, and medial.

1. The **supraorbital margin** is formed entirely by the frontal bone. At the junction of its lateral two-third and medial one-third, there is a notch called **supraorbital notch** (or foramen in some skulls), through which passes the supraorbital nerve and vessels.
2. The **lateral orbital margin** is formed by the frontal process of zygomatic bone and zygomatic process of frontal bone.

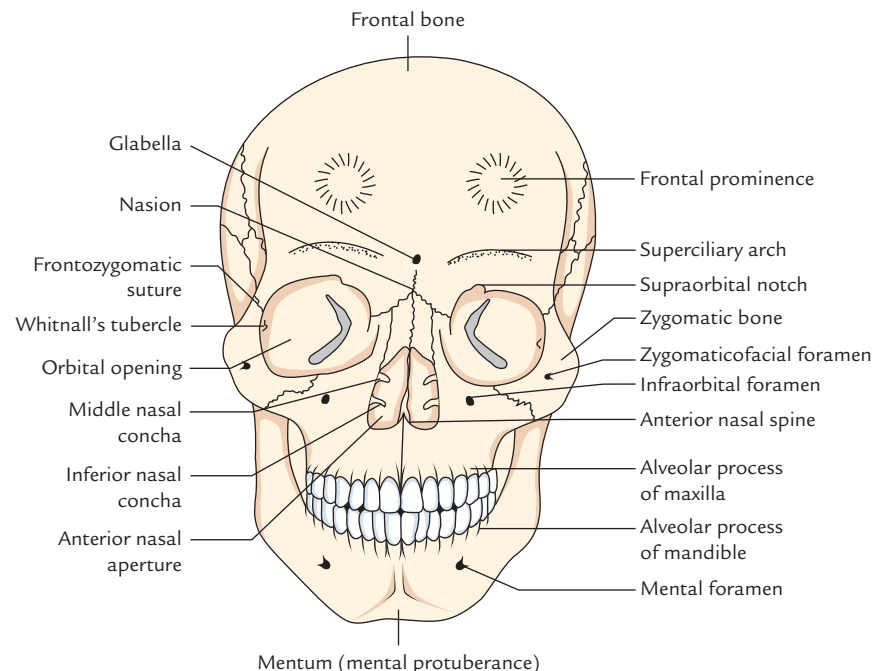


Fig. 2.5 Norma frontalis.

- The **infraorbital margin** is formed by the zygomatic bone laterally and the maxilla medially.

Below this margin the maxilla presents an opening called **infraorbital foramen** through which passes the infraorbital nerve and vessels.

- The **medial orbital margin** is ill-defined as compared to other margins. It is formed by the frontal bone above and the anterior lacrimal crest of the maxilla below.

Prominences of the cheek formed by zygomatic bones (malar bones): Each prominence is situated on the lower and lateral side of the orbit and rests on the maxilla. It is marked by a foramen called *zygomaticofacial foramen*.

Bony external nose and anterior nasal aperture: The *bony external nose* is formed by the nasal bones and maxillae. It terminates in front and below as piriform aperture of the nose called *anterior nasal aperture* which is bounded above by the nasal bones, and laterally and below on each side by the nasal notches of the maxillae.

The two nasal bones articulate in the midline with each other at internasal suture, *posteriorly* with frontal process of maxilla and *superiorly* with frontal bone at the frontonasal suture. Anterior nasal spine is a sharp bony projection which marks the meeting of the two maxillae in the lower boundary of the anterior nasal aperture.

Upper and lower jaws: The *upper jaw* is formed by two maxillae. On the anterior aspect each maxilla presents:

- a *zygomatic process*, which extends laterally and articulate with the zygomatic bone,
- a *frontal process*, which projects upwards and articulates with the frontal bone,
- an *alveolar process*, which carries the upper teeth, and
- the *anterior surface of the maxilla*, which presents: nasal notch medially; infraorbital foramen 1 cm below the infraorbital margin; incisive fossa above the incisor teeth; canine fossa lateral to canine eminence produced by the root of canine tooth.

The *lower jaw* is formed by the mandible. The upper border, also called **alveolar process of the mandible**, carries the lower teeth (mandible is described in detail on page 24).

Bones and Sutures

As discussed, the following **bones** are seen when skull is viewed from the front:

- Frontal bone**, forming the forehead.
- Nasal bones** (right and left), forming the bridge of the nose.
- Maxillae** (right and left), forming the upper jaw.
- Zygomatic bone** (right and left), forming the malar prominences.
- Mandible**, forming the lower jaw.

The **sutures** seen in this view are as follows:

- Frontonasal.**
- Internasal.**
- Frontomaxillary.**
- Zygomaxillary.**

Other Features

In addition to the above, the following features should be noted in the median plane and lateral regions of the anterior aspect of the skull:

- In the **median plane**:
 - Glabella*, a median elevation above the nasion and between the superciliary arches.
 - Nasion*, a median point at the root of the nose where the internasal and frontonasal sutures meet.
 - Anterior nasal spine*, a sharp bony projection in the median plane, in the lower boundary of the piriform aperture.
 - Symphysis menti*, a median ridge joining two halves of the mandible.
 - Mental protuberance*, a triangular elevation at the lower end of symphysis menti.
 - Mental point (gnathion)*, middle point of the base of the mandible.
- In the **lateral region (from above downwards)**:
 - Frontal prominence*, a low rounded elevation above the superciliary arch.
 - Three foramina* lying in same vertical plane, *viz.*
 - Supraorbital notch or foramen, at the junction of medial one-third and lateral two-third of the superior orbital margin.
 - Infraorbital foramen, 1 cm below the infra-orbital margin.
 - Mental foramen, below the interval between two premolar teeth.
 - An *oblique line on the body of the mandible*, extending between mental tubercle and lower end of anterior margin of ramus of the mandible.

Norma Lateralis (Fig. 2.6)

When skull is viewed from its lateral aspect it presents the following features:

Bones and Sutures

The **bones** seen on the lateral aspect of skull are frontal, parietal, occipital, temporal, sphenoid, zygomatic, mandible, maxilla, and nasal.

The **sutures** seen on this aspect of the skull are as follows:

- Coronal suture** (discussed previously on page 14).

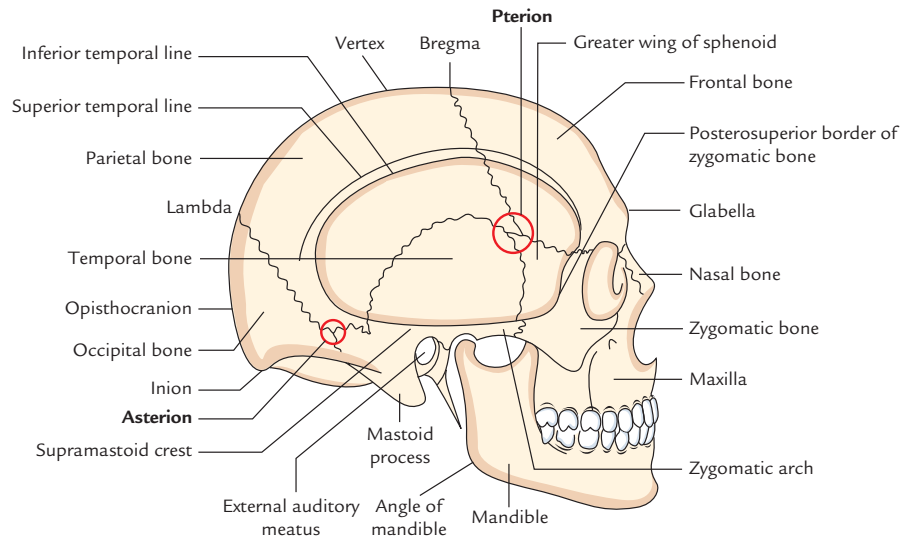


Fig. 2.6 Norma lateralis.

2. **Parietosquamosal suture**, between parietal and squamous part of temporal bones.
3. **Lambdoid suture** (discussed previously on page 14).

Other Features

The other features to be noted on the lateral aspect of the skull are as follows:

1. **Temporal line:** It commences at the frontal process of the zygomatic bone, arches upwards and backwards across the parietal bone where it splits into superior and inferior temporal lines. Traced behind, the superior temporal line fades away whereas prominent inferior temporal line curves downwards and forwards across the squamous part of the temporal bone as the **supramastoid crest**, which is continuous with the superior root of zygomatic process.
2. **Zygomatic arch:** It is a horizontal bar of bone formed by temporal process of zygomatic bone and zygomatic process of temporal bone. It presents two surfaces (outer and inner) and two borders (upper and lower). The upper border is continuous in front with the temporal line through posterosuperior border of the zygomatic bone, and behind with the *supramastoid crest*. The posterior end of lower border is marked by a tubercle called *tubercle of root of zygo*. Here zygomatic process of temporal bone divides into anterior and posterior roots. The anterior root (*articular tubercle*) passes medially forming anterior boundary of *mandibular fossa*. The posterior root forms lateral boundary of mandibular fossa and terminates behind into a small *postglenoid tubercle*.
3. **External acoustic meatus:** It is an opening just below the posterior root of the zygo. Its anterior wall, floor, and

lower part of the posterior wall are formed by tympanic part of the temporal bone, whereas its roof and upper part of the posterior wall are formed by the squamous part of the temporal bone.

4. **Suprameatal triangle (triangle of McEwen; Fig. 2.19):** It is a small depression posterosuperior to the external auditory meatus. It is bounded above by supramastoid crest in front by posterosuperior margin of external acoustic meatus and behind by a vertical tangent to the posterior margin of the meatus.

The mastoid antrum lies 1.25 cm deep to this triangle. A small bony projection called *suprameatal spine (spine of Henle)* may be present in the anteroinferior part of this triangle.

5. **Mastoid process:** It is a mamma-like process of temporal bone extending downwards behind the meatus.
6. **Asterion:** It is a meeting point of parietomastoid, occipitomastoid, and lambdoid sutures.
7. **Styloid process:** It is a thin long bony process of temporal bone, anterolateral to the mastoid process below and behind the external auditory meatus. Its base is partly ensheathed by tympanic plate. It is directed downwards forwards and slightly medially.
8. **Temporal fossa:** It is a shallow depression on the side of the skull bounded above by the temporal line and below by zygomatic arch and supramastoid crest (laterally), and infratemporal crest of sphenoid (medially). It communicates with the infratemporal fossa through a gap between the zygomatic arch and the side of the skull.

The region in the anterior part of the temporal fossa where four bones (frontal, parietal, squamous temporal,

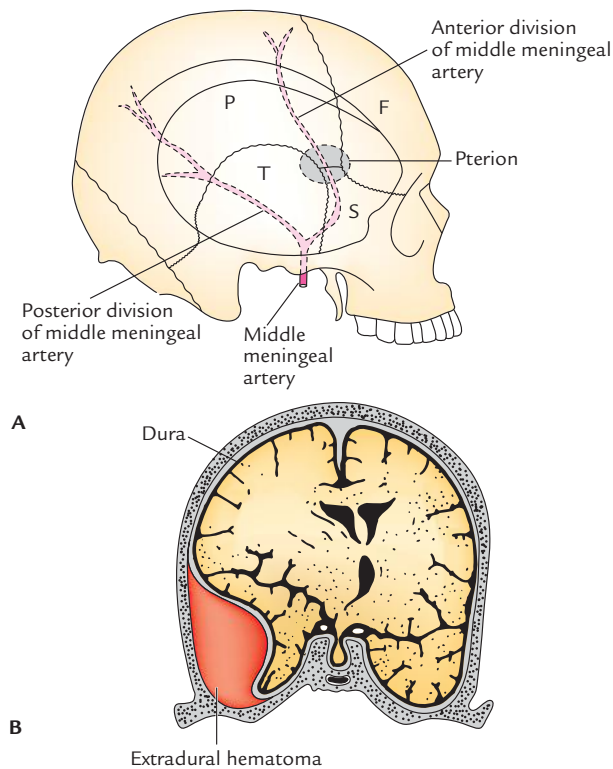


Fig. 2.7 Pterion and extradural hematoma: A, relationship of anterior division middle meningeal artery to pterion; B, extradural hematoma. (Source: Fig. 6.37, Page 355, *Clinical and Surgical Anatomy, 2e*, Vishram Singh, Copyright Elsevier 2007, All rights reserved.)

and greater wing of the sphenoid) meet to form an H-shaped suture is called **pterion**. It is situated 4 cm above the midpoint of the zygomatic arch.

9. **Infratemporal fossa:** It is the region on the side skull, below the zygomatic arch. It is bounded medially by lateral pterygoid plate and laterally by ramus of the mandible. It is described in detail in Chapter 10.
10. **Pterygomaxillary fissure:** It is a triangular gap between the body of maxilla and lateral pterygoid plate of sphenoid. The infratemporal fossa communicates with the pterygopalatine fossa through this fissure. The pterygopalatine fossa is described in Chapter 10.

Clinical correlation

Fracture of pterion: The pterion overlies the anterior division of middle meningeal artery, which ruptures following a blow in this region to form an extradural hematoma [a clot formation between the skull bone and the dura mater (Fig. 2.7)]. The clot, if big, may compress the brain leading to unconsciousness or even death. Therefore, it should be removed as early as possible by *trephination* or *craniotomy*.

Norma Basalis (Fig. 2.8)

For the sake of convenience of study, the norma basalis (undersurface of the skull) is divided into three regions/

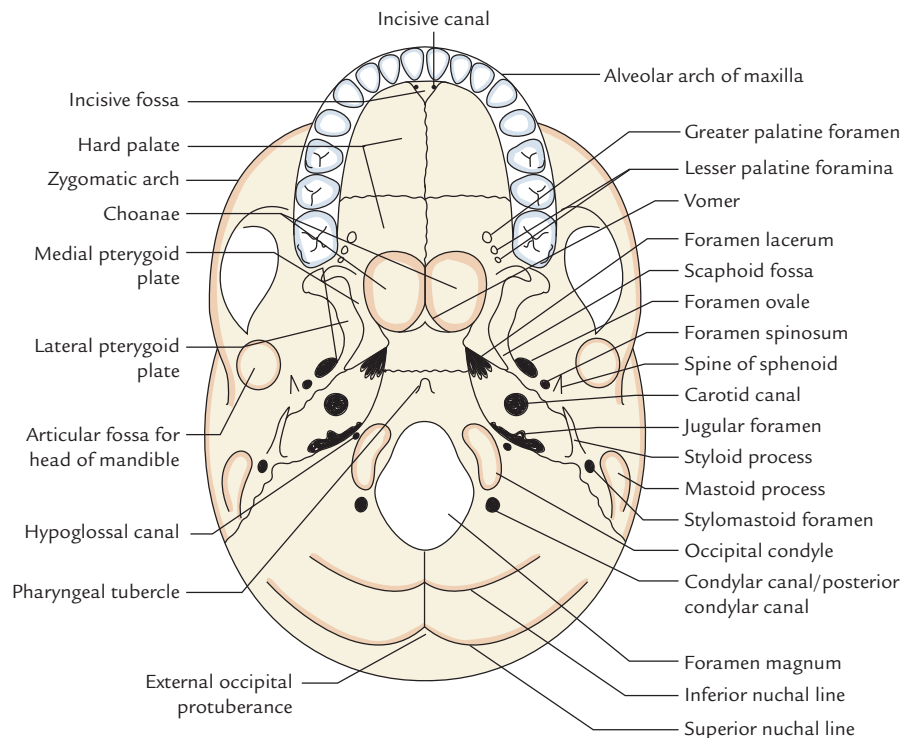


Fig. 2.8 Norma basalis.

parts: anterior, middle, and posterior by two imaginary transverse lines, viz.:

1. **Anterior transverse line**, which passes along the posterior-free margin of the hard palate.
2. **Posterior transverse line**, which passes along the anterior margin of the foramen magnum.

Anterior Part of Norma Basalis

It is formed by hard palate and alveolar processes of the maxillae.

Features in the anterior part of norma basalis are as follows:

1. **Alveolar arch**: The alveolar processes of two maxillae forms a U-shaped ridge of bone called *alveolar arch*, which bears the sockets for the roots of upper teeth.
2. **Hard palate**: It is formed by two pairs of bony processes: (a) palatine processes of maxillae in front (anterior two-third) and (b) horizontal plates of palatine bones behind (posterior one-third). The hard palate presents intermaxillary, interpalatine, and palatamaxillary sutures. The hard palate is described in detail in Chapter 14.

Middle Part of Norma Basalis

It extends from posterior margin of the hard palate to an imaginary transverse line that crosses the anterior margin of the foramen magnum.

Features in the middle part are as follows:

1. **The median area**: It presents –
 - (a) *Posterior border of vomer*: The two posterior nasal apertures (choanae) are separated by the posterior border of vomer.
 - (b) *Broad bar of bone*: It is formed by the fusion of the body of sphenoid and basilar part of the occipital bone. It is marked in the median plane by **pharyngeal tubercle**, a little in front of foramen magnum.
2. **The lateral area**: It presents –
 - (a) *Pterygoid process*: This process projects downwards from the junction between the body and greater wing of sphenoid behind last molar tooth. It divides into *medial and lateral pterygoid plates*, which are separated from each other by pterygoid fossa. Each plate has a free posterior border. The upper end of posterior border of medial pterygoid plate encloses a triangular depression called **scaphoid fossa**, and the lower end bears a hook-like process called **pterygoid hamulus**.
 - (b) *Infratemporal surface of the greater wing of sphenoid*: It presents:
 - (i) Four margins, viz.
 - *Anterior margin*, forms the posterior margin of inferior orbital fissure.

- *Anterolateral margin*, forms the infra-temporal crest.
 - *Posterolateral margin*, articulates with the squamous part of temporal bone.
 - *Posteromedial margin*, articulates with petrous part of temporal bone.
- (ii) Four foramina, all located along the postero-medial margin, viz.
 - *Foramen spinosum*, a small circular foramen at the base of spine of sphenoid.
 - *Foramen ovale*, a large oval foramen anterolateral to the upper end of the posterior border of the lateral pterygoid plate.
 - *Emissary sphenoidal foramen (foramen of Vesalius)*, a small foramen sometimes present between the foramen ovale and the scaphoid fossa.
 - *Canaliculus innominatus*, a very small foramen present between foramen ovale and spinosum. The structures passing through the above foramina are described in Chapter 21.
 - (iii) Spine of sphenoid, is a small sharp bony projection posterolateral to the foramen spinosum.

Clinical correlation

Fracture/necrosis of spine of sphenoid: Two nerves are related to the spine of sphenoid: *auriculotemporal nerve* on its lateral aspect and *chorda tympani* on its medial aspect.

Both these nerves carry secretomotor fibres to salivary glands—the auriculotemporal nerve to the parotid and chorda tympani to the submandibular and sublingual salivary glands.

Both these nerves would be damaged following fracture or necrosis of the spine. This will result in decreased salivation and loss of taste sensations in the anterior two-third of the tongue.

- (c) *Sulcus tubae (groove for auditory tube)*: It is a groove between the posterolateral margin of greater wing of the sphenoid and petrous temporal bone. It lodges the cartilaginous part of the auditory tube.
- (d) *Inferior surface of the petrous temporal bone*: It is triangular and presents an *apex*, which forms its anteromedial end. The apex is perforated by upper end of carotid canal and separated from the sphenoid by **foramen lacerum**.
- (e) *Downward edge of tegmen tympani*: It divides the squamous tympanic fissure into petrotympanic and petrosquamous parts.

Posterior Part of Norma Basalis

It is behind the imaginary transverse line passing along the anterior margin of the foramen magnum.

Features in the posterior part are as follows:

- The **median area** presents the following structures from backwards:
 - Foramen magnum
 - External occipital crest
 - External occipital protuberance
- The **lateral area** presents:
 - Occipital condyles*: These are oval condylar processes, one on each side of foramen magnum.
 - Hypoglossal canal*: It is located anterosuperior to occipital condyle.
 - Condylar fossa*: It is small fossa located behind the occipital condyle. Sometimes it is perforated by a canal called *condylar (posterior condylar) canal*.
 - Jugular process of occipital bone*: It lies lateral to occipital condyle and forms the posterior boundary of jugular foramen.
 - Jugular foramen*: It is a large elongated foramen at the posterior end of the *petro-occipital suture*. Its anterior wall is hollowed out to form the jugular fossa.
 - Tympanic canaliculus*: It opens on the thin edge of the bone between the jugular fossa and the lower end of the carotid canal.
 - Stylomastoid foramen*: It is situated posterior to the root of the styloid process.

N.B. It is interesting to note that foramen ovale, foramen lacerum, and line of fusion of the body of the sphenoid with basilar part of occipital bone lie in same transverse line

(Fig. 2.9). Similarly, anterior border of mastoid process, stylomastoid foramen, jugular foramen, and hypoglossal canal lie in the same transverse line (Fig. 2.9).

DIFFERENCES BETWEEN MALE AND FEMALE SKULLS

The sex-related differences of the skull are enumerated in Table 2.1.

Table 2.1 Features of male and female skulls

	Male	Female
Bones	Thicker and heavier	Thinner and lighter
Cranial capacity	More	Less
Muscular markings and ridges	Well-marked, hence seen prominently	Not well-marked
Superciliary arches	Prominent	Not prominent
Mastoid process	Prominent	Less prominent
Frontal and parietal tubers	Less prominent	Prominent

CRANIOMETRY

To compare skulls of different races and species, the physical anthropologists take various measurements of the skull. This process is called *craniometry*.

Cranial Points

The different points on the skull which are commonly used for taking measurements are as follows:

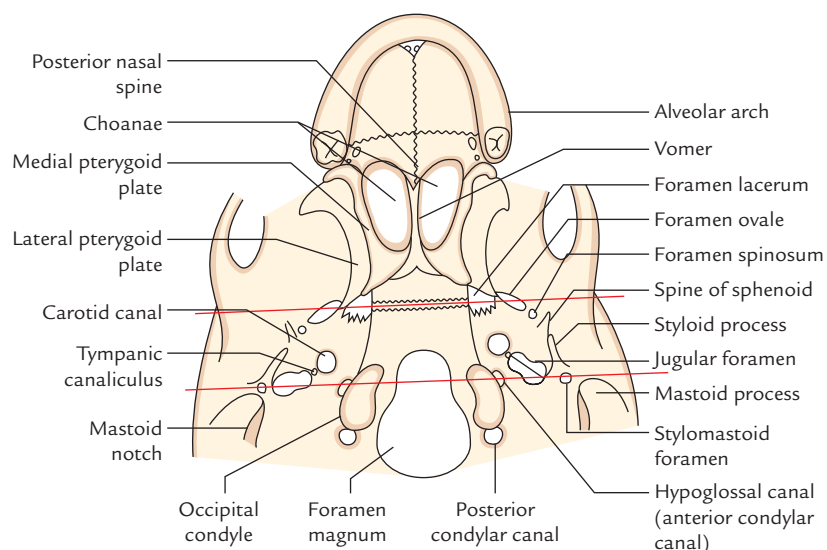


Fig. 2.9 Enlarged view of base of skull to show the features lying in the same imaginary transverse lines.

In the midline:

1. **Gnathion:** the midpoint of the chin at lower border of the mandible.
2. **Prosthion:** lowest point on the upper jaw between the central incisors.
3. **Acanthion:** anterior nasal spine.
4. **Nasion:** junction of nasal and frontal bones.
5. **Glabella:** midpoint at the level of superciliary arches.
6. **Bregma:** junction of coronal and sagittal sutures.
7. **Lambda:** junction of sagittal and lambdoid sutures.
8. **Opisthocranium (occipital point):** the most posteriorly projecting point on the occipital bone.
9. **Inion:** tip of external occipital protuberance.
10. **Opisthion:** central point on the posterior edge of the foramen magnum.
11. **Basion:** central point on the anterior edge of the foramen magnum.

At the side of the skull:

1. **Pterion:** region where frontal, parietal, greater wing of sphenoid, and squamous part of temporal bones meet.
2. **Dacryon:** junction of lacrimomaxillary and frontomaxillary sutures.
3. **Gonion:** outer side of the angle of the mandible.
4. **Porion:** point on the posterior root of the zygomatic arch above the middle of the upper border of external auditory meatus.
5. **Asterion:** region where occipital, parietal, and temporal bones meet.

The calvarial part of skull is measured as follows:

- Maximal cranial length: From centre of glabella to opisthocranium
- Maximus cranial breadth: Greatest breadth at right angle to the median plane
- Cranial height: From basion to bregma

The **cephalic index** is calculated as under:

$$\frac{\text{Maximum cranial breadth}}{\text{Maximum cranial length}} \times 100$$

N.B.

- If maximum width of cranium is less than 75% of its maximum length, it is called *dolichocephalic skull* (long headed individual).
- If maximum width of cranium is more than 80% of its maximum length it is called *brachycephalic skull* (broad headed individual).
- If ratio between maximum width of cranium and maximum length of cranium is between 75% and 80%, it is called *mesaticephalic*.

NEWBORN SKULL

The striking feature of the newborn skull is the huge size of its cranium and relatively small size of its facial skeleton. In newborn, the facial skeleton forms about 1/7th of the cranium. The facial skeleton is small and consists of tiny collection of bones, clustered under the anterior part of the cranium (Fig. 2.10).

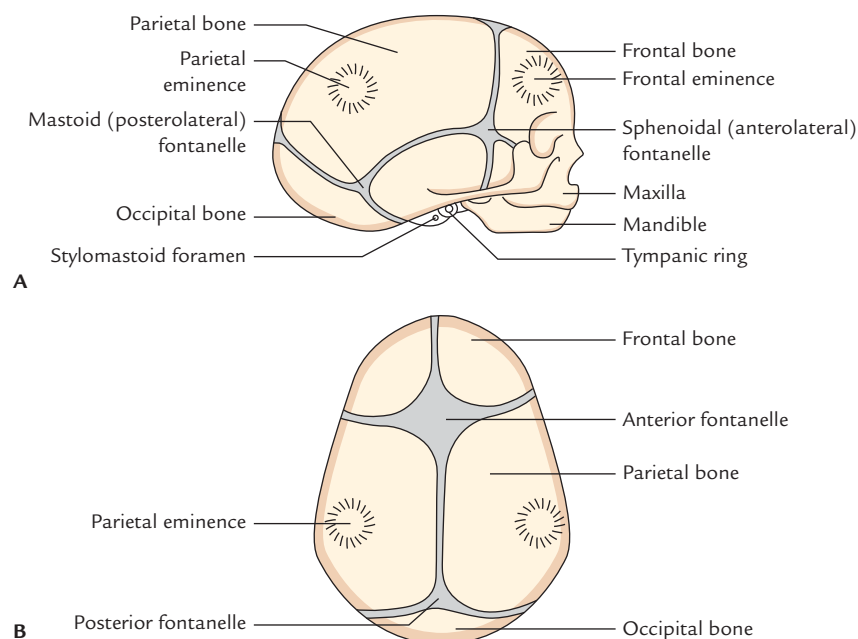


Fig. 2.10 Fetal skull to show the location of fontanelles: **A**, lateral aspect; **B**, superior aspect.

The huge size of the **cranium** is due to fast development of the brain. The brain reaches 25% of its adult size at birth and 75% by the age of 4 years.

The size of **facial skeleton** at birth is due to rudimentary stage of the mandible and maxillae, non-eruption of teeth and the small size of the maxillary air sinuses and the nasal cavity.

The following features of the newborn skull are clinically important:

1. **Fontanelles:** The bones of vault of skull are ossified in membrane. At birth, it is partly ossified and six unossified areas are seen between the bones which are called *fontanelles* (Fig. 2.10).

The fontanelles serve two important purposes, *viz.*

- (a) Permits some overlapping of the skull bones (moulding) during childbirth.
- (b) Permits growth of the brain.

Number of fontanelles: There are six fontanelles at birth situated at the four angles of the parietal bones. Two are, therefore, median (anterior and posterior) and four are lateral two (sphenoidal and mastoid) on each side. The **anterior fontanelle** is situated at the place where the two parietal bones and the two halves of the frontal bone come close together. It is largest and diamond shaped. It measures about 3–8 cm in length and 2–5 cm in breadth.

The **posterior fontanelle** is situated at the junction of the sagittal and lambdoid sutures. It is triangular in shape.

The **sphenoidal (anterolateral)** and **mastoid (posterolateral) fontanelles** are situated at the sphenoid and mastoid angles of parietal bones. They are small and irregular. Posterior fontanelle closes soon after birth, lateral fontanelles close within a few weeks of birth and anterior fontanelle closes by 2 years of age.

N.B. All fontanelles close around birth except anterior fontanelle which closes by two years of age.

Clinical correlation

The anterior fontanelle is largest and of great clinical significance. The degree of tenseness of the membrane gives an index of the intracranial pressure. An abnormal depression of membrane indicates dehydration (insufficiency of the body fluids). Further, the anterior fontanelle permits an access to the superior sagittal sinus as it lies just underneath it in the midline. Through its lateral angle a needle may be passed into the lateral ventricle of the brain.

2. **Tympanic cavity (middle ear cavity) and mastoid process:** The tympanum is a well-developed cavity at birth. The mastoid process does not begin to develop until the end of the second year. Before the mastoid process develops, the facial nerve is a subcutaneous structure and is in danger of being cut by an incision

behind the ear, if it extends too far down. In adult, it is 2.5–3.8 cm from the surface, being pushed to the base of the skull by the development of mastoid process. In infants, the middle ear cavity is separated from temporal lobe of brain only by a thin strip of cartilage, uniting the squamous and petrous parts of temporal bone. This cartilaginous strip is very thin and lies underneath the dura mater and temporal lobe of the brain. Therefore, infection of middle ear may spread through this cartilage to cause an extradural or temporal lobe abscess.

3. **Paranasal air sinuses:**
 - (a) Frontal air sinus does not exist at birth. It begins to develop during the first year and reaches its full development between 15th and 20th year.
 - (b) Maxillary air sinus is rudimentary at birth. It reaches its full development between 15th and 20th year.
4. **Mandible:** At birth, mandible is in two halves, united by the fibrous tissue at the symphysis menti.
5. **Frontal bone:** At birth, frontal bone is in two halves, united by the fibrous tissue in the midline. If it persists in the adult, it is called **metopic suture**.
6. **Basiocciput and basisphenoid:** Both these are united by a piece of hyaline cartilage (synchondrosis). It is responsible for growth of skull in length.

N.B. All the bones of the skull are in the process of ossification at birth except styloid process and the perpendicular plate of ethmoid.

Sutural (Wormian) Bones

These are small irregular bones found in the sutures. They are formed by additional ossification centres that may occur in or near sutures. They are most numerous in the lambdoid suture. Sometimes they occur at fontanelles, especially in lambdoidal and mastoid fontanelles. In lambdoidal fontanelle they may represent interparietal bone. An independent bone at lambda is called **Inca bone** or **Goethe's ossicle**. In the adult skull they are most common at the lambda and at the asterion. Rarely they may be seen at pterion (**epipteric bone**) and at bregma (**os Kerckring**). The wormian bones are common in hydrocephalic skulls.

N.B. The sutural bones are usually small and bilateral. The inca bone was common in the skull of Incas and is still present in their Andean descendants.

STRUCTURES PASSING THROUGH VARIOUS FORAMINA, CANALS, AND FISSURES OF THE SKULL

The total number of normal openings (foramina, canals, and fissures) in the skull is around 85, which provide passage to

various nerves and vessels. Some of these are of little significance as they provide passage to minor neurovascular structures of no clinical significance. Attention should, therefore, be paid to those openings which provide passage to major neurovascular structures such as openings for (a) spinal cord and vertebral arteries, i.e., foramen magnum, (b) internal jugular vein, i.e., jugular foramen, and (c) internal carotid artery, i.e., carotid canal.

In the Basis Cranii Interna (Internal Surface of the Base of Skull/Cranial Fossae)

The structures passing through various foramina in the cranial fossae are described in Chapter 21.

In the Basis Cranii External/Norma Basalis (Inferior Aspect of the Skull)

Lateral Incisive Foramina

They are two in number, right and left—present in the lateral wall of the incisive fossa and lead to the floor of the nasal cavity through incisive canal. They transmit:

1. Greater palatine vessels (terminal parts).
2. Nasopalatine nerve (terminal part): only when the median incisive foramina are absent.

Median Incisive Foramina

They are two in number, one present in the anterior and another in the posterior wall of the incisive fossa. They transmit:

1. Left nasopalatine nerve: passes through the one present in the anterior wall of the incisive fossa.
2. Right nasopalatine nerve: passes through the one present in the posterior wall of the incisive fossa.

Greater Palatine Foramen

One, on each side, located in the posterolateral angle of hard palate. It transmits:

1. Greater palatine nerves.
2. Greater palatine vessels.

Squamotympanic Fissure

Present between tympanic part (plate) of temporal bone and squamous part of temporal bone (mandibular fossa), it is divided by a down-turned part of tegmen tympani (a part of petrous temporal bone) into *petrotympanic* and *petrosquamous fissures*.

1. **Petrotympanic fissure transmits:**
 - (a) *Chorda tympani nerve*: a branch of facial nerve.
 - (b) *Anterior tympanic artery*: a branch of the first part of the maxillary artery.
 - (c) Anterior ligament of the malleus.
2. **Petrosquamous fissure:** no structure passes through it.

Palatovaginal Canal

Present between upper surface of sphenoidal process of palatine bone and lower surface of vaginal process of root of medial pterygoid plate (Fig. 2.26). It transmits:

1. Pharyngeal nerve: a branch from the pterygopalatine ganglion.
2. Pharyngeal artery: a branch of the third part of the maxillary artery.

Vomerovaginal Canal

Present between lower aspect of ala of vomer and upper aspect of vaginal process of root of medial pterygoid plate.

If present, it provides passage to:

1. Pharyngeal nerve: a branch from the pterygopalatine ganglion.
2. Pharyngeal artery: a branch of the third part of the maxillary artery.

Pterygoid Canal

Present in pterygoid process of the sphenoid bone connecting anterior wall of foramen lacerum to pterygopalatine fossa. It transmits:

1. Nerve of pterygoid canal (Vidian's nerve).
2. Vessels of the pterygoid canal.

Foramen Ovale

Foramen Spinosum

Emissary Sphenoidal Foramen

Foramen Lacerum

Described in Chapter 21

Carotid Canal

Located on inferior surface of the petrous temporal bone. It transmits:

1. Internal carotid artery with sympathetic plexus around it.
2. Internal carotid venous plexus connecting cavernous sinus and internal jugular vein.
3. Emissary vein connecting pharyngeal venous plexus and cavernous sinus.

Tympanic Canaliculus

Located on bony crest between carotid canal and jugular fossa and transmits:

1. Tympanic branch of glossopharyngeal (Jacobson's nerve).

Mastoid Canaliculus (Arnold's Canal)

Present in the lateral wall of the jugular fossa and transmits.

1. Auricular branch of vagus nerve (Alderman's nerve/Arnold's nerve).

Stylomastoid Foramen

Located between the roots of styloid and mastoid processes, at the anterior end of mastoid notch. It transmits:

1. Seventh cranial (facial) nerve.
2. Stylomastoid artery, a branch of posterior auricular artery.

Foramen Magnum

Hypoglossal (Anterior Condylar) Canal
Jugular Foramen

} Described in
Chapter 21

In the Norma Occipitalis (Posterior Aspect of the Skull)

Mastoid Foramen

Present on the posterior aspect of mastoid process near the occipitomastoid suture. It transmits:

1. Emissary vein, connecting the posterior auricular vein with transverse sinus.

In the Norma Lateralis (Lateral Aspect of the Skull)

Zygomatocotemporal Foramen

Present on the posteromedial surface of the zygomatic bone and transmits:

1. Zygomatocotemporal nerve.
2. Zygomatocotemporal artery.

Pterygomaxillary Fissure

Present between lateral pterygoid plate and posterior surface of the maxilla and transmits:

1. Third part of the maxillary artery: from infratemporal fossa to the pterygopalatine fossa.
2. Maxillary nerve: second division of the 5th cranial nerve (V2).

Sphenopalatine Foramen

Present in the roof of sphenopalatine fossa and transmits:

1. Nasopalatine nerve.
2. Sphenopalatine vessels.

Greater Palatine Canal

Present on either side between the palatine bone and maxilla. It transmits greater palatine nerve and vessels.

In the Norma Verticalis

Parietal Foramen

Present on the parietal bone near sagittal suture and transmits emissary vein, connecting superficial veins of the scalp to the superior sagittal sinus.

In the Norma Frontalis

Supraorbital Foramen/Notch

Present on the supraorbital margin and transmits:

1. Supraorbital nerve, a branch of frontal nerve which in turn is a branch of ophthalmic division of the 5th cranial nerve.
2. Supraorbital vessels.
3. Frontal diploic vein.

Superior Orbital Fissure

See page 346 Chapter 21.

Inferior Orbital Fissure

Present at the junction between floor and lateral wall of the orbit. It transmits:

1. Maxillary nerve.
2. Infraorbital vessels.
3. Zygomatic nerve.
4. Vein connecting inferior ophthalmic vein with pterygoid venous plexus.

Infraorbital Foramen

Present on the anterior aspect of maxilla, below the infraorbital margin and transmits:

1. Infraorbital nerve: continuation of maxillary nerve.
2. Infraorbital artery: continuation of maxillary artery.
3. Infraorbital vein.

Zygomatoco-orbital Foramen

Present on the orbital surface of zygomatic bone and transmits zygomatic branch of the maxillary nerve.

Mental Foramen

Present on the external aspect of body of mandible below the interval between premolar teeth and transmits:

1. **Mental nerve:** a branch of inferior alveolar nerve.
2. **Mental artery:** a branch of inferior alveolar artery.
3. **Mental vein:** a tributary of inferior alveolar vein.

STUDY OF INDIVIDUAL SKULL BONES

The following account is intended to provide the salient features of individual skull bones which are frequently asked in an oral examination.

MANDIBLE

The mandible is the bone of the lower jaw. It is the largest, strongest, and lowest bone of the face and bears the lower teeth.

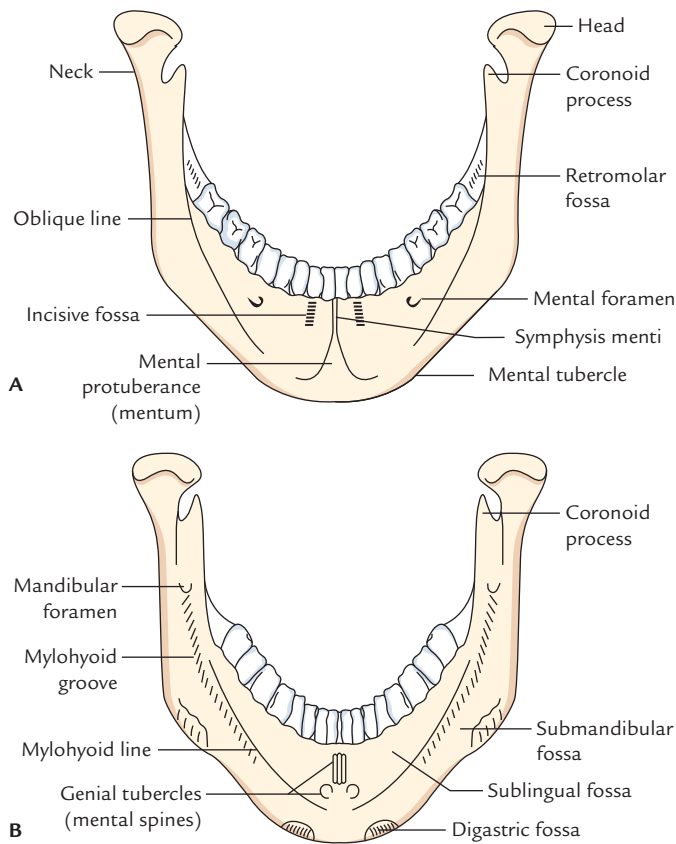


Fig. 2.11 Mandible: A, anterior view; B, posterior view.

Parts

The mandible is horseshoe-shaped and consists of **three parts**: a horizontally-oriented body and two vertically-oriented rami (Figs 2.11 and 2.12).

Body

The body of the mandible is U-shaped and it presents:

- Two surfaces**
 - External surface.*
 - Internal surface.*
- Two borders**
 - Superior border of the body* is called alveolar process. It bears sockets of lower 16 teeth.
 - Inferior border or base of the mandible* presents a small depression (**digastric fossa**) on either side near the median plane. It gives attachment to the anterior belly of the digastric.

Features on the external and internal surfaces of the body:

The **outer surface of the body** of the mandible presents the following features:

- Symphysis menti** (*mentum* = chin): It is a faint median ridge on the external surface of the body. It marks the

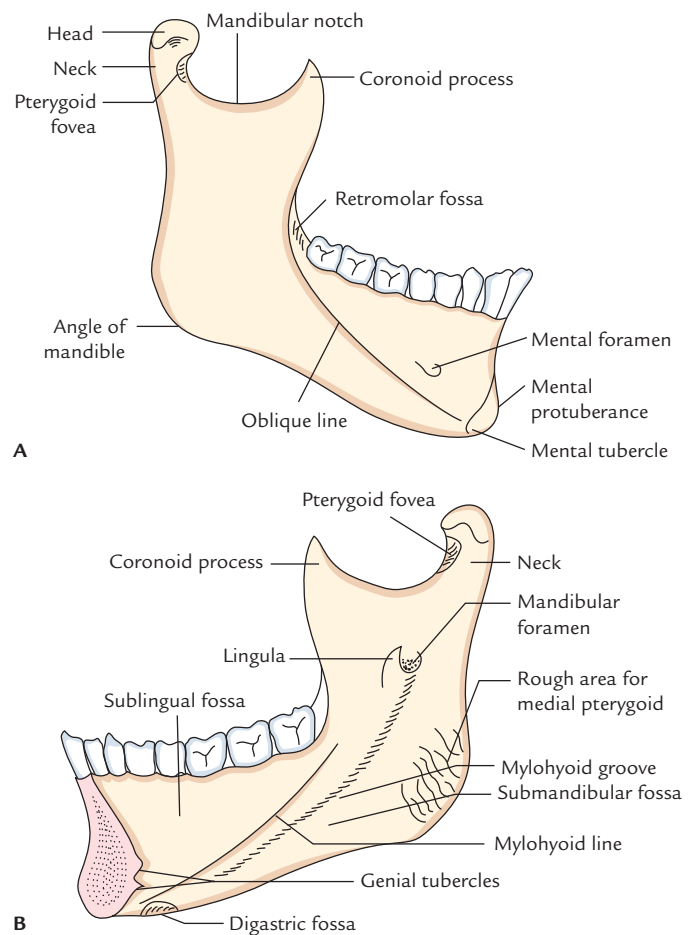


Fig. 2.12 Right half of the mandible: A, external aspect; B, internal aspect.

line of fusion of the two halves of the mandible at the age of 2 years. The symphysis menti expands below into a triangular elevation termed **mental protuberance**. It forms the **point of chin**, the base of which is limited on each side by the **mental tubercle**. The inner aspect of symphysis menti possesses four tubercles called **genial tubercles (mental spines)** arranged into two pairs: upper and lower. The upper pair provides attachment to genioglossus muscles and lower pair to geniohyoid muscles.

- Mental foramen:** It lies below the interval between the premolar teeth and provides passage to mental nerve and vessels.
- Oblique line:** It is the continuation of the anterior border of the ramus. It runs downwards and forwards towards the mental tubercle.
- Incisive fossa:** It is a shallow depression just below the incisor teeth.

The **internal surface of the body** in each half of the mandible presents the following features:

1. **Mylohyoid line** is a prominent oblique ridge that runs obliquely downwards and forwards from behind the 3rd molar tooth (about 1 cm below the alveolar border) to the symphysis menti below the genial tubercles.
2. **Mylohyoid groove** lies below the posterior end of the mylohyoid line. Mylohyoid nerve and vessels run in this groove.
3. **Sublingual fossa** is a shallow area above the anterior part of the mylohyoid line and lodges sublingual gland.
4. **Submandibular fossa** is a slightly hollowed out area below the posterior part of the mylohyoid line and lodges submandibular gland.

The **other features** on the inner and outer surfaces of the mandible are shown in Figures 2.11 and 2.12.

Muscles attached on the body of the mandible (Fig. 2.13): The various muscles attached to the body of the mandible are as follows:

1. **Buccinator:** arises from oblique line below the three molar teeth.
2. **Mylohyoid:** arises from mylohyoid line.
3. **Genioglossus:** arises from superior genital tubercle.
4. **Geniohyoid:** arises from inferior genital tubercle.
5. **Anterior belly of digastrics:** arises from digastric fossa on the base of mandible close to symphysis menti.
6. **Platysma:** inserted into the base.
7. **Superior constrictor:** arises from the area above the posterior end of the mylohyoid line.

Ramus of the Mandible

It is more or less a quadrilateral vertical plate of bone that projects upwards from the posterior part of the body.

Features

The ramus presents the following features:

1. **Two surfaces, viz.**
 - (a) Lateral surface.
 - (b) Medial surface.
2. **Four borders, viz.**
 - (a) Anterior.
 - (b) Superior (it is notched to form **mandibular notch**).
 - (c) Inferior.
 - (d) Posterior.
3. **Two processes, viz.**
 - (a) **Condylar process**, a strong upward projection from posterosuperior part. Its upper end is expanded to form head. Neck is the constricted part below head and presents a depression on its anterior surface called **pterygoid fovea**.
 - (b) **Coronoid process**, a flattened (side to side) triangular projection from anterosuperior part.

Angle of the Mandible

The meeting point between posterior and inferior borders of the ramus of mandible is called the **angle of the mandible**.

The features on the medial and lateral surfaces of the ramus of the mandible are shown in Figure 2.12.

The **lateral surface** of ramus is flat and bears a number of oblique ridges produced by masseter muscle.

The **medial surface** of the ramus presents the following features:

1. **Mandibular foramen:** It is located a little above the centre of ramus and leads into mandibular canal which runs downwards and forwards into the body to open on its external surface as **mental foramen**. It provides passage to:

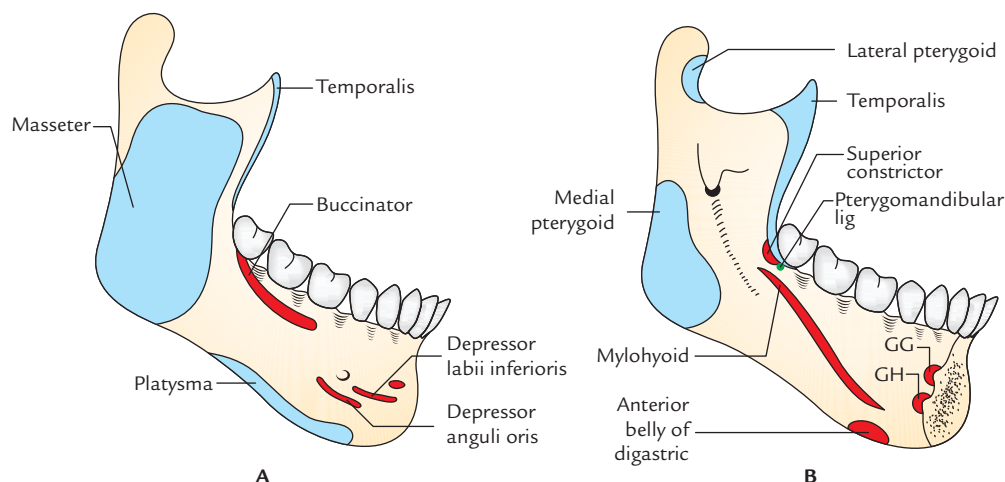


Fig. 2.13 Muscle attached to the mandible: A, lateral surface of the right half of the mandible; B, inner surface of left half of the mandible (GG = genioglossus, GH = geniohyoid).

- (a) *Inferior alveolar nerve*: a branch of the posterior division of the mandibular nerve.
 - (b) *Inferior alveolar artery*: a branch from the 1st part of the maxillary artery.
 - (c) *Inferior alveolar vein*.
2. **Lingula** is a small tongue-shaped projection on the anterior margin of the mandibular foramen.
 3. **Mylohyoid groove** begins just below the mandibular foramen and runs downwards and forwards to reach the body of mandible below the posterior part of mylohyoid line.

Muscles Attached to the Ramus of the Mandible (Fig. 2.13)

All the muscles of mastication are attached (inserted) into the ramus of mandible as under:

1. **Masseter** is inserted into the outer surface of the ramus.
2. **Temporalis** is inserted into the coronoid process on this tip, anterior border, and inner surface.
3. **Lateral pterygoid** is inserted into the pterygoid fovea present in front of the neck of the mandible.
4. **Medial pterygoid** is inserted into the inner surface of the ramus above the angle of the mandible.

Ligaments Attached to the Mandible (Fig. 2.14)

The following ligaments are attached to the mandible:

1. **Stylomandibular ligament** is attached to the angle of the mandible.
2. **Temporomandibular ligament** is attached to the lateral aspect of the neck of the mandible.
3. **Sphenomandibular ligament** is attached to the lingula of the mandible.

4. **Pterygomandibular raphe/ligament** is attached behind the last molar tooth to the upper end of mylohyoid line.

Nerves Related to the Mandible (Fig. 2.14)

The following nerves are related to the mandible:

1. **Lingual nerve** runs on the inner surface of the body close to the medial side of the root of the 3rd molar tooth.
2. **Inferior alveolar nerve** enters the mandibular foramen, and passes through the mandibular canal.
3. **Mylohyoid nerve** runs in the mylohyoid groove.
4. **Mental nerve** comes out of the mental foramen.
5. **Nerve to masseter (masseteric nerve)** runs through the mandibular notch.
6. **Auriculotemporal** runs to the medial side of the neck.
7. **Marginal mandibular nerve** across the lower border of the mandible.

Differences between Males and Females Mandibles

These are enumerated in Table 2.2.

Table 2.2 Differences between male and female mandibles

Features	Male mandible	Female mandible
Size	Larger and thicker	Smaller and thinner
Height of the body	Greater	Lesser
Angle of mandible	Everted	Inverted
Chin	Quadrilateral	Rounded
Inferior border of body of mandible	Irregular	Smooth
Condyles	Larger	Smaller

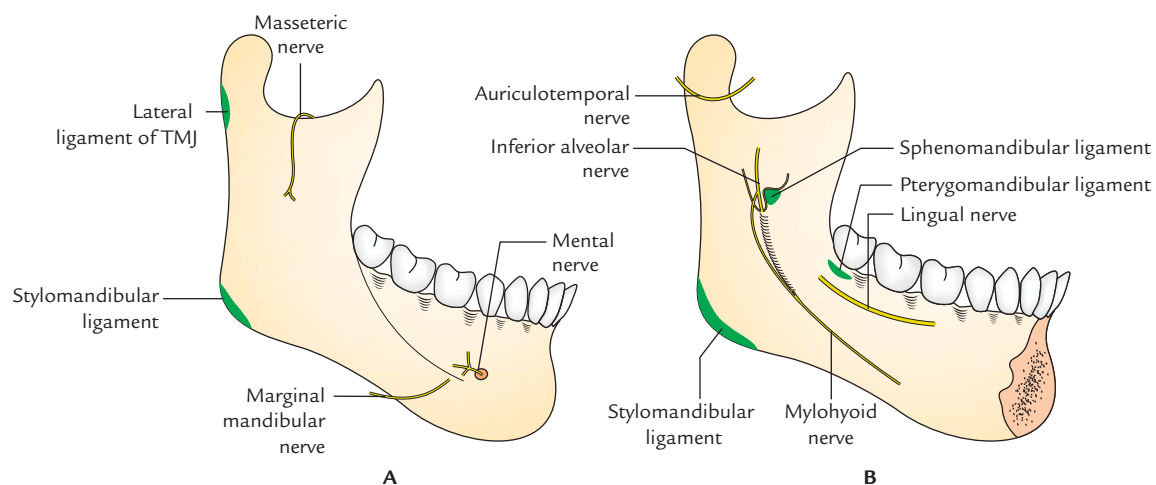


Fig. 2.14 Attachment of ligaments and nerves related to the mandible: A, lateral surface of the right half of the mandible; B, medial surface of the left half of the mandible.

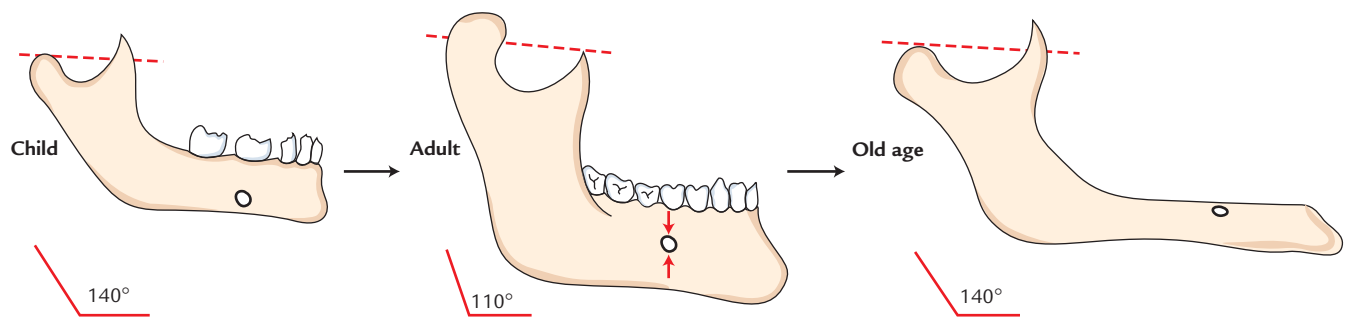


Fig. 2.15 Age-related changes in the mandible.

Changes in the Position of Mental Foramen with Age

These are as follows:

1. At birth, it is present below the sockets for deciduous molar teeth near the lower border.
2. In an adult, it gradually moves upwards and opens midway between the upper and lower borders.
3. In old age, it lies close to alveolar border due to resorption of alveolar process of the mandible due to loss of teeth.

Age Changes in the Mandible (Fig. 2.15)

The important distinguishing features of mandible in different age groups are listed in Table 2.3.

N.B.

- The two halves of mandible fuse during the first year of life.
- In infants and children, the body of mandible is mainly made up of alveolar part containing sockets for both deciduous and permanent teeth.
- In adults, alveolar and subalveolar parts of the body of the mandible are equally developed.
- In old age, teeth usually fall out and alveolar border is absorbed so that the height of the body is markedly reduced.

Clinical correlation

Fractures of the mandible: The mandible occupies a prominent and exposed position of the facial skeleton; hence it is commonly fractured following violent injuries.

Sites of the fracture: The mandible tends to fracture at one of the three sites (Fig. 2.16):

- (a) At the *neck of the mandible*, as this is the weakest part of the bone.
- (b) At the *angle of the mandible*, because here abrupt curvature concentrates the force of the blow.
- (c) In the *canine region of the body*, because elongated root of canine tooth reduces the bony substance and makes the mandible weaker at this site. The canine region is the commonest site of the fracture.

Table 2.3 Distinguishing features of mandible in different age groups

Features	In children	In adult	In old age
Mental foramen	Present close to the inferior border of the body	Present midway between the upper and lower borders of the body	Present close to the upper border
Angle of mandible	140°	110°	140°
Relationship between condylar and coronoid processes	Coronoid process above the level of condylar process	Condylar process projects above the level of coronoid process	Coronoid process projects above the level of condylar process
Mandibular canal	Runs near the lower border	Runs parallel with the mylohyoid line	Runs close to the upper border

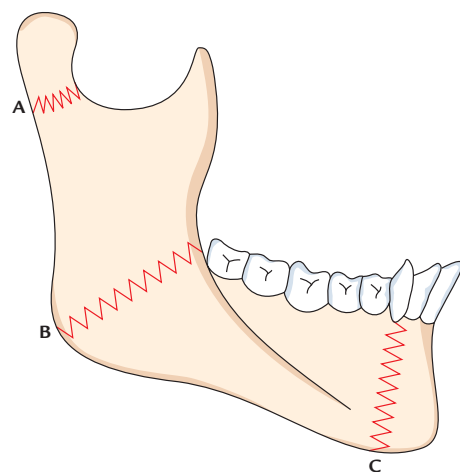


Fig. 2.16 Sites of the mandibular fracture: A, neck of the mandible; B, angle of the mandible; C, canine region.

N.B. A fracture of the mandible usually involves two fractures one in each half of the mandible, viz. fracture neck of mandible on one side and fracture of body in canine region on the other side.

Ossification of the Mandible

The mandible is formed by both intramembranous and endochondral ossification.

- Part of the mandible between mental and mandibular foramina ossifies in membrane from mesenchymal sheath of Meckel's cartilage (first arch cartilage).
- Part of the mandible medial to mental foramen ossifies directly from Meckel's cartilage (endochondral ossification).
- Coronoid and condylar processes ossify from secondary cartilages not related to Meckel's cartilage.

N.B.

- The mandible is the second bone to ossify in the body. The centre in the mesenchymal sheath of Meckel's cartilage appears during the 7th week of intrauterine life.
- The other centres forming the mandible appear during the 10th week of intrauterine life.
- At birth, mandible consists of two halves connected at the symphysis menti by cartilaginous nodules (**mental ossicles**). The bony union starts from below upwards during the 1st year of the age and completed at the end of the 2nd year.

MAXILLA

There are two maxillae, one on each side of midline (Fig. 2.17). The two together form the upper jaw. They are irregular pneumatic bones.

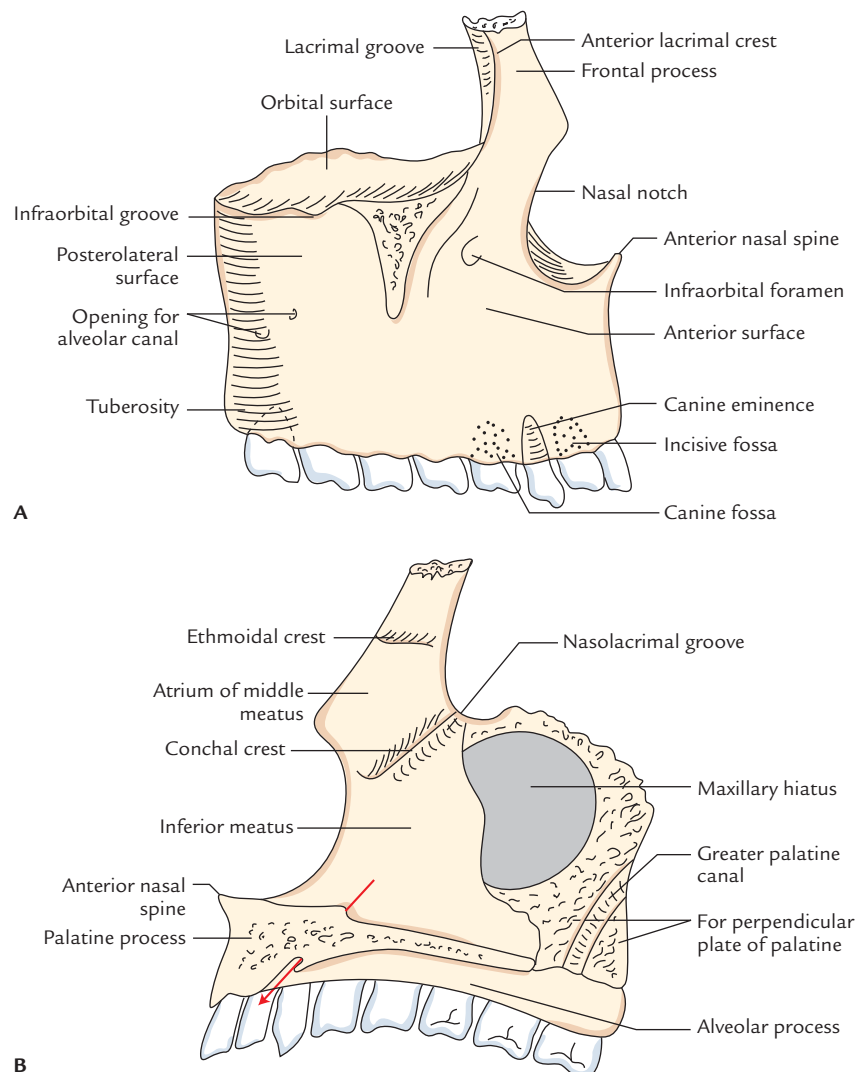


Fig. 2.17 Right maxilla: A, lateral aspect; B, medial aspect.

Parts of the Maxilla

The maxilla is the second largest bone of the face. It consists of five parts: a body and four processes.

Body of the Maxilla

It is pyramidal in shape and contains a large cavity inside called **maxillary air sinus**.

The body presents the following four surfaces:

1. Nasal (medial) surface
 2. Orbital (superior) surface
 3. Infratemporal (posterior) surface
 4. Anterior (facial) surface
1. **Nasal surface (base):** It forms the lateral wall of the nasal cavity and represents the base of the body of maxilla. It presents a large opening, the **maxillary hiatus**, which leads into maxillary sinus, a large air space within the body of the maxilla.

The maxillary hiatus is the most prominent feature of the nasal surface. In the articulated skull the maxillary hiatus is reduced in size by the four bones, viz. ethmoid, lacrimal, inferior nasal concha and palatine (for details see Chapter 17, page 262).

In front of the hiatus is the **nasolacrimal groove**. It is converted into **nasolacrimal canal** by lacrimal bone and inferior nasal concha.

An oblique ridge present in front of the nasolacrimal groove is called **conchal crest**. It articulates with the inferior nasal concha.

A vertical groove, running obliquely in the posterior part of nasal surface is converted into **greater palatine canal** by a perpendicular plate of the palatine bone.
 2. **Orbital surface:** It forms the major part of the floor of the orbital cavity. It presents infraorbital groove and canal for infraorbital nerve and vessels.
 3. **Infratemporal surface:** It forms the anterior boundary of infratemporal fossa. It is separated from the anterior surface by zygomatic process and bony ridge (jugular crest) that ascends to it from first molar socket. It presents few minute foramina for posterior superior alveolar nerve and vessels.
 4. **Anterior surface:** It forms the part of norma frontalis. About 1 cm below the **infraorbital margin**, the anterior surface presents the **infraorbital foramen** which transmits infraorbital nerve and vessels. Just above the alveolar process the anterior surface presents from medial to lateral: incisive fossa, canine eminence, and canine fossa. The canine eminence is caused by the root of canine tooth.

Processes of the Maxilla

Maxilla possesses the following four processes:

1. Frontal process: It projects upwards and articulates with the frontal bone. The thick frontal process lies in the line of buttress for dispersion of force of impact from teeth to the base of the skull.

Its lateral surface is divided into anterior and posterior parts by a vertical ridge called **anterior lacrimal crest**. The posterior part is grooved and forms a part of lacrimal fossa.

The medial surface of the frontal process is marked by a horizontal ridge called **ethmoidal crest**. It slopes downwards and forwards, and articulates with the middle nasal concha. An area below the ethmoidal crest forms the **atrium of the middle meatus**.
2. Zygomatic process: It extends laterally to articulate with the zygomatic bone.
3. Palatine process: It extends horizontally towards the medial side and forms the greater part of the hard palate.
4. Alveolar process: It extends downwards and carries the upper teeth. It is arched, being wider behind, to form the alveolar arch.

N.B. The two maxillae are united in the anteromedian plane at the intermaxillary suture. The portion of the maxillae that carry the incisor teeth is sometimes termed *premaxilla*.

Clinical correlation

Fractures of maxilla:

- (a) Unilateral fracture involves the alveolar process of the maxilla.
- (b) Bilateral fractures are classified into following three types (Fig. 2.18):
 - *Le Fort I:* In this a horizontal fracture runs along the floor of the nose above and parallel to the palates and below the zygomatic bone.
 - *Le Fort II:* In this, a pyramidal-shaped fracture line passes through the root of the nose, floor of orbits, and then runs medial to and below the zygomatic bones towards the alveolar margin.
 - *Le Fort III (craniofacial dysfunction):* In this, the fracture line runs through the root of the nose, superior orbital fissures and lateral walls of the orbits above the zygomatic bones. There is complete separation of cranial skeleton from facial skeleton.

TEMPORAL BONE

The temporal bone is an irregular pneumatic bone, situated on each side at the base and side of the skull (Fig. 2.19).

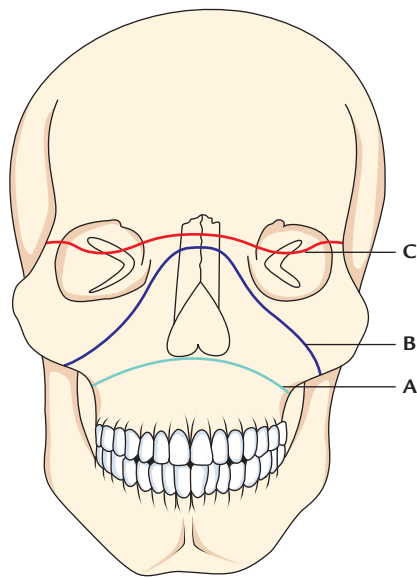


Fig. 2.18 Bilateral fractures of the maxilla: A, Le Fort I; B, Le Fort II; C, Le Fort III.

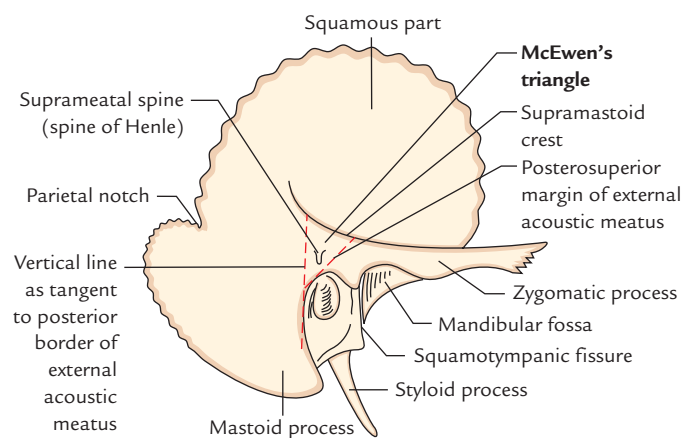


Fig. 2.19 Right temporal bone: external aspect.

Parts

It consists of the following four morphological parts:

1. Squamous part.
2. Petromastoid part.
3. Tympanic part.
4. Styloid process.

Squamous Part

It is thin, transparent, shell-like plate of bone which projects upwards to form the side of the skull. It presents external and internal surfaces; and superior and anteroinferior border and zygomatic process.

1. **External surface** forms the floor of temporal fossa and is grooved in its centre by the middle temporal artery.

The **zygomatic process** projects laterally from the lower and anterior parts of the temporal surface. It joins

the temporal process of the zygomatic bone to form the **zygomatic arch**.

A deep cavity behind the articular eminence is called **mandibular fossa**. The mandibular fossa and articular tubercle are fundamental portions of the squamous part of the temporal bone.

2. **Internal surface** lies in contact with the temporal lobe of the brain. It is grooved by the anterior and posterior branches of the middle meningeal artery.

Petromastoid Part

For the sake of convenience of description, the petromastoid part is generally divided into two parts: mastoid part and petrous part.

1. **Petrous part:** It is the hardest (rock-like) part of the temporal bone and contains inside it: internal ear, middle ear, and mastoid antrum, which it safely protects. It also contains carotid canal for internal carotid artery.

The petrous part has a shape of a three dimensional pyramid. It has a base, an apex, three surfaces, and three borders.

- The **base** is fused with the squamous part.
- The **apex** forms the posterolateral wall of the foramen lacerum.
- **Anterior surface** forms the posterior part of the middle cranial fossa. It presents five features (see Chapter 21).
- **Posterior surface** forms the anterior wall of the posterior cranial fossa. It presents three features (see Chapter 21).
- **Inferior surface** is seen at the base of the skull. It lies between the greater wing of sphenoid and basilar part of the occipital bone. It presents the lower opening of the carotid canal, jugular fossa, tympanic canaliculus, and a triangular depression in front of the jugular fossa.

The triangular depression in front of the jugular fossa lodges inferior ganglion of glossopharyngeal nerve. The apex of fossa presents an opening, which leads into a bony canal, the **cochlear canaliculus** which is traversed by aqueduct of cochlea/perilymphatic duct.

- **Superior border:** it is a long sharp crest which intervenes between middle and posterior cranial fossae. It is grooved by superior petrosal sinus. Its medial end is crossed by abducent nerve deep to petrosphenoid ligament (**ligament of Gruber**).
- **Anterior border:** its medial part articulates with greater wing of sphenoid and forms **sulcus tubae** on the undersurface of the base of the skull. Its lateral part joins squamous part at petrosquamosal suture.
- **Posterior border:** its medial part articulates with the basilar part of the occipital bone and forms a groove which lodges the **inferior petrosal sinus**. Its lateral

part forms the superolateral boundary of the jugular foramen.

2. **Mastoid part:** It lies below and behind the squamous part and contains mastoid antrum, which communicates with the middle ear cavity in the petrous part of the temporal bone. It ends below as mastoid process. It encloses the mastoid air cells. On the medial side of the mastoid process there is a notch called **digastric notch** for attachment to the posterior belly of digastric muscle.

N.B. *Mastoid air cells:* The mastoid process consists of a cortex of compact bone with a *honeycomb* of air cells underneath it. The air cells are small intercommunicating spaces which are continuous with the mastoid antrum and middle ear.

Depending upon the air cell development (pneumatization), the following three types of mastoid processes have been described:

- *Pneumatic or cellular mastoid process:* In this, air cells are well-developed and the intervening septa are thin.
- *Diploic or mixed process:* The process consists of narrow spaces and few air cells.
- *Sclerotic or acellular process:* There are no cells or narrow spaces in the mastoid process. The antrum is small and sigmoid sinus is interposed.

Clinical correlation

Middle ear infections often spread into mastoid antrum and mastoid air cells to cause *mastoiditis* and *mastoid abscess*.

Tympanic Part

It is a thin, triangular curved plate of bone which forms the floor and anterior wall of the external auditory meatus. The anterior surface of the tympanic part forms the non-articular part of the mandibular fossa and is related to the part of the parotid gland.

Styloid Process

It is a slender bony projection of about 1 inch length. It extends downward and forward from the under surface of the tympanic plate. It is crossed externally by the facial nerve.

External acoustic meatus (bony part) opens on the surface behind the mandibular fossa below the posterior part of the posterior root of zygoma and forms about two-third of the total length of the external auditory meatus.

The **suprameatal triangle (McEwen's triangle)** is a small depression posterosuperior to the external acoustic meatus (for details see Fig. 2.19 on page 31).

N.B. At birth, the tympanic cavity, tympanic membrane, mastoid antrum, ear ossicles, and internal ear—all are of the adult size.

PARIETAL BONE

The parietal bone (Fig. 2.20) is a curved plate of bone which forms the major portion of the vault of the skull. It is quadrilateral in shape.

Parts

The parietal bone presents:

1. **Two surfaces:** external and internal.
2. **Four borders:** superior (sagittal), inferior, anterior, and posterior.
3. **Four angles:** frontal, sphenoidal, occipital, and mastoid.

Surfaces

The two surfaces of the parietal bone are as follows:

1. **External surface:** It is smooth and convex, and presents near its centre an elevation called parietal eminence or parietal tuberosity or parietal tuber—the most prominent feature of this surface. Below the parietal tuberosity there are two curved lines called **superior and inferior temporal lines**. The parietal foramen is situated close to the posterior part of the superior border.
2. **Internal surface:** It is concave and overlies the parietal lobe of the cerebral hemisphere.

It presents the following features:

- (a) *Sagittal sulcus* (only half) along the superior border, which lodges superior sagittal sinus.
- (b) *Granular pits* by the side of sagittal sulcus, which lodge the arachnoid granulations.
- (c) *Deep groove immediately behind the anterior border*, which lodges the anterior branch of the middle meningeal artery.
- (d) *An impression for posterior division of middle meningeal artery*, which runs upwards from the middle of the lower border.
- (e) *Transverse sulcus* across the posteroinferior angle, which lodges the sigmoid sinus.

Borders

The four borders of the parietal bone are as follows:

1. **Superior (sagittal) border:** articulates with similar border of opposite parietal bone to form sagittal suture.
2. **Inferior (squamosal) border:** articulates with three bones. From anterior to posterior, these are: (a) greater wing of sphenoid bone, (b) squamous part of temporal bone, and (c) mastoid portion of the temporal bone.
3. **Anterior (frontal) border:** articulates with the frontal bone to form the coronal suture.
4. **Posterior (occipital) border:** articulates with the squamous part of the occipital bone to form the lambdoid suture.

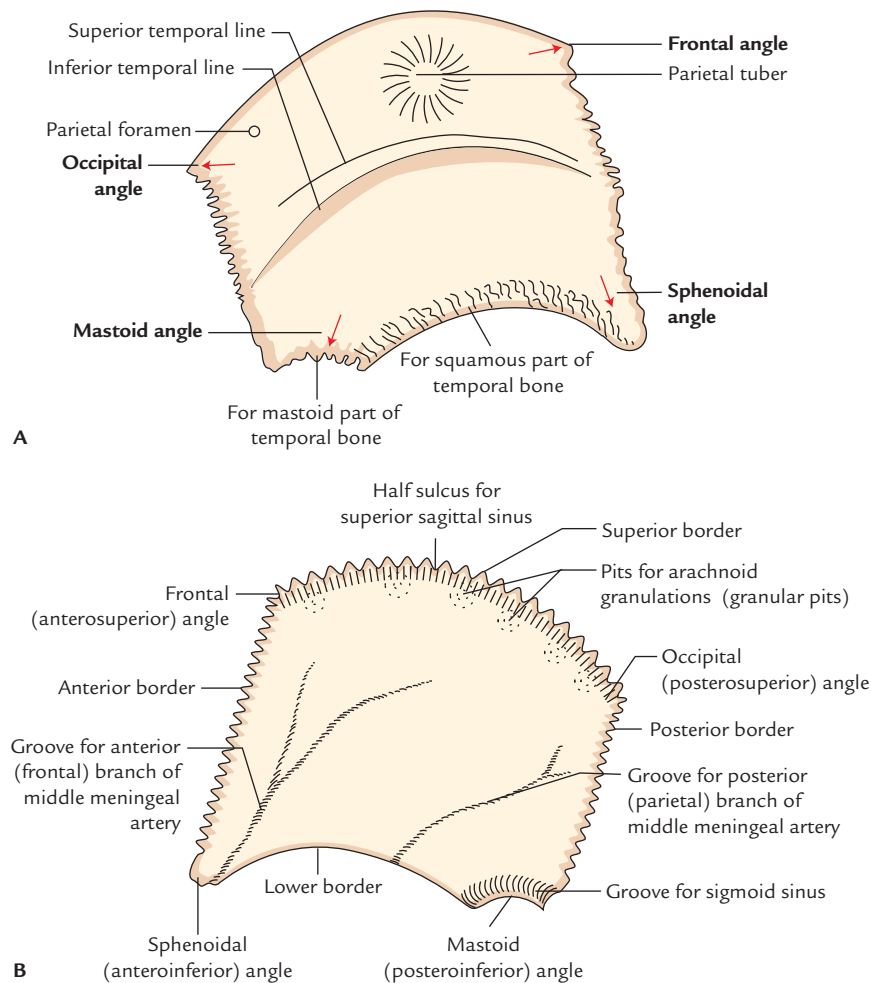


Fig. 2.20 Right parietal bone: **A**, external surface; **B**, internal surface.

Angles

The four angles of the parietal bone are as follows:

1. **Anteroinferior (sphenoidal) angle**—lies at pterion.
2. **Anterosuperior (frontal) angle**—lies at the bregma.
3. **Posteroinferior (mastoid) angle**—lies at the asterion.
4. **Posterosuperior (occipital) angle**—lies at lambda.

N.B. The anteroinferior (sphenoidal) angle projects downwards and forwards to a considerable extent.

Clinical correlation

- Occasionally, the parietal bone is divided into two parts: upper and lower by an anomalous anteroposterior suture. The clinician may confuse this condition with a fracture. But it can be ruled out easily as the anomalous parietal suture is bilateral.
- The regenerating capacity of parietal bone is very poor due to lack of cambium layer in the periosteum.

ZYGOMATIC BONE (CHEEK BONE)

The zygomatic bone is also called **malar bone** because it forms the prominence of the cheek which is called *mala* in Latin.

Parts

The zygomatic bone consists of the following three parts:

1. A body.
2. Two processes: frontal and temporal.

Body

It presents three surfaces, *viz.* orbital surface, lateral surface, and temporal surface.

1. **Orbital surface** forms a part of the lateral wall and floor of the orbit. It has a foramen, the zygomatico-orbital foramen, which transmits a zygomatic nerve.
2. **Lateral surface** is subcutaneous and presents a zygomaticofacial foramen through which zygomaticofacial nerve comes out.

3. **Temporal surface** forms the part of anterior wall of the temporal fossa and presents a zygomaticotemporal foramen, which transmits the zygomaticotemporal nerve.

Processes

These are as follows:

1. **Frontal process:** It is a thick upward projection. It articulates with the zygomatic process of the frontal bone. Its orbital surface presents a small tubercle near the orbital margin and 1 cm below the frontozygomatic suture called **Whitnall's tubercle**.
2. **Temporal process:** It extends backwards and joins the zygomatic process of the temporal bone to form the zygomatic arch.

Clinical correlation

The strong frontal process acts as a *line of buttress* for dispersion of force of impact to the frontal bone during mastication by the molar and premolar teeth.

N.B. The zygomatic bone ossifies in membrane. Sometimes a fissure divides the bone into upper and lower parts. This is a usual feature in the Mongolian race—making their malar prominences flat, hence it is known as **OS Japonicum**.

FRONTAL BONE

The frontal (L. *frontal* = forehead) bone (Fig. 2.21) is located in the region of the forehead. It is shaped like a shell.

Parts

It consists of the following six parts:

1. Squamous part (main part).
2. Nasal part.
3. Two orbital plates.
4. Two zygomatic processes.

Squamous Part

On each side the lower part of the squamous part joins the orbital plate. The junction of these two forms the supraorbital margin. The squamous part presents external and inner surfaces.

The external surface above each supraorbital margin presents a curved elevation called **superciliary arch**. A rounded prominence between the medial ends of two superciliary arches is called **glabella**. Above the superciliary arch the external surface displays an elevation called **frontal tuber** or **eminence** or **tuberosity**.

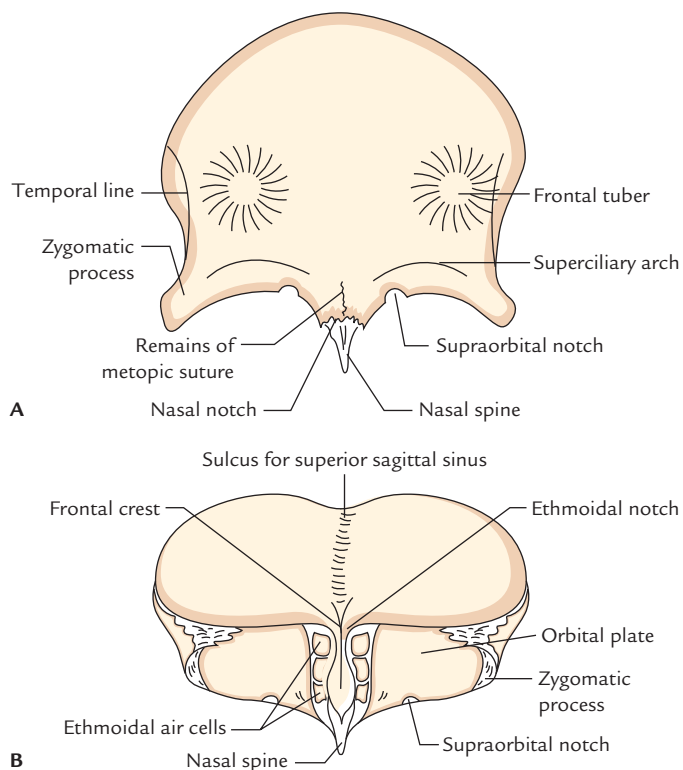


Fig. 2.21 Frontal bone: A, external aspect; B, inferior aspect.

The internal surface is deeply concave and presents a median bony ridge called **frontal crest**, which is continuous above with the sagittal sulcus.

Nasal Part

It is the portion of bone which projects downwards between the right and left supraorbital margins. It presents a **nasal notch**, which articulates inferiorly with the two nasal bones one on each side of median plane and laterally on each side with frontal process of maxilla and the lacrimal bone.

Orbital Plates

Each orbital is a triangular curved plate of bone extending horizontally backwards from the supraorbital margin. It forms most of the roof of the orbit. The two orbital plates are separated from each other by U-shaped **ethmoidal notch** for accommodating cribriform plate of the ethmoid bone.

Zygomatic Processes

One on each side, it extends downwards and laterally from the lateral end of the supraorbital margin. The zygomatic process joins the frontal process of the zygomatic bone. From the posterior margin of each zygomatic process the temporal line curves upwards and backwards and splits into superior and inferior temporal lines.

Clinical correlation

- The frontal bone ossifies in membrane. The primary centres appear one for each half of the frontal bone in the region of frontal tuberosity. At birth, frontal bone is made up of two halves, separated by a median frontal suture. The union between the two halves begins at second year and usually completes by the end of the eighth year. The remains of this suture in the adult are often seen in the region of glabella. It is termed **metopic suture**.
- The fracture of orbital plate of frontal bone leads to hemorrhage into the orbit. The hemorrhage acquires a triangular shape underneath the conjunctiva with apex towards the cornea and base towards the orbital margin.
- The frontal squama is prone to fracture. In neonates and infants, it is a depressed fracture (a dimple in the bone), whereas in adults it is a fissured fracture, i.e., the depressed area always shows an irregular line of fracture at its periphery.

OCCIPITAL BONE

The occipital bone (Fig. 2.22) occupies the posterior part of the skull. It is characterized by the presence of the large foramen magnum.

Parts

It consists of the following four parts:

1. Squamous part.
2. Two condylar parts.
3. Basilar part.

Squamous Part

It is an expanded plate above and behind the foramen magnum. It presents two surfaces and three angles.

1. **External surface:** It is convex and shows the following features:

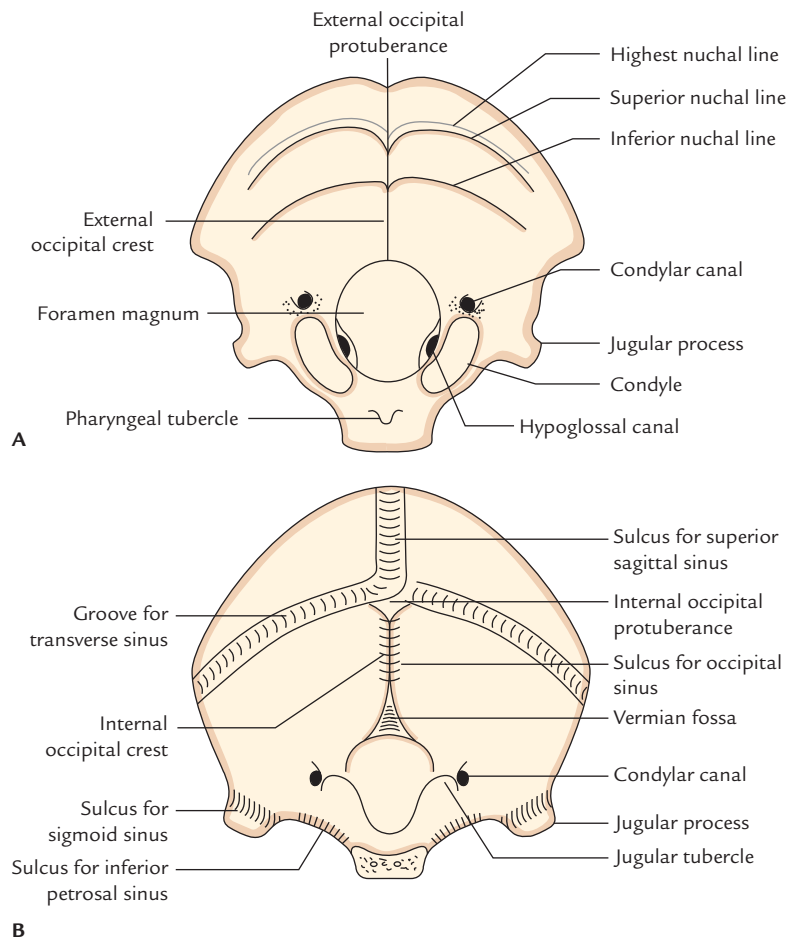


Fig. 2.22 Occipital bone: A, external surface; B, internal surface.

- (a) *External occipital protuberance*, a median elevation at the point of its maximum convexity. The most prominent point of this protuberance is called **inion**.
 - (b) *External occipital crest*, a bony crest running downwards from external occipital protuberance to the foramen magnum.
 - (c) *Two superior nuchal lines*, one on each side, curve laterally from external occipital protuberance.
 - (d) *Two inferior nuchal lines*, one on each side curve laterally from the middle of the external occipital crest.
2. **Internal surface:** It is concave and shows the following features:
- (a) *Internal occipital protuberance*, a bony elevation close to the centre.
 - (b) *Internal occipital crest*, a vertical bony crest which runs downwards from the internal occipital protuberance towards the foramen magnum. Near the foramen magnum it splits to form a triangular depression called **vermian fossa**.
 - (c) *Cruciate arrangement of four grooves, radiating from the internal occipital protuberance:*
 - Sagittal sulcus/groove, runs upwards towards the superior angle it is occupied by superior sagittal sinus.
 - Transverse sulcus/groove, one on each radiate towards the lateral angle; it is occupied by the transverse sinus.
 - A groove descends downwards towards the foramen magnum. It is occupied by the occipital sinus.

The small parts of grooves for sigmoid and inferior petrosal sinuses are also seen on the internal surface.

Clinical correlation

The squamous part of temporal bone below the highest nuchal line is ossified in cartilage from two centres—one on each side in the 7th prenatal week and soon joins with each other. The squamous part above the highest nuchal line is ossified in membrane from two centres—one on each side in the 8th prenatal week and soon fuses with each other.

The two portions, upper and lower, of squamous part usually unite with each other in the 3rd month after birth when the baby starts holding his neck.

Sometimes the part above the highest nuchal line remains separate and persists as **interparietal bone**.

Condylar Parts

It is situated one on each side of the foramen magnum. The medial part bears occipital condyles. The lateral part, a quadrilateral plate projecting laterally from the posterior half of the occipital condyle is called **jugular process**.

The outer opening of **hypoglossal canal** transmitting hypoglossal nerve lies lateral to the anterior part of the occipital condyle.

The depression just behind the occipital condyle is called **condylar fossa**. Sometimes it presents a foramen in its floor called **posterior condylar canal**.

The anterior margin of jugular process presents a concave **jugular notch** which with similar notch on the petrous temporal bone forms the **jugular foramen**.

The superior surface of the condylar part presents the **jugular tubercle**.

Basilar Part (Basiocciput)

It is a wide bar of bone which lies in front of the foramen magnum and articulates in front with the body of sphenoid to form the basisphenoid joint (a primary cartilaginous joint).

The upper surface of the basisphenoid presents a shallow gutter, which slopes downwards and backwards from dorsum sellae to the foramen magnum. It is called **clivus**. The inferior surface of the basilar part presents a pharyngeal tubercle in median plane, about 1 cm in front of the foramen magnum.

Clinical correlation

Medicolegal importance of basisphenoid joint: The *basisphenoid joint is of medicolegal importance in assessing the age of the individual*. It is the primary cartilaginous joint with plate of hyaline cartilage between the basilar part of the occipital bone and posterior part of the body of sphenoid bone. This cartilaginous plate is completely replaced by the bone (synostosis) by the 25th year of the age.

The basisphenoid joint is responsible for growth of the skull in length.

SPHENOID BONE

The sphenoid (Fig. 2.23) is an unpaired bone situated at the base of the skull. It resembles the shape of a butterfly or bat with outstretched wings.

Parts

It consists of the following seven parts:

- A body.
- Two lesser wings.
- Two greater wings.
- Two pterygoid processes.

N.B. Two pterygoid processes represent the legs of the bat.

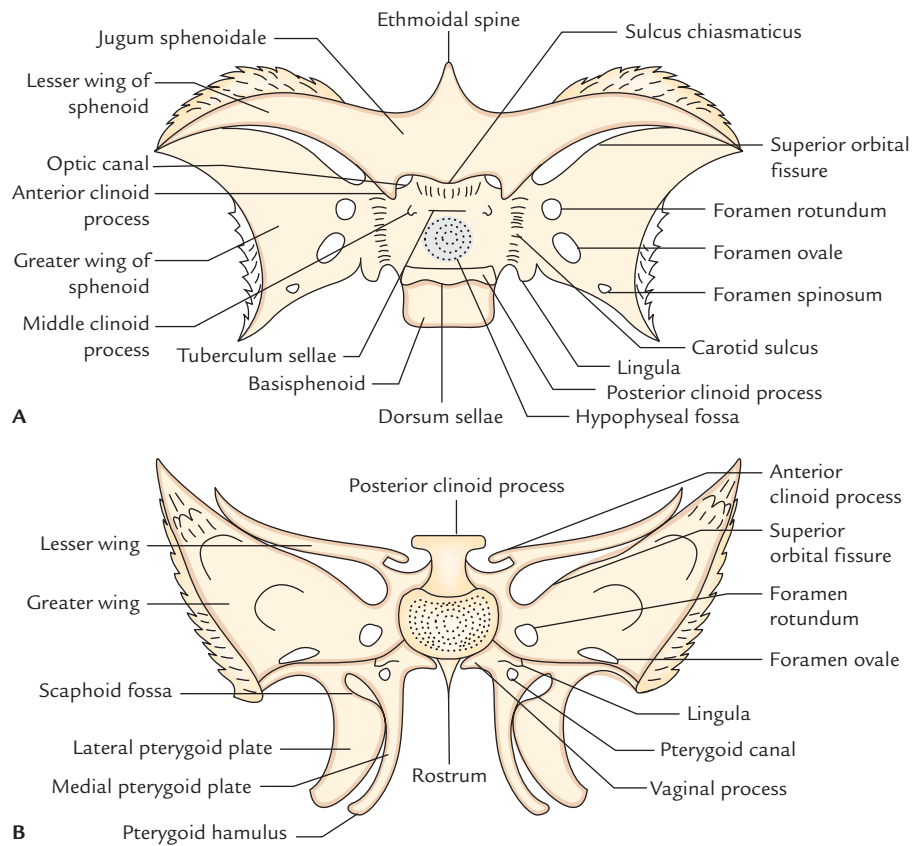


Fig. 2.23 Sphenoid bone: A, superior aspect; B, posterior aspect.

Body

It is cuboidal in shape and contains a pair of sphenoidal air sinuses. The body presents six surfaces: superior, inferior, anterior, posterior and right and left lateral surfaces.

- The **superior surface** presents the following features from before backwards:
 - Ethmoidal spine*, a triangular projection between the two lesser wings. It articulates with the posterior margin of the cribriform plate.
 - Jugum sphenoidale*, a flattened plate of bone behind the ethmoidal spine.
 - Sulcus chiasmaticus*, a shallow transverse groove, which leads on each side into optic canal.
 - Tuberculum sellae*, a horizontal elevation forming posterior limit of sulcus chiasmaticus. On each side it presents small conical projections, the **middle clinoid process**.
 - Hypophyseal fossa*, a deep depression which lodges pituitary gland.
 - Dorsum sellae*, a square plate of bone which projects upwards and presents a conical projection on each side called **posterior clinoid process**.

N.B. *Sella turcica* is collective name given to tuberculum sellae, hypophyseal fossa, and dorsum sellae. It resembles a Turkish saddle.

- Inferior surface** presents the following three features:
 - Sphenoidal rostrum*, a median ridge projecting downward. It occupies the groove between the alae of Vomer.
 - Sphenoidal concha*, a triangular plate of bone on each side of rostrum which articulates with the alae of Vomer.
 - Vaginal process*, a triangular bony shelf projecting downwards and medially from the base of each medial pterygoid plate. It helps form vomerovaginal and palatovaginal canals.
- Anterior surface** presents the following features:
 - Sphenoidal crest*, a vertical median ridge which articulates with the posterior border of the perpendicular plate of ethmoid to form part of nasal septum. On each side of the sphenoid crest lies the opening of sphenoidal air sinuses.
 - Upper vertical parts of sphenoidal conchae*, it lie on each side of the crest.

4. **Posterior surface** is quadrilateral in shape and articulates by a plate of hyaline cartilage with the basiocciput.
5. Each **lateral surface** of the body joins with the greater wing of sphenoid (projecting laterally) and the pterygoid process (extending downwards). The lateral surface presents a groove called **carotid sulcus** produced by the internal carotid artery.

Lesser Wings

Each lesser wing arises from the anterior part of the body of sphenoid by two roots. Between these two roots lies the optic canal. The projecting medial ends of the lesser wings are called **anterior clinoid processes**.

Greater Wings

Each greater wing spans out laterally from the side of the body forming the floor of the middle cranial fossa.

The greater wing has the following three surfaces:

1. **Upper surface:** It lies in the middle cranial fossa (for details see middle cranial fossa on page 318).
2. **Lateral (infratemporal) surface:** It is divided into temporal and infratemporal surfaces by the **infratemporal crest**.
3. **Anterior (orbital) surface:** It lies at the lateral wall of the orbit and separates the superior orbital fissure from the inferior orbital fissure.

Pterygoid Processes

They have been described on page 19.

Clinical correlation

- The **craniopharyngeal canal** is occasionally present in the floor of the pituitary fossa. It represents the remnant of *Rathke's pouch* which forms the anterior lobe of the pituitary gland.
- The observation of sella turcica in radiographs of skull is of great clinical significance because pathological changes in it reflect intracranial space-occupying lesions such as **pituitary tumor**.

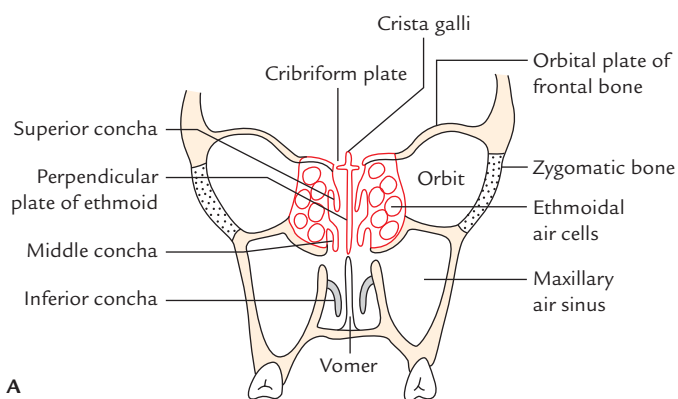
ETHMOID BONE

The ethmoid is an unpaired fragile bone (Fig. 2.24) located between two orbital cavities. The ethmoid is so named because it possesses a perforated (sieve-like) plate called cribriform plate (Gr. *ethmoid* = sieve-like).

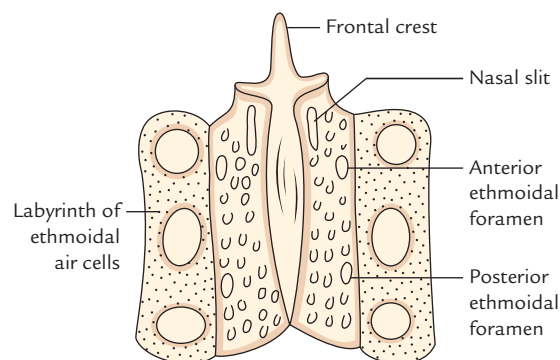
Parts

The ethmoid bone consists of the following parts:

- Cribriform plate.
- Crista galli.
- Perpendicular plate.
- Two labyrinths.



A



B

Fig. 2.24 Ethmoid bone: **A**, location of ethmoid in relation to nasal cavity, orbits, and maxillary sinuses; **B**, superior view of ethmoid bone.

Cribriform Plate

The cribriform plate fills the ethmoidal notch between the two orbital plates of the frontal bone and separates the nasal cavities from the anterior cranial fossa. It has a number of small pores in it which transmit the filaments of olfactory nerve from the olfactory epithelium of the nasal cavity to the olfactory bulb of the brain.

Crista Galli

It is a triangular median crest on the upper surface of the cribriform plate. It resembles the crest on the head of *Gallus domesticus* (cock's comb), the red growth of flesh on the top of the head of a cock, and gives attachment to the anterior end of the falx cerebri.

Perpendicular Plate

It is a quadrilateral plate which projects downwards from the inferior surface of cribriform plate. It forms the upper part of the nasal septum.

Labyrinths

The labyrinths are the cuboidal bony boxes filled with air cells. The air cells, according to their location, are divided into three groups: anterior, middle, and posterior. The lateral surfaces of the labyrinth forms the medial wall of the orbit

and medial surface forms the lateral wall of the nasal cavity. The two shelf-like projections from the medial surface are called *superior* and *middle conchae* (remember: inferior concha is an independent bone).

Clinical correlation

In case of head injury, the blood-stained discharge of CSF from nose (CSF rhinorrhea) indicates fracture of cribriform plate of the ethmoid in the anterior cranial fossa. It may result into anosmia (loss of smell) due to damage of olfactory nerves.

INFERIOR NASAL CONCHA (TURBINATE BONE)

There are two inferior nasal conchae. Each inferior nasal concha projects downwards from the lateral wall of the nasal cavity. It is a curved bony plate and presents the following features:

- Medial and lateral surfaces.
- Superior and inferior borders.
- Anterior and posterior ends.

Medial and Lateral Surfaces

The **medial surface** is convex. The **lateral surface** is deeply concave and forms the medial wall of the inferior meatus of the nose.

Superior and Inferior Borders

The **superior border** is thin and irregular. Its anterior part articulates with conchal crest of maxilla and posterior part with conchal crest of the palatine bone. The middle presents three processes from before backwards: lacrimal, maxillary, and ethmoidal. The **inferior border** is thick and gently curved.

Anterior and Posterior Ends

Both **anterior** and **posterior ends** are pointed; the latter is more marrow.

Clinical correlation

The lacrimal process of inferior nasal concha articulates with the margins of nasolacrimal groove of maxilla to form nasolacrimal canal. The surgical fracture of inferior nasal concha is sometimes needed to manage congenital lacrimal defects.

PALATINE BONE

There are two palatine bones (Fig. 2.25). Each palatine bone is lodged between the maxilla in front and the pterygoid process of sphenoid bone behind. The palatine bone is so

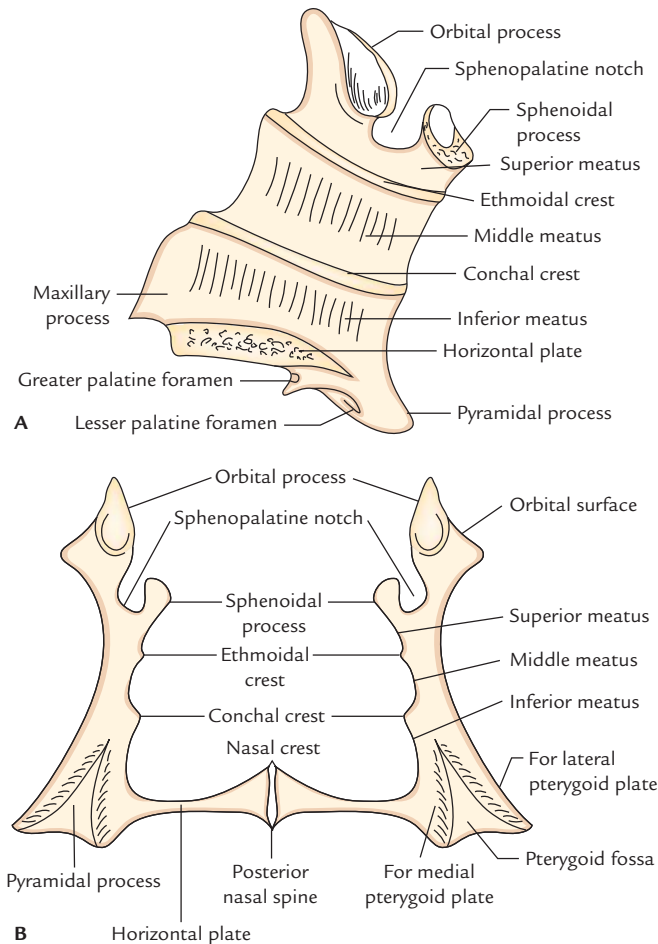


Fig. 2.25 Palatine bone: A, medial aspect; B, posterior aspect of two palatine bones together.

named because the two palatine bones form the posterior one-third of the hard palate.

Parts

The palatine bone is L-shaped and consists of the following two plates:

1. Horizontal plate.
2. Perpendicular plate.

It also possesses the following three processes:

1. Orbital process.
2. Sphenoidal process.
3. Pyramidal process.

Horizontal Plate

It projects medially and unites with its counterpart of opposite side to form the posterior one-fourth of the hard palate.

Perpendicular Plate

It is a vertical plate which is fixed with the posterior part of the medial surface of the maxilla. At its upper border the

perpendicular plate presents two processes: (a) sphenoidal process and (b) orbital process. Between the two processes it encloses the **sphenopalatine notch**, which is converted into sphenopalatine foramen by inferior surface of the body of sphenoid. The lateral surface of the perpendicular plate presents a vertical groove, the *greater palatine groove*.

Orbital Process

It projects upwards and laterally from the anterior part of the upper border of the perpendicular plate, in front of sphenopalatine notch. It presents three articular and two non-articular surfaces.

Sphenoid Process

It projects upwards and medially from the posterior part of the upper border of the perpendicular plate. It presents three surfaces and three borders.

Pyramidal Process

It projects posterolaterally from the junction between the perpendicular and horizontal plates. The pyramidal process is pierced by the lesser palatine canals. The greater palatine canals run between the maxilla and the perpendicular plate of the palatine.

Clinical correlation

The Le Fort fractures of mid-facial skeleton always involve the perpendicular plates of palatine bones. The Le Fort I involves the lower one-third of the perpendicular plates, whereas Le Fort II and Le Fort III involve the upper parts of the perpendicular plates of palatine.

VOMER

The vomer (Fig. 2.26) is a thin quadrilateral plate of bone, which forms the posteroinferior part of the nasal septum.

Parts

The vomer presents the following features:

- Four borders.
- Two lateral surfaces.

Borders

The four borders are as follows:

1. **Superior border** is thick and grooved between the two diverging alae. The groove fits over the sphenoidal rostrum.

The margin of ala intervenes between the body of sphenoid and vaginal process of medial pterygoid plate. The *vomerovaginal canal* is formed between the ala of vomer and vaginal process of medial pterygoid plate (Fig. 2.26).

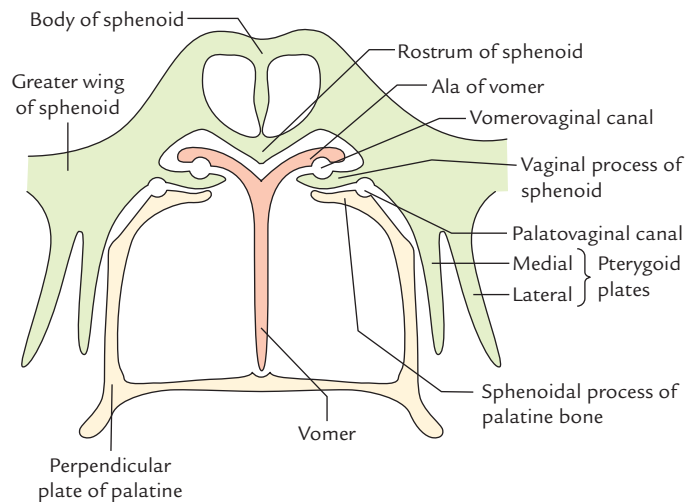


Fig. 2.26 Vomer in relation to sphenoid and palatine bones. Note the formation of vomerovaginal and palatovaginal canals.

2. **Lower border** articulates with the nasal crest formed by the maxillae and palatine bones of the two sides.
3. **Posterior border** is free and separates the two posterior nasal apertures.
4. **Anterior border** is longest and slopes downwards and forwards. In its upper part it articulates with the perpendicular plate of ethmoid and in its lower part with the septal cartilage.

Lateral Surfaces

The lateral surface on each side is covered by a mucous membrane and is marked by an anteroinferior groove for nasopalatine nerve and vessels.

Clinical correlation

- The vomer is involved in all three types of Le Fort fractures of midfacial skeleton.
- The vomer is paper thin. A transverse fracture of vomer due to direct blow on the nose leads to deviated nasal septum (DNS).

HYOID BONE

It is not actually a part of the skull. This U-shaped bone is located in the front of the neck between the mandible and the larynx at the level of the 3rd cervical vertebra. It is unique in the sense that, it does not articulate with any other bone in the body, but it is suspended from styloid processes of temporal bones by stylohyoid ligaments (Fig. 2.27).

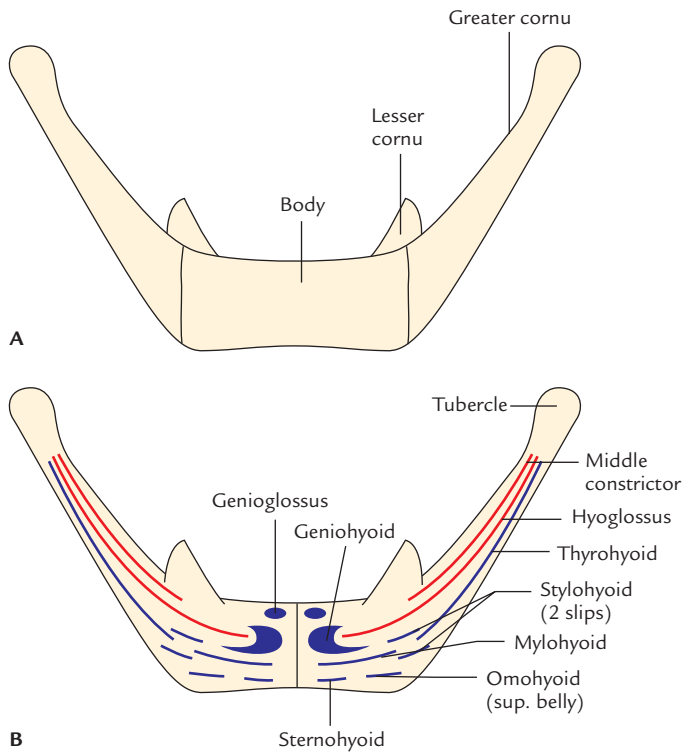


Fig. 2.27 Hyoid bone (anterior view): A, parts of hyoid bone; B, muscle attachments.

Parts (Fig. 2.27A)

The hyoid bone consists of the following five parts:

- A body.
- A pair of greater cornu (or horns).
- A pair of lesser cornu (or horns).

Body

It is elongated and quadrilateral in form. The body presents two surfaces (anterior and posterior) and two lateral extremities:

1. The **anterior surface** is convex and faces forwards and upwards. Its upper part is crossed by a transverse line or ridge and in many cases a vertical median ridge divides the body into two lateral halves.
2. The **posterior surface** is smooth and concave. It faces backwards and downwards. The posterior surface of hyoid bone is separated from the epiglottis by the thyrohyoid membrane; a bursa intervenes between the bone and the membrane.
3. The **lateral extremities** of the body on each side are continuous with the greater cornu. In early life, the lateral extremities are connected with the greater cornu by a cartilage, but after middle life, they become united by a bone.

Greater Cornu

Each greater cornu projects backwards and upwards from the side of the body of the bone. They diminish in size from before backwards. Each cornu ends posteriorly in a tubercle.

When the neck is relaxed, the two greater cornua can be gripped in vivo between the index finger and the thumb, and then the hyoid bone can be moved from side to side.

Lesser Cornu

Each lesser cornu is a small conical bony projection that is attached at the junction of the body and greater cornu. The stylohyoid ligament is attached to the tip of the lesser cornu and is sometimes ossified.

N.B. The hyoid bone provides attachment to a number of muscles, otherwise it is of little functional significance (Fig. 2.27B).

Clinical correlation

- In suspected cases of death, the **examination of hyoid bone is of great medicolegal significance**, because fracture of hyoid bone in such cases suggests death by throttling or strangulation.
- The tip of greater cornu can be palpated in the relaxed neck near the anterior border of sternocleidomastoid muscle, midway between the laryngeal prominence and mastoid process. The lingual artery forms a loop above the greater cornua, hence the latter forms an important surgical landmark for locating the lingual artery for ligation in radical surgery of the neck.

CERVICAL VERTEBRAE

There are seven cervical vertebrae, numbered 1 to 7 from above downwards. They are small in size as compared to thoracic and lumbar vertebrae as they have to carry less weight. They are identified by the presence of foramen in their transverse processes called **foramen transversarium**—the *cardinal feature of cervical vertebrae*. The 3rd to 6th are **typical** because they have common features. The 1st, 2nd, and 7th are **atypical** because they possess special features for individual identification.

FEATURES OF TYPICAL CERVICAL VERTEBRAE (Fig. 2.28)

The features of typical cervical vertebrae are as follows:

- The **body**:
 - (a) It is small.
 - (b) It is broader from side to side than from before backwards.

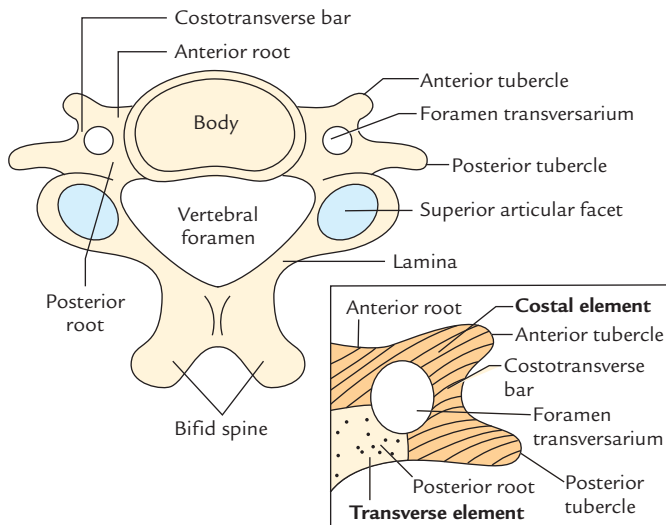


Fig. 2.28 Typical cervical vertebra (superior aspect); inset on the right side shows the costal and transverse elements of the transverse process.

- (c) Its superior surface is concave transversely with upward projecting lips on each side.
- (d) The inferior surface on the anterior margin of the body projects downwards in front of the intervertebral disc while the lateral margins are beveled laterally to form the synovial joints with projecting lips of the vertebra below. These are called **uncovertebral joints (joints of Luschka)**.
- The **vertebral foramen** is triangular and larger than the body.
 - The **superior and inferior articular facets** are flat:
 - (a) Superior facets are directed backwards and upwards.
 - (b) Inferior facets are directed forwards and downwards.
 - The **transverse processes** are small and pierced by foramen transversarium. Each process has anterior and posterior roots, which end in tubercles called anterior and posterior tubercles. They are joined together by costotransverse bar. The costal element consists of anterior root, anterior tubercle costotransverse bar, and posterior tubercle. The posterior root represents the transverse element of the developing vertebra.
 - The **spine** is short and bifid.

FEATURES OF ATYPICAL CERVICAL VERTEBRAE (Fig. 2.29)

First Cervical Vertebra (Fig. 2.29A)

The 1st cervical vertebra is called **atlas** because it supports the globe of the head on its shoulders. According to Greek mythology, the Atlas is the God who supported the globe of earth on his shoulders.

It has following features:

1. It is ring shaped and has no body and no spine.
2. It consists of:
 - (a) right and left lateral masses connected by a short anterior arch and a long curved posterior arch, and
 - (b) right and left transverse processes.

The **anterior arch** is marked in the median plane by the anterior tubercle on its anterior aspect, and an oval facet on its posterior aspect for articulation with the dens of the 2nd cervical vertebra to form atlantoaxial joint.

The **posterior arch** forms two-fifth of the ring and its posterior aspect is marked by a median posterior tubercle. The upper surface of the posterior arch behind the lateral mass is marked by a groove which lodges the vertebral artery and the 1st cervical nerve.

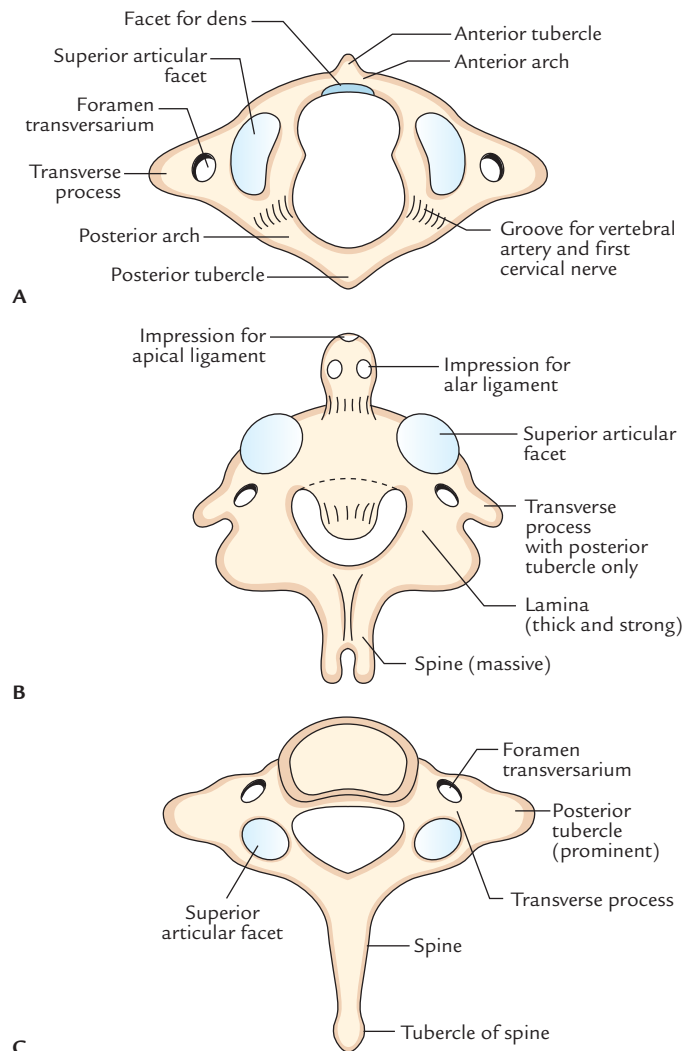


Fig. 2.29 Atypical cervical vertebrae: **A**, atlas vertebra (superior aspect); **B**, axis vertebra (posterosuperior aspect); **C**, seventh cervical vertebra (superior aspect).

The **lateral mass** presents the following features:

- (i) Its upper and lower surfaces bear superior and inferior articular facets, respectively.
 - The superior articular facet is concave and elongated. It is directed upwards and medially to articulate with the corresponding condyle of the occipital bone to form the *atlanto-occipital joint*.
 - The inferior articular facet is flat and circular. It is directed downwards, medially and backwards to articulate with the corresponding facet on the axis vertebra to form the *atlantoaxial joint*.
- (ii) The medial surface of the lateral mass is marked by a small roughened tubercle to provide attachment to the transverse ligament of the atlas.
- (iii) The transverse processes project laterally from the lateral masses. They are strong and larger than that of other cervical vertebrae. The elongated transverse processes act as efficient **levers** for the rotation of the atlas vertebra.

N.B. The most important feature of atlas vertebra is the absence of its body. The body is absent because during development the centrum of 1st cervical vertebra gets fused with the centrum of axis to form the dens. Thus dens of axis vertebra represents the body of the atlas vertebra.

Second Cervical Vertebra (Fig. 2.29B)

The 2nd cervical vertebra is called **axis** because the atlas rotates like a wheel around the pivot provided by the odontoid process (or dens) of 2nd cervical vertebra. It has the following features:

1. It possesses a strong tooth-like process projecting upwards from the body called **odontoid process**. The odontoid process represents the centrum (body) of the atlas, which has fused with the centrum of the axis vertebra.

The dens articulates anteriorly with the anterior arch of the atlas and posteriorly with the transverse ligament of the atlas. It provides attachment to the **apical ligament** at its apex and on each side below the apex to the **alar ligaments**.
2. The prominent anterior margin of the inferior surface of the body projects downwards to a considerable extent.
3. The spine is massive, i.e., it is large, thick and very strong and deeply grooved inferiorly. Its tip is bifid.
4. The transverse processes are very small and lack the anterior tubercles. The foramen transversarium is directed upwards and laterally.
5. The laminae are thick and strong.
6. The superior articular facets on the upper surface of the body extend onto the pedicles. The massive pedicle overhangs the foramen transversarium laterally.

The superior articular facet is large, flat, and circular. They are weight bearing and encroach on the side of the body. It is directed upwards and laterally to articulate with the corresponding facet of the atlas.

The inferior articular facet lies posterior to the transverse process and is directed downwards and forwards to articulate with the 3rd cervical vertebra.

N.B. The old name of the axis was the **OS Cheloni** because of its resemblance to the head of a tortoise.

Table 2.4 Atypical features of 1st, 2nd, and 7th cervical vertebrae

First cervical (atlas)	<ol style="list-style-type: none"> (a) Absence of body (b) Absence of spine (c) Long transverse processes (d) Superior articular facets are concave and elongated. They are kidney-shaped. The inferior articular facets are more or less circular
Second cervical (axis)	<ol style="list-style-type: none"> (a) Presence of odontoid process (b) Transverse processes are small and lack the anterior tubercle (c) Anterior margin of the inferior surface of the body projects downwards to a considerable extent (d) Foramen transversarium is directed superolaterally (cf. in typical vertebrae it is directed vertically) (e) Inferior surface presents a deep and wide inferior vertebral notch placed in front of the inferior articular process. The superior vertebral notch is shallow and is present behind the superior articular process
Seventh cervical (vertebra prominens)	<ol style="list-style-type: none"> (a) Spine is strong, long and not bifid (b) Transverse process is relatively long and lacks the anterior tubercle (c) Foramen transversarium is relatively small

Seventh Cervical Vertebra (Fig. 2.29C)

The 7th cervical vertebra is called **vertebra prominens** because its spine is very long and forms a prominent palpable projection in the lower part of the nuchal furrow.

The features of the 7th vertebra are as follows:

1. Its spine is thick, long, and nearly horizontal. It is not bifid and ends in a tubercle.
2. The transverse processes are comparatively long and large and lack the anterior tubercles.
3. The foramen transversarium is relatively small and does not transmit the vertebral artery. It transmits only accessory vertebral vein.

The atypical features of 1st, 2nd, and 7th cervical vertebrae are summarized in Table 2.4.

Clinical correlation

- **Carotid tubercle:** The anterior tubercle of the transverse process of 6th cervical vertebra is large and called **carotid tubercle of Chassaignac** because the common carotid artery can be compressed against it, medial to the anterior border of sternocleidomastoid muscle.
- **Hangman's fracture** (see page 109, Chapter 7).
- Luschka's joints are commonest sites of osteophyte formation (see page 105, Chapter 7).
- **Klippel–Feil syndrome** is a clinical condition in which cervical vertebrae are fused and deformed congenitally.
- The congenital fusion of ring of atlas vertebra to the base of the occiput is called **occipitalization of atlas**. It is one of the most common abnormalities of the upper cervical vertebrae.

Golden Facts to Remember

- | | |
|---|--|
| ▶ OS-Japonicum | Zygomatic bone divided into upper and lower parts |
| ▶ Most commonly fractured cranial fossa | Middle cranial fossa |
| ▶ Largest fontanelle | Anterior fontanelle |
| ▶ Metopic Suture | Median suture above nasion between two halves of frontal bone in adult skull |
| ▶ McEwen's triangle (suprameatal triangle) | A small triangular depression posterosuperior to the external auditory meatus (refer to page 31) |
| ▶ Largest foramen of skull | Foramen magnum |
| ▶ Most fragile and irregular bone of skull | Ethmoid |
| ▶ Commonest site of fracture mandible | Canine region |
| ▶ Cavities and bones within skull which are of full adult size at birth | Tympanic cavity, mastoid antrum, and ear ossicles |
| ▶ Most important part of temporal bone | Petrous part |
| ▶ Largest primary cartilaginous joint of skull | Basisphenoid joint |

Clinical Case Study



Mr Ramu, a young taxi driver, suffered a head injury following a collision of his taxi with a truck. He became unconscious. He was taken to the emergency room by the traffic police. Radiographs of the skull were taken. The lateral view of skull radiograph revealed a fracture in the region of temporal fossa and an underlying epidural/extradural hematoma. He was referred to the Department of Neurosurgery where he was operated. The surgical procedure involved the removal of hematoma and ligation of ruptured artery the next day. Mr Ramu regained consciousness and he was discharged from the hospital.

Questions

1. What is most important surface landmark in the region of temporal fossa?
2. Can this surface landmark be visualized or palpated. If not, then tell the method to locate it.
3. Name the vessels which ruptured to cause extradural hematoma and were ligated by the neurosurgeon.

Answers

1. Pterion (for details refer to page 18 of this chapter).
2. No. It lies 4 cm above the midpoint of the zygomatic arch and can be located by Stiles method (see page 11, Chapter 1).
3. Middle meningeal vessels.

Scalp, Temple, and Face

The scalp, temple, and face are important areas of the head, and therefore, need to be studied thoroughly. The injuries are frequently inflicted in these areas. The nature of injuries varies from superficial wounds to deep cuts. The scalp and temple are covered by thick hair; hence lesions at these sites go unnoticed for quite sometime by the people. Infection from these regions can travel inside cranial cavity through venous channels leading to fatal consequences. The face is the commonest site for plastic surgery done to enhance the beauty or to repair congenital defects and defects produced by the injuries. The simple inspection of face provides a substantial clue to a number of underlying bodily diseases. Also, the face being the exposed part of the body is prone to sun allergy and skin cancer.

SCALP

The term *scalp* is applied to the soft tissues covering the vault of skull.

Extent

It extends anteriorly up to the eyebrows (superciliary arches), posteriorly up to the superior nuchal lines, and laterally on each side up to superior temporal line (Fig. 3.1).

N.B. According to some authorities, scalp extends laterally on each side, up to the zygomatic arch.

LAYERS

The scalp consists of five layers. From superficial to deep these are as follows (Fig. 3.2):

1. Skin.
2. Connective tissue (superficial fascia).
3. Aponeurosis (occipitofrontalis muscle and its aponeurosis).

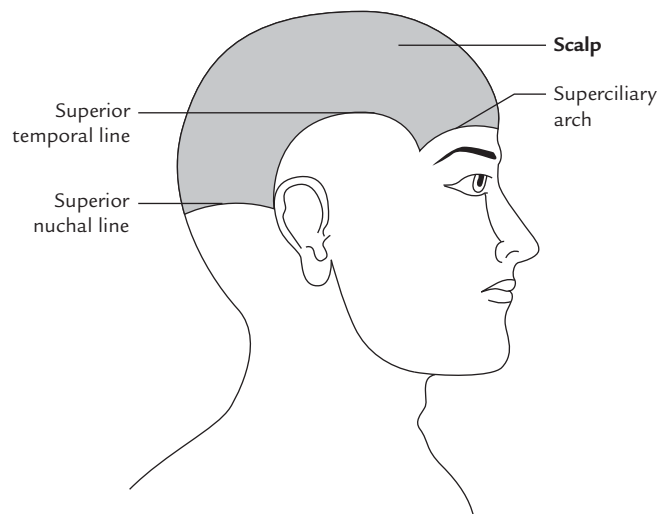


Fig. 3.1 Extent of the scalp.

4. Loose areolar tissue.
5. Pericranium.

The sequence of the layers of scalp can be easily remembered by a perfect **mnemonic SCALP** derived by using initial letter of each layer.

Skin: The skin of scalp is thick and hairy except over the forehead. It is firmly adherent to epicranial aponeurosis by dense connective tissue of superficial fascia, as in palms and soles. Being hairy it contains maximum number of hair follicles and associated sebaceous glands. As a result, scalp is the commonest site of **sebaceous cysts**. It also contains numerous sweat glands.

N.B. It has been estimated that there are about 1,20,000 hair on the scalp of an adult individual. About 20–100 hair are lost daily and replaced concomitantly. The baldness (loss of hair) mainly affects males and few elderly females with high level of androgenic hormones in their blood.

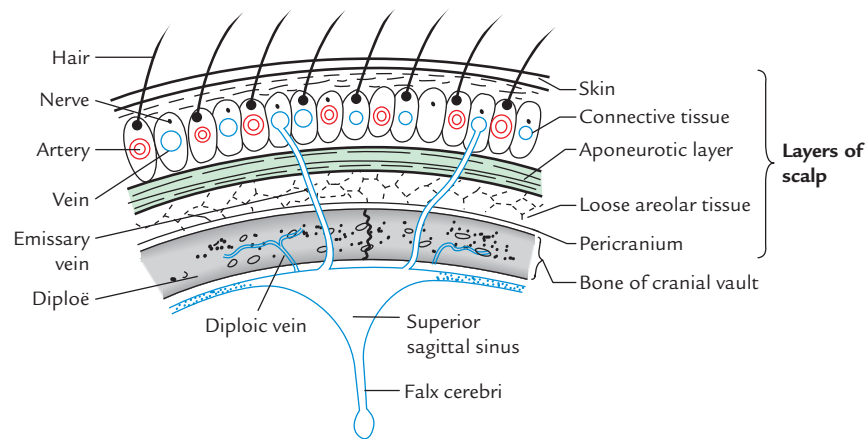


Fig. 3.2 Layers of the scalp.

Connective tissue (superficial fascia): The superficial fascia of the scalp is made up of dense fibrous connective tissue that firmly binds the skin to the underlying occipitofrontalis and its aponeurosis. Fibrous septa divide this layer into numerous small pockets containing lobules of fat. The blood vessels and nerves of the scalp lie in this layer. They enter it from below at the periphery.

The walls of the vessels are adherent to the fibrous network; hence when blood vessels are torn or cut during an injury, they are unable to retract and cause *profuse bleeding*. The bleeding, however, can be stopped by pressing against the underlying bone.

Aponeurosis: This layer is formed by occipitofrontalis muscle and its aponeurosis. The occipitofrontalis muscle consists of four small bellies: two frontal bellies and two occipital bellies. Since greater part of this layer is formed by aponeurosis, it is called *aponeurotic layer*. The aponeurosis of occipitofrontalis muscle is also called *epicranial aponeurosis* or *galea aponeurotica* (Latin: *galea* = helmet).

The wounds of the scalp do not gape unless epicranial aponeurosis is cut transversely because the aponeurosis is under tension in the anteroposterior direction by the tone of occipitofrontalis muscle.

Loose areolar tissue: As the name indicates, this layer is made of loose areolar tissue. It serves as a natural plane of cleavage during craniotomy. This layer is traversed by emissary veins connecting veins in the second layer of scalp with intracranial dural venous sinuses.

Pericranium: The fifth layer of scalp is formed by the periosteum of bones of vault of skull called *pericranium*. It is loosely attached to the bones and can be easily stripped, but at sutures it is firmly attached to sutural membrane, which in turn attaches it to the endocranium (the periosteum covering inner aspect of the skull bones).

Further Details

Occipitofrontalis muscle (Fig. 3.3)

Origin and insertion:

1. The frontal bellies arise from skin and subcutaneous tissue over the eyebrows and root of the nose, run backwards to be inserted into epicranial aponeurosis in front of coronal suture. They have no bony attachment of their own. The deeper fibres of frontal belly merge with procerus, corrugator supercilii, and orbicularis oculi muscles. The front bellies are longer, wider, and partly united with each other along their medial borders.
2. The occipital bellies arise from lateral two-third of the superior nuchal lines and extend forwards to be inserted into the epicranial aponeurosis. The two occipital bellies are small and separated from each other by a considerable gap. This gap is filled by epicranial aponeurosis.

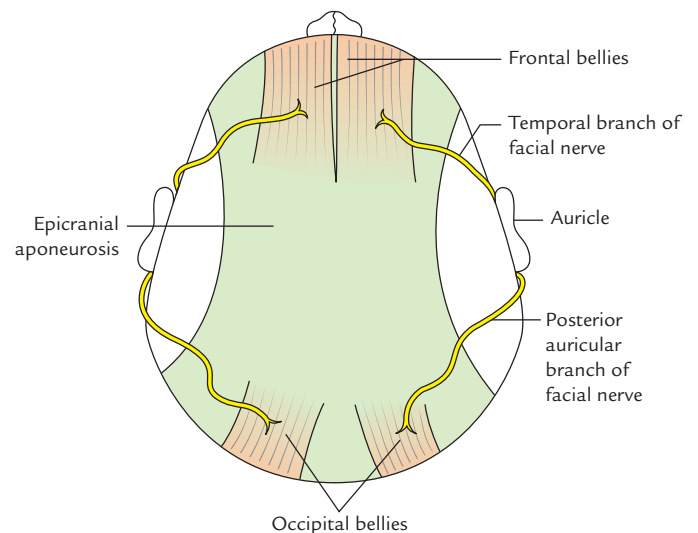


Fig. 3.3 Occipitofrontalis muscle.

Nerve supply: The occipital belly on each side is supplied by *posterior auricular branch of facial nerve* whereas the frontal belly is supplied by *temporal branch of the facial nerve*.

Actions

1. Alternate contractions of frontal and occipital bellies move the scalp forwards and backwards over the vault of the skull.
2. Acting from above, the contraction of frontal bellies raise the eyebrows as in surprise.
3. Acting from below, the contractions of frontal bellies produce transverse wrinkles on the forehead as in fright.

Clinical correlation

- **Surgical layers of the scalp:** First three layers of the scalp, i.e., skin, connective tissue layer, and aponeurotic layer are firmly adhered to each other and cannot be separated from each other. These layers are termed *surgical layers of the scalp* and form the *scalp proper*.

The layer of loose areolar tissue beneath the aponeurotic layer accounts for the free mobility of the scalp proper on the underlying bone. Further, it provides an easy plane of cleavage in injury and a plane in which blood from severed blood vessels can spread for a long distance. When the hairs are caught in machinery, the scalp proper is avulsed. The Red Indians of bygone days used to remove the scalp (proper) of their victims as punishment. It is in this plane that surgeons mobilize scalp flaps.

- **Black eye:** The blood and fluid collecting in the layer of loose areolar tissue following a blow on head tracks freely under the scalp producing generalized swelling over the dome of the skull, but cannot pass into either occipital or temple regions because of the bony attachments of the occipitofrontalis. The blood and fluid can, however, track forward into the eyelids because occipitofrontalis has no bony attachment anteriorly (Fig. 3.4). This leads to formation of hematoma few hours after a head injury or cranial operation causing black discoloration of skin around the eyes, a condition called **black eye**.

It is important to note that the commonest cause of black eye is local violence, such as fist fight causing subcutaneous extravasation of blood into the eyelids.

- **Dangerous area of the scalp:** The layer of loose areolar tissue is called *dangerous layer of scalp* because blood and pus freely tend to collect in this layer. If pus collects in this layer, the infection may travel readily along emissary veins into the intracranial dural venous sinuses leading to their thrombosis, which may be fatal.
- **Safety-valve hematoma, cephalhematoma and caput succedaneum**
 - Fracture of cranial vault in children may be associated with the tearing of dura mater and pericranium. In such cases the blood from intracranial hemorrhage communicates with the subaponeurotic space of the scalp through the fracture lines. The signs of cerebral compression do not develop until the subaponeurotic space is fully filled with blood. For this reason the collection of blood in the fourth layer is called a *safety-valve hematoma*.

If cerebrospinal fluid collects in the subaponeurotic space, the condition is called *cephalhydrocele*.

- **Cephalhematoma** is a subperiosteal collection of blood. Since the periosteum of skull loosely covers the bones of skull except at the sutural lines where it is firmly attached to the sutural membranes, the hematoma is bound by suture lines and assumes the shape of related bones. It is firm and its edges are well-defined. A cephalhematoma is commonly found in the parietal region.
- **Caput succedaneum** is a subcutaneous edema over the presenting part of the head at delivery. It takes place during the passage of head through the birth canal due to interference of the venous return. It is the most common form of birth trauma of the scalp and usually occurs over the occiput and crosses the suture lines. The affected parts of the scalp feel soft and margins are partly defined. Generally the edema subsides, in a few days.

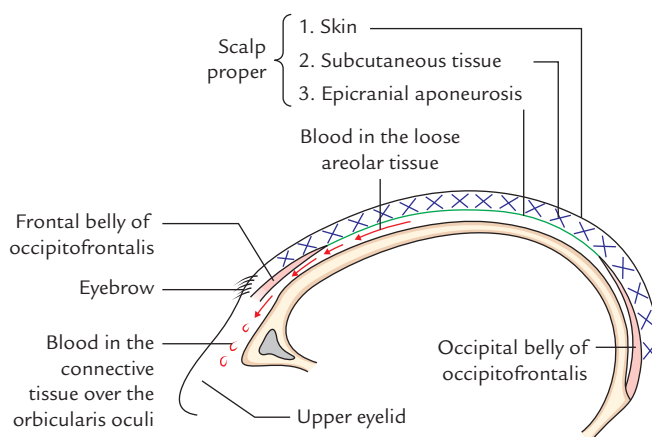


Fig. 3.4 Sagittal section of the skull cap and overlying soft tissues. Note the migration of blood from 4th layer of the scalp (layer of loose areolar tissue) to the scanty subcutaneous tissue over orbicularis oculi.

NERVE SUPPLY

A. Sensory supply of the scalp (Fig. 3.5)

The scalp on each side of the midline is supplied by eight sensory nerves: four in front of the auricle and four behind the auricle. The nerves in front of the auricle are derived from trigeminal nerve, whereas those behind the auricle are derived from the 2nd and 3rd cervical nerves (Table 3.1).

B. Motor supply of the scalp

The scalp on each side of the midline is supplied by two motor nerves: one in front of the ear and one behind the ear; both these nerves are derived from the facial nerve (Fig. 3.3).

- Nerve in front of the ear is *temporal branch of the facial nerve*. It supplies frontal belly of occipitofrontalis muscle.

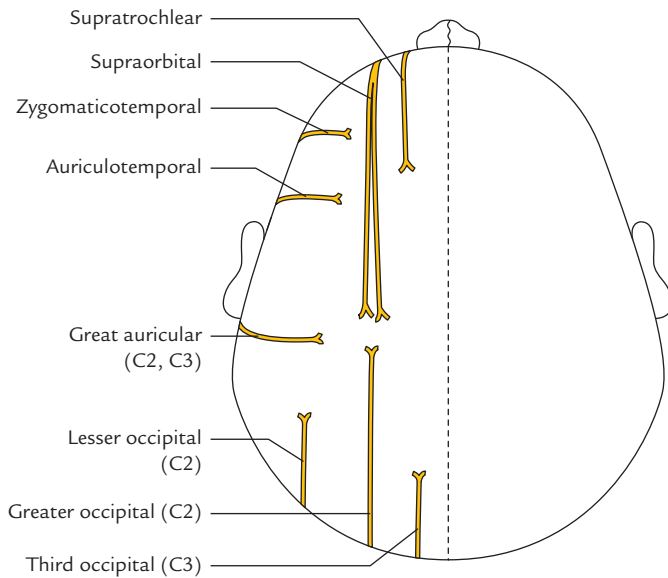


Fig. 3.5 Sensory supply of the scalp (shown in left half only).

- Nerve behind the ear is the *posterior auricular branch of the facial nerve*. It supplies occipital belly of occipitofrontalis muscle.

ARTERIAL SUPPLY

The scalp has very rich blood supply. On each side of midline, it is supplied by *five arteries*: three in front of the auricle and two behind the auricle (Table 3.2 and Fig. 3.6).

Site of Entry of Arteries in the Scalp

1. **Supratrochlear artery**, enters the scalp around supraorbital margin one-finger breadth lateral to the midline.

Table 3.1 Sensory nerves of the scalp

In front of the auricle (from before backwards)	Behind the auricle (from before backwards)
Supratrochlear, a branch of frontal nerve from ophthalmic division of trigeminal nerve	Great auricular, derived from ventral rami of 2nd and 3rd cervical nerves
Supraorbital, a branch of frontal nerve from ophthalmic division of trigeminal nerve	Lesser occipital, derived from ventral ramus of 2nd cervical nerve
Zygomaticotemporal, a branch of zygomatic nerve from maxillary division of trigeminal nerve	Greater occipital, derived from dorsal ramus of 2nd cervical nerve
Auriculotemporal, a branch of mandibular division of trigeminal nerve	Third occipital, derived from dorsal ramus of 3rd cervical nerve

Table 3.2 Arteries supplying the scalp

In front of the auricle (from before backwards)	Behind the auricle (from before backwards)
Supratrochlear, a branch of ophthalmic artery from internal carotid artery	Posterior auricular artery, a branch of external carotid artery
Supraorbital, a branch of ophthalmic artery from internal carotid artery	Occipital artery, a branch of external carotid artery
Superficial temporal, a branch of external carotid artery	

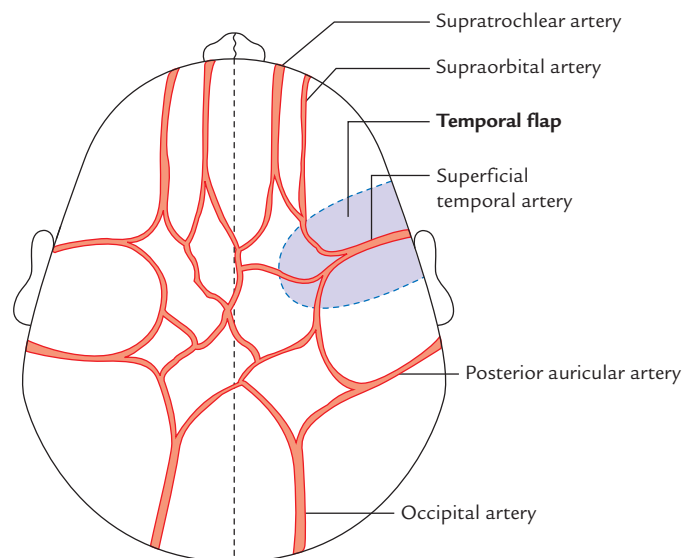


Fig. 3.6 Arterial supply of the scalp. The area enclosed by blue dotted line shows the temporal flap.

2. **Supraorbital artery**, enters the scalp through supraorbital notch 2–3 cm lateral to the supratrochlear artery.
3. **Superficial temporal artery** (the smaller terminal branch of the external carotid), enters the scalp in front of the root of zygoma and divides into anterior and posterior branches.
4. **Posterior auricular artery**, enters the scalp behind the root of the ear.
5. **Occipital artery**, enters the scalp midway between the ear and the external occipital protuberance.

N.B. The first two arteries are the branches of ophthalmic artery from internal carotid artery while later three arteries are the branches of external carotid artery.

The arteries of one side freely anastomose with one another. There is also cross anastomosis between the

arteries of two sides. Thus the scalp is also the site of potential collateral circulation between the external and internal carotid arteries.

Clinical correlation

- The **scalp wounds bleed profusely but heal quickly** due to high vascularity. The avulsed portions of scalp, therefore, should not be cut away rather they should be placed in position and stitched.
- Since all the arteries supplying the scalp enter it from below at the periphery, (i.e., from face and neck) the flaps of scalp during craniotomy are made by incisions given in the centre and reflected towards the periphery; thereby preserving their blood supply. To ensure the blood supply of the scalp, the skin incisions should be placed in such a way that the base of the flap incorporates the stem of one of the arteries supplying the scalp.
- Since all the superficial arteries supplying the scalp ascend from face and neck. Therefore *life-threatening scalp-hemorrhage* can be stopped as a first-aid measure, by encircling the head just above the ears and eyebrows with a string or strong-strap of cotton and tied tightly.

VENOUS DRAINAGE

The scalp on each side of the midline is drained by five veins. The veins of the scalp accompany the arteries and have similar names. These are as follows:

1. **Supratrochlear and supraorbital veins:** They join each other at the medial angle of the eye to form the **angular vein**, which continues downwards as the facial vein behind the facial artery.
3. **Superficial temporal vein:** It descends in front of tragus to enter the parotid gland where it joins the maxillary vein to form the **retromandibular vein**, which terminates by dividing into anterior and posterior divisions. The anterior division unites with the facial vein to form *common facial vein*, which drains into the internal jugular vein.
4. **Posterior auricular vein:** It descends behind the auricle and unites with the posterior division of the retromandibular vein to form the *external jugular vein*, which drains into the subclavian vein.
5. **Occipital vein:** It terminates in the *suboccipital venous plexus*.

The veins of the scalp communicate with intracranial dural venous sinuses through emissary veins.

Clinical correlation

In infants, the veins of the scalp are easily seen deep to the skin, hence they are the favored sites for **intravenous infusion**.

Emissary Veins

The veins connecting the veins outside the cranium with the intracranial dural venous sinuses by passing through foramina in the cranium are called *emissary veins*.

Emissary Veins in the Region of the Scalp

On each side of the midline in the region of the scalp two sets of emissary veins are encountered, viz.

1. **Parietal emissary vein**, which passes through parietal foramen and communicates with the superior sagittal sinus.
2. **Mastoid emissary vein**, which passes through mastoid foramen and communicates with the sigmoid sinus.

Diploic Veins

The diploic veins are described in detail in Chapter 21.

Clinical correlation

Diploic veins are thin walled. They are devoid of valves and drain the diploë of some cranial bones. They begin to develop with diploë at about 2 years of age.

Radiologically they may be seen as relatively transparent bands, 3–4 mm wide.

LYMPHATIC DRAINAGE

The lymphatics from anterior part of the scalp except the lower half of the forehead drain into *preauricular (or superficial parotid) lymph* nodes situated on the surface of the parotid gland.

The lymphatics from posterior part of the scalp drain into *posterior auricular (mastoid) and occipital lymph nodes*.

TEMPLE

The area on the side of the skull between the superior temporal line and zygomatic arch is popularly known as *temple*. The name temple is supposedly derived from the fact that with age (i.e., time) greying of hair occur first in this area (tempus = time).

LAYERS OF SOFT TISSUE IN THE TEMPLE

There are *six layers* of soft tissue in the region of temple. From superficial to deep, these are (Fig. 3.7):

1. Skin.
2. Connective tissue.
3. Extension of epicranial aponeurosis.
4. Temporal fascia.
5. Temporalis muscle.
6. Pericranium.

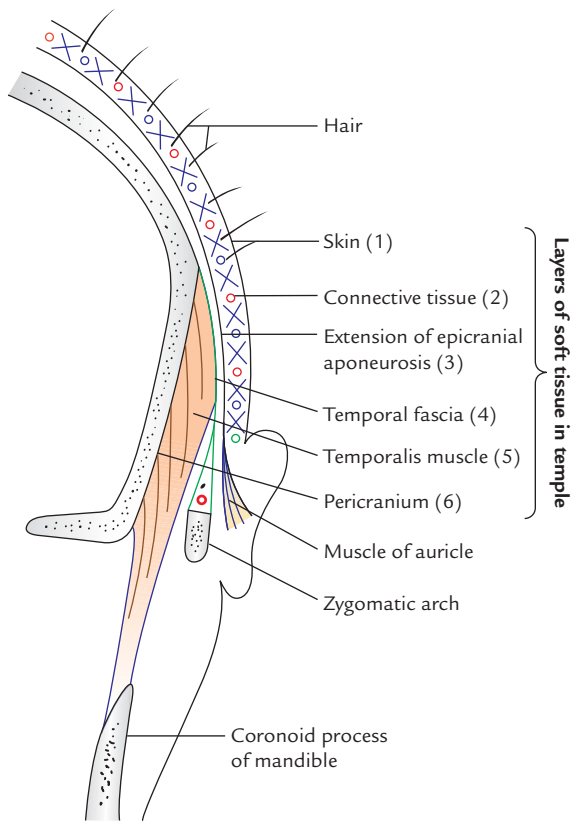


Fig. 3.7 Layers of the soft tissue in the temple.

Skin and connective tissue: These two layers are same as in the region of the scalp.

Extension of epicranial aponeurosis: It gives origin to the auricularis anterior and auricularis superior muscles of the auricle.

Temporal fascia: It forms a roof over temporal fossa. It is attached above to the temporal line and below to the zygomatic arch. Inferiorly the temporal fascia splits into two layers, which are attached to the inner and outer lips of the zygomatic arch. A small gap between the two layers contains (a) fat, (b) a branch from superficial temporal artery, and (c) zygomaticotemporal nerve.

The superficial surface of temporal fascia is related to: (a) superficial temporal vessels, (b) auriculotemporal nerve, and (c) temporal branches of the facial nerve.

The deep surface of temporal fascia gives origin to some fibres of temporalis muscle.

Temporalis muscle: This large fan-shaped muscle arises from the floor of the temporal fossa and inner aspect of the temporal fascia. Its fibres converge inferiorly and pass deep to the zygomatic arch to be inserted into the coronoid process of mandible. (It is described in detail in Chapter 10.)

Pericranium: This layer is same as in the region of the scalp.

Clinical correlation

The temporal fascia is silvery-white thick fibrous sheet, which is more or less aponeurotic in character. It is the thickest fascia in the body. Morphologically, it represents a shell of a bone. In some species (e.g., tortoise), it is replaced by bone to make the temporal fossa a bony tunnel.

The temporal fascia is as a graft used by ENT surgeons for **tympanoplasty** (repair of the tympanic membrane).

FACE

The face is the front aspect of the head possessing eyes, nose, and mouth. It extends superiorly up to the hair line, inferiorly up to the chin and base of the mandible and on each side up to the auricle. The forehead is common to both the face and the scalp. For proper understanding of anatomy of the face, one should first study the features on the anterior aspect of the skull (norma frontalis) described in Chapter 2 and living anatomy described in Chapter 1.

SKIN OF THE FACE

The skin of the face is thick, elastic, and very vascular. It contains large number of sweat and sebaceous glands. The sweat glands help to regulate the body temperature whereas sebaceous glands keep the face oily by their secretion. The skin of face is lax except on the nose where it is firmly attached to the underlying cartilages and provides insertion to the muscles of facial expression.

Clinical correlation

Since the blood supply to the skin of the face is profuse, therefore it is rare in plastic surgery for skin flaps to necrose in this region. The laxity of greater part of skin facilitates rapid spread of edema in the region of the face. Face is also the common site for acne due to the presence of large number of sebaceous glands in this region.

Cleavage Lines of Skin in the Face (Fig. 3.8)

The direction of cleavage lines in the face varies regionally. However, these lines frequently (but not always) coincide with natural wrinkle lines of the face. The natural wrinkle lines result from repeated folding of the skin perpendicular to the long axis of the underlying contracting muscles of facial expression. They become prominent in the elderly due to loss of youthful skin elasticity.

When the lesions of skin, *viz.* scars, pigmented patches, skin cancers are excised. It is important to give incisions along the long axis of natural wrinkle lines and the lesion should be enclosed in an ellipse. If the resulting scar is to be aesthetically acceptable.

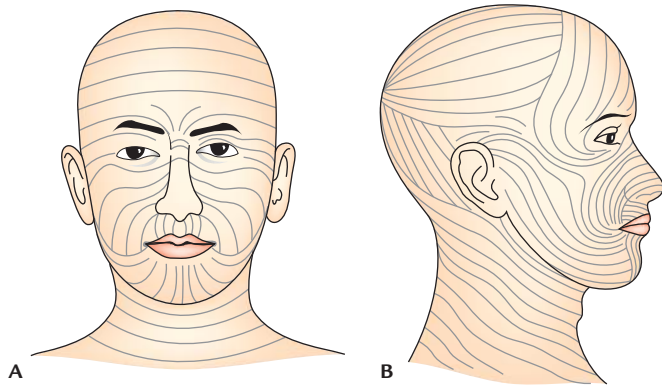


Fig. 3.8 Lines of cleavage in the head and neck region: A, front view; B, lateral view.

Superficial Fascia

It contains muscles of facial expression, vessels and nerves, and variable amount of fat. The fat is absent in the eyelids but is well-developed in cheeks forming *buccal pad of fat*, which provides rounded contour to cheeks. The buccal pads of fat are very prominent in infants in whom they help in suckling the milk and are called *suctorial pad of fat*.

Deep Fascia

The deep fascia is absent in the region of face except over the parotid gland and masseter muscle, which are covered by *parotidomasseteric fascia*. The absence of deep fascia in the face is essential for the facial expression.

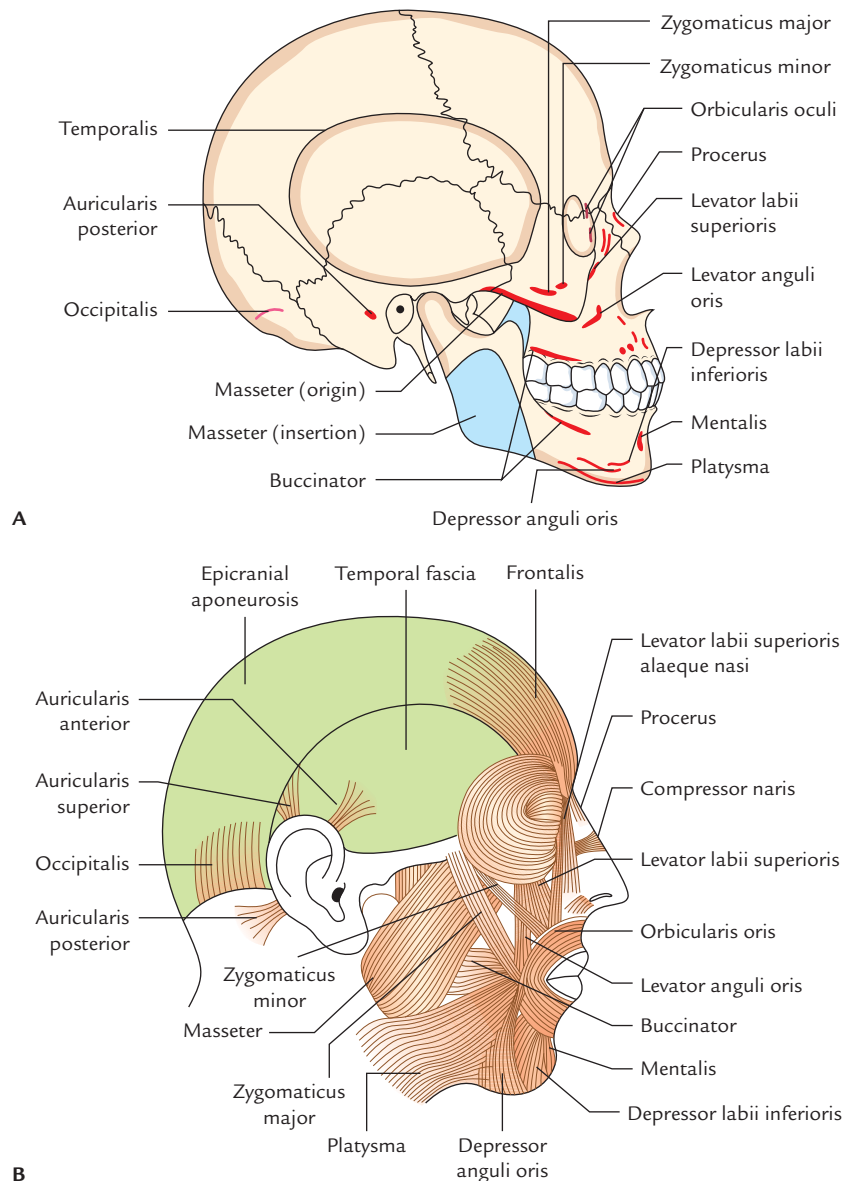


Fig. 3.9 Muscles of the facial expression: A, sites of bony attachment; B, position in the face. Masseter (muscle of mastication) is also shown.

MUSCLES OF FACIAL EXPRESSION

The muscles of facial expression are embedded in the superficial fascia. Most of them arise from bones of the skull and are inserted into the skin. They bring about different types of facial expressions, hence the name *muscles of facial expression*, the actions of many of them are implied by their names (Fig. 3.9).

Characteristic Features of the Muscles of Facial Expression

The characteristics of the muscles of facial expressions are as follows:

1. They *lie in superficial fascia and inserted into the skin*.
2. Morphologically, they represent the specialized members of the subcutaneous muscle (*panniculus carnosus*), of lower animals.
3. Embryologically, they *develop from mesoderm* of 2nd pharyngeal arch, hence supplied by facial nerve, the nerve of 2nd arch.
4. Functionally, they perform all important functions of *non-verbal communication* in addition to closing and opening the orifices in the region of the face.

Location and Function

The facial muscles are arranged in groups around the orifices of mouth, eye, and nose as sphincters and dilators of these orifices.

In addition to regulating the opening and closing of these orifices, as mentioned earlier, they produce different types of facial expressions. To perform fine movements of facial expressions the facial muscles have *small motor units*.

Though all these muscles are important for facial expression, the students are advised not to burden their memory with their attachments. However, they should appreciate the importance of *orbicularis oculi*, *orbicularis oris*, and *buccinator* for the serious consequences following their paralysis.

N.B. In addition to muscles around the eye, nose, and mouth, the muscles of facial expression also include the muscles of scalp, auricle and the subcutaneous muscle of the neck—the platysma.

Muscles Around the Orifice of the Eye

These include:

1. Orbicularis oculi.
2. Corrugator supercilii.
3. Frontalis.
4. Levator palpebrae superioris.

Orbicularis oculi It consists of three parts—orbital, palpebral, and lacrimal.

1. **Orbital part**—arises from medial palpebral ligament, frontal process of maxilla, and adjoining part of the frontal bone. The fibres form complete elliptical loops on and around the orbital margin, without interruption before returning to their point of origin.

It closes the eye tightly to protect the eye from intense light and dust particles. It is also used by people for winking.

2. **Palpebral part**—arises from medial palpebral ligament and sweeps laterally over the upper and lower eyelids to be inserted into the lateral palpebral ligament. A small group of fibres called *ciliary bundle* lie along the margins of both eyelids.

It closes the eyelids gently as in sleep or in blinking.

3. **Lacrimal part**—lies behind the lacrimal sac. It arises from posterior lacrimal crest and lacrimal fascia forming a sheath of lacrimal sac that passes laterally in front of tarsal plates of both eyelids to be inserted into the lateral palpebral raphe.

It dilates the lacrimal sac by exerting traction on the lacrimal fascia, thus helping in the drainage of lacrimal fluid.

Clinical correlation

- **Crow's feet:** The contraction of entire orbicularis oculi draws the skin of forehead, temple, and cheek towards the lateral angle of the eye, producing radiating skin folds from the lateral angle of the eye, which may be a permanent feature in some old people forming the so called *crow's feet*.
- **Ectropion:** The paralysis of orbicularis oculi results in drooping of the lower eyelid (ectropion) causing spilling of tear on the cheek (epiphora).

Corrugator supercilii: It arises from the medial end of the superciliary arch, passes laterally and upwards to be inserted into the skin of the eyebrow above the middle of the supraorbital margin.

It drags the eyebrow medially and downwards producing vertical wrinkles on the forehead as in frowning, an expression of annoyance.

Frontalis: It is already described in the section on scalp. The frontalis elevates the eyebrows and produces transverse wrinkles on the forehead as an expression of surprise, horror or fright.

Levator palpebrae superioris: It is not a muscle of the face but one of the orbital muscles, hence described in detail under orbit (Chapter 19). Levator palpebrae superioris is an antagonist to the sphincteric action of palpebral part of orbicularis oculi. It elevates the upper eyelid.

Muscles Around the Nasal Cavity

The muscles associated with nasal cavity are as follows:

1. Procerus.

2. Nasalis.
3. Depressor septi.

These muscles are poorly developed because anterior nares are open.

Procerus: It arises from nasal bone, passes upwards to be inserted into the skin of the lower part of the forehead.

It produces transverse wrinkles across the bridge (root) of the nose as in frowning.

Nasalis: It consists of two parts: transverse part called *compressor naris* and alar part called *dilator naris*.

1. Compressor naris arises from maxilla close to the nasal notch, passes upwards and medially to form an aponeurosis across the bridge of nose where it becomes continuous with its counterpart on the opposite side.

It compresses the nasal aperture.

2. Dilator naris arises from maxilla from the margin of the nasal notch and inserted into the lateral part of the ala of the nose.

It dilates the anterior nasal apertures as in deep inspiration. It also expresses the anger (sign of omega).

Depressor septi: It arises from the incisive fossa of the maxilla and is inserted into the lower mobile part of the nasal septum.

It fixes the nasal septum to allow dilatation of anterior nasal aperture by dilator naris.

Muscles Around the Mouth

The muscles around the mouth are responsible for the movement of lips and cheek. These include:

1. **Orbicularis oris:** Acts as sphincter.
2. **Nine muscles** converging around the mouth act as dilators.

Orbicularis Oris (Fig. 3.10)

This complex muscle surrounds the oral orifice and forms the greater part of the lips. It has extrinsic and intrinsic portions. The major *extrinsic (or superficial) portion* is composed of interlacing fibres of the muscles which converge around the mouth for their insertion into the lips, viz. levator anguli oris, depressor anguli oris, buccinator, etc. Most of the fibres come from buccinator. The fibres of buccinator converge towards the modiolus. At modiolus they form chiasma. The uppermost and lowermost fibres pass straight into their respective lips, whereas the middle fibres decussate, so that the upper fibres pass into the lower lip, and lower into the upper lip.

The *intrinsic portion* consists of fibres running obliquely between the skin and mucus membrane of the lips, and incisive slips, which pass laterally into the lips from the jaws adjacent to the incisor teeth and interlace with the fibres of

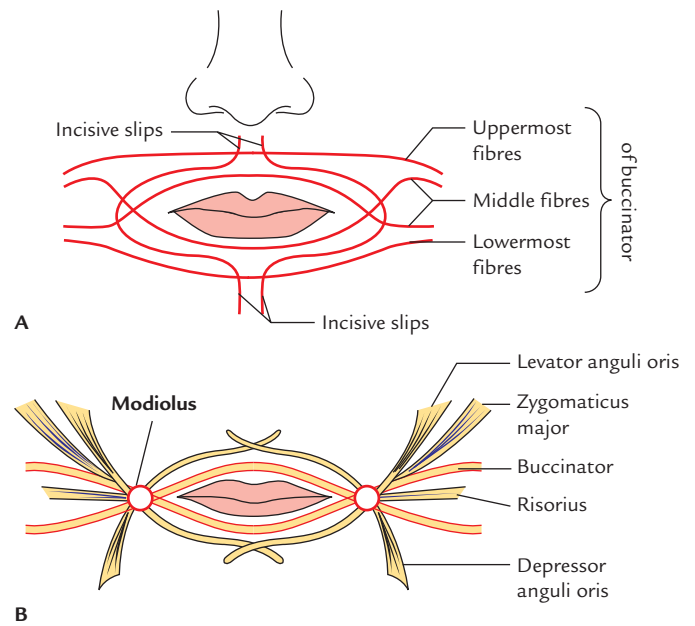


Fig. 3.10 Orbicularis oris muscle: A, arrangement of fibres; B, formation of modiolus.

peripheral part of orbicularis oris as they approach the modiolus.

Nerve supply

Buccal branch of the facial nerve.

Actions

Because of its complex nature, orbicularis oris is capable of producing wide variety of movements of lips such as closing, pouting, pursing, twisting, etc.

Clinical correlation

Paralysis of orbicularis oris: The paralysis of one-half of orbicularis oris prevents the proper closure of lips on that side. Consequently the speech is slurred and the saliva escapes between the lips at the angle of the mouth (*dribbling of saliva from the angle of the mouth*).

Nine Muscles Converging Around the Mouth

These are as follows:

1. Levator labii superioris alaeque nasi.
2. Levator labii superioris.
3. Levator anguli oris.
4. Zygomaticus minor.
5. Zygomaticus major.
6. Depressor labii inferioris.
7. Depressor anguli oris.
8. Risorius.
9. Buccinator.

The muscle of chin called *mentalis* is usually discussed with muscles around the mouth.

- **Levator labii superioris alaeque nasi** arises from the frontal process of the maxilla and is inserted into the ala of nose by one slip and to the upper lip by another slip.

It elevates the upper lip and helps to dilate the nostril.

- **Levator labii superioris** arises from maxilla just above the infraorbital foramen and is inserted into the upper lip.

It elevates the upper lip.

- **Levator anguli oris** arises from maxilla below the infraorbital foramen and is inserted into the angle of the mouth. It lies deep to levator labii superioris.

It raises the angle of the mouth.

- **Zygomaticus minor** arises from zygomatic bone and is inserted into the upper lip.

It elevates the upper lip.

- **Zygomaticus major** arises from zygomatic bone and is inserted into the angle of the mouth.

It draws the angle of the mouth upward and laterally.

- **Depressor labii inferioris** arises from the anterior oblique line of the mandible and is inserted into the lower lip.

It draws the lower lip downwards and somewhat laterally.

- **Depressor anguli oris** arises from the posterior part of the oblique line of the mandible and is inserted into the angle of the mouth.

It draws the angle of the mouth downwards and laterally.

- **Risorius** arises from parotid fascia as a continuation of posterior fibres of platysma and is inserted into the angle of the mouth.

It retracts the angle of the mouth gently.

- **Mentalis**, a small conical muscle arises from the incisive fossa of the mandible and is inserted into the skin of the lower lip.

It puckers the chin and protrudes the lower lip.

- **Buccinator (Bugler's muscle/trumpeter's muscle)** is muscle of the cheek and needs to be discussed in detail (Fig. 3.11).

Origin: The buccinator arises from the following 4 sites:

1. **Outer surface of the alveolar process of maxilla** opposite three molar teeth.
2. **Fibrous band** that extends from pterygoid hamulus to maxillary tuberosity (pterygomaxillary raphe).
3. **Pterygomandibular raphe**, which extends from pterygoid hamulus to the mandible behind the third molar tooth.
4. **Outer surface of the alveolar process of mandible** opposite three molar teeth.

After origin, the fibres run towards the mouth and fill the gap between the upper and lower jaws. The fibres are arranged into upper, intermediate, and lower groups.

Insertion: The buccinator is inserted in a complicated manner into the upper and lower lips.

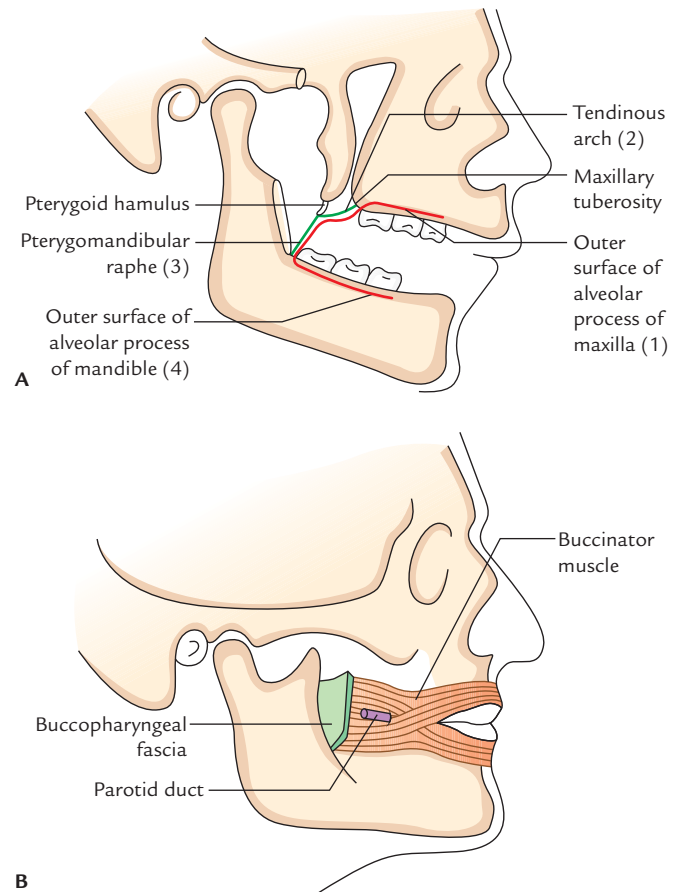


Fig. 3.11 Buccinator muscle: A, origin; B, location in the face and insertion.

On reaching near the angle of the mouth:

- (a) upper fibres pass into upper lip,
- (b) lower fibres pass into the lower lip, and
- (c) intermediate fibres decussate and as a result upper fibres of this group pass into lower lip and lower fibres pass into the upper lip.

Nerve supply: Buccal branches of facial nerve.

Actions:

1. It flattens the cheek against the gum and teeth, and thus prevents the accumulation of food in the vestibule of mouth during mastication.
2. It is responsible for blowing the cheek and expelling the air between the lips from inflated vestibule as in blowing the trumpet (hence the name *trumpeter's muscle*).

N.B. The outer surface of buccinator muscle is covered by *buccopharyngeal* fascia and its inner surface is lined by a mucus membrane. It is pierced by parotid duct. The pterygomandibular raphe separates it from superior constrictor of the pharynx. A gap between maxillary fibres and those from pterygomaxillary raphe provides passage to the tendon of tensor palati.

Clinical correlation

- **Paralysis of buccinator muscle:** If the buccinator muscle is paralyzed, as it occurs in facial palsy, the food accumulates in the vestibule of mouth during mastication and the person cannot blow his cheek.
- **Modiolus:** It is a dense, compact, mobile, fibromuscular mass situated about 1.25 cm lateral to the angle of the mouth. It is formed due to interlacing of fibres of five muscles which converge towards the angle of the mouth. These muscles (modiolar muscles) are: levator anguli oris, zygomaticus major, buccinator, depressor anguli oris and risorius (Fig. 3.10B).

It can be easily palpated by using opposed thumb and index finger to compress the skin and mucosa simultaneously. The pulsations of facial artery can be felt just lateral to the modiolus. The inadvertent damage of modiolus during plastic surgery leads to unacceptable facial asymmetry.

Facial Muscles and Emotional Expressions

The facial muscles responsible for important emotional expressions are presented in Table 3.3.

Clinical Testing of the Muscles of Facial Expression

The muscles of facial expression are involved in facial nerve lesion. They are tested clinically in the following ways:

- **Frontalis**, by asking the patient to look upwards without moving his head and then look for horizontal wrinkles on the forehead.
- **Corrugator supercillii**, by asking the patient to frown and then look for vertical wrinkles between the two eyebrows.

- **Orbicularis oculi**, by asking the patient to close the eyes tightly.
- **Orbicularis oris**, by asking the patient to whistle.
- **Dilators of the mouth**, by asking the patient to show his teeth.
- **Buccinator**, by asking the patient to puff his mouth and then blow out the air forcefully.
- **Zygomaticus major**, by asking the patient to laugh.
- **Risorius**, by asking the patient to smile gently.

NERVE SUPPLY

Motor Nerve Supply (Fig. 3.12)

The motor nerve supply of the face is derived from the *facial nerve*. After coming out of cranial cavity through stylo mastoid foramen, the facial nerve wind around the lateral aspect of styloid process and then enters the parotid gland. Here it divides into five terminal branches (viz. temporal, zygomatic, buccal, marginal mandibular, and cervical), which emerge in the face radiating through the anterior border of the parotid gland and supply the muscles of facial expression (Table 3.4). These five sets of terminal branches form the *goose-foot pattern* (pes anserinus) on the face (also see p. 117). The facial nerve is described in detail in Chapter 22.

N.B. The general course of five terminal branches of facial nerve can be easily remembered by putting the palm of your hand over the auricle and spreading the five digits (Fig. 3.13). The five digits represent the five terminal branches of the facial nerve.

Table 3.3 Facial muscles and emotional expressions

Emotional expression	Presenting features	Facial muscle/muscles
Surprise/horror/fright	Transverse wrinkles of the forehead	Frontalis
Frowning	<ul style="list-style-type: none"> • Vertical wrinkles of the forehead • Transverse wrinkle across the root of nose 	<ul style="list-style-type: none"> • Corrugator supercillii • Procerus
Anger	<ul style="list-style-type: none"> • Dilation of the anterior nasal aperture • Depression of lower mobile part of the nasal septum 	<ul style="list-style-type: none"> • Dilator naris • Depressor septi
Laughing	Angle of mouth drawn upwards and laterally	Zygomaticus major
Sadness/sorrow/grief	<ul style="list-style-type: none"> • Accentuation of nasolabial fold • Elevation and eversion of the upper lip 	<ul style="list-style-type: none"> • Levator labii superioris • Levator anguli oris and zygomaticus minor
	<ul style="list-style-type: none"> • Angle of mouth drawn downwards and laterally 	<ul style="list-style-type: none"> • Depressor anguli oris
Grinning	Retraction of angle of the mouth laterally	Risorius
Disdain/doubt	Puckering of the chin, protrusion of lower lip	Mentalis
Worry	Skin folds radiating laterally from lateral angle of the eye	Orbicularis oculi
Irony	Angle of the mouth drawn downwards and somewhat laterally	Depressor labii inferioris

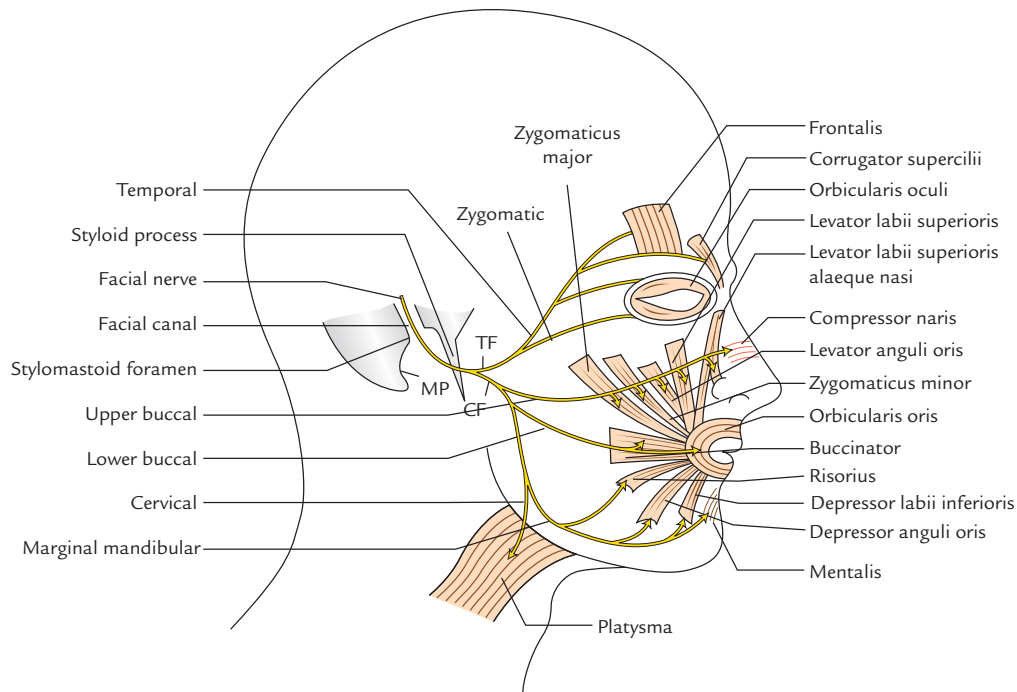


Fig. 3.12 Motor supply of the muscles of facial expression. Auricular muscles are not shown as they have no role in the facial expression in human beings (CF = cervicofacial trunk, MP = mastoid process, TF = temporofacial trunk).

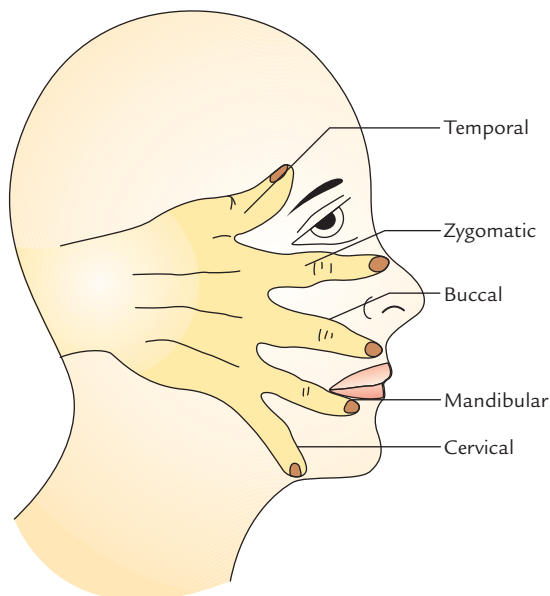


Fig. 3.13 Lateral view of the face illustrating the simple method of remembering the terminal branches of the facial nerve.

Clinical correlation

Bell's palsy (Fig. 3.14): It is lower motor neuron type paralysis of facial muscles due to compression of facial nerve in the facial canal near stylomastoid foramen. The exact etiology is not known but it is probably due to viral infection.

Characteristic Features on the Side of Paralysis (Fig. 3.14)

1. *Facial asymmetry* (affected side is drawn to the healthy side)—due to unopposed action of muscles of normal side.
2. *Loss of horizontal wrinkles on forehead*—due to paralysis of occipitofrontalis muscle.
3. *Widening of palpebral fissure and inability to close the eye*—due to paralysis of orbicularis oculi.
4. *Tears flow down from the eye (epiphora)*—due to paralysis of the lower part of the orbicularis oculi.
5. *Sagging of the angle of the mouth towards the affected side and inability of the angle of the mouth to move upwards and laterally during laughing*—due to paralysis of zygomaticus major.
6. *Loss of nasolabial furrow*—due to paralysis of levator labii superioris alaeque nasi.
7. *Accumulation of food into the vestibule of the mouth*—due to paralysis of buccinator muscle.
8. *Dribbling of saliva from the angle of the mouth*—due to paralysis of orbicularis oris.
9. *Loss of resistance when one presses cheek with inflated vestibule and air leaks out from between the lips*—due to paralysis of buccinator muscle.

N.B. In upper motor neuron type paralysis of facial muscles due to involvement of the pyramidal tract, the upper part of the face is not affected. This part of face remains normal because lower motor neurons supplying this part of face receive corticonuclear fibres (upper motor neurons) from cerebral cortex of the both sides (bilateral cortical innervation; for detail see Chapter 22).

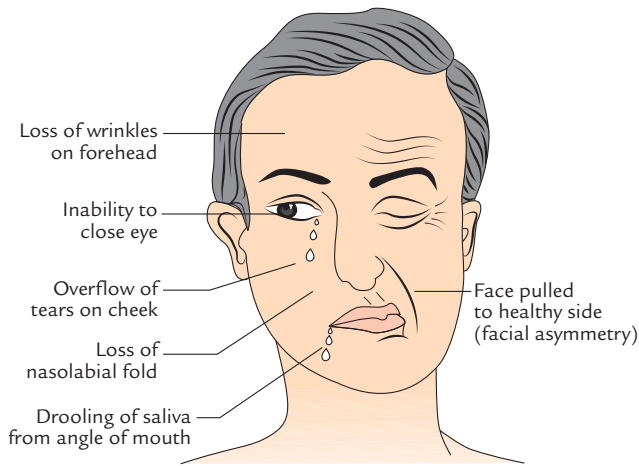


Fig. 3.14 Bell's palsy on the right side. Note the facial asymmetry (right side appears to be pulled on the left side).

Table 3.4 Innervation of muscles of facial expression by the terminal branches of facial nerve

Terminal branches of facial nerve	Muscles innervated
Temporal branch	<ul style="list-style-type: none"> • Upper part of the orbicularis oculi • Frontalis • Corrugator supercilii
Zygomatic branch	Lower part of the orbicularis oculi
Buccal branches	<ul style="list-style-type: none"> • Zygomaticus major and minor • Levator anguli oris • Levator labii superioris • Levator labii superioris alaeque nasi • Muscles of the nose
(a) upper buccal branch	
(b) lower buccal branch	<ul style="list-style-type: none"> • Buccinator • Orbicularis oris
Marginal mandibular branch	<ul style="list-style-type: none"> • Risorius • Depressor anguli oris • Depressor labii inferioris • Mentalis
Cervical branch	Platysma

Sensory Nerve Supply

The **trigeminal nerve** is the sensory nerve of the face because it supplies the whole of the face, except skin over the angle of mandible, which is supplied by great auricular nerve derived from ventral rami of the 2nd and 3rd cervical nerves (C2, C3).

The upper one-third face (developing from frontonasal process) is supplied by ophthalmic division, middle third of face (developing from maxillary processes) is supplied by maxillary division and lower third of face (developing from mandibular processes) is supplied by mandibular division of the trigeminal nerve.

The territories of cutaneous innervation of ophthalmic, maxillary, and mandibular nerves are not horizontal, but curved in the posterosuperior direction, indicating the direction of growth of brain and head (Fig. 3.15). Thus the original beard area has been drawn up to the temple and necessarily the neck skin is drawn up to overlap the angle of the mandible. This explains the innervation of face by the 2nd cervical nerve (C2).

The cutaneous nerves of the face derived from three divisions of the trigeminal nerve are as follows (Fig. 3.16):

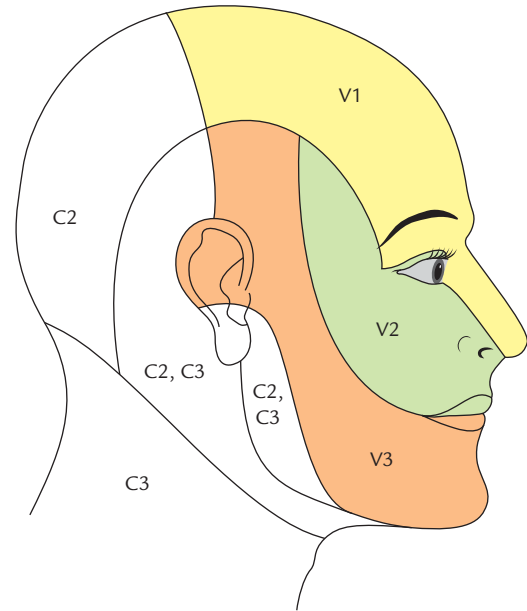


Fig. 3.15 Sensory innervation of the face. Note trigeminal and spinal fields (V1 = ophthalmic division of trigeminal nerve, V2 = maxillary division of trigeminal nerve, V3 = mandibular division of trigeminal nerve).

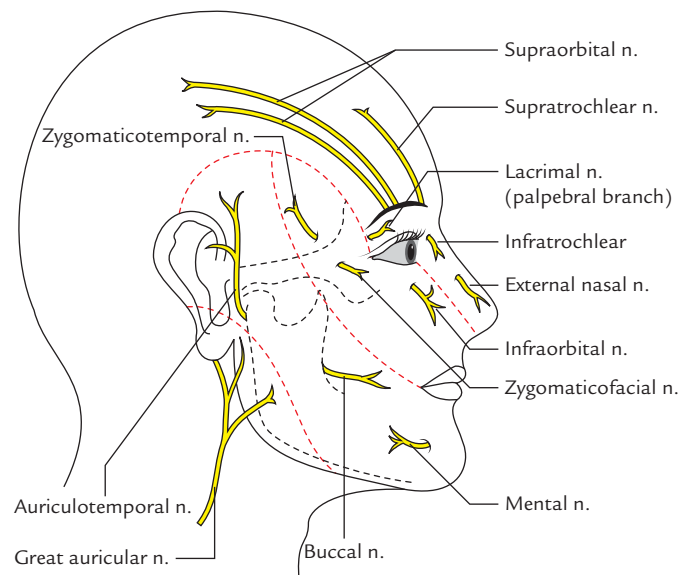


Fig. 3.16 Sensory nerves of the face.

Supraorbital] Branches of ophthalmic division of trigeminal nerve
Supratrochlear	
Infratrochlear	
External nasal	
Lacrimal	
Infraorbital] Branches of maxillary division of trigeminal nerve
Zygomatofacial	
Zygomatotemporal	
Mental] Branches of mandibular division of trigeminal nerve
Buccal	
Auriculo-temporal	

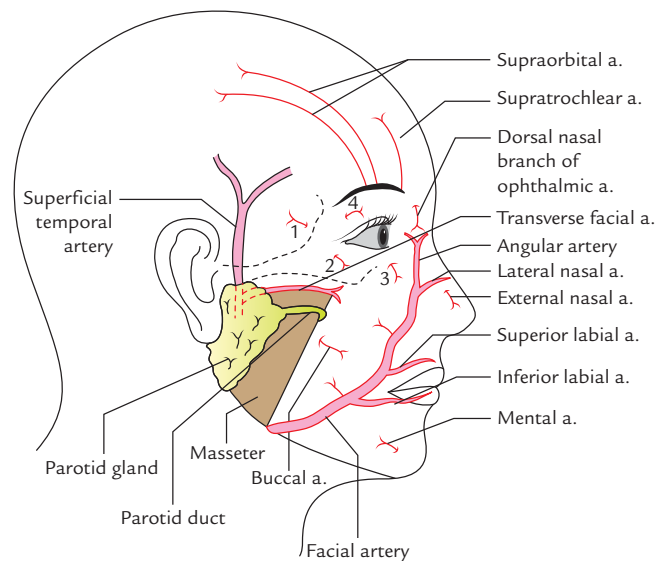


Fig. 3.17 Arterial supply of the face (1 = zygomaticotemporal, 2 = zygomaticofacial, 3 = infraorbital, 4 = palpebral branch of lacrimal artery).

Clinical correlation

- **Trigeminal neuralgia (tic douloureux):** It is a clinical condition characterized by sudden paroxysmal attacks of lancinating pain lasting from few hours to several days, confined to distribution of one or more divisions of trigeminal nerve. It commonly starts in the maxillary territory and more frequently on the right side.
- **Herpes zoster ophthalmicus:** It is a viral infection involving the ophthalmic nerve. It presents as severe pain and edema in the ophthalmic territory and is characterized by the appearance of vesicles along the course of cutaneous branches of the ophthalmic nerve.

ARTERIAL SUPPLY

The face is the highly vascular region and is supplied by the following arteries (Fig. 3.17):

1. Facial artery.
2. Transverse facial artery.
3. Arteries that accompany the cutaneous nerves.

The main arterial supply to the face is by the *facial artery*, hence it is called **chief artery of the face**.

Facial Artery

It arises from external carotid artery in the neck at the level of greater cornu of the hyoid bone, and after a looped course in the submandibular region, it enters the face by winding around the lower border of the mandible at the anteroinferior angle of the masseter by piercing the investing layer of deep cervical fascia.

In the face, the artery passes tortuously, first upwards and forwards to a point 1.25 cm lateral to the angle of the mouth and then ascends along the side of the nose to the medial angle of the eye where it ends by anastomosing with the *dorsal nasal branch of ophthalmic artery*. The terminal part of facial artery is called **angular artery**.

The course and branches of facial artery in the neck is described in Chapter 16.

Branches of the Facial Artery in the Face

In the face it gives three sets of named branches, *viz.*

1. **Inferior labial artery**, to supply the lower lip.
2. **Superior labial artery**, to supply the upper lip.
3. **Lateral nasal artery**, to supply the ala and dorsum of the nose. All these branches arise anteriorly.
4. **Muscular branches**, are small, unnamed and arise from the posterior aspect of the artery.

N.B.

- The *tortuosity of facial artery* prevents its walls from being unduly stretched during the movements of mandible, lips, and cheeks.
- The facial artery takes part in the formation of numerous anastomoses, *viz.*
 - Across the midline with the branches of the opposite side. In the lips, the anastomoses between the superior and inferior labial arteries of two sides are large and so efficient that if cut blood spurts from both cut ends.
 - At the medial angle of eye, it anastomoses with the branches of ophthalmic artery, a branch of internal carotid artery and hence the site of anastomosis between the branches of external and internal carotid arteries.

Clinical correlation

- Since the face is richly vascular, the wounds of face bleed profusely but fortunately they heal quickly.
- The **pulsations of facial artery** can be felt at two sites, *viz.*
 - At the base of the mandible close to anteroinferior angle of the masseter.
 - About 1.25 cm lateral to the angle of the mouth.

Transverse Facial Artery

It is a small artery that arises from superficial temporal artery, within the parotid gland. After emerging from parotid gland it runs forwards on the masseter between the zygomatic arch and the parotid duct accompanied by buccal branch of the facial nerve.

Arteries Accompanying the Cutaneous Nerves

They are small and usually go unnoticed but some of them can be easily seen, *viz.* infraorbital artery, buccal artery, and mental artery. Note, they all are derived from maxillary artery.

VENOUS DRAINAGE (Fig. 3.18)

The venous blood from the face is drained by two veins (Fig. 3.18), *viz.*

1. Facial vein.
2. Retromandibular vein.

Facial Vein

It is the largest vein of the face. It is formed at the medial angle of the eye by the union of supratrochlear and supraorbital veins. After formation, it runs straight downwards and backwards behind the facial artery to reach the anteroinferior angle of the masseter. Here it pierces the deep fascia, crosses superficial to submandibular gland and joins the anterior division of *retromandibular vein* below the angle of the mandible to form the *common facial vein*, which drains into the internal jugular vein.

The **tributaries** of facial vein correspond to the branches of facial artery.

Deep Connections

The facial vein communicates with the cavernous sinus through the following two routes:

1. **At the point of commencement**, the facial vein communicates with the superior ophthalmic vein, which passes backwards within the orbit and drains into cavernous sinus.
2. **In the cheek**, the facial vein is joined to the pterygoid venous plexus by the *deep facial vein*. The deep facial vein passes backwards over the buccinator deep to the ramus of the mandible and communicates with the *pterygoid venous plexus* around the lateral pterygoid muscle, which in turn communicates with the cavernous sinus through an emissary vein.

Clinical correlation

Dangerous area of the face (Fig. 3.19): The facial vein and its communications are devoid of valves in their lumens. Since facial vein rests directly on the muscles of facial expression, the movements of these muscles may facilitate the spread of septic emboli from infected area of the lower part of the nose, upper lip, and adjoining part of the cheek in retrograde direction through deep facial vein, pterygoid venous plexus, and emissary vein into the cavernous sinus leading to meningitis and cavernous sinus thrombosis. For this reason, this portion of the face is called *dangerous area of the face*.

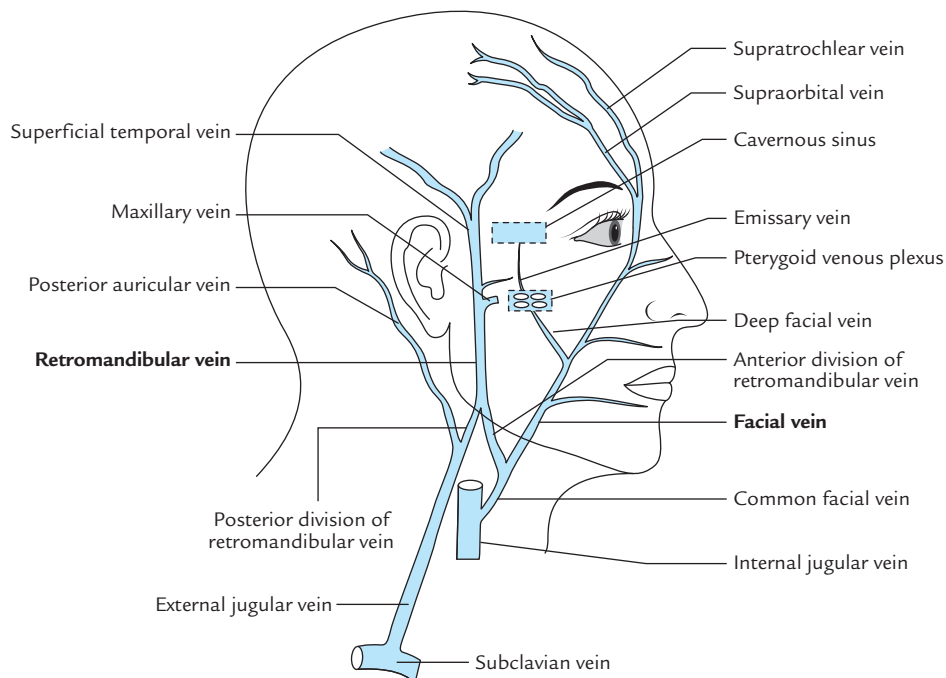


Fig. 3.18 Venous drainage of the face.

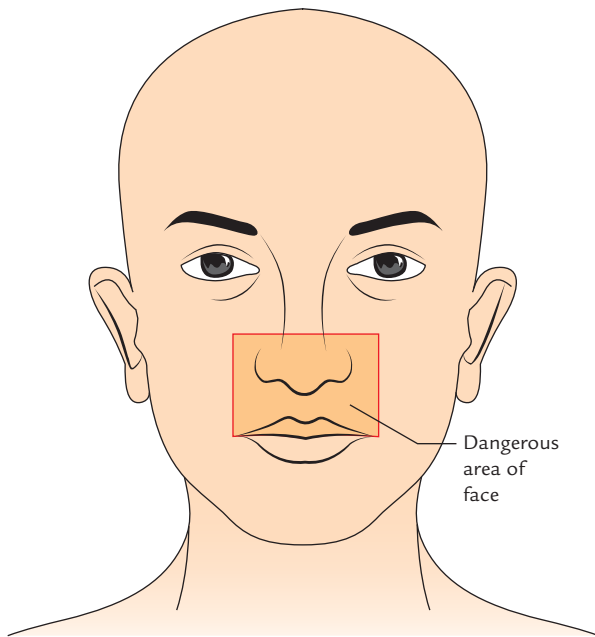


Fig. 3.19 Dangerous area of the face.

Retromandibular Vein

The retromandibular vein is formed by the union of the superficial temporal and the maxillary vein within the parotid gland. On leaving the parotid gland, it divides into two divisions: anterior and posterior. The anterior division joins the facial vein to form the common facial vein, whereas posterior division joins the posterior auricular vein to form the external jugular vein.

LYMPHATIC DRAINAGE (Fig. 3.20)

The face is divided into three lymphatic territories, *viz.*

1. **Upper territory**—comprising greater part of the forehead, lateral halves of the eyelids including conjunctiva, parotid area, and adjoining part of the cheek.
Lymph from upper territory is drained into preauricular lymph nodes (also called superficial parotid lymph nodes).
2. **Middle territory**—comprising central part of the forehead, medial halves of the eyelids, external nose, upper lip, lateral part of lower lip, medial part of cheek, and greater part of the lower jaw.
Lymph from middle territory is drained into submandibular lymph nodes.
3. **Lower territory**—comprising central part of the lower lip and chin.
Lymph from lower territory is drained into submental lymph nodes.

EYELIDS

The eyelids, also called *palpebrae*, are movable curtains in front of the eyeball. They protect the eye from injury, foreign

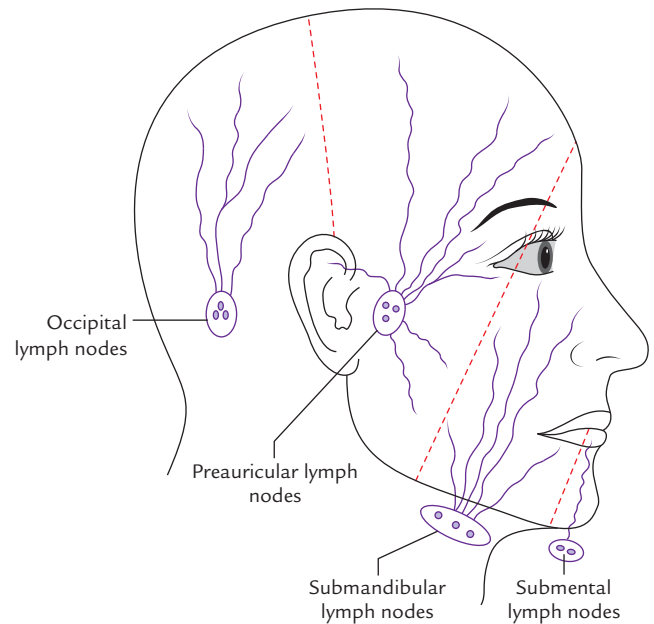


Fig. 3.20 Lymphatic drainage of the scalp and face.

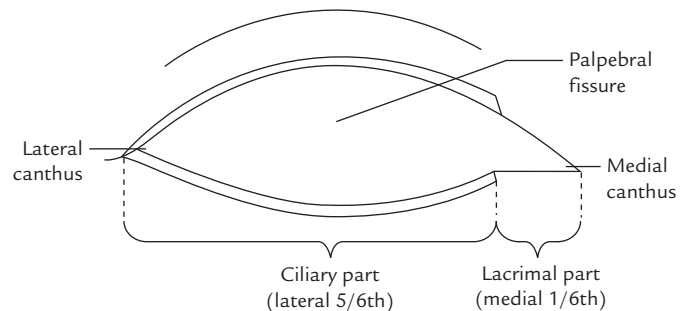


Fig. 3.21 Free margins of the eyelids.

bodies, and bright light. They also keep the cornea moist and clean. The space between the two eyelids is called *palpebral fissure*. The lateral angle of the palpebral fissure where two eyelids meet is called *lateral canthus* of the eye and medial angle of the palpebral fissure where two eyelids meet is called *medial canthus* of the eye.

The free margin of each eyelid is divided into two parts: (a) *Lateral 5/6th ciliary part*, which is flat and possesses eyelashes and (b) *medial 1/6th lacrimal part*, which is round and does not possess cilia (Fig. 3.21).

STRUCTURE

Each eyelid consists of five layers (Fig. 3.22). From without inwards these are:

1. Skin.
2. Superficial fascia.
3. Orbicularis oculi (palpebral fibres).
4. Tarsal plate and palpebral fascia.
5. Conjunctiva.

Skin: The skin of eyelids is very thin and without hair except at the lid margin. At the lid margin, it becomes continuous with the conjunctiva.

Superficial fascia: The superficial fascia of eyelids is thin, loose and devoid of fat. It allows the skin to move freely over the lid, and can become greatly swollen with fluid or blood after injury.

Orbicularis oculi: The fibres of palpebral part of orbicularis oculi sweep across the eyelids parallel to the palpebral fissure. A layer of loose areolar tissue lies deep to these fibres and in the upper eyelid it is continuous with the subaponeurotic space of the scalp.

Tarsal plate and palpebral fascia (Fig. 3.23): The tarsi are two thin plates of condensed fibrous tissue, which form the skeleton of the eyelids and provide them stiffness. The inferior tarsal plate is a narrow strip attached to the inferior orbital margin by palpebral fascia. The superior tarsal plate is much larger and diamond shaped and can be felt if the upper lid is pinched sideways between finger and thumb.

The medial ends of tarsi are attached to lacrimal crest of maxilla in front of lacrimal sac by a strong fibrous band called **medial palpebral ligament** and lateral ends of tarsi to a tubercle of zygomatic bone (Whitnall's tubercle) by **lateral palpebral ligament**.

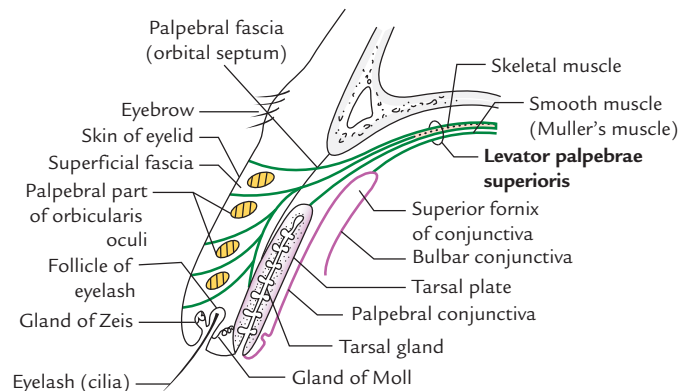


Fig. 3.22 Structure of the eyelid (sagittal section of upper eyelid).

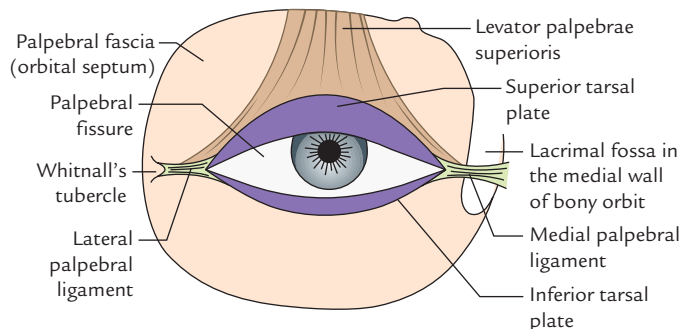


Fig. 3.23 Tarsal plates and palpebral fascia.

The large modified sebaceous glands (**Meibomian or tarsal glands**) are partly embedded on the deeper aspects of the tarsal plates. These glands are arranged in a single row and their ducts open into the lid margin by minute foramina behind the eyelashes.

The **tarsal glands** secrete oily fluid that reduces evaporation of tears and prevent them from overflowing onto the cheek.

The **ciliary glands** are arranged in several rows immediately behind the root of eyelashes. Their ducts open on the lid margin close to the lashes.

The ciliary glands are of two types: (a) **glands of Zeis**, which are modified sebaceous glands and open into the follicles of eyelashes, and (b) **glands of Moll**, which are modified sweat glands. They also open into the follicles of the eyelashes.

The palpebral fascia of upper eyelid is attached above to the superior orbital margin and below to the anterior surface of the tarsal plate some distance away from its upper border.

The **palpebral fascia** is the thin fibrous membrane, which connects the tarsi to the orbital margins and forms the **orbital septum** with them. Medially it passes posterior to the lacrimal sac and attached to the posterior margin of the lacrimal groove, which lodges the lacrimal sac.

The upper palpebral fascia in the upper lid is pierced by:

1. fibres of levator palpebrae superioris,
2. palpebral part of lacrimal gland, and
3. nerves and vessels that pass from orbit to the face.

Conjunctiva (palpebral part): It is a transparent mucus membrane, which lines the inner surface of each eyelid. About 2 mm from the edge of each eyelid the palpebral conjunctiva presents a groove where foreign bodies frequently lodge.

Clinical correlation

- **Ptosis:** It is the drooping of the upper eyelid due to paralysis of levator palpebrae superioris following lesion of oculomotor nerve, which supplies this muscle.
- **Stye (hordeolum):** It is the suppurative inflammation of the Zeis gland. In this condition, the gland is swollen, hard, and painful. The pus points near the base of the cilia, hence can be easily drained by plucking the cilia.
- **Chalazion:** It is the inflammation of the tarsal (Meibomian gland). It causes localized swelling on the inner aspect of the eyelid.
- **Blepharitis:** It is the inflammation of the eyelids mostly involving lid margins.

ARTERIAL SUPPLY

The arterial supply is by medial palpebral branches of ophthalmic artery and lateral palpebral branches of lacrimal artery. These branches form an arterial arch in each eyelid.

VENOUS DRAINAGE

The venous blood from eyelids is drained into ophthalmic and facial veins.

LYMPHATIC DRAINAGE

The lymph from medial halves of lid is drained into submandibular lymph nodes and from lateral halves into the preauricular lymph nodes.

PALPEBRAL FISSURE

When the eye is open, the eyelids are separated by an elliptical fissure called **palpebral fissure**.

Features seen through palpebral fissure (Fig. 3.24)

1. **Lacus lacrimalis**, a small triangular space in the medial part with reddish fleshy looking elevation in its centre called **lacrimal caruncle**.
2. **Plica semilunaris**, a small curved fold of conjunctiva immediately lateral to lacrimal caruncle. It represents nictitating membrane of lower animals.
3. **Cornea and pupil**, present in its center. Note that upper one-seventh of the cornea is overlapped by the upper eyelid.
4. **Sclera of eye ball**, seen as white areas on either side of cornea.

DEVELOPMENT

Above and below the cornea, the eyelids develop as folds of skin, which come together and adhere along their edges during the third month of intrauterine life. The space between the folds and the cornea is the **conjunctival sac**.

When the eyelids separate, the palpebral fissure is established.

The orbital septum develops from mesodermal core in the skin folds. When the eyelids are closed, the orbital septum

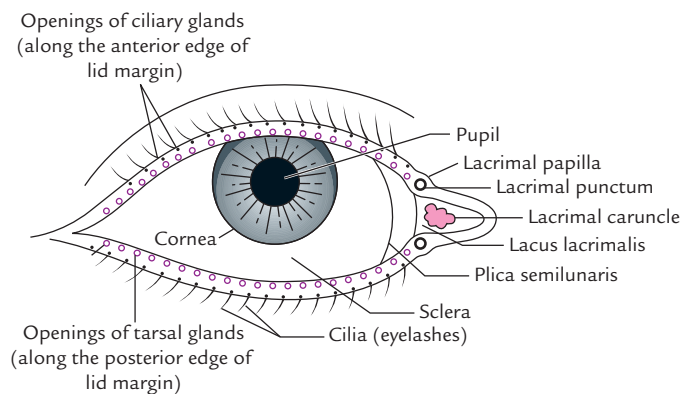


Fig. 3.24 Features of the palpebral fissure.

from orbital margin to the eyelids forms a complete diaphragm of the orbital cavity; the medial part of orbital septum passes behind the lacrimal sac and is attached to the lacrimal bone. This attachment produces sharp **posterior lacrimal crest**.

Clinical correlation

- **Surgical operations on the lacrimal sac**, therefore, are always anterior (outside) to the orbital cavity proper because orbital septum passes behind the lacrimal sac to gain attachment on the posterior lacrimal crest.
- The condensation and thickening of orbital septum within the developing eyelids forms the tarsal plates.

CONJUNCTIVA

The conjunctiva is a thin transparent mucus membrane, which lines the inner surfaces of eyelids (**palpebral conjunctiva**) and the front of sclera and cornea of eyeball (**bulbar conjunctiva**). The potential space between eyelids and eyeball when eyes are closed is called **conjunctival sac**. The lines of reflexion between palpebral and bulbar conjunctiva above and below form the **superior** and **inferior fornices**, respectively.

The palpebral conjunctiva is highly vascular and firmly adherent to the tarsal plates. On the other hand, bulbar conjunctiva is loose over the sclera but firmly adherent to the cornea forming its anterior epithelium (the corneal epithelium). The conjunctiva contains mucus-secreting goblet cells.

Conjunctival Fluid

The conjunctival sac is filled with three films of fluid from within outwards these are:

1. Watery from lacrimal fluids.
2. Mucus from conjunctiva.
3. Oily from tarsal glands.

The blinking movements of eyelids make these films moisten cornea and help drain the conjunctival fluid into nasal cavity.

Clinical correlation

- The inflammation of conjunctiva (**conjunctivitis**) due to infection or allergy is one of the commonest diseases of the eye. **Trachoma** is a granular conjunctivitis caused by trachoma virus. It is contagious and considered as the commonest cause of blindness in India.
- It is usual for physician to examine palpebral conjunctiva for **anemia** and bulbar conjunctiva for **jaundice**.

Nerve Supply

The conjunctiva is supplied by the following nerves:

1. Palpebral conjunctiva of upper eyelid and ocular conjunctiva—by ophthalmic nerve.
2. Palpebral conjunctiva of lower eyelid—by maxillary nerve.

Arterial Supply

The conjunctiva is supplied by palpebral and anterior ciliary arteries derived from ophthalmic artery.

Venous Drainage

The venous blood from palpebral conjunctiva is drained into facial vein while from ocular conjunctiva into ophthalmic veins.

Lymph Drainage

The lymph from conjunctiva is drained into preauricular lymph nodes.

LACRIMAL APPARATUS (Fig. 3.25)

STRUCTURE

The structures concerned with secretion and drainage of lacrimal (tear) fluid together form the *lacrimal apparatus* (Fig. 3.25).

The lacrimal apparatus consists of the following structures:

1. Lacrimal gland.
2. Ducts of lacrimal gland.
3. Conjunctival sac.
4. Lacrimal puncta.

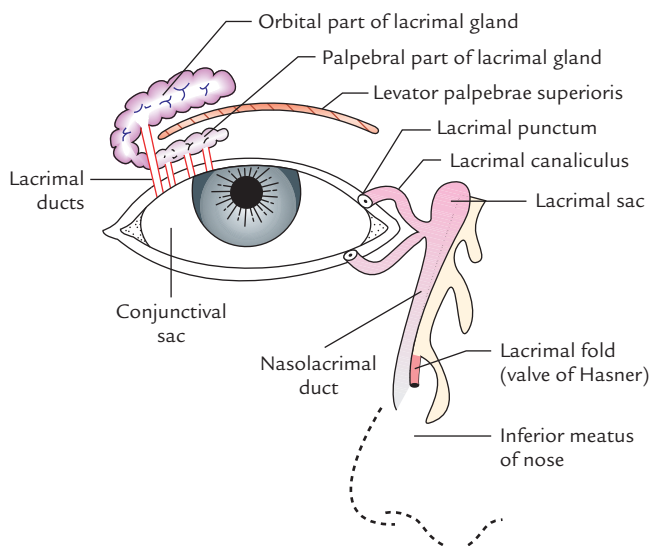


Fig. 3.25 Lacrimal apparatus.

5. Lacrimal canaliculi.
6. Lacrimal sac.
7. Nasolacrimal duct.

Lacrimal gland: The lacrimal gland is a (J-shaped) *serous gland*. It consists of upper large **orbital part** and lower small **palpebral part**. The two parts are continuous with each other around the lateral margin of the levator palpebrae superioris.

The *orbital part* is almond shaped and situated in the lacrimal fossa in the anterolateral part of the roof of the bony orbit.

The *palpebral part* is one-third of the size of the orbital part and is situated in the lateral part of the upper eyelid below the levator palpebrae superioris and extends up to the superior fornix of conjunctiva.

Ducts of the lacrimal gland: The ducts of lacrimal gland are approximately 12 in number, about 4 or 5 from orbital part and 6–8 from palpebrae part. They open into the lateral parts of the superior fornix of the conjunctival sac.

Lacrimal gland secretes the *lacrimal (tear) fluid* and its ducts convey it to conjunctival sac.

About 1 ml of lacrimal fluid is secreted per day. Half of it evaporates and remaining half is drained into lacrimal sac.

Functions of lacrimal fluid

1. Flushes the conjunctiva and keeps the cornea moist.
2. Provides nourishment to cornea.
3. Serves to express emotions—shedding of tears during grief and sorrow.
4. Prevents infection (for it contains bactericidal lysozyme).

Clinical correlation

When lacrimal gland fails to secrete lacrimal fluid as in case of Bell's palsy, the artificial tears are instilled in the eye at regular intervals to prevent the cornea from drying and desiccation.

Ducts from orbital part traverse the palpebral part to open into conjunctival sac. Therefore, removal of palpebral part of gland is functionally equivalent to removal of the entire lacrimal gland.

Accessory lacrimal glands (glands of Krause): These are very small serous glands located beneath the palpebral conjunctiva near the fornices. They are about 35–40 in the upper eyelid and 6–8 in the lower eyelid.

Clinical correlation

The removal of entire lacrimal gland does not lead to dryness of conjunctiva because it is kept moist by the secretions of accessory lacrimal glands.

Arterial supply: It is by lacrimal branch of ophthalmic artery.

Venous drainage: It is by ophthalmic veins.

Nerve supply of lacrimal gland (Fig. 10.25): The lacrimal gland is supplied by parasympathetic (secretomotor), sympathetic, and sensory fibres through lacrimal nerves. The following nerves supply the lacrimal gland:

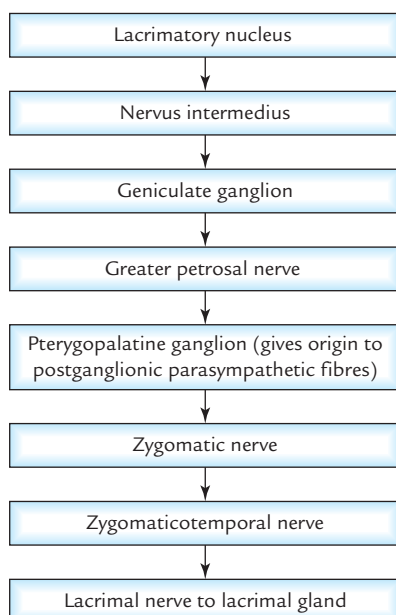
- Parasympathetic (secretomotor) supply of the lacrimal gland:** The pathway of parasympathetic innervation is as follows:
 - The *preganglionic parasympathetic fibres* arise from lacrimatory nucleus in the pons and pass successively through nervus intermedius, geniculate ganglion, greater petrosal nerve, nerve of pterygoid canal to reach the pterygopalatine ganglion where they relay.
 - The *postganglionic fibres* arise from the cells of the pterygopalatine ganglion and pass successively through maxillary nerve, zygomatic nerve, zygomaticotemporal nerve and lacrimal nerve to reach the lacrimal gland.

This parasympathetic pathway is summarized in Flowchart 3.1.

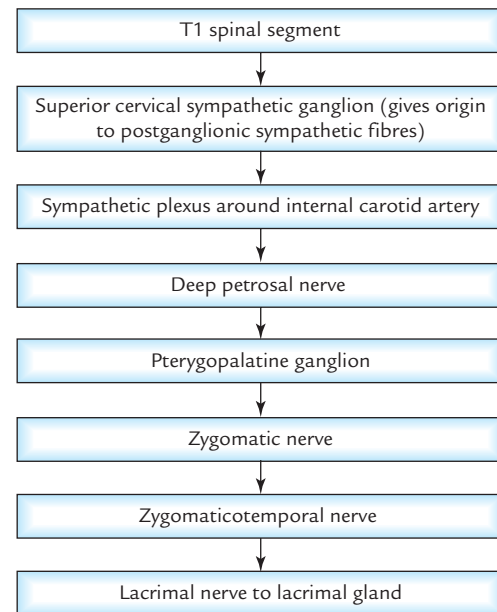
- Sympathetic (vasomotor) supply:** The pathway of sympathetic innervation is as depicted in Flowchart 3.2.
- Sensory supply:** It is by sensory fibres of lacrimal nerve, a branch of ophthalmic division of trigeminal nerve.

Conjunctival sac: It is a potential space between palpebral and bulbar conjunctiva.

Lacrimal puncta: These are small openings on the lid margins.



Flowchart 3.1 Parasympathetic pathway of lacrimal gland.



Flowchart 3.2 Sympathetic pathway of lacrimal gland.

At the junction of these, there is a small conical projection called *lacrimal papilla* surmounted by a tiny aperture called *lacrimal punctum*. The lacrimal papilla faces inwards towards the *lacus lacrimalis*.

Lacrimal canaliculi: There are two lacrimal canaliculi, superior and inferior in upper and lower eyelids, respectively. Each canaliculus measures about 10 mm in length and begins at lacrimal punctum. The superior canaliculus at first runs upwards and then bends downwards and medially along the free margin of the eyelid to open into the lacrimal sac.

The *inferior canaliculus* at first runs downwards and then bends upwards and medially to open into the lacrimal sac. At the bending each canaliculus presents a small dilatation called *ampulla*.

N.B.

- Both canaliculi converge medially towards the lacrimal sac into which they open separately but sometimes by a common dilated stem.
- Canaliculi lie behind the medial palpebral ligament.
- Canaliculi are lined by stratified squamous epithelium and contain elastic fibres in their walls, which make them dilatable by the probe.
- A few muscle fibres derived from lacrimal part of orbicularis oculi are arranged circularly around the base of the lacrimal papilla and exert sphincteric action.

Lacrimal sac: It is the upper dilated end of the nasolacrimal duct. It is situated in the deep lacrimal groove bound by posterior lacrimal crest of lacrimal bone and anterior lacrimal crest of frontal process of the maxilla. The sac is

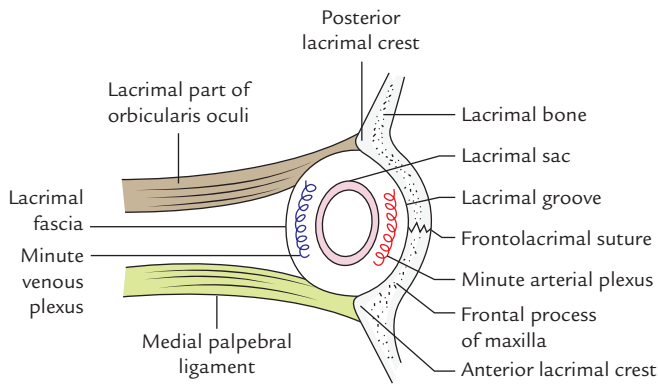


Fig. 3.26 Relations of the lacrimal sac.

enclosed in the lacrimal fascia; when distended the lacrimal sac is about 15 mm long and 5–6 mm in breadth. It is divisible into three parts: fundus, body, and neck from above downwards. The narrow neck becomes continuous with nasolacrimal duct.

Relations (Fig. 3.26):

Anteriorly: Medial palpebral ligament.

Posteriorly: Lacrimal part of orbicularis oculi (which arises from crest of lacrimal bone and from lacrimal fascia).

Laterally: Lacrimal fascia, which is derived from orbital periosteum and minute plexus of veins.

Medially: Lacrimal groove and minute arterial plexus.

Nasolacrimal duct: It is a membranous canal, about 18 mm long, extending from neck of lacrimal sac to the anterior part of inferior meatus of the nose. It is lodged in the bony canal formed by maxilla, lacrimal bone, and inferior nasal concha. Its lower opening presents an incomplete mucous fold called *lacrimal fold* or *valve of Hasner*, which prevents the air from

blowing the duct into the eye when one blasts his nose to clean nasal secretions.

Factors Helping the Drainage of Tears

Drainage of tears occurs by following means:

1. Blinking movements of eyelids.
2. Capillary action of the film of the fluid.
3. Contraction of lacrimal part of orbicularis oculi leading to distension of lacrimal sac.

DEVELOPMENT OF NASOLACRIMAL DUCT AND LACRIMAL SAC

The nasolacrimal duct develops from a solid cellular **ectodermal cord**, which forms along the nasolacrimal groove, the line of fusion of maxillary and lateral nasal processes. Later, the cord become submerged beneath the surface ectoderm and becomes canalized during the third month to form the nasolacrimal duct. The upper end of the duct widens to form the lacrimal sac, which develops secondary connection with the conjunctival sac by lacrimal canaliculi.

Clinical correlation

Epiphora: It is an overflow of tears from conjunctival sac over the cheeks. It may occur due to:

- (a) excessive secretion of tears (*hyperlacrimation*) following intake of spicy food or emotional outbreak, or
- (b) obstruction in lacrimal passages, viz. lacrimal punctum, lacrimal canaliculi, lacrimal sac and nasolacrimal duct, or
- (c) eversion of lower eyelid (*ectropion*), hence that of lacrimal papilla and lacrimal punctum due to laxity of orbiculi oculi in old age or loss of its tone due to paralysis.

Golden Facts to Remember

▶ Most obvious feature of the scalp	Galea aponeurotica (epicranial aponeurosis)
▶ Richest cutaneous blood supply in the body	In the region of scalp
▶ Most important layer of the scalp from clinical point of view	Fourth layer (i.e., layer of loose areolar tissue)
▶ Dangerous layer of the scalp	Layer of loose areolar tissue (4th layer)
▶ Most common form of birth trauma of the scalp	Caput succedaneum
▶ Toughest fascia in the body	Temporal fascia
▶ Sensory supply of whole face is by trigeminal nerve <i>except</i>	Skin over the angle of the mandible which is supplied by great auricular nerves (C2, C3)
▶ Chief artery of the face	Facial artery
▶ Largest vein of the face	Facial vein
▶ Muscle of the body with largest name	Levator labii superioris alaeque nasi

Clinical Case Study



A 55-year-old school teacher went to his family physician and complained that since morning he has not been able to close his right eye and during eating the food accumulates between the teeth and cheek on the right side. He is also not able to whistle or puff out his cheek properly.

On examination, the physician made the following observations:

- The right side of face appeared flattened and expressionless.
- Loss of wrinkles on the forehead on the right side.
- Saliva drooled out from the right corner of the mouth.
- When patient smiled, the lower portion of right half of the face was pulled to the left side and right corner of the face was not raised.

Based on above observation he concluded that all the muscles of facial expression on the right side of teacher's face are paralysed and he diagnosed him as a case of Bell's palsy.

Questions

1. What are the characteristic features of muscles of facial expression?

2. What is Bell's palsy? Mention its most common cause.
3. What is difference between upper and lower motor neuron type of facial palsies?

Answers

1. They are located in the superficial fascia and inserted into the skin of the face. All of them are supplied by the facial nerve.
2. It is lower motor neuron (LMN) type of facial palsy. The exact cause is not known but most probably it occurs due to compression of facial nerve in the facial canal just above the stylomastoid foramen following an inflammation.
3. In lower motor neuron facial palsy whole of the face on the side of lesion is paralyzed whereas in upper motor neuron facial palsy the upper part of face is not affected and only lower half of the face on the opposite side is paralyzed.

Skin, Superficial Fascia, and Deep Fascia of the Neck

The knowledge of skin, superficial fascia, and deep fascia of the neck is extremely important. The lines of cleavage in skin help to plan the direction of surgical incisions. The structures within superficial fascia help in closing the surgical incisions and stop profuse bleeding. The deep fascia forms fascial compartments and spaces in the neck. It also forms fascial planes along which infection can travel from one place to the other. The superficial veins in the neck are often examined to assess the state of health.

SKIN

The skin in the region of neck is thin and normally under tension. The direction of tension lines (also called *cleavage lines* or *Langer's lines*) often correspond with the wrinkle lines. The cleavage (*Langer's*) lines are disposed transversely around the neck. Therefore, surgical incisions made along these lines, i.e., transverse incisions, in neck heal with invisible scars.

CUTANEOUS INNERVATION (Fig. 4.1)

The cutaneous innervation of the neck is derived from C2, C3, and C4 spinal segments.

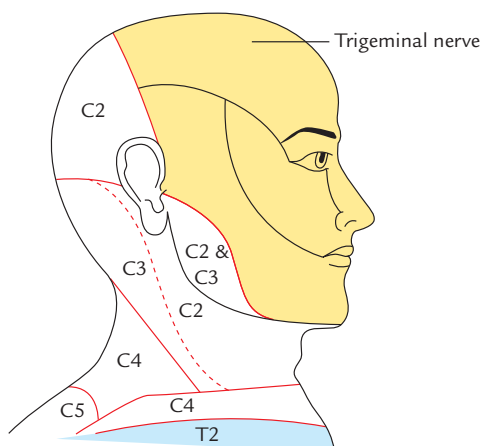


Fig. 4.1 Dermatomes of the head and neck.

The 1st cervical (C1) nerve has no cutaneous branch and ventral rami of C5–T1 form the brachial plexus to supply the upper limb. The skin above the C2 dermatome is supplied by trigeminal nerve and the skin below the C4 dermatome is supplied by T2 spinal segment (Fig. 4.1).

The skin on the anterolateral aspect of the neck is supplied by four cutaneous nerves derived from ventral rami of C2, C3, and C4 spinal nerves. The skin on the posterior aspect of the neck is supplied by dorsal rami of C2, C3, and C4 spinal nerves.

SUPERFICIAL FASCIA

The superficial fascia of the neck consists of a thin layer of loose areolar tissue and contains a thin sheet of muscle called **platysma**.

In addition to platysma, it also contains cutaneous nerves, superficial veins, superficial lymph nodes, and lymph vessels. *The cutaneous nerves and veins lie deep to the platysma.*

The amount of subcutaneous fat is more in children and women than men.

PLATYSMA (Fig. 4.2)

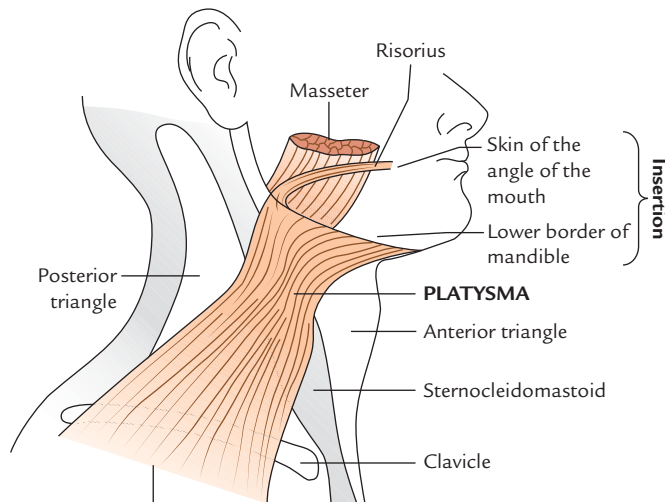
It is a thin quadrilateral broad sheet of muscle in the superficial fascia of the side of the neck. It ascends onto the face from the front of the neck. Morphologically it represents the remnant of **panniculus carnosus** of animals. It develops from the 2nd pharyngeal arch. It covers the anteroinferior part of the posterior triangle and superior part of the anterior triangle of the neck.

Origin

The platysma arises from skin and deep fascia covering the upper parts of the pectoralis major and anterior part of the deltoid muscle.

Insertion

After origin, the fibres sweep upwards and forwards superficial to the clavicle and sternocleidomastoid. It crosses



Skin and deep fascia covering the upper part of pectoralis major and anterior part of deltoid muscle (**origin**)

Fig. 4.2 Origin and insertion of the platysma.

over the lower part of the posterior triangle and upper part of the anterior triangle to reach the lower border of the mandible, where anterior fibres decussate with the corresponding fibres of the opposite side across the midline for about 2.5 cm below and behind the symphysis menti (Fig. 4.3). Most of the fibres (intermediate and posterior) are inserted into the lower border of the body of the mandible. Some posterior fibres pass superficial to the angle of the mandible and masseter muscle and then turn medially to insert into the skin of angle of the mouth through risorius.

Nerve Supply

The platysma is supplied by the cervical branch of the facial nerve.

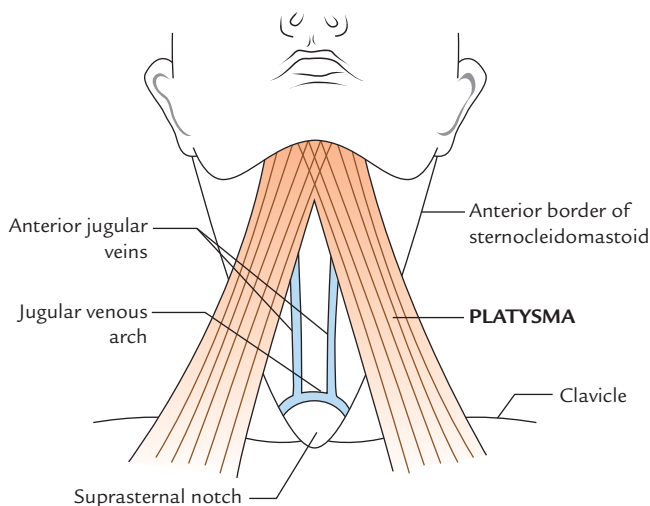


Fig. 4.3 Decussation of the anterior fibres of platysma. Also note the location of anterior jugular veins and jugular venous arch.

Actions

1. **Acting from above**, the platysma produces vertical ridges in the skin of the neck releasing the pressure of skin over the underlying veins and thus helps in the venous return. It, therefore, serves to ease the pressure of tight collar.
2. **Acting from below**, it helps to depress the mandible and draws the angle of the mouth downwards and laterally as in expression of terror/horror.

N.B. Though the risorius appears to be a continuation of platysma, it has a different nerve supply, namely, the buccal branch of facial nerve.

Clinical correlation

The surgeons while closing an incision in the neck, suture platysma meticulously as a separate layer to prevent adhesion of skin and subcutaneous tissue to deeper neck muscles because such adhesions cause the overlying skin to move as the deeper muscles contract or relax and the wound will heal with an ugly scar, which is cosmetically unacceptable.

Since the superficial veins of the neck lie under the cover of platysma, the retraction of divided platysma keeps the cut veins open. These veins are unable to retract due to their attachment to the deep cervical fascia. However, if deep fascia is cut, the veins retract and most of the bleeding stops.

CUTANEOUS NERVES OF THE NECK (Fig. 4.4)

The skin on the back of the neck is supplied segmentally by cutaneous nerves, derived from dorsal rami of C2, C3, and

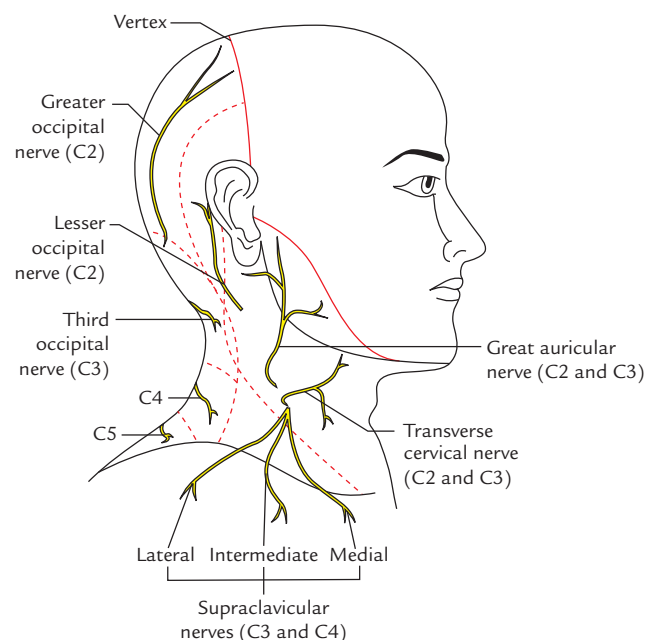


Fig. 4.4 Cutaneous nerves of the neck.

C4 spinal nerves (Fig. 4.4). The cutaneous nerves of the back of the neck are described in Chapter 7.

The skin on the front and side of the neck on each side is supplied by four cutaneous nerves derived from ventral rami of C2 to C4 spinal nerves through branches of the cervical plexus.

They are named as follows:

1. Lesser occipital nerve (C2).
2. Great auricular nerve (C2 and C3).
3. Transverse cervical nerve (C2 and C3).
4. Supraclavicular nerves (C3 and C4).

The course and distribution of these nerves is described in Chapter 5.

SUPERFICIAL VEINS OF THE NECK

There are two superficial veins of the neck. These are as follows:

1. External jugular vein.
2. Anterior jugular vein.

External jugular vein It begins just below the angle of the mandible by the union of posterior division of retromandibular vein and posterior auricular vein. It then runs almost vertically downward across the sternocleidomastoid under the cover of platysma to pierce the deep cervical fascia in the anteroinferior angle of the posterior triangle about 2.5 cm above the clavicle along the posterior border of the sternocleidomastoid and enters the supraclavicular space. After passing through this space it terminates in the subclavian vein. The external jugular vein varies considerably in its size and course. It becomes visible in old age particularly when the individual holds his breath or blows his cheek with mouth closed, as it impedes the venous return to the right side of the heart and distends the vein.

Surface anatomy: The external jugular vein can be marked on the surface by a line extending downward and backward from angle of the mandible to the middle of the clavicle.

Its **tributaries** (Fig. 4.5) are as follows:

- | | |
|------------------------------------|-------------------------|
| 1. Posterior auricular vein | } Formative tributaries |
| 2. Retromandibular vein | |
| 3. Posterior external jugular vein | |
| 4. Oblique jugular vein | } Terminal tributaries |
| 5. Transverse cervical vein | |
| 6. Suprascapular vein | |
| 7. Anterior jugular vein | |

N.B. The posterior auricular vein descends behind the auricle to join the posterior division of retromandibular vein. Posterior external jugular vein descends along the posterior border of sternocleidomastoid to join the

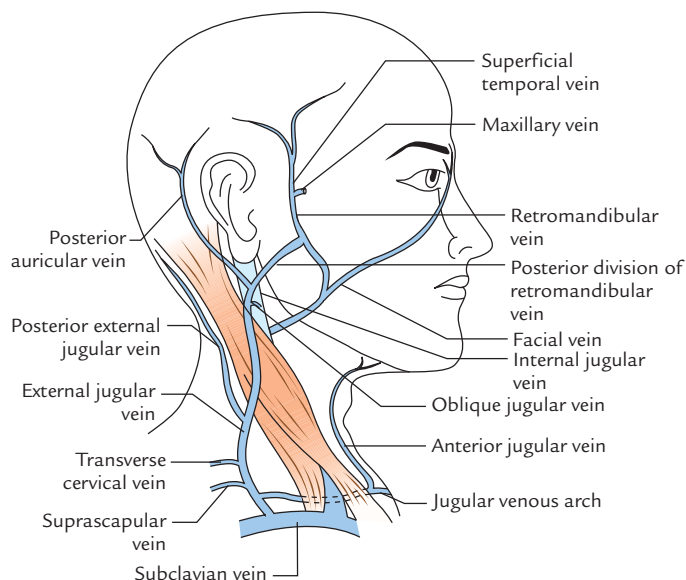


Fig. 4.5 Superficial veins of the neck.

external jugular vein a little below the midpoint of posterior border of the muscle. The oblique jugular vein communicates with the internal jugular vein in the upper part of the neck. The suprascapular, transverse cervical, and anterior jugular veins join the external jugular vein in the posterior triangle.

There are two pairs of valves in the lumen of the external jugular vein, one at its site of termination into the subclavian vein and the other about 4 cm above the clavicle. These valves, however, do not prevent regurgitation of blood.

Clinical correlation

- The wall of the external jugular vein is adherent to deep fascia where it pierces the deep fascia (about 2.5 cm above the clavicle). Therefore, if external jugular vein is cut at this site, its walls cannot collapse. Consequently, air is sucked into its lumen due to negative intrathoracic pressure during inspiration leading to **venous air embolism** which may cause death subsequently.
- The external jugular vein is occasionally used for **central venous cannulation**, but due to its variable size and presence of valves it is often difficult to manipulate the cannula through the lower part of the vein. The right external jugular vein being in the most direct line with the superior vena cava, is the one most commonly used.
- The external jugular vein is often examined by clinicians to assess the **venous pressure** in the right atrium. Normally, in recumbent (lying down) position, the lower one-third of the vein becomes filled with blood but it collapses on reclining at 45° angle. However, if it remains full even when the patient reclines at 45° angle, it suggests increased right atrial pressure often seen in congestive cardiac failure.

Anterior jugular vein It begins below the chin in the submental region by the union of small unnamed veins from the chin. It descends in the superficial fascia about 1 cm lateral to the midline. At about 2.5 cm above the suprasternal notch, it pierces the investing layer of deep cervical fascia to enter the **suprasternal space (of Burns)**, where it turns sharply laterally and passes deep to sternocleidomastoid and terminates in the external jugular vein. In the suprasternal space, the anterior jugular vein is united across the midline to its fellow of opposite side by a transverse venous channel called **jugular venous arch**.

SUPERFICIAL LYMPH NODES AND LYMPH VESSELS

The superficial cervical lymph nodes (Fig. 4.6) are situated around the junction of the head with the neck. They drain all the superficial structures and some deep structures of the head. Most of the efferent lymph vessels from these lymph nodes pass to deep cervical lymph nodes arranged along the internal jugular vein. A few scattered superficial nodes are found along the external and anterior jugular veins. They also drain into deep cervical lymph nodes.

The superficial cervical lymph nodes situated around the junction of head and neck to form *pericervical/cervical collar*. They are arranged into the following groups:

1. Submental nodes.
2. Submandibular nodes.
3. Superficial parotid (preauricular) nodes.
4. Retroauricular nodes.
5. Occipital nodes.

Submental nodes Three or four in number, the **submental nodes** lie on mylohyoid muscle below the symphysis menti (chin) and receive the lymph from the tip of the tongue, lower lip, and chin.

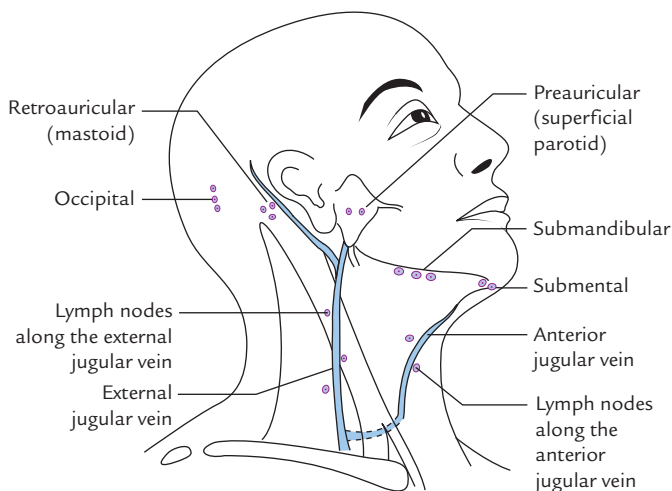


Fig. 4.6 Superficial cervical lymph nodes.

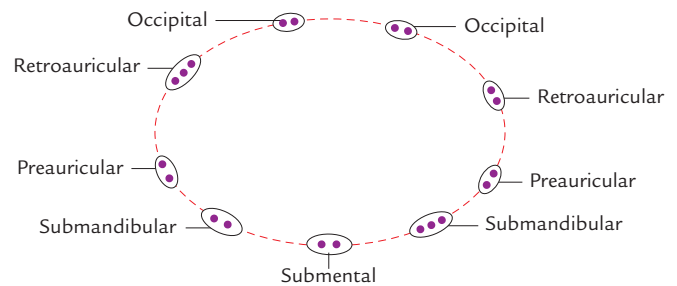


Fig. 4.7 Ring of superficial cervical lymph nodes at the junction of the head and neck.

Submandibular nodes The submandibular nodes, about half a dozen in number, lie on the surface of the submandibular gland and receive the lymph from the face, cheek, nose, upper lip, gums, and tongue.

Parotid (preauricular) nodes

The preauricular nodes lie superficial to parotid fascia and drain the lymph from the scalp, auricle, eyelids, and cheeks.

Mastoid (postauricular) nodes One or two in number, the retroauricular nodes lie on the mastoid process and drain the lymph from the scalp and auricle.

Occipital nodes One or two in number, the occipital nodes lie on trapezius about 2.5 cm inferolateral to the inion and drain the lymph from the scalp. They are notable for being palpable in **German measles**.

These groups form a kind of ring of lymph nodes at the junction of the head and neck and may appropriately be called **necklace of lymph nodes at the craniocervical junction** (Fig. 4.7). The lymph nodes of pericervical collar are clinically palpable only when enlarged.

DEEP CERVICAL FASCIA (FASCIA COLLI)

The deep cervical fascia of the neck (Figs 4.8 and 4.9) is clinically very important as it forms various fascial spaces in the neck. It also provides capsules to the glands and invests the muscles in the region. In addition, it forms protective sheaths around neurovascular structures. The layers of deep cervical fascia form fascial planes to direct the spread of infection or pus in the neck.

The deep cervical fascia of the neck consists of three layers. From outside inwards these are as follows:

1. Investing layer of deep cervical fascia.
2. Pretracheal fascia.
3. Prevertebral fascia.

The spaces among the structures of the neck are filled with loose areolar tissue. The structures of the neck are mostly destined to move up and down. The layers of deep cervical fascia are no more than the laminar condensation of

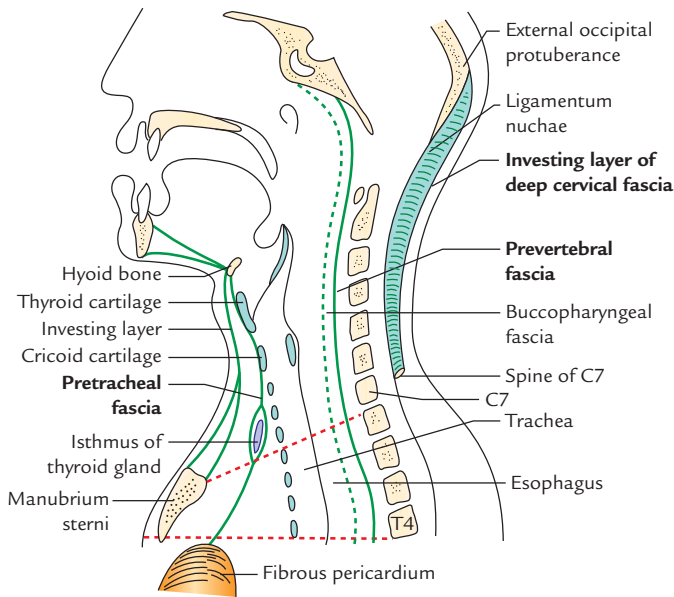


Fig. 4.8 Vertical extent (disposition) of the three layers of the deep cervical fascia. Buccopharyngeal fascia is also shown. Note the continuity of fascial spaces of the neck into the mediastinum.

loose areolar tissue produced by the movements of these structures.

These laminar condensations take different names in different regions and are continuous with each other either directly or indirectly through loose areolar tissue.

The loose areolar tissue forms fascial sheets or laminae in the same way as unwoven cotton forms sheets of cloth after spinning.

These laminae ensheath muscles and other moving structures. This permits movement between the sheaths and movements of structures within them.

Investing fascia This layer encircles the neck like a collar, deep to platysma and superficial fascia. In doing so it encloses the sternocleidomastoid and trapezius—the two large superficial muscles on either side of the neck.

Attachments

1. **Superiorly** it is attached to external occipital protuberance, superior nuchal line, mastoid process, and lower border of mandible from behind forwards.
2. **Inferiorly** it is attached to the spine of scapula, acromion process, upper aspect of clavicle, and jugular notch of manubrium sterni from behind forwards.
3. **Anteriorly** across the midline, it becomes continuous with its counter part of the other side. In the anterior midline it is attached to symphysis menti, hyoid bone jugular notch from above downwards.
4. **Posteriorly** it is attached to ligamentum nuchae and spine of 7th cervical vertebra.

Tracing of the investing layer

Vertical tracing: When traced upwards above the hyoid bone, it splits to enclose the submandibular salivary gland (Fig. 4.10). The superficial layer covers the superficial surface of the gland and it is attached to the lower border of the body of the mandible. The deep layer covers the medial surface of the gland and is attached to the mylohyoid line of the mandible. Posterior to the submandibular gland, at the lower pole of the parotid gland, it splits to enclose this gland also (Fig. 4.10).

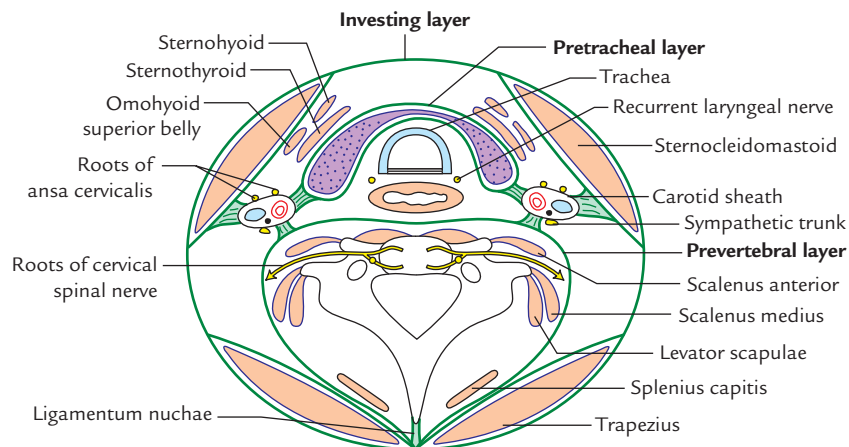


Fig. 4.9 Diagrammatic transverse section through neck at the level of the 6th cervical vertebra to show the horizontal disposition of the three layers of deep cervical fascia.

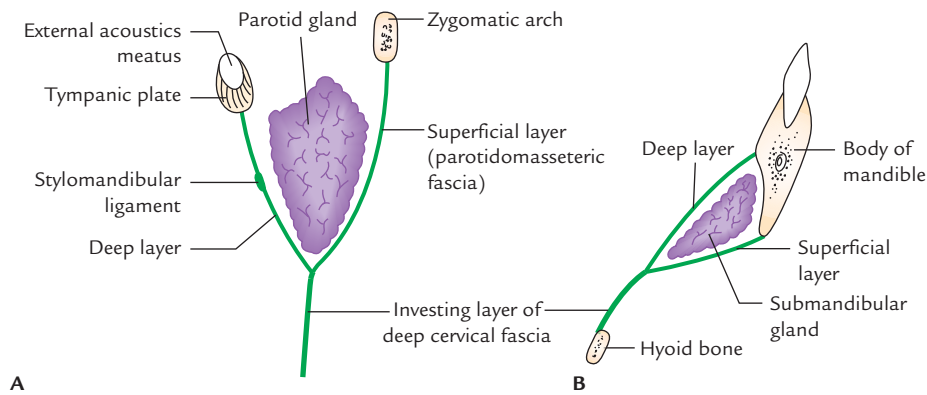


Fig. 4.10 Investing layer of the deep cervical fascia enclosing two glands: **A**, parotid gland; **B**, submandibular gland.

The superficial layer is strong and covers the superficial surface of the parotid gland as **parotidomasseteric fascia** to get attached to the lower border of the zygomatic arch. The deeper layer passes deep to the parotid gland to get attached to the lower border of the tympanic plate and styloid process of the temporal bone. The part of this layer stretching between the styloid process and the angle of mandible condenses to form the **stylomandibular ligament** which separates the parotid gland from submandibular gland.

When traced downwards, the fascia splits twice to enclose two spaces:

Above the suprasternal notch, it splits into two layers to enclose **suprasternal space (of Burns)** before being attached to the anterior and posterior borders of the suprasternal notch.

The *suprasternal space* contains:

- sternal heads of sternocleidomastoid muscles,
- jugular venous arch,
- interclavicular ligament, and
- lymph node (sometimes).

Above the middle third of clavicle, it splits into two layers to enclose the **supraclavicular space** (Fig. 4.11). The anterior and posterior layers get attached to the anterior and posterior borders of the upper surface of the clavicle. The posterior layer encloses the inferior belly of omohyoid and after being attached to clavicle it becomes continuous with the posterior layer of **clavipectoral fascia**.

The *supraclavicular space* contains:

- terminal part of the external jugular vein, and
- supraclavicular nerves before they become cutaneous.

The investing layer also forms fascial pulleys to anchor the tendons of the digastric and omohyoid muscles.

Horizontal tracing: When traced forwards from its attachment to ligament nuchae, it first splits to enclose the

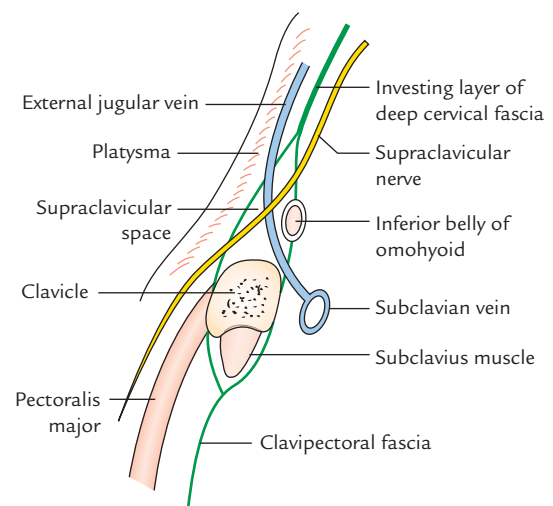


Fig. 4.11 Investing layer of the deep cervical fascia enclosing supraclavicular space.

trapezius, then forms the roof of the posterior triangle, then again splits to enclose the sternocleidomastoid, and finally forms the roof of the anterior triangle.

N.B. 'Rule of 2'. When summed up, it is noted that investing layer of deep cervical fascia presents everything in '2', for example it

- encloses 2 muscles, trapezius and sternocleidomastoid.
- forms roofs of 2 triangles, anterior and posterior triangles.
- splits to enclose 2 glands, submandibular and parotid.
- splits to enclose 2 spaces, suprasternal and supraclavicular.
- forms 2 fascial slings (pulleys) for inferior belly of omohyoid and intermediate tendon of digastric muscle.

Pretracheal fascia This layer of deep cervical fascia covers the front and sides of trachea, hence its name—*pretracheal fascia*. It splits to enclose the thyroid gland forming its capsule and is attached to the oblique line of thyroid cartilage

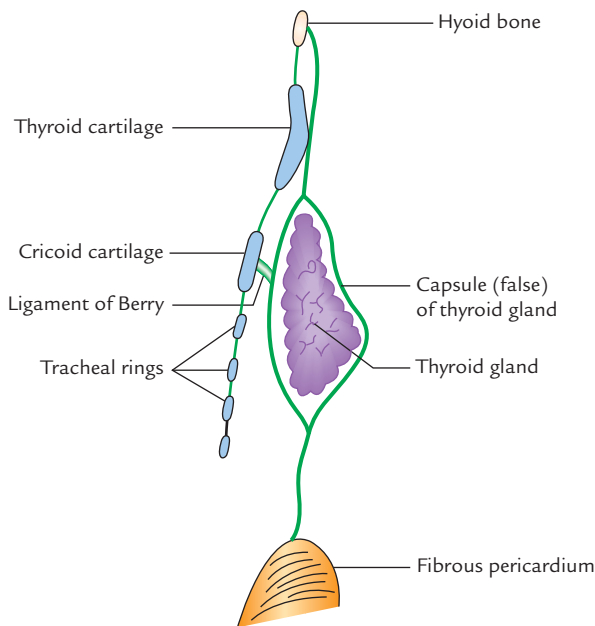


Fig. 4.12 Vertical disposition of pretracheal fascia enclosing thyroid gland.

and to the arch of cricoid cartilage anteriorly. A fibrous band called **ligament of Berry** is derived from this fascia and connects the capsule of the lateral lobe of the thyroid gland to the cricoid cartilage (Fig. 4.12).

Tracing of the pretracheal fascia

Horizontal tracing: When traced horizontally, it merges with the investing layer of deep cervical fascia enclosing the sternocleidomastoid and the anterior wall of the carotid sheath.

Vertical tracing: When traced above, it is attached to the hyoid bone and when traced below, it enters the thorax in front of the trachea and blends with the apex of the fibrous pericardium.

Clinical correlation

- The attachment of pretracheal fascia to hyoid bone and thyroid and cricoid cartilages allows the thyroid gland to move up and down with the larynx during swallowing.
- The layers of pretracheal fascia which cover the posterior surface of the thyroid lobe is ill defined. As a result, enlarged thyroid (goitre) easily bulges posteriorly to compress the esophagus causing dysphagia.
- The pretracheal fascia provides a slippery surface to allow free movements of trachea during swallowing.

Prevertebral fascia It is extremely strong and lies in front of the prevertebral muscles.

Tracing of the prevertebral fascia

Horizontal tracing: When traced laterally, it covers the scalene muscles, levator scapulae, and splenius capitis forming the fascial carpet of the posterior triangle. The roots of cervical spinal nerves that form the cervical and brachial plexuses lie deep to it.

As the trunks of brachial plexus and subclavian artery emerge between the scalenus anterior and scalenus medius and move towards the axilla, they carry with them a tubular sheath of this fascia, called **axillary sheath**, which may extend up to the elbow.

N.B. The subclavian and axillary veins lie outside the sheath to allow their free dilation during increased venous return from the upper limb.

Vertical tracing: Traced above, the fascia extends up to the base of the skull to which it is attached. Traced below, it continues downwards in front of longus colli muscles into the superior mediastinum where it blends with the anterior longitudinal ligament of the upper thoracic vertebrae (T1 to T3).

Other features

Anteriorly, the prevertebral layer of deep cervical fascia is separated from posterior aspect of the pharynx and its covering, buccopharyngeal fascia, by a potential space called **retropharyngeal space** (Fig. 4.13). This space allows the expansion of the pharynx during swallowing. The retropharyngeal space is continuous with the parapharyngeal spaces at the sides of the pharynx. The retropharyngeal space is divided into two lateral compartments (**spaces of Gillette**) by a midline fibrous raphe. Each lateral space contains retropharyngeal lymph nodes, which usually disappear at 3–4 years of age.

The space behind the prevertebral fascia and in front of the vertebral bodies is called **prevertebral space**.

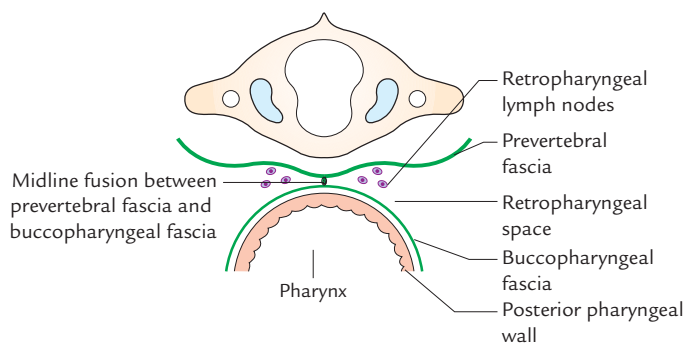


Fig. 4.13 Retropharyngeal space.

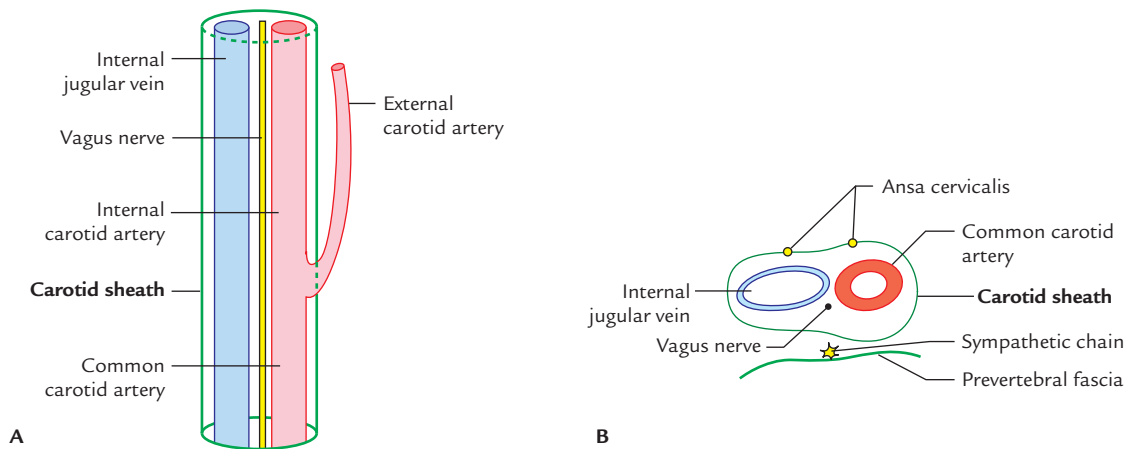


Fig. 4.14 Carotid sheath: A, surface view; B, sectional view.

Clinical correlation

- The infections of retropharyngeal space can pass down behind the esophagus and may extend into the posterior mediastinum, of course, through superior mediastinum.
- The retropharyngeal abscess due to involvement of retropharyngeal lymph nodes produces paramedian unilateral bulge in the posterior pharyngeal wall due to fusion of buccopharyngeal fascia to the prevertebral fascia in the median plane.
- Tubercular caries of cervical vertebra produce abscess in the prevertebral space which often extends into the retropharyngeal space.
- Pus collected in the prevertebral space due to caries of cervical vertebrae may travel forward and cause midline bulge in the posterior pharyngeal wall. Pus may travel laterally first into the posterior triangle deep to fascial carpet formed by prevertebral fascia and then along the axillary sheath into the axilla or even into the arm.

Other Derivatives of the Deep Cervical Fascia

These include:

1. Carotid sheath.
2. Buccopharyngeal fascia.

Carotid sheath It is a tubular condensation of deep cervical fascia around the (a) common carotid and internal carotid arteries, and (b) internal jugular vein and vagus nerve (Fig. 4.14). The vagus nerve lies posteriorly between the vein and arteries. The carotid sheath is wedged between the three layers of the deep cervical fascia, i.e., investing layer, pretracheal fascia, and prevertebral fascia, and attached to all

these layers by loose areolar tissue. The sheath is thick around common and internal carotid arteries but thin over the internal jugular vein in order to allow its expansion during increased venous return.

Carotid sheath extends from the base of the skull above to the arch of aorta below. At the base of the skull, it is attached to the margins of the carotid canal and jugular fossa. At the arch of aorta, it blends with its tunica adventitia.

Relations

1. The ansa cervicalis is embedded in the anterior wall of the carotid sheath.
2. The cervical sympathetic chain is closely related to posterior wall of the sheath, plastered to the prevertebral fascia.

Clinical correlation

The malignant and tuberculous deep cervical lymph nodes frequently become adherent to the internal jugular vein. Therefore, during block dissection of the neck, the sheath is exposed and a portion of the vessel is resected to facilitate removal of these lymph nodes.

Buccopharyngeal fascia It is a delicate and distensible layer of fascia that covers the constrictor muscles of pharynx and buccinator muscle. The buccopharyngeal fascia extends from the base of the skull to the esophagus.

N.B. Together with similar layer of fascia on the internal surfaces of the constrictor muscles, the *pharyngobasilar fascia* closes the gaps in the muscular wall of the pharynx.

Golden Facts to Remember

- | | |
|---|---|
| ▶ Most important superficial vein in the neck | External jugular vein |
| ▶ Most commonly used external jugular vein for central venous cannulation/catheterization | Right external jugular vein |
| ▶ Muscle of the neck representing panniculus carnosus of lower animals | Platysma |
| ▶ Cold abscess (tubercular abscess) | Abscess without signs of acute inflammation like pain and redness |
| ▶ Commonest cause of cold abscess in the neck | Tuberculosis of cervical vertebrae (caries of cervical vertebrae) |
| ▶ Ligament of Berry | Fibrous band connecting thyroid capsule to the cricoid cartilage |
| ▶ Muscle in the neck, which serves to ease the tight collar | Platysma |

Clinical Case Study



A 27-year-old individual reported to the emergency OPD. He had linear cut on the anterolateral aspect of his neck which was bleeding profusely. On examination the doctors found that the wound was superficial and not involving any major structure that could threaten his life. The wound was located in the upper part of the carotid triangle. It was cleaned and stitched. The boy was discharged and given a course of antibiotics. He was asked to come for removal of stitches after 7 days. After removal of stitches a wide ugly scar was seen on the side of the cut.

Questions

- Enumerate the structures present in the superficial fascia of the neck (anterolateral aspect).
- Why do superficial cut-wounds in the region of neck bleed profusely?
- What likely mistake the doctor could have made during stitching that resulted in wide ugly scar?

Answers

- Platysma, superficial veins, cutaneous nerves, superficial lymph nodes, and lymph vessels.
- The superficial cut wounds of the neck bleed profusely because retraction of divided platysma keeps the cut superficial veins open.
- He may not have sutured the platysma as a separate layer; for details refer to clinical correlation on page 69.

Side of the Neck

The side of the neck is roughly **quadrangular** in shape. It is bounded *anteriorly* by anterior midline of the neck, *posteriorly* by anterior border of the trapezius, *superiorly* by the lower border of the body of the mandible and a line extending from the angle of the mandible to the mastoid process, and *inferiorly* by the clavicle.

The side of the neck is the common site for various pathological lesions, such as lymphadenopathy, cysts, tumors, etc. It is also a frequent site for performing various clinical procedures such as biopsy, venepuncture, nerve block, etc.

Surface Landmarks on the Side of the Neck (Fig. 5.1)

1. **Sternocleidomastoid** forms the most important landmark on the side of the neck. It becomes prominent when the face is turned to the opposite side and is seen as a raised ridge extending obliquely from the sternum to the mastoid process.
2. **Mastoid process** is a large bony projection easily felt behind the lower part of the auricle.
3. **Anterior border of trapezius** becomes prominent when shoulder is elevated against the resistance.

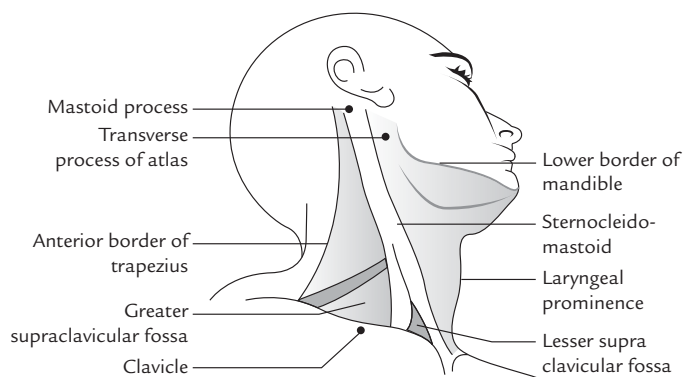


Fig. 5.1 Surface landmarks on the side of the neck.

4. **Lesser supraclavicular fossa** is a small triangular depression above the medial end of the clavicle between the sternal and clavicular heads of sternocleidomastoid. It overlies the internal jugular vein.
5. **Greater supraclavicular fossa** is a depression above the middle one-third of the clavicle. It overlies the cervical part of brachial plexus and the third part of the subclavian artery.
6. **Transverse process of first cervical vertebra** can be felt on deep pressure midway between the angle of the mandible and mastoid process. It is crossed by spinal accessory nerve.
7. **Lower border of the mandible** can be easily felt by running a finger backwards from chin to the angle of the mandible.
8. **Clavicle** being subcutaneous can be palpated along its entire extent at the junction of the neck and chest.

Skin, Superficial Fascia, and Deep Fascia

The skin, superficial fascia, and deep fascia on the side of neck is described in Chapter 4.

TRIANGLES ON THE SIDE OF THE NECK

The side of the neck is quadrangular in shape (vide supra).

This quadrilateral area is divided into large anterior and posterior triangles by the sternocleidomastoid muscle which runs across this area diagonally from mastoid process to the upper end of the sternum (Fig. 5.2).

The students should first know the attachments of two major superficial muscles, i.e., sternocleidomastoid and trapezius, encountered on the side of neck before studying the anterior and posterior triangles. The trapezius is described in Chapter 7 on page 98, while sternocleidomastoid is described in the following text.

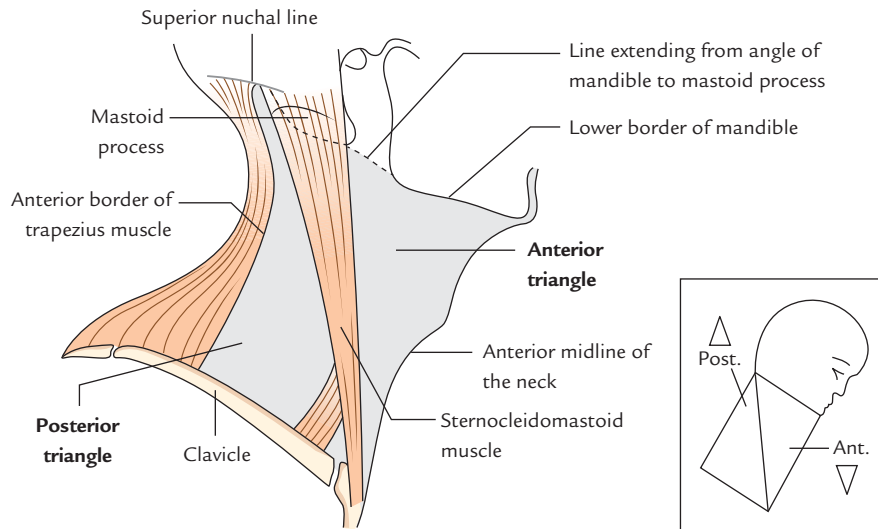


Fig. 5.2 Boundaries and triangles on the side of the neck. The quadrilateral shape of the side of the neck can be well appreciated by Figure in the inset.

Sternocleidomastoid Muscle (Fig. 5.3)

It is the key muscle of the neck which extends obliquely across the side of the neck, dividing it into posterior and anterior triangles.

Origin

The muscle arises by two heads: sternal and clavicular.

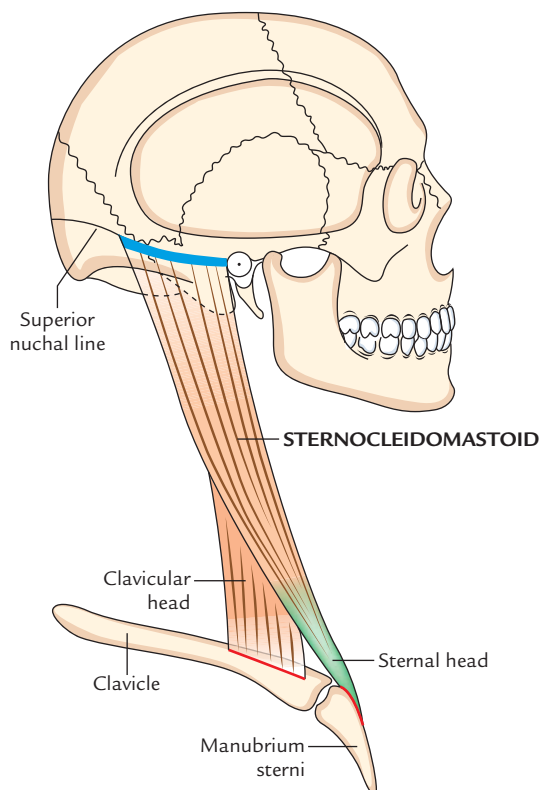


Fig. 5.3 Origin and insertion of the sternocleidomastoid muscle.

1. **Sternal head**, is tendinous and arises by a rounded tendon from the superolateral part of the front of the manubrium sterni, below the suprasternal notch and passes upwards, backwards, and laterally in front of the sternoclavicular joint.
2. **Clavicular head**, is flat and musculoaponeurotic. It arises from the medial third of the superior surface of the clavicle. It passes vertically upwards deep to the sternal head with which it unites to form a fusiform belly.

N.B. A small triangular gap exists between the two heads above the sternoclavicular joint. It is called *lesser supraclavicular fossa*. It contains the terminal part of the internal jugular vein, which can be entered at this site by a needle or catheter.

Insertion

The muscle is inserted by (a) a thick tendon on the lateral surface of the mastoid process extending from its tip to its base, and (b) by a thin aponeurosis into the lateral half of the superior nuchal line of the occipital bone.

Arterial Supply

The sternocleidomastoid is supplied by branches of following arteries:

1. **Upper part**, by occipital and posterior auricular arteries.
2. **Middle part**, by superior thyroid artery.
3. **Lower part**, by suprascapular artery.

N.B. The knowledge of arterial supply is important to make muscle flap in reconstructive surgery.

Nerve Supply

The sternocleidomastoid muscle is supplied by the spinal accessory nerve. It is also supplied by the ventral rami of C2

and C3, which are mostly sensory and carry proprioceptive sensations from the muscle.

Actions

When muscle contracts, it tilts the head towards the shoulder on the same side and rotates the head so that chin turns to the opposite side (Fig. 5.4A). This movement occurs during an upward sideways glance.

When muscles of both sides contract together they draw the head forwards as in lifting the head from the pillow or bending the head during eating food (Fig. 5.4B). If the head is fixed by prevertebral muscles, the two sternocleidomastoid muscles act as accessory muscles of respiration during forced inspiration.

Relations

The sternocleidomastoid is enclosed in the investing layer of deep cervical fascia. It is pierced by the spinal accessory nerve and 4 sternocleidomastoid arteries. Its superficial and deep relations are as under:

Superficial Relations

- Skin
- Platysma
- Three cutaneous nerves
 - (a) Great auricular
 - (b) Transverse cervical
 - (c) Medial supraclavicular
 - (d) Lesser occipital
- External jugular vein
- Superficial cervical lymph nodes
- Parotid gland

Deep Relations

- *In the upper part*
 - (a) *Muscle:* Posterior belly of digastric, longissimus capitis, and splenius capitis
 - (b) *Artery:* Occipital artery

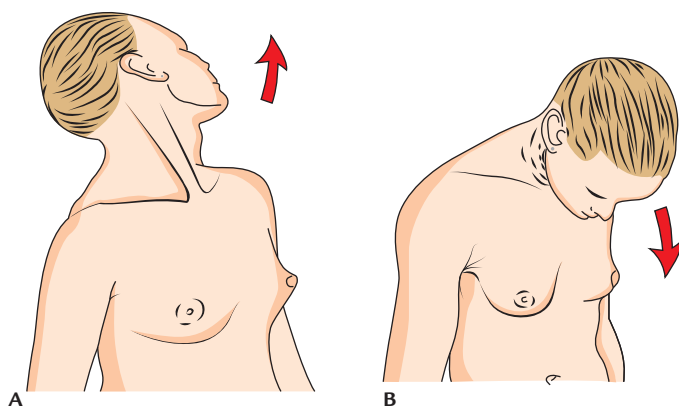


Fig. 5.4 Actions of the sternocleidomastoid muscle: A, when acting alone; B, when acting together.

- *In the middle part*
 - (a) *Muscles:* Levator scapulae, scalenus anterior, scalenus medius, scalenus posterior, splenius capitis, inferior belly of omohyoid
 - (b) *Arteries:* Common carotid, internal carotid
 - (c) *Veins:* Internal jugular, anterior jugular
 - (d) *Nerves:* Vagus, spinal accessory, cervical plexus, brachial plexus (upper part), ansa cervicalis (inferior root)
 - (e) *Glands:* Thyroid gland, lymph nodes
- *In the lower part*
 - (a) *Muscles:* Sternohyoid, sternothyroid, scalenus anterior
 - (b) *Arteries:* Suprascapular, transverse cervical
 - (c) *Veins:* Anterior jugular
 - (d) *Nerves:* Brachial plexus (lower part), phrenic nerve

Clinical correlation

- **Torticollis or wry neck:** It is a clinical condition in which head is bent to one side and chin points to the opposite side. This occurs due to spasm of sternocleidomastoid and trapezius muscles supplied by spinal accessory nerve.
 - The *spasmodic torticollis* is characterized by repeated painful contractions of the trapezius and sternocleidomastoid muscles on one side. It is usually caused by exposure to cold and maladjustment of pillow during sleep.
 - The *reflex torticollis* occurs due to irritation of spinal accessory nerve caused by inflamed or suppurating lymph nodes.
 - The *congenital torticollis* occurs due to birth injury to muscle. Permanent torticollis may occur due to subsequent ischemic contracture.
- **Sternocleidomastoid tumor:** It is the swelling in the middle third of the sternocleidomastoid muscle due to edema and ischemic necrosis caused by birth trauma.

N.B. The sternocleidomastoid is crossed superficially by the great auricular nerve, external jugular vein, and transverse cervical nerve, in that order from above downwards. On the deeper aspect, it is also related to deep cervical lymph nodes.

POSTERIOR TRIANGLE

It is the triangular space on the side of neck behind the sternocleidomastoid muscle. Its apex is directed upwards and backwards towards the mastoid process and base downwards towards the clavicle.

Boundaries (Fig. 5.6)

- Anterior:** Posterior border of sternocleidomastoid muscle.
- Posterior:** Anterior border of trapezius muscle.
- Inferior (base):** Superior aspect of middle third of the clavicle.
- Superior (apex):** Meeting point of sternocleidomastoid and trapezius muscles at the superior nuchal line of the occipital bone.

Roof

It is formed by the investing layer of the deep cervical fascia, stretching between the sternocleidomastoid and trapezius muscles.

The **superficial fascia overlying the roof** contains platysma, external jugular and posterior jugular veins, and cutaneous nerves and vessels.

Structures piercing the roof of the posterior triangle (Fig. 5.5) are:

- Four cutaneous branches of cervical plexus, viz.**
 - Lesser occipital nerve (C2)
 - Great auricular nerve (C2, C3)
 - Transverse cervical nerve (C2, C3)
 - Supraclavicular nerves (C3, C4).

They pierce the roof near the middle of the posterior border of the sternocleidomastoid muscle (for details see page 83).
- External jugular vein:** It begins just below the angle of mandible, runs downwards and backwards crossing the sternocleidomastoid obliquely and under the cover of platysma (for details see page 70).

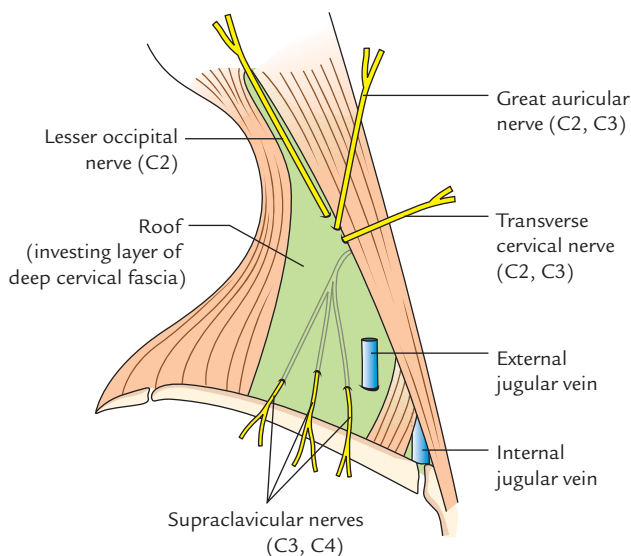


Fig. 5.5 Structures piercing the roof of the posterior triangle.

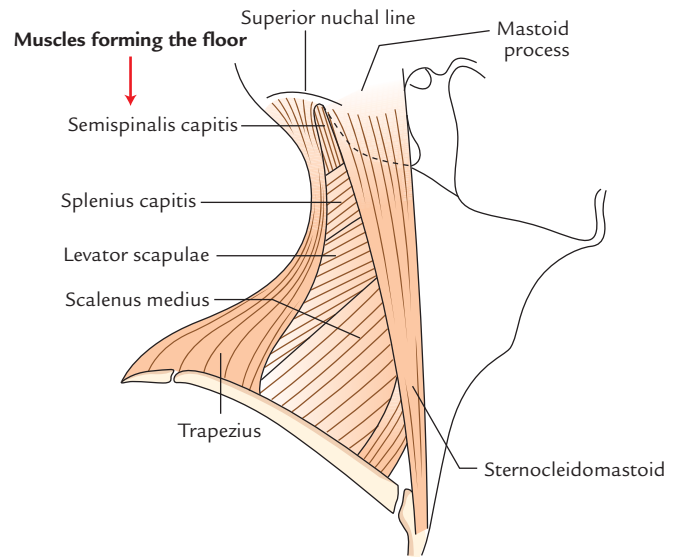


Fig. 5.6 Boundaries and floor of the posterior triangle.

Floor (Fig. 5.6)

The floor of posterior triangle is muscular and is formed from above downwards by the following muscles:

- Semispinalis capitis.
- Splenius capitis.
- Levator scapulae.
- Scalenus medius.
- First digitation of serratus anterior (sometimes).

Fascial carpet of the posterior triangle

The muscular floor of posterior triangle is covered by prevertebral layer of deep cervical fascia, which forms the **fascial carpet of the floor of the posterior triangle**. It forms axillary sheath around subclavian artery and brachial plexus travelling from the root of the neck to the upper limb.

The lower part of the posterior triangle is crossed by inferior belly of omohyoid superficial to the fascial carpet.

Clinical correlation

Pus collected in the posterior triangle deep to its fascial carpet from tubercular cervical vertebrae may track downwards and laterally along the axillary sheath to first appear in the axilla or even in the arm subsequently.

Subdivisions (Fig. 5.7)

The posterior triangle is subdivided into two parts by the inferior belly of the omohyoid, which crosses the lower part of the triangle obliquely upwards and forwards (a) a larger upper part called **occipital triangle**, and (b) a small lower part called **subclavian (supraclavicular) triangle**. These parts are so named because they contain occipital and subclavian arteries, respectively.

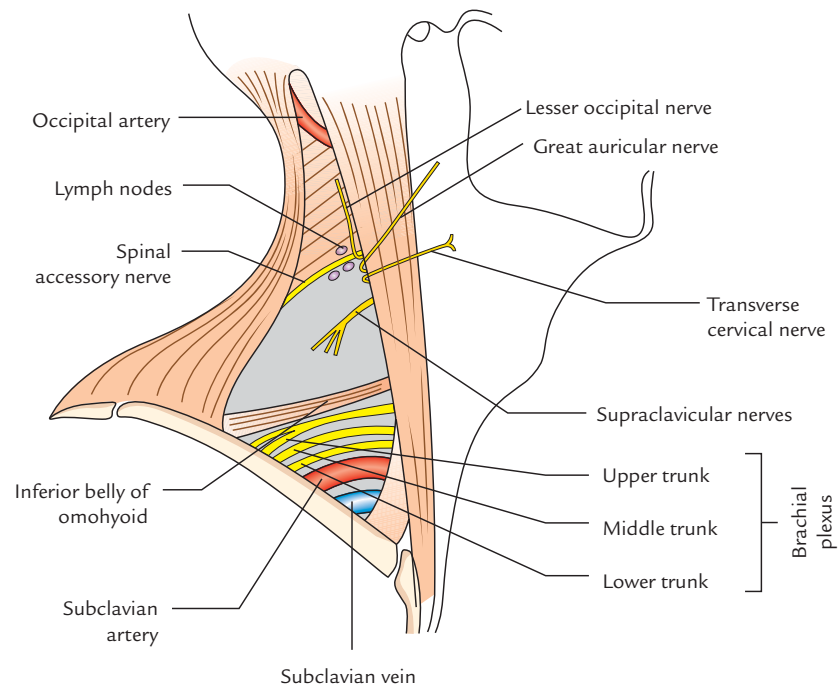


Fig. 5.7 Subdivisions and main contents of the posterior triangle.

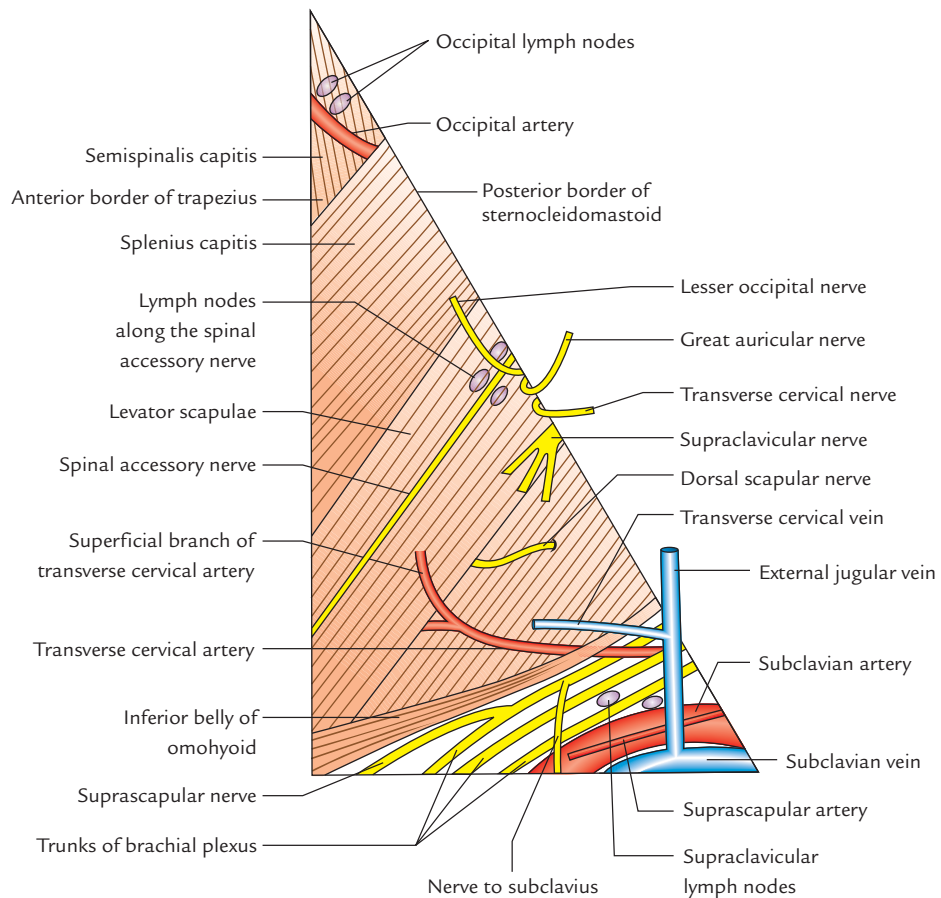


Fig. 5.8 Schematic diagram showing the floor and contents of the right posterior triangle.

Contents (Figs 5.7 and 5.8)

1. **In the occipital triangle (i.e., above the omohyoid)**
 - (a) Spinal accessory nerve
 - (b) 3rd and 4th cervical nerves providing branches to levator scapulae and trapezius muscles
 - (c) Dorsal scapular nerve (C5)
 - (d) Four cutaneous branches of cervical plexus (initial parts)
 - (e) Superficial transverse cervical artery
 - (f) Occipital artery.
2. **In the subclavian/supraclavicular triangle (i.e., below the omohyoid)**
 - (a) 3rd part of the subclavian artery
 - (b) Subclavian vein
 - (c) Terminal part of external jugular vein
 - (d) Trunks of brachial plexus
 - (e) Superficial (transverse) cervical, suprascapular, and dorsal scapular arteries
 - (f) Lymph nodes.

N.B.

- The most important contents of posterior triangle are:
 - (a) third part of subclavian artery, (b) brachial plexus (cervical part), (c) spinal accessory nerve, and (d) lymph nodes.
- All the important contents of the posterior triangle lie deep to the fascial carpet of the floor except spinal accessory nerve, which lies just underneath the roof. In operations on the posterior triangle all the structures except spinal accessory nerve are safe, provided fascial carpet of posterior triangle is left intact.

Relevant Features of Some of the Contents

- **Spinal accessory nerve:** This nerve emerges in the posterior triangle by piercing the posterior border of the sternocleidomastoid (a little above the middle of this border). In this situation, it is related to lymph nodes of the upper deep cervical chain (Fig. 5.9). The nerve then crosses the posterior triangle by running downwards and laterally over and parallel to the fibres of levator scapulae muscle to disappear underneath the anterior border of trapezius (about 5–6 cm above the clavicle) and supplies trapezius muscle. In the posterior triangle it is adherent to the deep aspect of the fascial roof of this triangle.

N.B. More proximally, the nerve lies in front of transverse process of atlas vertebra runs downwards and laterally to enter the anterior border of sternocleidomastoid muscle between its upper two quarters and supplies it.

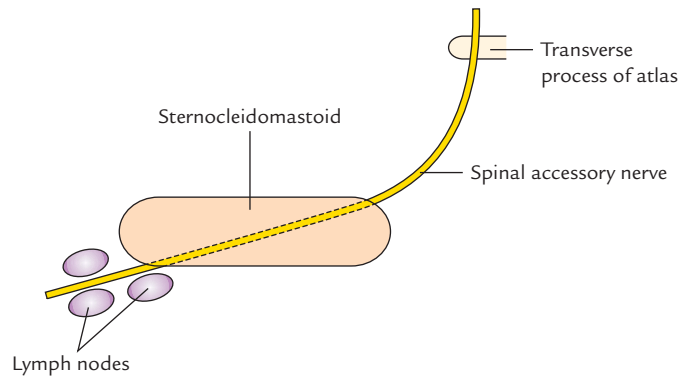


Fig. 5.9 Course of spinal accessory nerve right through sternocleidomastoid muscle. Note the relation of lymph nodes to this nerve.

Clinical correlation

The spinal accessory nerve may be damaged in operations involving the removal or biopsy of lymph nodes in the posterior triangle of the neck.

- **Four cutaneous branches of cervical plexus (Fig. 5.10):** Although cervical plexus is located deep to the sternocleidomastoid but its cutaneous branches emerge at the midpoint or just above the midpoint of the posterior border of the sternocleidomastoid by piercing the deep cervical fascia.

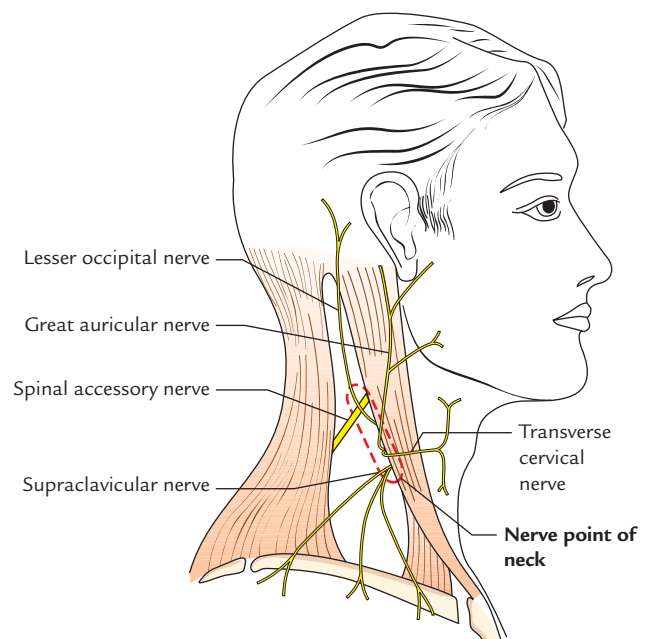


Fig. 5.10 Cutaneous branches of the cervical plexus. Note the location of 'nerve point of the neck' (dotted red circle).

The course and distribution of these cutaneous nerves are as follows:

- The **lesser occipital nerve** hooks around the spinal accessory nerve and ascends for a short distance along the posterior border of sternocleidomastoid to innervate the skin of the upper one-third of the cranial surface of the auricle and that of the head behind the auricle.
- The **great auricular nerve** runs forwards and upwards across the sternocleidomastoid towards the angle of mandible where it divides into anterior and posterior branches. It first supplies the skin of the face over the angle of the mandible and then the skin over the mastoid region and lower part of both the surfaces of the auricle.
- The **transverse cervical nerve** passes forward across the sternocleidomastoid deep to the external jugular vein and then divides into ascending and descending branches to supply the skin of the front of the neck.
- The **supraclavicular nerve** arises as a common trunk which descends downwards and divides into medial, intermediate, and lateral supraclavicular nerves.
 - The **medial supraclavicular nerve** crosses in front of the medial one-third of the clavicle to supply the skin on the chest up to the 2nd rib.
 - The **intermediate supraclavicular nerve** passes in front of the middle third of the clavicle to supply the skin on the front of the chest. Occasionally it pierces the clavicle through and through.
 - The **lateral supraclavicular nerve** crosses in front of the lateral third of the clavicle and supplies the skin over the shoulder and the upper half of the deltoid muscle.

N.B. The point at the junction of the upper and middle third of the posterior border of sternocleidomastoid where four cutaneous nerves and spinal accessory nerve emerge is termed **nerve point of the neck**.

In 'cervical plexus nerve block' the anesthetic agent is injected at this site.

- Muscular branches to levator scapulae and trapezius (C3, C4):** They appear at about the middle of sternocleidomastoid. The branches going to levator scapulae soon end in it, whereas those going to trapezius run below and parallel to the spinal accessory nerve and cross the middle of the triangle.
- Nerve to rhomboids:** It pierces scalenus medius muscle and immediately passes deep to levator scapulae muscle.
- Cervical part of the brachial plexus:** The roots and trunks of brachial plexus lie in the neck.

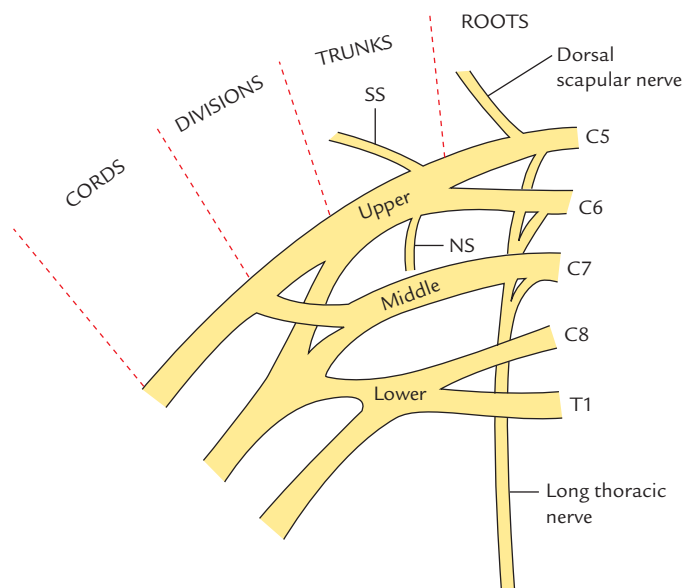


Fig. 5.11 Branches arising from cervical part (roots of trunks) of brachial plexus (SS = suprascapular nerve, NS = nerve to subclavius).

Four branches arise from cervical part of brachial plexus—two from roots and two from trunks (Fig. 5.11).

From roots

- Dorsal scapular nerve** arises from C5 root. It pierces the scalenus medius and runs laterally across it to pass deep to levator scapulae, which it supplies.
- Long thoracic nerve (or nerve to serratus anterior)** arises from C5, C6, and C7 roots. It passes downwards behind the brachial plexus and third part of the subclavian artery. It crosses the first rib to supply the serratus anterior muscle.

Remember that C5 and C6 roots pierce the scalenus medius and C7 root joins the nerve at the lower level in the axilla.

From trunks

- Nerve to subclavius** arises from upper trunk (C5 and C6). It passes downwards in front of brachial plexus and subclavian vessels to supply the subclavius muscle.
 - Suprascapular nerve** also arises from the upper trunk (C5 and C6). It passes laterally deep to inferior belly of omohyoid and trapezius to enter the suprascapular fossa through suprascapular notch to supply the supraspinous and infraspinatus muscles.
- Transverse cervical artery:** It is a branch of thyrocervical trunk of the first part of subclavian artery. It passes laterally and upwards crossing the scalenus anterior, upper trunk of brachial plexus and scalenus medius.

At the lower border of levator scapulae, it divides into the superficial and deep branches.

- **Suprascapular artery:** This is also a branch of thyrocervical trunk. It passes laterally and backwards behind the clavicle to reach the upper border of the scapula.
- **Dorsal scapular artery:** It arises from the third part of the subclavian artery. It passes laterally in front of scalenus medius and through the brachial plexus to reach the superior angle of the scapula.
- **Occipital artery:** It is a branch of external carotid artery. It crosses the apex of the triangle superficial to the semispinalis capitis.
- **Subclavian artery:** It passes behind the scalenus anterior over the first rib. It is closely related to the **lower trunk of the brachial plexus**.
- **Subclavian vein:** It passes in front of scalenus anterior over the first rib.
- **Terminal part of external jugular vein:** It pierces the fascial roof of the posterior triangle about 2.5 cm above the clavicle to terminate in the subclavian vein (for details see Chapter 4, p. 70).
- **Lymph nodes:** These are deep cervical lymph nodes found at the following sites in the posterior triangle:
 - (a) A chain of nodes **along the posterior border of sternocleidomastoid**.
 - (b) A chain of nodes **along the spinal accessory nerve**.
 - (c) A few nodes in the **apical region of the triangle** called **occipital lymph nodes**.
 - (d) A group of lymph nodes in the supraclavicular part of triangle called **supraclavicular lymph nodes**. These nodes lie **superficial to brachial plexus and subclavian vessels**.

ANTERIOR TRIANGLE

The anterior triangle is the triangular space on the side of the neck, in front of the sternocleidomastoid (for detail see Chapter 6, page 87).

Clinical correlation

- **Brachial plexus block:** The brachial plexus in the posterior triangle is located below the line extending from the posterior border of the sternocleidomastoid (at the level of cricoid cartilage) to the midpoint on the superior aspect of the clavicle. In this region, the brachial plexus can be blocked by injection of a local anesthetic between the first rib and the skin above the clavicle. The brachial plexus block is sometimes done to perform surgical procedures in the upper limb.
- **Pulsations of subclavian artery** can be felt at the root of the neck by pressing behind clavicle at the posterior border of the sternocleidomastoid muscle.

The hemorrhage from the arteries of the upper limb can be stopped by pressing subclavian artery on to the first rib lateral to the lower end of the sternocleidomastoid muscle.
- **Swelling in the posterior triangle:** The most common cause of swelling in the posterior triangle is due to enlargement of lymph nodes. The supraclavicular lymph nodes are commonly involved and enlarged in tuberculosis, Hodgkin's disease, and malignant growth of breast, arm, and chest. The left supraclavicular lymph nodes (also called *Virchow's lymph nodes*) are commonly involved in metastasis from cancer stomach, cancer testis, and cancer of other abdominal organs. The biopsy of these lymph nodes is helpful in early diagnosis of distant malignancies.

Golden Facts to Remember

▶ 'Key muscle' of the neck	Sternocleidomastoid
▶ All the important structures of posterior triangle are present deep to prevertebral fascia (fascial carpet) <i>except</i>	Spinal accessory nerve
▶ Most common cause of swelling in the posterior triangle	Enlargement of supraclavicular lymph nodes
▶ Most commonly injured nerve during removal of enlarged cervical lymph nodes in the posterior triangle	Spinal accessory nerve
▶ Most important surface landmark on the side of the neck	Sternocleidomastoid
▶ Virchow's lymph nodes	Left supraclavicular lymph nodes
▶ Pulsations of subclavian artery can be felt by	Pressing downwards above the clavicle at the posterior border of sternocleidomastoid
▶ Commonest cause of cervical lymphadenopathy in adults	Metastatic deposits of cancer cells in cervical lymph nodes

Clinical Case Study



A 65-year-old woman visited her family physician with a swelling in her neck in the region of left posterior triangle. The swelling had gradually increased in size. On examination, it felt very hard and the physician thought that it was due enlarged lymph node/nodes containing secondary carcinoma (cancer). He referred her to the hospital where she underwent open excisional biopsy followed by fine needle aspiration biopsy. Following surgery the patient complained that she was not able to elevate her left shoulder above 90° to comb her hair. On examination, it was found that her left trapezius was paralyzed, while left sternocleidomastoid was normal and he concluded that the spinal accessory nerve might have been excised inadvertently during biopsy.

Questions

1. What could be the cause of paralysis of her left trapezius?

2. Describe the course of spinal accessory nerve in the posterior triangle.
3. Why is spinal accessory nerve liable to injury during the excisional biopsy of enlarged cervical lymph nodes in the posterior triangle?
4. Why sternocleidomastoid is not paralyzed?

Answers

1. Injury to spinal accessory nerve which provides motor supply to the trapezius.
2. Refer to page 82.
3. Refer to page 82.
4. Because spinal accessory nerve supplies sternocleidomastoid before entering the posterior triangle.

Anterior Region of the Neck

The triangular area on the front of the neck between the two sternocleidomastoid muscles is called *anterior region of the neck*. It is limited above by lower border of the body of mandible and line extending on either side from the angle of the mandible to the mastoid process, and below by the suprasternal notch. This area includes both **anterior triangles**, and **suprahyoid** and **infrahyoid** areas (Fig. 6.1).

The anterior region of the neck is divided by the anterior median line (extending from symphysis menti to the jugular notch) into two anterior triangles of the neck.

Before going into details of anterior triangles of the neck, it is of great clinical importance to know the structures in the anterior median line of the neck. The identification of these

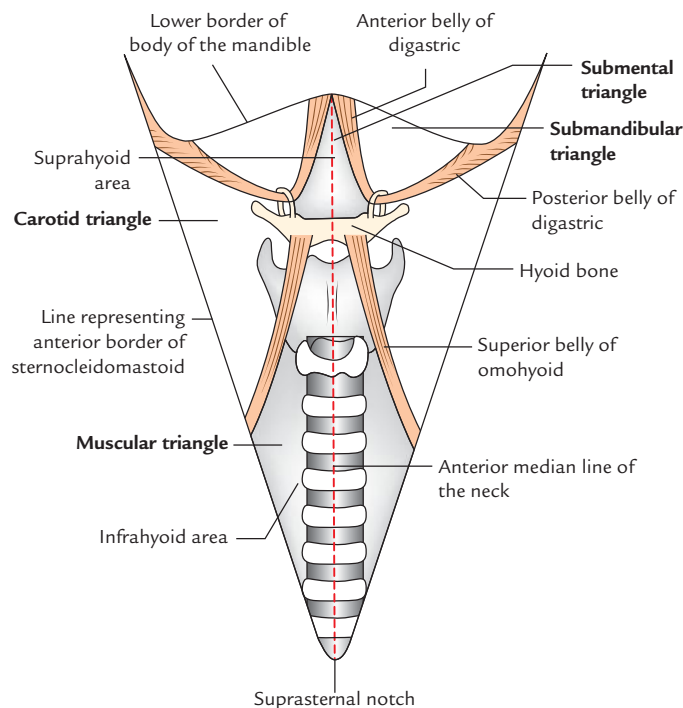


Fig. 6.1 Schematic diagram of anterior median region of the neck showing suprahyoid and infrahyoid area.

structures is essential while performing tracheostomy. It is also useful in clinical examination of midline swellings of the neck.

STRUCTURES IN THE ANTERIOR MEDIAN REGION OF THE NECK

The anterior median region of the neck is 2–3 cm wide strip extending from symphysis menti to the suprasternal notch. Deep to skin and underlying the superficial and deep cervical fasciae, the anterior median region presents the following structures from above downwards (Fig. 6.2):

1. **Symphysis menti:** Its lower border can be felt where the two halves of the body of the mandible unite in the midline.

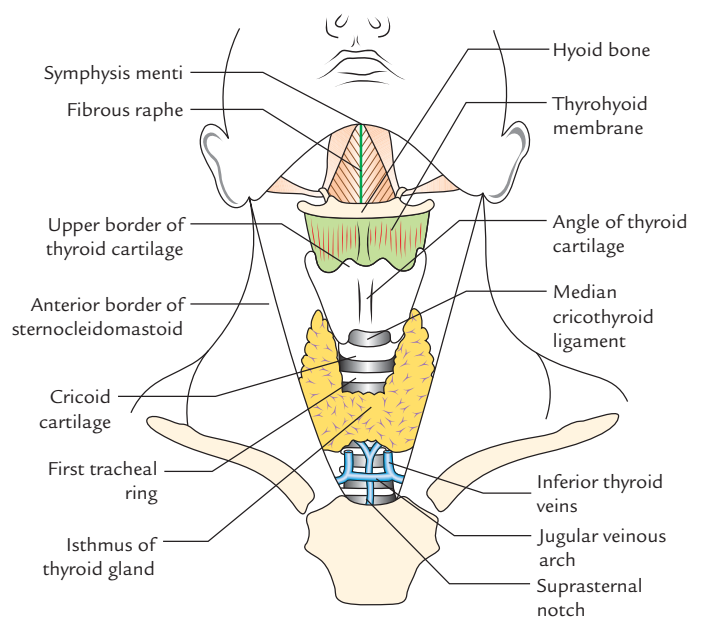


Fig. 6.2 Structures in the anterior median line of the neck.

2. **Fibrous raphe:** It extends from symphysis menti to the hyoid bone. Mylohyoid muscles of both sides meet along this raphe to form the floor of the mouth (diaphragma oris).
3. **Hyoid bone:** It is a horseshoe-shaped bone suspended inferior to mandible by stylohyoid ligaments like children's swing. Hyoid bone does not articulate with any other bone and has only muscular and ligamentous attachments. It lies at the level of C3 vertebra. The regions above and below the hyoid bone are called **suprahyoid region** and **infrahyoid region**, respectively.
4. **Median thyrohyoid ligament:** It is the midline thickening of the thyrohyoid membrane that connects the upper border of thyroid cartilage to the lower border and greater cornu of the hyoid bone. The membrane is separated from the hyoid bone by a **subhyoid bursa**.
5. **Upper border of the thyroid cartilage:** It is notched and can be felt. It lies opposite the body of T4 vertebra.
6. **Angle of the thyroid cartilage:** It forms the laryngeal prominence, which is more prominent in adult males and is called **Adam's apple**.
7. **Median cricothyroid ligament:** It is the midline thickening of the cricothyroid membrane extending between upper border of cricoid cartilage and lower border of the thyroid cartilage.
8. **Cricoid cartilage:** It lies at the lower border of C6 vertebra and is the most important surface landmark on the front of the neck because a number of important structures are located at this level, such as (a) junction of larynx and trachea, (b) junction of pharynx and esophagus, and (c) anterior tubercle of transverse process of C6 vertebra (carotid tubercle) against which common carotid artery can be compressed.
9. **First tracheal ring:** It can be felt by gentle pressure just above the isthmus of the thyroid gland.
10. **Isthmus of the thyroid gland:** It lies in front of the 2nd, 3rd, and 4th tracheal rings.
11. **Inferior thyroid veins:** After emerging from isthmus they run downwards to lie in front of the 5th, 6th, and 7th tracheal rings.
12. **Thyroidea ima artery:** When present, it ascends in front of the trachea to the isthmus of the thyroid; it usually arises from the brachiocephalic artery.
13. **Jugular venous arch:** This traverses the venous arch, which connects the anterior jugular veins just above the suprasternal notch.
14. **Suprasternal notch:** It can be felt between the anterior ends of the clavicle. It lies opposite the lower border of the body of T2 vertebra. Occasionally, left brachiocephalic vein and brachiocephalic artery may lie in front of trachea in the suprasternal notch.

Clinical correlation

- The **most common anterior midline swellings of the neck** are: (a) enlarged submental lymph nodes, (b) thyroglossal cyst, and (c) goitre.
- The **tracheostomy** is most commonly done in the retrothyroid region after cutting the isthmus of thyroid gland (for detail see page 164).
- The **cut-throat wounds** are most commonly observed just above or below the hyoid bone. The main vessels of the neck, viz. common carotid, internal and external carotid arteries, and internal jugular vein, usually escape the injury as they are automatically pushed backwards to the deeper plane, when neck is inadvertently extended by the culprit, before being cut.

ANTERIOR TRIANGLE OF THE NECK

The anterior triangle of the neck is a large triangular space on each side of the neck, in front of sternocleidomastoid with its apex directed downwards and base directed upwards (Fig. 6.3).

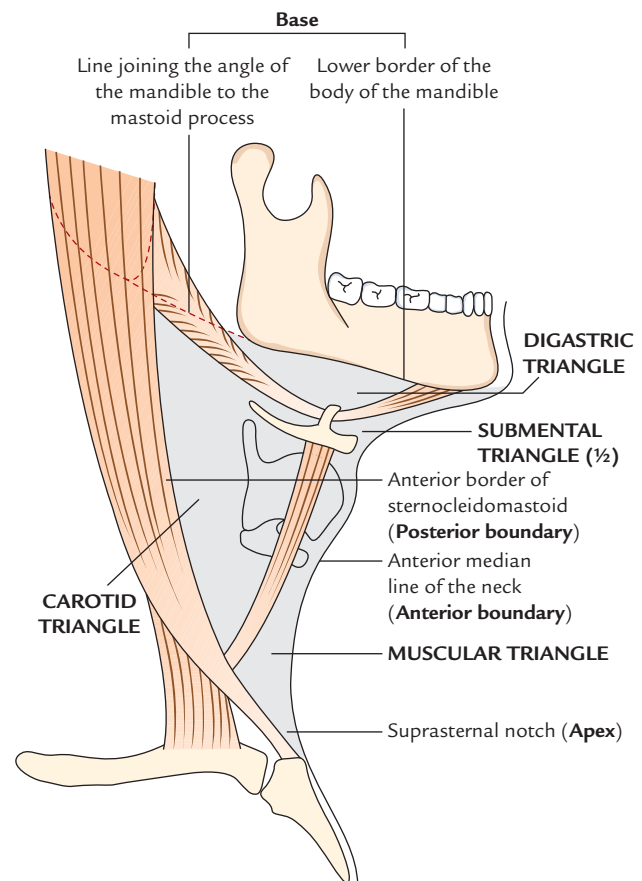


Fig. 6.3 Boundaries and subdivisions of the right anterior triangle.

Boundaries (Fig. 6.3)

Anterior: Anterior median line of the neck.

Posterior: Anterior border of the sternocleidomastoid muscle.

Base: Lower border of the body of mandible and a line extending from the angle of mandible to the mastoid process.

Apex: Suprasternal notch at the meeting point between anterior border of sternocleidomastoid and anterior median line.

Roof: Investing layer of deep cervical fascia.

The superficial fascia over the fascial roof contains platysma in the upper and anterior parts. The cervical branch of facial nerve and ascending and descending branches of transverse cervical cutaneous nerve traverse the plane between the platysma and the fascial roof of the triangle.

SUBDIVISIONS

For convenience of description, the anterior triangle has been subdivided, by the digastric muscle and superior belly of omohyoid muscle, into the following 3½ triangles (Fig. 6.3):

1. Submental triangle (half only).
2. Digastric (submandibular) triangle.
3. Carotid triangle.
4. Muscular triangle.

Before studying the subdivisions of anterior triangle, it is appropriate for students to know the attachments of digastric and omohyoid muscles, which are used for its subdivision.

Digastric muscle (Fig. 6.5A): It has two bellies – posterior and anterior. The triangular posterior belly arises from the digastric notch on the medial surface of the base of the mastoid process, and runs downwards and forwards, towards the hyoid bone. The narrow anterior belly arises from digastric fossa on the base of the mandible near symphysis menti and runs downwards and backwards, towards the hyoid bone. Above the hyoid bone the two bellies are connected by an intermediate tendon, which is anchored to the hyoid bone by a fascial sling of investing layer of deep cervical fascia.

Omohyoid muscle (Fig. 6.9): It consists of superior and inferior bellies joined at an angle by an intermediate tendon. The inferior belly arises from upper border of scapula, near the suprascapular notch, it then passes behind the sternocleidomastoid and ends there in an intermediate tendon. The superior belly begins at the intermediate tendon and passes almost vertically upwards to be attached to the lower border of the hyoid bone. The intermediate tendon lies at the level of arch of cricoid cartilage and anchored to the clavicle by fascial sling derived from investing layer of deep cervical fascia.

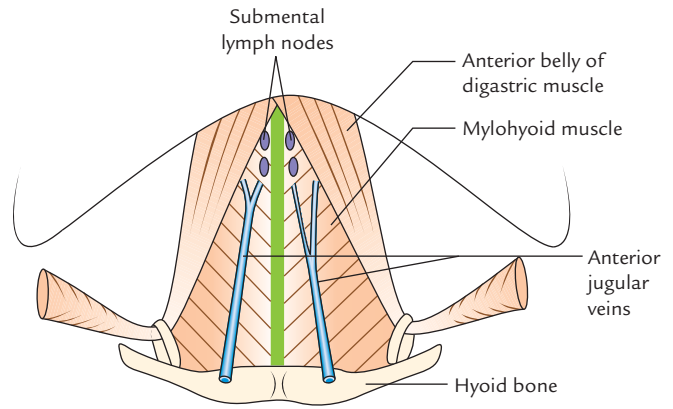


Fig. 6.4 Boundaries and contents of the submental triangle.

Submental Triangle (Fig. 6.4)

It is actually a median triangle on the front of neck below the chin and above the hyoid bone. It thus occupies the upper portions of both the anterior triangles.

Boundaries

On each side: Anterior belly of digastric muscle.

Base: Body of hyoid bone.

Apex: Chin or symphysis menti.

Floor

It is formed by the two mylohyoid muscles meeting at the median fibrous raphe extending from symphysis menti to the hyoid bone.

Roof

Investing layer of deep cervical fascia.

Contents

1. Submental lymph nodes (3 or 4 in number). Efferents from these nodes pass to the submandibular lymph nodes.
2. Submental veins and commencement of anterior jugular veins.

N.B. The contents of the triangle actually lie in the superficial fascia over the roof of the submental triangle.

Clinical correlation

Infections of floor of mouth, tip of tongue, and incisor teeth cause painful enlargement of submental lymph nodes because lymph from these structures is drained into these nodes.

Digastric (Submandibular) Triangle (Fig. 6.5 A, B)

It is so named because it is located between the two bellies of the digastric muscle and below the base of the mandible.

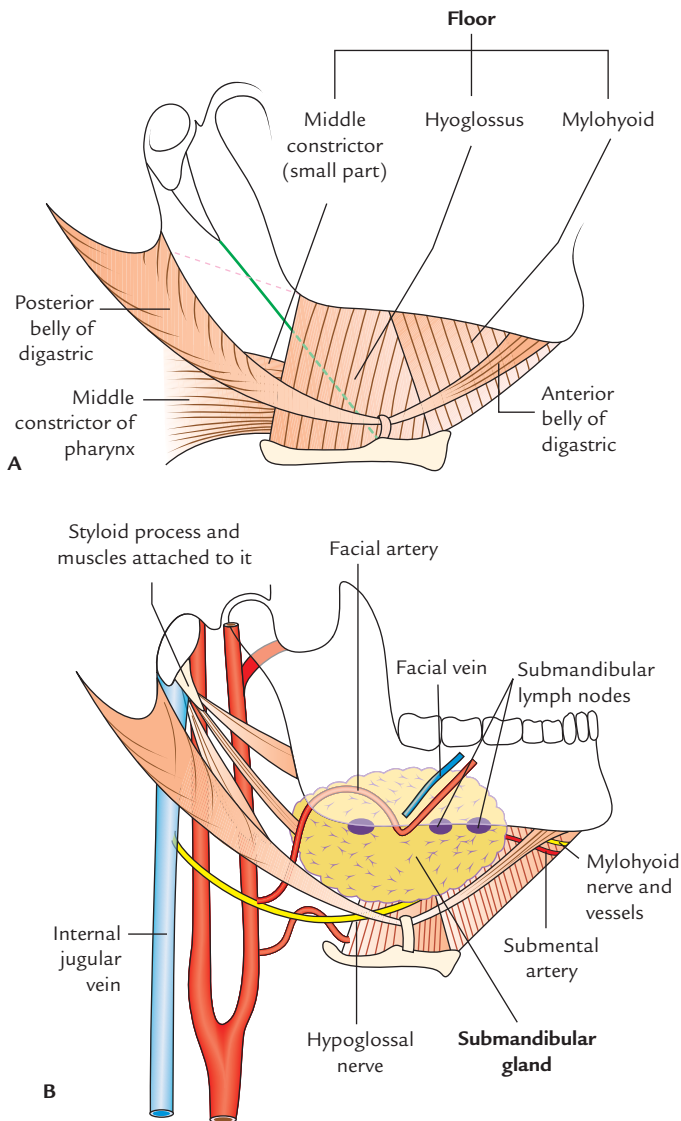


Fig. 6.5 Digastric (submandibular) triangle: **A**, boundaries and floor; **B**, boundaries and contents.

Boundaries

- Anteroinferiorly:** Anterior belly of digastric muscle.
Posteroinferiorly: Posterior belly of digastric muscle, supplemented by stylohyoid muscle.
Base: It is formed by the base of the mandible and imaginary line joining the angle of the mandible to the mastoid process.
Apex: It is formed by the intermediate tendon of the digastric muscle, being bound down to hyoid bone by a fascial sling derived from investing layer of deep cervical fascia.

Floor

It is formed by mylohyoid (anteriorly), hyoglossus, and small part of the middle constrictor (posteriorly).

Roof

It is formed by investing layer of deep cervical fascia, which splits to enclose the submandibular salivary gland. In the superficial fascia over the roof lies platysma, cervical branch of facial nerve, and ascending branch of transverse cervical nerve.

Contents

The digastric triangle is subdivided into anterior and posterior parts by the stylomandibular ligament, which extends from the tip of the styloid process to the angle of the mandible. The posterior part of the triangle is continuous above with the parotid region.

Contents in the anterior part of the triangle:

1. Submandibular salivary gland.
2. Submandibular lymph nodes.
3. Hypoglossal nerve.
4. Facial vein (lies superficial to the gland).
5. Facial artery (lies deep to the gland).
6. Submental artery.
7. Mylohyoid nerve and vessels.

Contents in the posterior part of the triangle:

1. External carotid artery.
2. Carotid sheath and its contents.
3. Structures passing between the external and internal carotid arteries (for details refer to page 241).

All these structures are discussed in detail in the submandibular region (Chapter 9, p. 131).

Clinical correlation

Submandibular triangle is the common site of swellings due to: (a) involvement of submandibular lymph nodes as they drain lymph from widespread areas such as anterior two-third of tongue (except tip), floor of mouth, frontal, ethmoidal, and maxillary air sinuses, etc. and (b) enlargement of the submandibular gland. The efferents from submandibular lymph nodes mostly pass to jugulo-omohyoid and partially to jugulodigastric nodes situated along the internal jugular vein.

Carotid Triangle (Fig. 6.6)

It is so called because it contains all the three carotid arteries, viz. common carotid, internal carotid, and external carotid.

Boundaries

- Superiorly:** Posterior belly of digastric supplemented by stylohyoid.
Anteroinferiorly: Superior belly of omohyoid.
Posteriorly: Anterior border of sternocleidomastoid.
Roof: It is formed by investing layer of deep cervical fascia. The superficial fascia over the roof contains platysma, cervical branch

of facial nerve and transverse cervical nerve (a cutaneous branch of the cervical plexus).

Floor:

It is formed by the following four muscles:

1. Thyrohyoid.
2. Hyoglossus.
3. Middle constrictor.
4. Inferior constrictor.

Contents

1. Carotid arteries
 - (a) Common carotid artery
 - (b) Internal carotid artery

- (c) External carotid artery and its first five branches.
2. Carotid sinus and carotid body.
3. Internal jugular vein.
4. Last three cranial nerves
 - (a) Vagus nerve
 - (b) Spinal accessory nerve
 - (c) Hypoglossal nerve.
5. Carotid sheath
6. Ansa cervicalis.
7. Cervical part of the sympathetic chain.
8. Deep cervical lymph nodes.

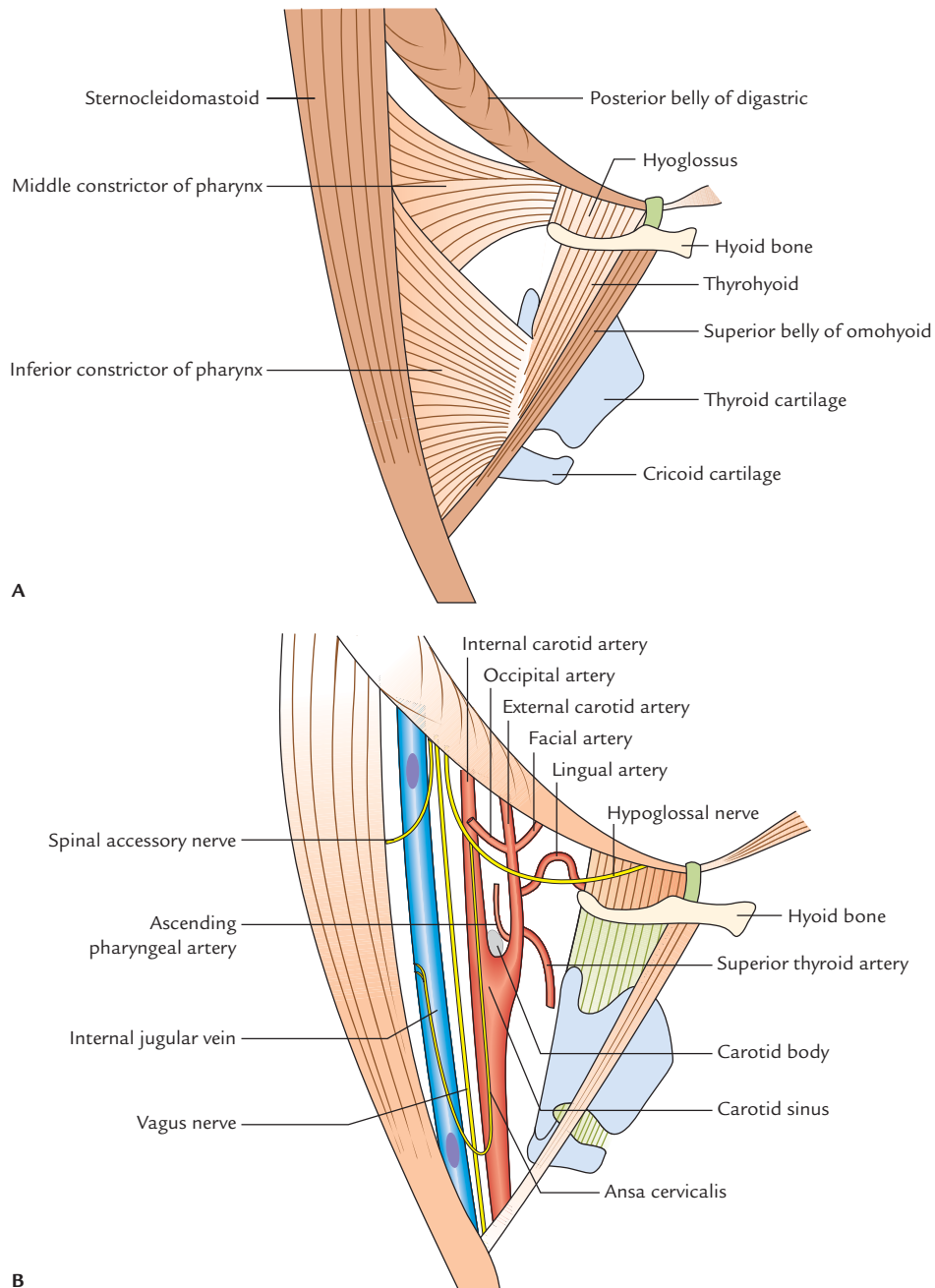


Fig. 6.6 Carotid triangle: A, boundaries and floor; B, boundaries and contents.

N.B. The major contents of carotid triangle are common carotid artery, internal carotid artery, external carotid artery, internal jugular vein, and last three cranial nerves, all overlapped by sternocleidomastoid.

The carotid triangle provides good view of all its contents only if sternocleidomastoid is retracted slightly backwards.

Relevant Features of the Contents of the Carotid Triangle

Common carotid artery

It ascends from just behind the inferior angle of the carotid triangle in the carotid sheath under cover of anterior border of sternocleidomastoid and in front of lower 4 cervical transverse processes and at the level of the upper border of the thyroid cartilage divides into external and internal carotid arteries. The common carotid artery gives no other branches in the neck (for details see page 237).

Internal carotid artery

It runs straight upwards as the continuation of the common carotid artery.

N.B. The common carotid artery and its continuation, the internal carotid artery can be represented in living body by a straight line from sternoclavicular joint to the retromandibular fossa.

Clinical correlation

The common carotid artery can be compressed against the prominent anterior tubercle of transverse process of the 6th cervical vertebra called *carotid tubercle* by pressing medially and posteriorly with the thumb. The carotid tubercle of the 6th cervical vertebra is about 4 cm above the sternoclavicular joint.

External carotid artery

It ascends anteromedial to the internal carotid artery and gives the following five branches in the triangle:

1. Ascending pharyngeal artery (first branch).
 2. Superior thyroid artery.
 3. Lingual artery.
 4. Facial artery.
 5. Occipital artery.
- **Ascending pharyngeal artery:** It is a slender artery that arises from the medial aspect of external carotid artery near its lower end. It ascends in the deeper plane on the side of the pharynx (for details see page 240).
 - **Superior thyroid artery:** It arises from the front and descends downwards and forwards to pass deep to the infrahyoid muscles to reach the upper part of the thyroid gland (for details see page 238).
 - **Lingual artery:** It arises from the front aspect of external carotid artery, opposite the tip of greater cornu of hyoid

bone. It then runs upwards and forwards forming a characteristic loop over the greater cornu of the hyoid and disappear deep to the hyoglossus muscle. Before disappearing it gives rise to suprahyoid artery, which runs superficial to hyoglossus above the hyoid (for details see page 238).

N.B. The loop of lingual artery above the greater cornu of hyoid bone permits free movements of hyoid bone without damaging the artery.

- **Facial artery:** It arises from the front aspect of external carotid artery just above the lingual artery and runs upwards on the superior constrictor deep to digastric and stylohyoid muscles (for details see page 239).
- **Occipital artery:** It arises from the posterior aspect of external carotid artery at the lower border of posterior belly of digastric muscle and runs backwards superficial to internal carotid artery, internal jugular vein, and last three cranial nerves along the lower border of posterior belly of digastrics (for details see page 239).

Hypoglossal nerve

It descends between the internal jugular vein and internal carotid artery. Then just above the level of greater cornu of hyoid bone, it hooks around the origin of the occipital artery, runs forwards, crossing in front of internal carotid artery, external carotid artery, and loop of lingual artery to run on the hyoglossus muscle above the hyoid bone.

As it crosses the internal carotid artery, it gives off the superior root of ansa cervicalis (also called *descendens hypoglossi*), which descends on the anterior wall of the internal and common carotid arteries and becomes embedded in the anterior wall of the carotid sheath.

Deep cervical lymph nodes

They lie on and along the internal jugular vein (for details see page 249).

Internal jugular vein

It is partly hidden by the posterior edge of the sternocleidomastoid. It descends posterolateral to common and internal carotid arteries and receives the following three veins in the region of carotid triangle:

1. Lingual vein.
 2. Common facial vein.
 3. Superior thyroid vein.
- The **lingual vein** lies just below and parallel to the hypoglossal nerve, crosses external and internal carotid arteries to join the internal jugular vein.
 - The **common facial vein** after crossing the digastric triangle, crosses the upper part of carotid triangle to drain into the internal jugular vein.
 - The **superior thyroid vein** crosses the lower part of the triangle to end into the internal jugular vein.

Vagus nerve

It descends vertically downwards, first between the internal carotid artery and internal jugular vein and then between common carotid artery and internal jugular vein. It gives the following two branches in the carotid triangle.

1. **Pharyngeal branch:** It runs inferomedially between the external and internal carotid arteries to join the pharyngeal plexus on the superior constrictor of the pharynx.
2. **Superior laryngeal nerve:** It runs on a deep plane, deep to both internal and external carotid arteries, where it divides into internal and external laryngeal nerves. The internal laryngeal nerve (sensory) passes forwards to disappear deep to thyrohyoid muscle; there it pierces the thyrohyoid membrane to supply the laryngeal mucosa.

The external laryngeal nerve (motor) descends to supply the inferior constrictor and cricothyroid muscles after passing deep to the superior belly of the omohyoid.

Accessory nerve

It runs downwards and backwards across the upper part of the triangle, superficial to the internal jugular vein to enter the sternocleidomastoid muscle, which it supplies.

Carotid sheath

It is a fascial sheath which encloses internal jugular vein, and internal and common carotid arteries. The vagus nerve lies in between the vein and the artery on a deeper plane (for details refer to Chapter 4). The ansa cervicalis is embedded in its anterior wall whereas the cervical sympathetic chain lies just deep to its posterior wall on the prevertebral fascia.

Carotid sinus

It is a fusiform dilatation at the terminal end of common carotid artery or at the beginning of internal carotid artery. It has rich innervation from glossopharyngeal, vagus, and sympathetic nerves. The carotid sinus acts as a baroreceptor (pressure receptor) and regulates the blood pressure in the cerebral arteries.

Clinical correlation

In an individual with *carotid sinus hypersensitivity*, pressure on carotid sinuses can cause enough slowing of heart rate, fall in blood pressure, and cerebral ischemia that will lead to fainting (syncope). Individuals with hypersensitive carotid sinuses often had sudden attacks of syncope on rotation of head especially when wearing a shirt with tight collar or a tie with tight knot, condition called **carotid sinus syndrome**. Symptoms can be relieved by periarterial neurectomy.

Carotid body

It is a small oval structure situated behind the bifurcation of the common carotid artery. It is reddish-brown and receives

rich nerve supply from glossopharyngeal, vagus, and sympathetic nerves. It acts as a chemoreceptor and responds to the changes in the oxygen and carbon dioxide content of the blood. The excess of CO₂ and reduced O₂ tension in blood stimulates it causing increase in blood pressure and heart rate.

Ansa cervicalis (Figs 6.7 and 6.8)

The ansa cervicalis (ansa hypoglossi) is a U-shaped nerve loop present in the region of the carotid triangle embedded in the anterior wall of the carotid sheath. It is derived from

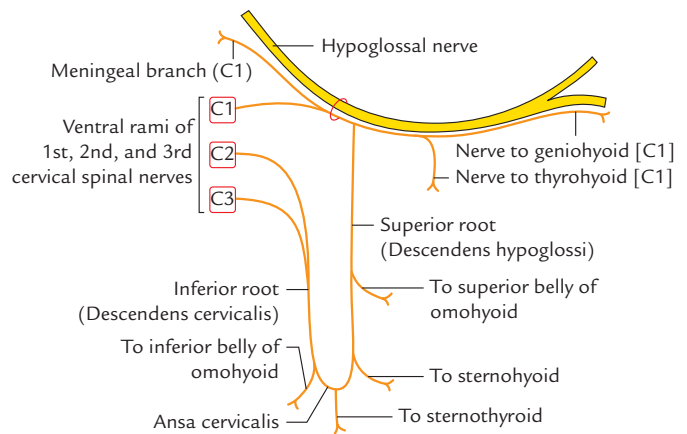


Fig. 6.7 Formation and distribution of the ansa cervicalis.

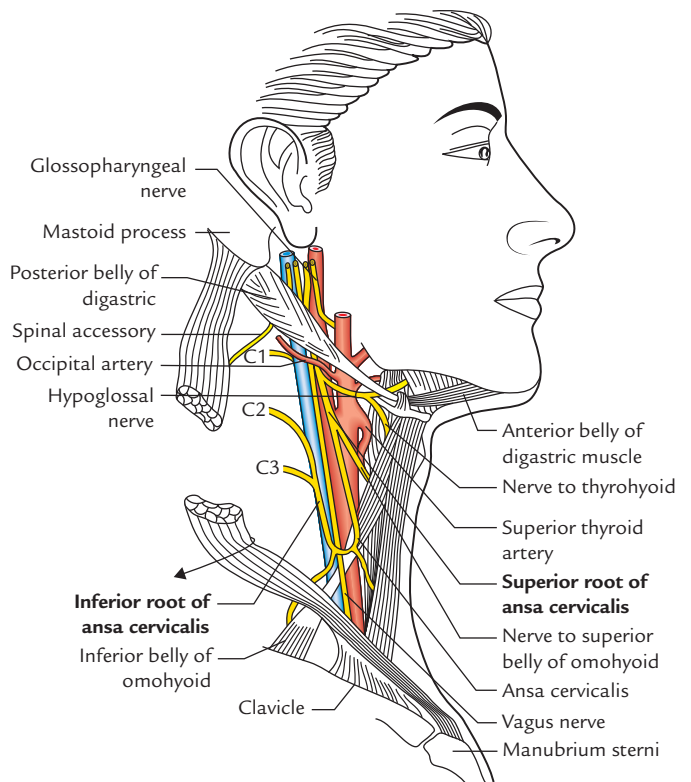


Fig. 6.8 Location and relations of the ansa cervicalis.

ventral rami of C1, C2, and C3 spinal nerves. It supplies all the infrahyoid muscles except thyrohyoid, which is supplied by nerve to thyrohyoid (C1) from hypoglossal nerve.

Roots: Ansa cervicalis has the following two roots:

1. **Superior root (descendens hypoglossi)** is formed by the descending branch of the hypoglossal nerve carrying C1 spinal nerve fibres. It descends downwards over internal and common carotid arteries.
2. **Inferior root (descendens cervicalis)** is derived from C2 and C3 spinal nerves. As this root descends, it first winds round the internal jugular vein and then continues anteroinferiorly to join the superior root in front of the common carotid artery at the level of cricoid cartilage.

Distribution

1. Superior root gives branch to superior belly of omohyoid.
2. Dependent loop gives branches to sternohyoid, sternothyroid, and inferior belly of the omohyoid.

Muscular Triangle (Figs 6.1 and 6.3)

Boundaries

- Anterior:** Anterior median line of the neck, extending from hyoid bone to the suprasternal notch.
- Anterosuperior:** Superior belly of the omohyoid.
- Posteroinferior:** Anterior border of sternocleidomastoid.

Floor

It is formed by sternothyroid, sternohyoid, and thyrohyoid muscles.

Roof

It is formed by investing layer of deep cervical fascia. The superficial fascia over the roof contains anterior jugular vein and associated lymph nodes.

Contents

Infrahyoid muscles, *viz.* sternothyroid, sternohyoid, and thyrohyoid.

The important deeper structures in the region of muscular triangle are thyroid gland, trachea, and esophagus. They are studied separately.

N.B. Supra and infrahyoid areas: These are the areas on the front of neck above and below the hyoid bone, respectively.

Suprahyoid area corresponds to submental triangle (for details see submental triangle on page 88).

Infrahyoid area is bounded superolaterally by the superior bellies of the omohyoid muscles and inferolaterally by the sternocleidomastoid muscles. It includes muscular triangles of both anterior triangles.

The infrahyoid area contains strap (ribbon-like) muscles of the neck. Underneath these muscles lie all important structures. From superficial to deep, these are:

1. Thyroid and parathyroid glands.
2. Larynx and trachea.
3. Hypopharynx (laryngopharynx) and esophagus.

SUPRAHYOID AND INFRAHYOID MUSCLES OF THE NECK

Suprahyoid Muscles of the Neck

The suprahyoid muscles comprise following four paired muscles.

1. Digastric.
2. Stylohyoid.
3. Mylohyoid.
4. Geniohyoid.

These muscles are described in detail in Chapter 9.

Infrahyoid Muscles of the Neck (Strap Muscles of the Neck)

The infrahyoid muscles are ribbon-like and comprise following four paired muscles (Fig. 6.9).

1. Sternothyroid.
2. Sternohyoid.
3. Thyrohyoid.
4. Omohyoid.

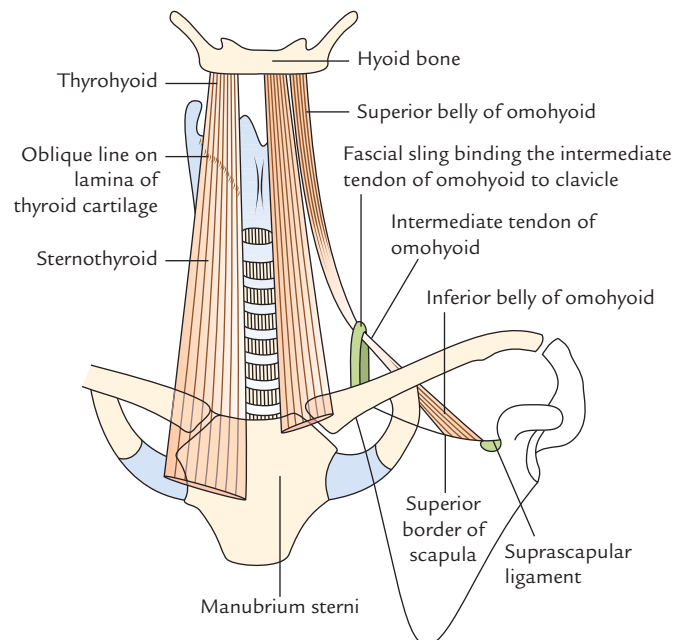


Fig. 6.9 Origin and insertion of the infrahyoid muscles.

Table 6.1 Origin, insertion, and actions of the infrahyoid muscles

Muscle	Origin	Insertion	Actions
Sternohyoid (thin narrow strap muscle)	Posterior surface of manubrium and adjoining part of clavicle, and posterior sternoclavicular ligament	Medial part of the lower border of the hyoid bone	Depresses hyoid bone following its elevation during swallowing
Sternothyroid (shorter and wider than sternohyoid)	Posterior surface of the manubrium and adjoining part of the first costal cartilage	Oblique line on the lamina of thyroid cartilage	Depresses the larynx following its elevation during swallowing
Thyrohyoid (It is an upward extension of the sternothyroid being broken by the oblique line on the thyroid lamina)	Oblique line on the lamina of thyroid cartilage	Lower border of the greater cornu and adjoining part of the body of the hyoid bone	<ul style="list-style-type: none"> Depresses the hyoid bone during swallowing Elevates the larynx when hyoid bone is fixed by suprahyoid muscles
Omohyoid consists of inferior and superior bellies united by an intermediate tendon	<ul style="list-style-type: none"> Inferior belly from upper border of scapula near the suprascapular notch and occasionally from superior transverse scapular ligament Superior belly proceeds upwards from the intermediate tendon almost vertically upwards near the lateral border of sternohyoid 	Lower border of the body of the hyoid bone lateral to the sternohyoid. The intermediate tendon is bound to the clavicle by a fascial pulley derived from investing layer of deep cervical fascia	Depresses the hyoid bone following its elevation during swallowing

N.B. Developmentally, the infrahyoid muscles are the derivatives of the longitudinal muscle sheet that extends vertically from the symphysis menti to pubic symphysis. This sheet ultimately divides into different segments; some of them disappear altogether. The remaining segments are represented by:

- geniohyoid, above the hyoid,
- infrahyoid muscles, between the hyoid and sternum,
- sternalis (occasional) in front of sternum, and
- rectus abdominis and pyramidalis (occasional) in the anterior abdominal wall.

The attachment of inferior belly of omohyoid to scapula is secondary to its migration from its initial attachment to medial end of the clavicle.

The infrahyoid muscles are arranged into two layers with two muscles in each layer, *viz.*

1. Superficial layer

- Sternohyoid
- Omohyoid.

2. Deep layer

- Sternothyroid
- Thyrohyoid.

Nerve Supply

All are supplied by ventral rami of C1, C2, and C3 spinal nerves.

The sternohyoid, omohyoid, and thyrohyoid are supplied by the ansa cervicalis and its superior root. The thyrohyoid is innervated directly by a branch from the hypoglossal nerve carrying fibres of ventral ramus of C1. The origin, insertion, and actions of individual muscles are presented in Table 6.1.

N.B. All the infrahyoid muscles depress the hyoid bone following its elevation during swallowing.

The thyrohyoid also elevates the larynx when the hyoid is fixed by the suprahyoid muscles.

Golden Facts to Remember

- | | |
|--|--|
| ▶ Most important pressoreceptor in the body | Carotid sinus |
| ▶ Most important landmark in the neck | Cricoid cartilage |
| ▶ Commonest site of tracheostomy | Retrothyroid (i.e. behind the isthmus of thyroid gland) |
| ▶ Carotid tubercle (Chassaignac's tubercle) | Prominent anterior tubercle of the transverse process of sixth cervical vertebra |
| ▶ Carotid pulse can be easily palpated | Just beneath the anterior border of sternocleidomastoid at the level of superior border of thyroid cartilage |
| ▶ All the strap muscles of the neck are supplied by the branches of ansa cervicalis except | Thyrohyoid muscle which is supplied by a branch of hypoglossal nerve carrying C1 fibres |
| ▶ Potato tumor | Tumor arising from carotid body (also called <i>carotid body tumor</i>) |
| ▶ Arteriosclerosis of common carotid and/or internal carotid artery can cause | Cerebrovascular ischemia (cerebral stroke) |

Clinical Case Study



CASE 1

A 35-year-old man complained to his physician that he is a victim of sudden attacks of syncope (fainting) from sudden rotation of his head especially when wearing a tight collar or tie. He was told by the physician that he was suffering from a disease called *carotid sinus syndrome* and a surgical procedure may be needed to relieve his symptoms.

Questions

1. What is carotid sinus?
2. What are the functions of carotid sinus?
3. Mention the nerve supply of the carotid sinus.
4. Mention the surgical procedure performed to relieve the symptoms.

Answers

1. It is a fusiform dilatation in the terminal part of common carotid artery and the commencement of internal carotid artery.
2. It is the main pressoreceptor of the body and regulates the blood pressure in the cerebral arteries.
3. (a) Carotid sinus branch of glossopharyngeal nerve.
(b) Twigs from vagus and cervical sympathetic chain.

4. Periarterial neurectomy.

CASE 2

A 75-year-old man visited his physician and complained that he is having a small painless swelling below his chin and his tip of tongue is ulcerated. On examination the physician found that the swelling was single and located in the submental triangle. It was hard mobile, and not attached to the skin.

Questions

1. What are the boundaries of the submental triangle?
2. Give the number of lymph nodes located in this triangle.
3. Name the structures drained by submental lymph nodes.
4. Name the veins which commence in the submental triangle.

Answers

1. Refer to submental triangle on page number 88.
2. Three or four.
3. Floor of mouth, incisor teeth, tip of tongue.
4. Anterior jugular veins.

Back of the Neck and Cervical Spinal Column

BACK OF THE NECK

The back of the neck is limited above by external occipital protuberance and superior nuchal lines, and below by spine of C7 vertebra and horizontal lines extending on either side from it to the acromial process of scapula.

The important structures on the back of the neck include ligamentum nuchae, extensor muscles of the neck, suboccipital triangle and arterial anastomosis around the semispinalis capitis.

The structures encountered in the suboccipital region during surgical procedure/dissection are shown in Figure 7.1.

Surface Landmarks

1. **External occipital protuberance:** It is a bony projection felt at the upper end of the **nuchal furrow**—a vertical groove in the midline on the back of the neck.
2. **Superior nuchal lines:** These are curved bony ridges passing laterally from external occipital protuberance. Their convexity faces upwards.
3. **Spine of 7th cervical vertebra:** It is knob-like bony projection felt at the lower end of the nuchal furrow. The spines of other cervical vertebrae are covered by *ligamentum nuchae* and hence cannot be felt.
4. **Acromion process:** It is felt as a bony edge immediately above the bulge of the deltoid muscle.

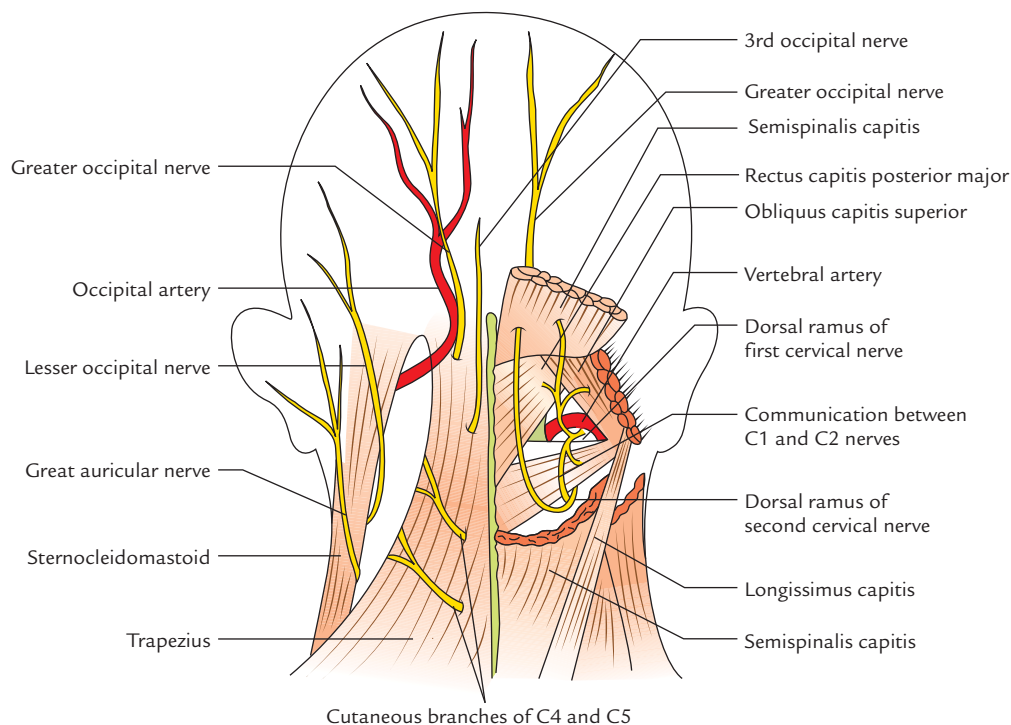


Fig. 7.1 Dissection of suboccipital region showing superficial structures on the left side and deep structures on the right side.

Soft Tissues on the Back of the Neck

The soft tissues on the back of the neck are divided into four layers. From superficial to deep these are:

1. Skin (cutaneous innervation).
2. Superficial fascia.
3. Deep fascia.
4. Muscles.

SKIN

The skin on the back of the neck is supplied by the medial branches of the dorsal rami of C2, C3, and C4 spinal nerves. (The dorsal ramus of the C1 does not divide into medial and lateral branches and does not give a cutaneous branch.)

The cutaneous nerves derived from the medial branches of dorsal rami of C2, C3, and C4 are (Fig. 7.1):

1. **Greater occipital nerve (C2):** It pierces the deep fascia on the level with the superior nuchal line 2.5 cm lateral to the external occipital protuberance and supply the posterior part of the scalp as far as the vertex. It is the **thickest cutaneous nerve** in the body.
2. **Third occipital nerve (C3):** It pierces the deep fascia medial to the greater occipital nerve, a little below the superior nuchal line. It is a small cutaneous nerve and supplies the skin of the nape of the neck up to the external occipital protuberance.
3. **Cutaneous branches of C4 and C5:** These branches pierce the deep fascia close to the midline in series with the 3rd occipital nerve. They supply the adjacent skin.

SUPERFICIAL FASCIA

The **superficial fascia** (subcutaneous tissue) of the back is thick and in spite of its fat content, it is very tough. It contains cutaneous nerves and vessels. The cutaneous nerves are greater occipital, third occipital, and cutaneous branch of C4 and C5 (described above).

The cutaneous vessels are **occipital artery** and minute twigs derived from second part of the vertebral artery. The occipital artery appears 2.5 cm from midline and accompanies the greater occipital nerve.

DEEP FASCIA

The deep fascia of the back is called **nuchal fascia**. It is attached in the median plane to the spines, supraspinous ligaments, and ligamentum nuchae. Extending laterally, it sheaths the muscles of the back.

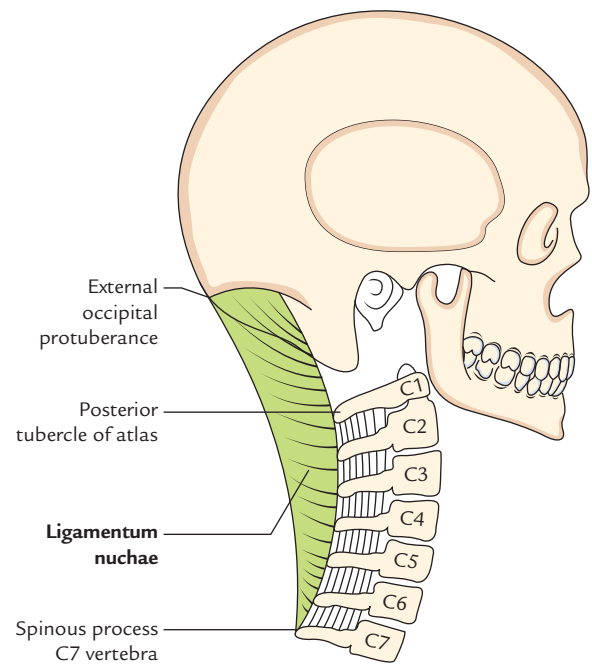


Fig. 7.2 Ligamentum nuchae.

LIGAMENTUM NUCHAE (Fig. 7.2)

It is a triangular sheet of fibroelastic tissue that forms the median fibrous septum between the muscles of the two sides of the back of the neck.

The ligamentum nuchae presents three borders:

1. **Superior border** attached to the external occipital crest.
2. **Anterior border** attached to the posterior tubercle of atlas and the spines of the cervical vertebrae (C2 to C7).
3. **Free posterior border**, which extends from the external occipital protuberance to the spine of the 7th cervical vertebrae.

N.B. In quadrupeds, the ligamentum nuchae is a well-developed powerful elastic structure, which supports the heavy head against the gravity. In human beings, it is not that powerful and contains little elastic tissue.

MUSCLES

The muscles of the back of the neck on either side of midline are arranged into **superficial and deep groups**:

1. **Superficial group:** The muscles of this group are arranged into two layers:
 - (a) *First (or superficial) layer*—consisting of trapezius muscle.
 - (b) *Second (or deep) layer*—consisting of levator scapulae, rhomboideus minor, and rhomboideus major.

2. **Deep group:** The muscles of this group form the **intrinsic musculature**. The intrinsic muscles are arranged in four layers; from superficial to deep, these are as follows:
- External layer*—consisting of splenius capitis and splenius cervicis muscles.
 - Intermediate layer*—consisting of longissimus capitis and longissimus cervicis muscles.
 - Deep layer*—consisting of semispinalis capitis and semispinalis cervicis muscles.
 - Deepest layer*—consisting of suboccipital muscles.

TRAPEZIUS (Fig. 7.3)

The trapezius is a large, flat, triangular muscle, which is placed superficially on the back of the neck and thorax. It forms the sloping ridge of the neck. The trapezius muscles of two sides together form the **trapezium** (Greek word meaning irregular four-sided figure), hence the name trapezius.

Origin: It arises from the medial third of the superior nuchal line, external occipital protuberance, ligamentum nuchae, spine of C7, and spines of all the thoracic vertebrae.

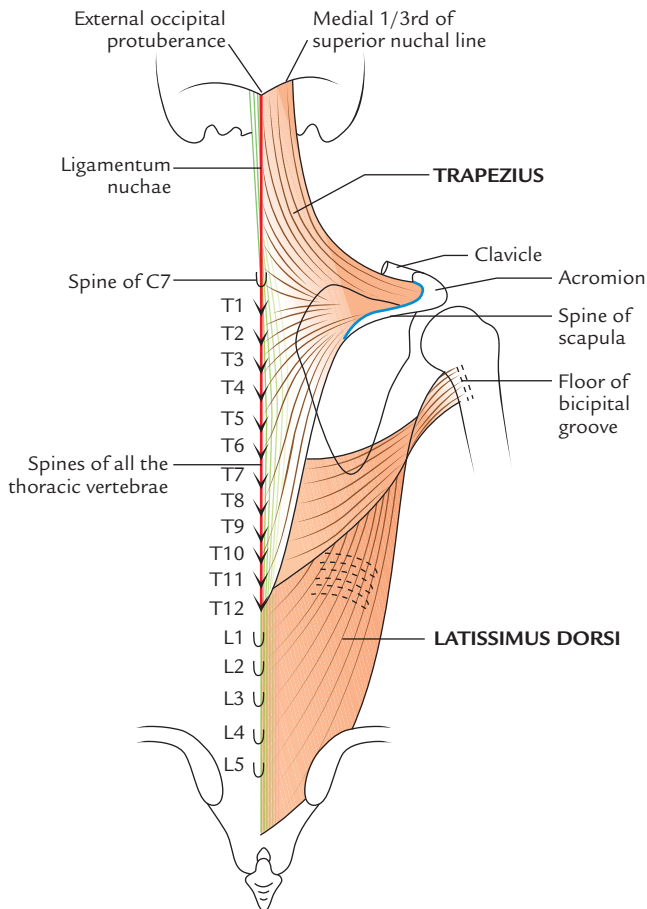


Fig. 7.3 Origin and insertion of the trapezius. The latissimus dorsi is also shown.

Insertion

- Upper fibres* sweep downwards to be inserted into the posterior border and upper surface of the lateral third of the clavicle.
- Middle fibres* run horizontally to be inserted into the medial border of the acromion and the upper lip of the spine of the scapula.
- Lower fibres* ascend to be inserted into the tubercle of the spine of the scapula near its root.

Nerve supply: Supplied by:

- Spinal accessory nerve (motor).
- Ventral rami of C3 and C4 (sensory).

Actions

- The uppermost fibres together with the levator scapulae elevate the shoulder and are thus responsible for shrugging the shoulder.
- The middle and lower parts of the muscles act with the rhomboids in retracting and steadying the scapula.

The muscles of second layer of superficial group are described in detail in the *Textbook of Anatomy: Upper Limb and Thorax, Vol. I* by Vishram Singh.

SPLENIUS CAPITIS MUSCLE (Fig. 7.4)

Origin: Arises from spines of 7th cervical and upper four thoracic vertebrae and lower portion of the ligamentum nuchae.

Insertion: Runs upwards and laterally, and emerges from beneath the trapezius in the posterior triangle and inserts into the mastoid process and lateral third of the superior nuchal line.

Nerve supply: Supplied by posterior rami of middle cervical nerves.

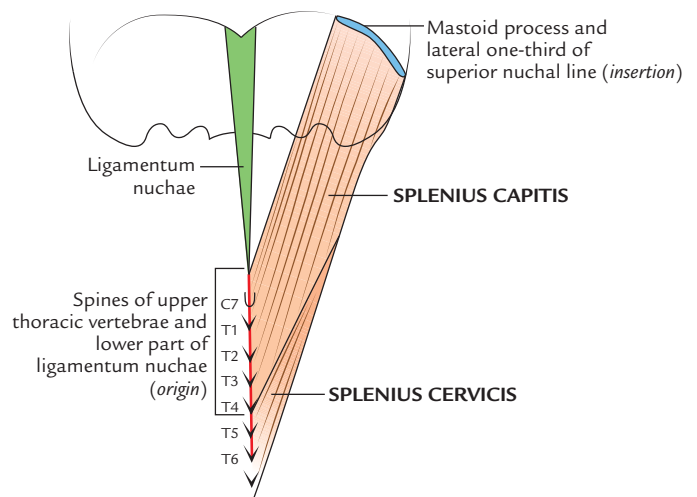


Fig. 7.4 Origin and insertion of the splenius capitis. The part of splenius cervicis is also seen.

Actions: Rotates the head and face to the same side. Acting bilaterally, they draw head backwards and extend the neck.

SPLenius CERVICIS MUSCLE

Origin: Arises from spines of T3–T6 thoracic vertebrae.

Insertion: Passes deep to splenius capitis, to be inserted into the transverse process of the upper four cervical vertebrae.

Nerve supply: Supplied by posterior rami of lower cervical nerves.

Actions: Turns the head and face towards the same side. Acting bilaterally, they extend the head and neck.

N.B. The splenius (splenius capitis and splenius cervicis together) lies deep to trapezius and sternocleidomastoid and superficial to semispinalis capitis and levator scapulae. It binds the deep extensors of the back of the neck like a bandage, hence the name splenius (L. *splenius* = bandage).

LONGISSIMUS CAPITIS MUSCLE (Fig. 7.5)

Origin: Arises from transverse processes of the lower four cervical vertebrae.

Insertion: Inserts into the mastoid process, deep to the splenius capitis.

Nerve supply: Supplied by posterior rami of lower cervical nerves.

Actions: It extends the head and turns the face to the same side.

SEMISPINALIS CAPITIS MUSCLE (Fig. 7.6)

It is long, thick powerful muscle and produces longitudinal bulging of the neck on each side of the median furrow. Its

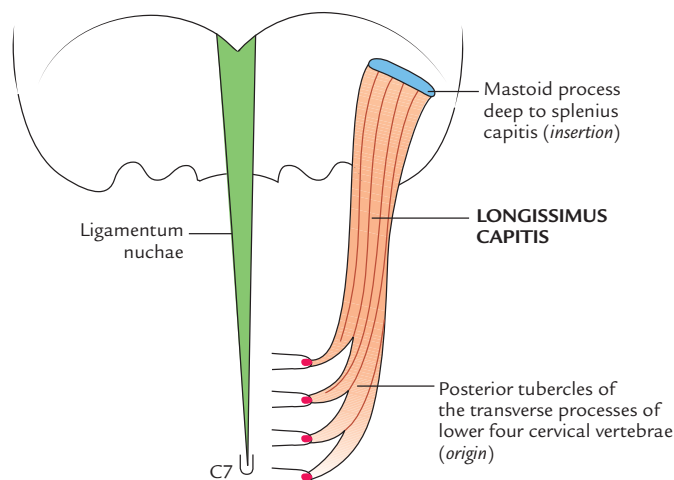


Fig. 7.5 Origin and insertion of the longissimus capitis.

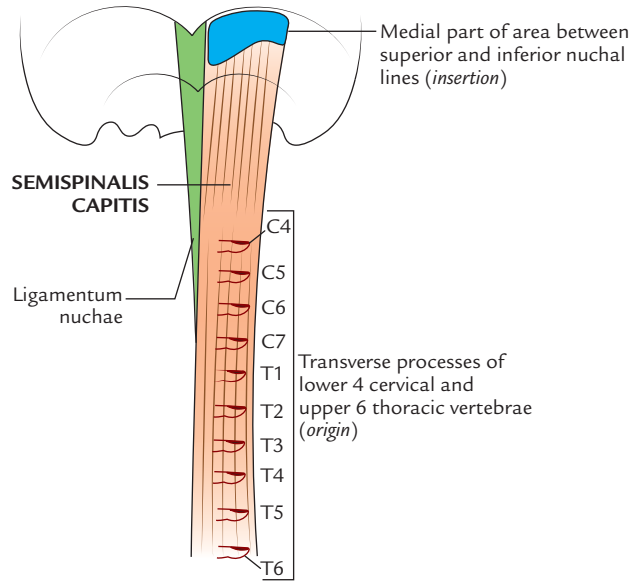


Fig. 7.6 Origin and insertion of the semispinalis capitis.

medial border is free and is in contact with the ligamentum nuchae (Fig. 7.6).

Origin: Arises from transverse processes of lower four cervical and upper six thoracic vertebrae (C4–T6).

Insertion: Runs vertically upwards and inserted into the medial part of the area between the superior and inferior nuchal lines of the occipital bones.

Nerve supply: Supplied by posterior rami of spinal nerves, usually by medial branches.

Actions: It extends the head.

SEMISPINALIS CERVICIS MUSCLE (Fig. 7.6)

It lies deep to the lower fibres semispinalis capitis.

Origin: Arises from transverse processes of lower cervical and upper thoracic vertebrae (C5–T4).

Insertion: Spines of cervical vertebrae (C2–C4).

Nerve supply: Supplied by posterior rami of spinal nerves, usually by medial branches.

Actions: It extends the neck.

Clinical correlation

Neck rigidity: The *neck rigidity* occurs in meningitis due to spasm of extensor muscles on the back of the neck. This is caused due to irritation of nerve roots of cervical spinal nerves during their passage through the subarachnoid space, which is infected in this disease.

SUBOCCIPITAL REGION

The suboccipital region is limited *above* by inferior nuchal line of occipital bone; *below* by massive spine and laminae of the axis vertebra; and *laterally* by the mastoid process and the transverse processes of atlas and axis vertebrae (Fig. 7.7). This region is clinically important because the neurosurgeons approach the posterior cranial fossa through this region.

N.B. This region lies beneath the semispinalis capitis, i.e., underneath the apex of the posterior triangle on the side of the neck. It is important to remember that posterior triangle spirals from front to back, as a result its apex lies on the back of the neck.

SUBOCCIPITAL MUSCLES

The suboccipital muscles (Fig. 7.8) are the short postural muscles that lie deep in the suboccipital region. They connect the 1st cervical vertebra (atlas) to the 2nd cervical vertebra (axis), and connect both these vertebrae to the base of the

skull. The suboccipital muscles cause extension of the head at the atlanto-occipital joints and rotation of head and atlas on the axis. They can act as extensors and rotators of the head but they function chiefly as postural muscles.

On each side, the following four muscles comprise the suboccipital group of muscles:

1. Rectus capitis posterior major.
2. Rectus capitis posterior minor.
3. Obliquus capitis inferior.
4. Obliquus capitis superior.

All these muscles are supplied by the dorsal ramus of C1 spinal nerve (*suboccipital nerve*). The origin, insertion, nerve supply, and actions of these muscles are enumerated in Table 7.1.

Clinical correlation

The posterior cranial fossa is approached by neurosurgeons to remove the brain tumor by clearing the suboccipital muscles and removing the exposed occipital bone.

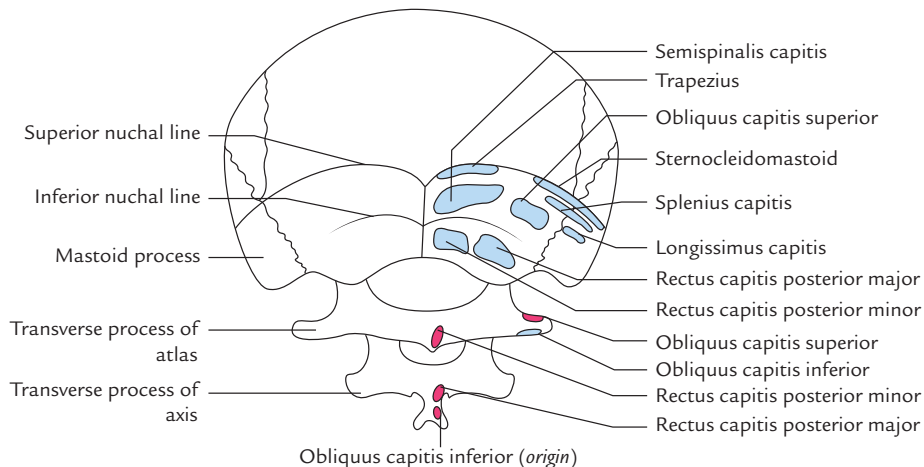


Fig. 7.7 Schematic posterior view of the skull, showing bony boundaries of suboccipital region and sites of the muscular attachments.

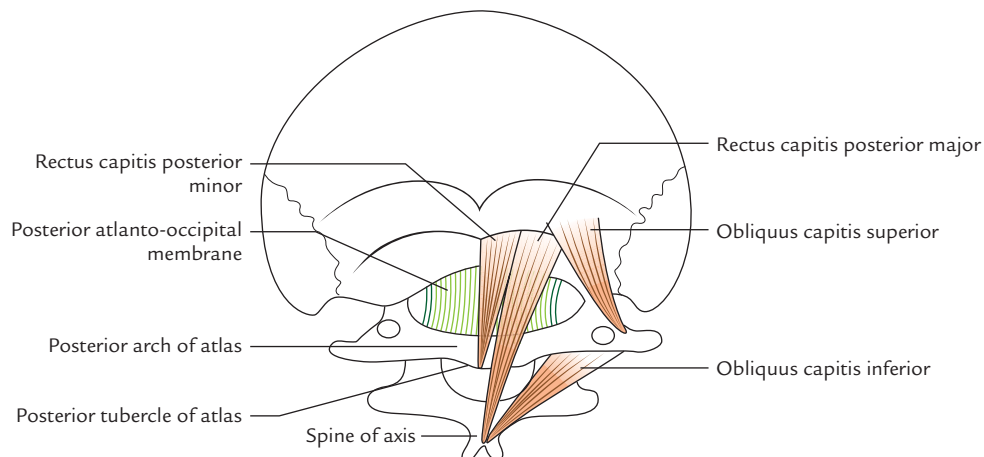


Fig. 7.8 Suboccipital muscles. Boundaries and floor of the suboccipital triangle are also seen.

Table 7.1 Suboccipital muscles

Muscles	Origin	Insertion	Actions
Rectus capitis posterior major	From spine of axis by a pointed tendon	Passes upwards and laterally, and inserted by a broad base to the lateral part of the inferior nuchal line and area of bone below it	Extends the head at atlanto-occipital joint
Rectus capitis posterior minor (two minor muscles, one on each side, fills the triangular gap between diverging major muscles)	From posterior tubercle of the atlas	Passes upwards to be inserted into the medial part of the inferior nuchal line and area of bone below it	Extend the head at the atlanto-occipital joint
Obliquus capitis inferior	From spine of the axis	Passes laterally and slightly upwards to be inserted into the transverse process of the atlas	Rotates the head to the same side at the atlantoaxial joint
Obliquus capitis superior	From transverse process of the atlas	Passes upwards and backwards to be inserted into area between superior and inferior nuchal lines of the occipital bone, lateral to the semispinalis capitis. Here it overlies the insertion of rectus capitis posterior major	Rotates the head to the same side (lateral flexion) at atlanto-axial joint. Acting along with its counterpart of the opposite side, they extend the head at the atlanto-occipital joint

SUBOCCIPITAL TRIANGLE (Figs 7.8 and 7.9)

This is a triangular muscular space situated deep in the suboccipital region of the neck, one on each side of the midline and bounded by four suboccipital muscles.

Boundaries (Fig. 7.8)

Superomedial: Rectus capitis posterior major, supplemented by rectus capitis posterior minor.

Superolateral: Obliquus capitis superior.

Inferior: Obliquus capitis inferior.

Roof: This is formed by dense fibrous tissue, and covered by semispinalis capitis laterally and longissimus capitis and splenius capitis (occasionally) laterally.

Floor: The floor is formed by (a) posterior arch of atlas and (b) posterior atlanto-occipital membrane.

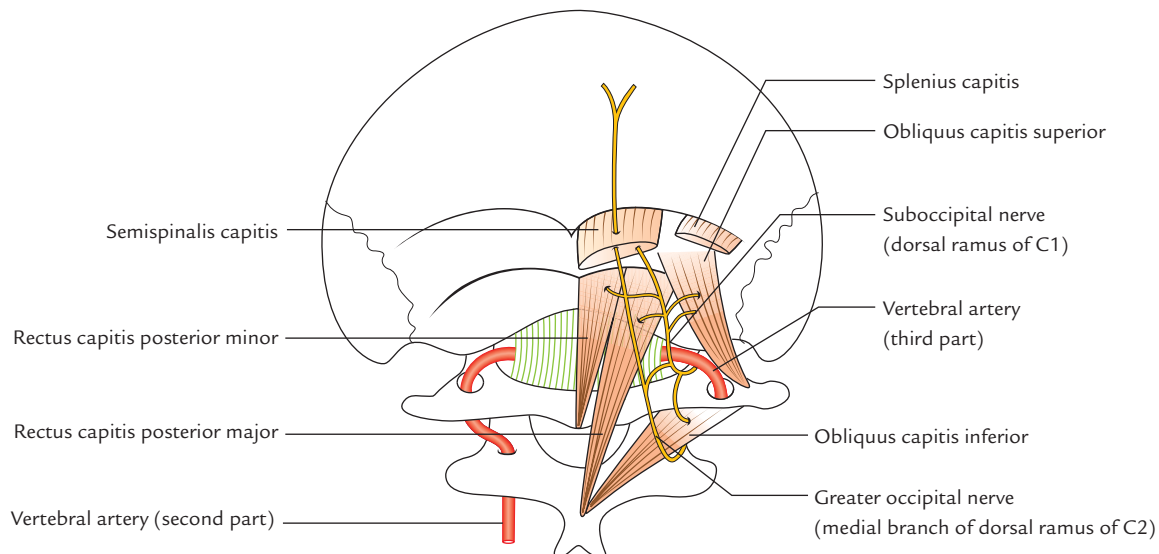


Fig. 7.9 Boundaries and contents of the suboccipital triangle.

Contents

The contents of suboccipital triangle are as follows:

1. Suboccipital plexus of veins.
2. Greater occipital nerve.
3. Dorsal ramus of 1st cervical nerve (suboccipital nerve).
4. Third part of vertebral artery.

N.B. The vertebral artery and the dorsal ramus of the 1st cervical nerve lie in a groove on the upper surface of the posterior arch of the atlas. Here artery is separated from arch by the nerve.

Clinical correlation

Cisternal puncture is done when lumbar puncture fails to take out CSF sample for therapeutic and diagnostic purposes. Needle is introduced in the midline just above the spine of the axis vertebra. It pierces the posterior atlanto-occipital membrane at a depth of about 2 inch/5 cm in adults. Utmost care should be taken while introducing the needle as medulla lies only 1 inch anterior to the posterior atlanto-occipital membrane which, if damaged, may be fatal.

Suboccipital plexus of the veins

It lies in and around the suboccipital triangle. It connects the following veins:

1. Muscular veins from neighboring six muscles.
2. Occipital veins.
3. Internal vertebral venous plexus.
4. Condylar emissary vein from sigmoid sinus.
5. Deep cervical vein.
6. Plexus of the veins around vertebral artery.

Thus it provides a number of alternative routes for venous drainage.

Clinical correlation

The connection between suboccipital venous plexus and internal vertebral venous plexus serves as a path of intracranial infection in *carbuncles of the neck*.

The *carbuncle* is an infective gangrene of subcutaneous tissue following infection of hair follicles.

Greater occipital nerve

It is the thickest cutaneous nerve in the body. It winds around the middle of the lower border of the inferior oblique muscle, and runs upwards and medially. It crosses the suboccipital triangle and pierces the semispinalis capitis and trapezius muscles to supply the back of scalp up to the vertex.

Occipital artery in the suboccipital region

The occipital artery runs deep to the mastoid process and muscles attached to it, e.g., sternocleidomastoid, splenius

capitis and longissimus capitis. The artery then crosses the rectus capitis lateralis, the superior oblique, and semispinalis capitis muscles at the apex of the posterior triangle. Finally, it pierces the trapezius 2.5 cm away from the midline and comes to lie along the greater occipital nerve. It presents a tortuous course in the superficial fascia of the scalp.

Its branches in the region are (a) mastoid, (b) meningeal, and (c) muscular.

Arterial anastomosis around semispinalis capitis muscle

One of the muscular branches is biggest—the **descending branch**, which divides into superficial and deep branches.

The superficial branch anastomoses with the superficial branch of the transverse cervical artery superficial to the semispinalis capitis. The deep branch anastomoses with deep cervical artery, a branch of costocervical trunk deep to the semispinalis capitis.

Thus, this *arterial anastomosis around the semispinalis capitis* is between external carotid artery (via occipital artery) and subclavian artery (via transverse cervical and costocervical trunk).

Third part of the vertebral artery

The third part of the vertebral artery appears in the suboccipital triangle through foramen transversarium of the atlas vertebra. After emerging from the foramen, the artery winds backwards and medially behind the lateral mass of the atlas; lodges in a groove on the upper surface of its posterior arch, and finally leaves the triangle by passing deep to the thick lateral edge of the posterior atlanto-occipital membrane (oblique ligament of atlas) to enter the vertebral canal where it continues as the fourth part of the vertebral artery.

The vertebral artery is separated from the posterior arch of the atlas by the 1st cervical nerve and its dorsal and ventral rami.

Clinical correlation

The tortuous course of the third part of the vertebral artery in this region may serve to damp down the arterial pulsations within the cranial cavity.

But if it is affected by atheroma, movements of the head and neck may affect the flow of blood through it and cause temporary fainting or unconsciousness.

First cervical nerve: The 1st cervical nerve while passing behind the lateral mass of atlas divides into dorsal and ventral rami (Fig. 7.10):

1. The **dorsal ramus** (also called *suboccipital nerve*) emerges backwards between the vertebral artery and the posterior arch of the atlas and soon breaks up into five muscular branches to supply four suboccipital muscles (rectus capitis posterior major, rectus capitis posterior minor, obliquus capitis superior, and

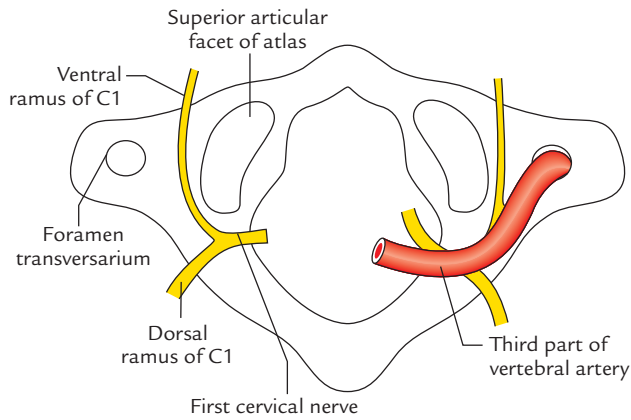
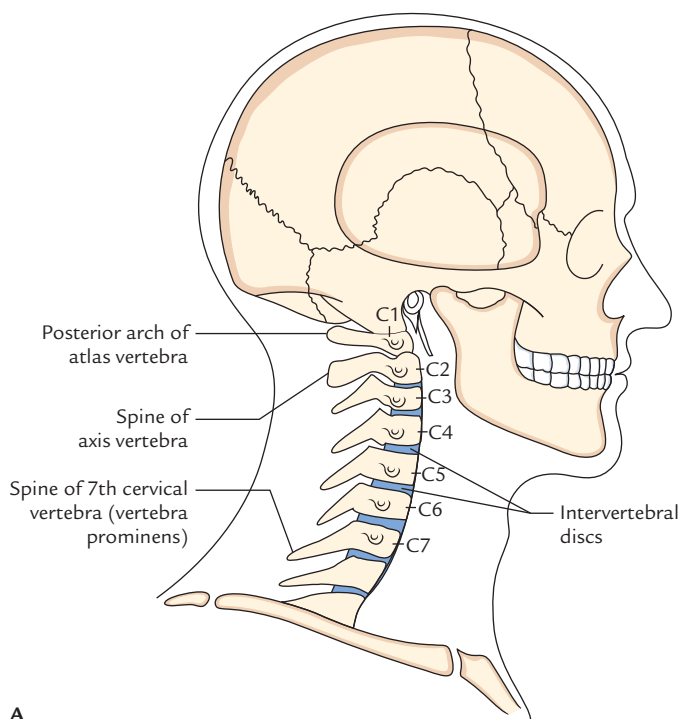


Fig. 7.10 Relationship of the third part of vertebral artery and first cervical nerve to the atlas vertebral as seen from the superior aspect.

obliquus capitis inferior) and semispinalis capitis. The branch to inferior oblique joins the **greater occipital nerve**. It usually does not give any cutaneous branch (cf. unlike other spinal nerves, the 1st cervical spinal nerve has no sensory root).

2. The **ventral ramus** winds forwards around the lateral mass and lies medial or deep to the artery. It then descends in front of the root of the transverse process of the atlas between rectus capitis lateralis and rectus capitis anterior, which it supplies. Thereafter, it joins the ventral ramus of C2 to take part in the formation of cervical plexus.



A

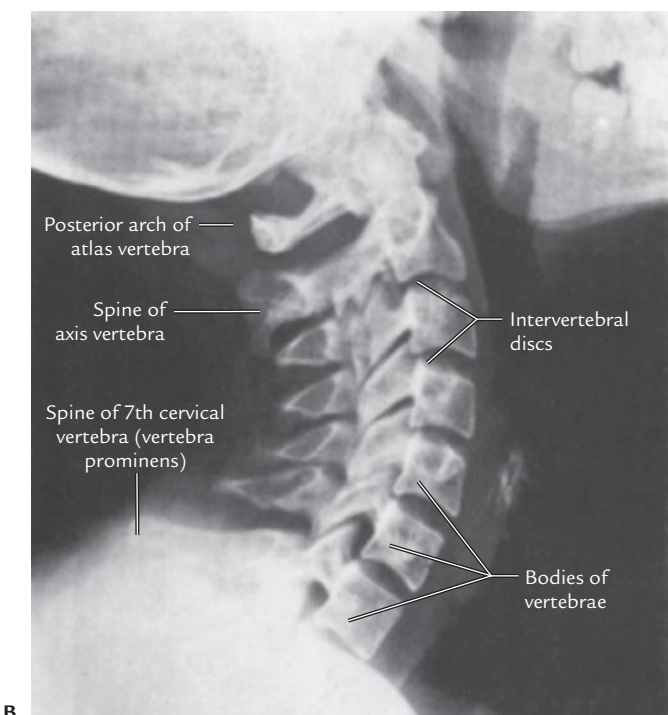
CERVICAL SPINAL COLUMN AND JOINTS OF THE NECK

The cervical spinal column (Fig. 7.11) is generally referred to as **cervical spine** by the clinicians. It consists of 7 cervical vertebrae and the intervening intervertebral discs. It is convex anteriorly. The cervical spine is a bony pillar of the neck, which supports the skull and transmits the weight. Within its cavity lies the spinal cord, roots of spinal nerves, and covering meninges to which it provides protection. Because it is segmented, being made up of vertebrae and pads of fibrocartilage (intervertebral discs), it is a flexible structure and responsible for the mobility of the neck.

Most of the problems on the back of the neck are due to involvement of cervical vertebrae and their joints. Therefore, it is very important for medical students to understand the anatomy of cervical spinal column in detail (also see the chapter on vertebral column in, *General Anatomy* by Vishram Singh).

CERVICAL VERTEBRAE

Cervical vertebrae (Fig. 7.11) are seven in number and numbered from above downwards. They are characterized by the presence of foramen in each of their transverse processes called **foramen transversarium**. It transmits vertebral artery (Fig. 7.12), *except* for 7th cervical vertebra. First cervical vertebra is called **atlas** and the skull rests on it.



B

Fig. 7.11 Cervical vertebral column: A, schematic diagram; B, lateral radiograph.

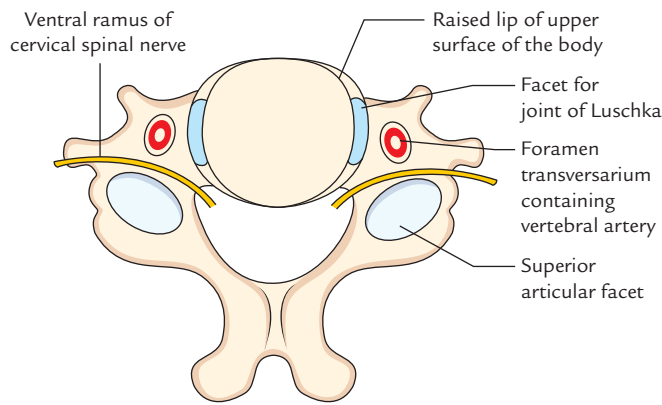


Fig. 7.12 Typical cervical vertebra (superior aspect).

It is named after mythological Greek Titan who was reputed to support the heavens on his shoulders. The 2nd cervical vertebra is called **axis**, because its odontoid process forms a pivot around which atlas rotates and carries the skull. The atlas and axis are specialized vertebrae. The *atlas has neither body nor spine*. It is ring-like and consists of two lateral masses, connected by a short anterior arch and long posterior arch (Fig. 2.29B). The axis possesses, tooth-like odontoid process which projects upwards from the body. *The 3rd–6th cervical vertebrae are regarded as typical vertebrae*. The cervical vertebrae are described in detail in Chapter 2.

JOINTS OF THE NECK

The joints of the neck include intervertebral joints between the lower 6 cervical vertebrae and craniovertebral joints. The joints between the lower 6 cervical vertebrae are *typical cervical joints*. These are similar to those in the other parts of the vertebral column. They permit flexion, extension, and lateral bending but little rotation. The joints between 1st and 2nd cervical vertebrae and those between 1st cervical vertebrae and skull permit rotation and nodding of head, respectively. The joints of neck are clinically important due to high incidence of spondylosis, disc prolapse, and fracture dislocation in the cervical region.

TYPICAL CERVICAL JOINTS

These are the joints between lower 6 cervical vertebrae.

They include joints between the vertebral bodies, vertebral arches, and vertebral articular processes.

Joints Between the Vertebral Bodies

They are of two types, *viz.*

1. Secondary cartilaginous (intervertebral disc) between the bodies of adjacent vertebrae.

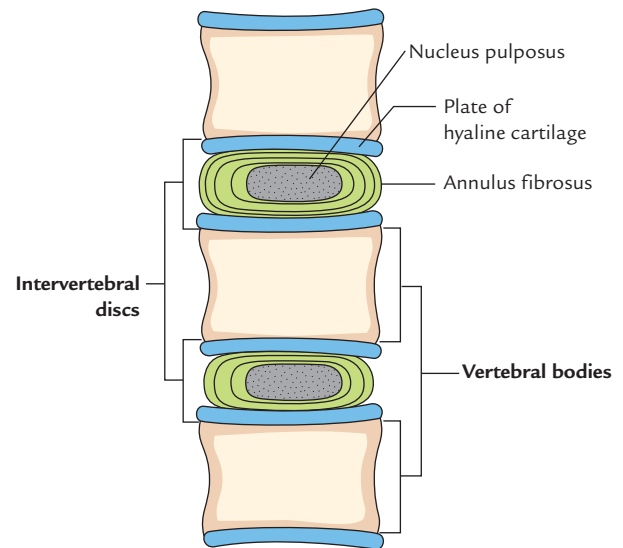


Fig. 7.13 Secondary cartilaginous joints (symphyses) between the vertebral bodies.

2. Synovial (joints of Luschka), between the lateral margins of the bodies of adjacent vertebrae.

Secondary Cartilaginous Joints (Fig. 7.13)

These are articulations between two bodies of adjacent vertebrae from 2nd to 7th cervical vertebrae.

The adjacent articular surfaces are covered by the plates of hyaline cartilage and held together by an intervertebral disc.

The disc is fibrocartilaginous in nature. It consists of an outer part formed by a series of fibrocartilaginous laminae called **annulus fibrosus** and an inner part consisting of jelly-like material called **nucleus pulposus**. The most peripheral laminae of annulus fibrosus are formed of pure collagenous tissue and on the front and on the back they blend with strong anterior and the weak posterior longitudinal ligaments. The discs are firmly bound to the edges of the hyaline cartilages and bodies of the vertebrae. The intervertebral discs are thick anteriorly in the cervical region contributing to the anterior convexity of the neck. No discs are found between the first two cervical vertebrae.

The intervertebral disc along with hyaline cartilage covering the upper and lower articular surfaces of the adjoining vertebral bodies form the **intervertebral symphysis**.

Ligaments

Anterior longitudinal ligament (Fig. 7.14): It extends anterior to the anterior arch of atlas and bodies of remaining cervical vertebrae. It is a strong ligament and consists of long and short fibres. The long fibres are superficial and bridge across several vertebrae whereas short fibres are deep and bridge across a single pair of vertebrae, and blend with the annulus fibrosus of the intervertebral disc.

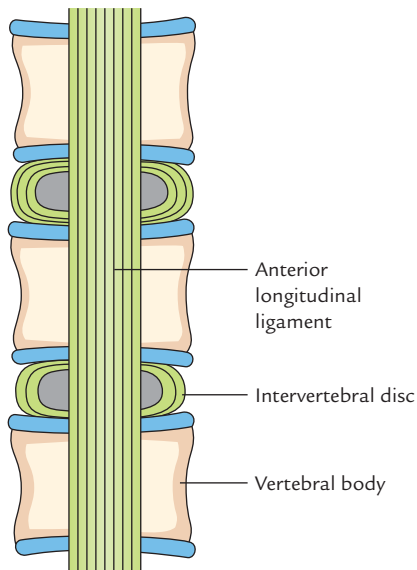


Fig. 7.14 Anterior longitudinal ligament.

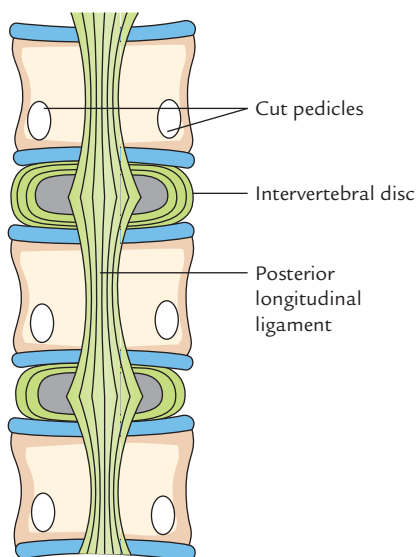


Fig. 7.15 Posterior longitudinal ligament.

Posterior longitudinal ligament (Fig. 7.15): It runs longitudinally across the posterior surfaces of the cervical vertebrae and hence situated within the vertebral canal. Above, it is attached to the body of C2 (axis) vertebra and continues above as **membrana tectoria**. It is fairly wide where it is attached to the intervertebral discs but narrow over the bodies. It is loosely attached to the bodies to provide space for **basivertebral veins** and **paravertebral venous plexus**.

It is weaker than anterior longitudinal ligament. Its superficial long fibres bridge across three or four vertebrae whereas its short deep fibres extend between adjacent vertebrae as **perivertebral ligaments** and are attached to annulus fibrosus of the disc.

Clinical correlation

Prolapse of intervertebral disc in the cervical region: It usually involves the disc between C5 and C6 or C6 and C7. The nucleus pulposus generally herniates in the posterolateral direction and compresses a nerve root. The herniated disc between C5 and C6 compresses C6 nerve root, hence patient feels pain in the thumb, whereas herniated disc between C6 and C7 compresses C7 nerve root and consequently there is pain, tingling and numbness on the posterior aspect of arm, forearm, and middle and index fingers.

Joints of Luschka (also called *uncovertebral joints*)

The lateral margins of vertebral bodies overlap the sides of intervertebral disc and directly articulate to form small synovial joints of plane variety called **joints of Luschka**.

Clinical correlation

Cervical spondylosis: It is the most common clinical condition affecting the neck. Degenerative changes appear in the cervical spine, often during the third or fourth decade. The disc space between the 5th and 6th cervical vertebrae is most frequently affected. The earliest changes are confined to the intervertebral disc but the facet joints and uncovertebral joints (joints of Luschka) get involved soon.

The joints of Luschka are the commonest sites of formation of **osteophytes**. Since cervical nerve roots lie posterolateral to these joints, they are often compressed by the osteophytes leading to pain along their distribution. The foramina transversaria containing vertebral artery lie lateral to these joints, hence osteophytes can also cause distortion of vertebral artery leading to **vertebrobasilar insufficiency** which clinically presents as dizziness and allied symptoms following jerky neck movements.

Joints Between the Vertebral Arches

Joints between the vertebral arches include:

1. Joints between the articular processes of vertebrae (zygapophyseal joints).
2. Intervertebral syndesmoses between laminae, spines, and transverse processes.

Zygapophyseal Joints (also called *facet joints*)

These are joints between the superior and inferior articular processes of adjacent vertebrae (Fig. 7.16).

Type

These are synovial joints of plane variety. The articular surfaces are covered by hyaline cartilage.

The articular surfaces are inclined horizontally and slope inferiorly from anterior to posterior. This allows rotation of neck to look sideways and upwards.

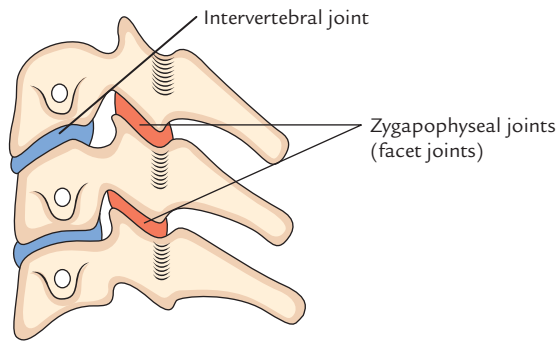


Fig. 7.16 Zygapophyseal joints between the superior and inferior articular processes of adjacent vertebrae.

Ligaments

Fibrous capsule: It is thin and loose, and attached to the periphery of articular facets.

Movements

Permits side-to-side rotation of the neck.

Clinical correlation

Dislocation of vertebrae without fracture: It occurs only in cervical region because of the inclination of the articular surfaces of articular processes. In thoracic and lumbar regions, dislocations are always associated with fracture of articular processes.

The dislocations mostly occur between 4th and 5th or between 5th and 6th cervical vertebrae.

Intervertebral Syndesmoses

Between the adjacent laminae (Fig. 7.17): *Ligamenta flava* connect the laminae of adjacent vertebrae. They extend from lower border of lamina above to the upper border of the lamina below in the vertebral canal. They are predominantly made up of yellow elastic tissue.

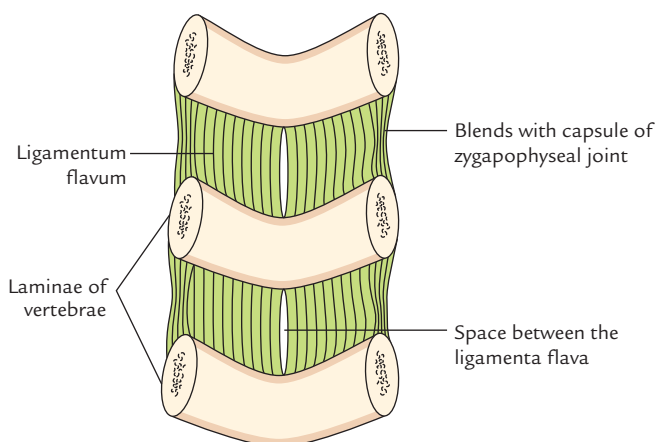


Fig. 7.17 Ligamenta flava (anterior aspect).

The ligamenta flava prevent the separation of laminae in spinal flexion and help to restore the erect posture after flexion thus protecting the disc from the injury.

Between the adjacent spines: *Interspinous ligament* connects the adjacent spines and *supraspinous ligaments* connect the tips of spinous processes.

Between the adjacent transverse processes: The *intertransverse ligaments* connect the adjacent transverse processes. They are very weak in cervical region and largely replaced by intertransverse muscles.

Nerve Supply of the Intervertebral Joints

All intervertebral joints are innervated by adjoining spinal nerves, particularly by their posterior divisions.

Movements of the Cervical Spinal Column

Movements of cervical spinal column include:

1. Flexion.
2. Extension.
3. Lateral flexion.
4. Rotation.

Flexion is forward whereas **extension** is a backward movement. Both these movements have extensive range of motion.

Lateral flexion is the bending of the neck to one or the other side with extensive range of motion.

Rotation is a twisting movement with greater degree of freedom.

Circumduction is the combination of all the aforementioned movements.

N.B. All these movements are enhanced by movements occurring at craniovertebral joints.

CRANIOVERTEBRAL JOINTS

These articulations take place between occipital condyles, atlas, and axis (Fig. 7.18).

All these articulations together act as a universal joint, permitting horizontal and vertical scanning movements of the head, superbly adapted for eye and head coordination.

The craniovertebral joints include:

1. Atlanto-occipital joints.
2. Atlantoaxial joints.

Atlanto-occipital Joints (Fig. 7.18)

These are two atlanto-occipital joints, one on either side between the atlas vertebra and occipital bone.

Type

These are synovial joints of **ellipsoidal variety**.

Articular surfaces

Above: Convex articular surface of occipital condyles.

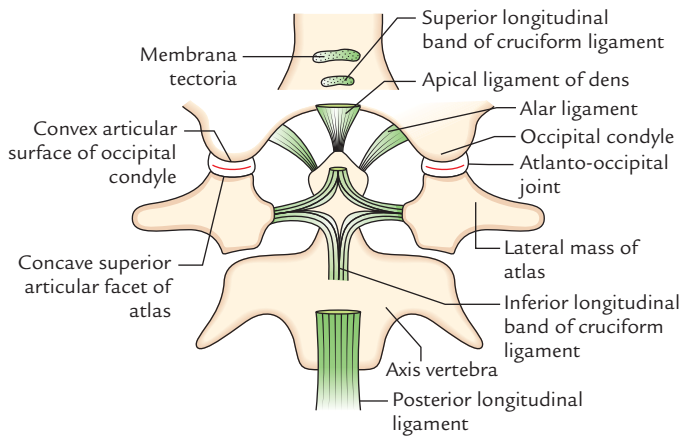


Fig. 7.18 Posterior view of the ligaments connecting the axis with occipital bone. The superior band of cruciform ligament is cut.

Below: Concave superior articular facets of the atlas (cervical vertebra). They are elongated and kidney shaped with the constrictions in the middle. They are directed medially and forward. Thus the superior and inferior articular surfaces are reciprocally curved.

Ligaments

1. **Fibrous capsule (capsular ligament):** It surrounds the joint and is attached to the margins of the articular surfaces. It is thick posterolaterally and thin posteromedially.
2. **Accessory ligaments**
 - (a) *Anterior atlanto-occipital membrane*
 - It is attached below to the anterior arch of the atlas and above to the anterior margin of the foramen magnum.
 - It fuses with the fibrous capsule laterally and is strengthened by cord-like anterior longitudinal ligament anteriorly.
 - (b) *Posterior atlanto-occipital membrane*
 - It is attached below to the upper border of the posterior arch of the atlas and above to the posterior margin of the foramen magnum. Inferolaterally it arches over a groove on the upper surface of the posterior arch of atlas for vertebral artery and 1st cervical nerve.

Arterial supply

By vertebral artery.

Nerve supply

By 1st cervical nerve.

Movements

Since these are ellipsoid joints, the movements are permitted in transverse as well as in anteroposterior axes. The movements are listed in Table 7.2.

Table 7.2 Movements occurring at atlanto-occipital joints

Movement	Axis	Muscles responsible for movements
Flexion and extension (nodding or yes movements)	Transverse	<i>Flexion by:</i> longus capitis and rectus capitis anterior <i>Extension by:</i> (a) Rectus capitis posterior major and minor (b) Semispinalis capitis (c) Splenius capitis (d) Upper part of the trapezius
Lateral flexion (slight)	Anteroposterior	Rectus capitis lateralis

Clinical correlation

The **line of gravity of the weight of the head** (about 7 lbs) passes in front of the atlanto-occipital joints. Therefore, position of head in erect position is maintained by the traction caused by the extensor muscles, particularly by semispinalis capitis. Thus semispinalis muscle is responsible for keeping the head in proper position (Fig. 7.6).

Atlantoaxial Joints

Three well-separated joints are formed between the atlas and the axis, viz.

1. Median atlantoaxial joint.
2. Two lateral atlantoaxial joints.

N.B. All these joints function as one unit to produce the movement of rotation of atlas with head around the vertical axis.

Median Atlantoaxial Joint (Fig. 7.19)

Type

It is a synovial joint of **pivot variety**. It is formed between the dens of axis and osseoligamentous ring formed by anterior arch and transverse ligament of the atlas.

Articular surfaces

1. Odontoid process of axis.
2. Anterior arch and transverse ligament of atlas.

There are two articulations—anterior and posterior—with separate synovial cavities.

Anteriorly, the vertically oriented oval facet on the anterior surface of dens articulates with a similar facet on the posterior surface of the anterior arch of the atlas.

Posteriorly, the cartilaginous anterior surface of transverse ligament of atlas articulates with the horizontally oriented ovoid facet on the posterior surface of the base of the dens.

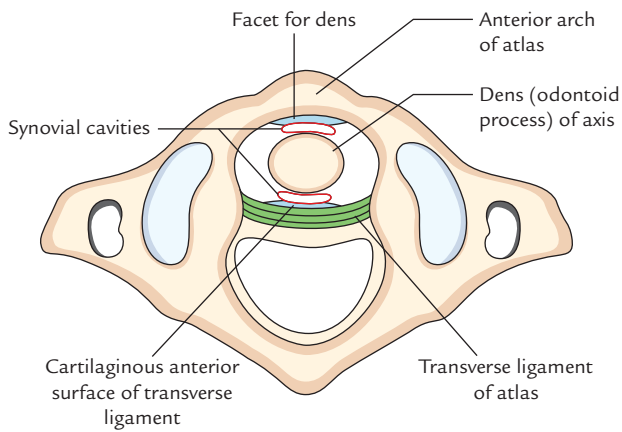


Fig. 7.19 Median atlantoaxial articulation.

Ligaments

1. **Fibrous capsule:** It is loose and surrounds the anterior joint. It is attached around the margins of the articular facets. It is lined by synovial membrane.
2. **Transverse ligament:** It is attached on each side to the medial surface of the lateral mass of the atlas. In the median plane its fibres are prolonged: (a) upwards to the basiocciput and (b) downwards to the body of the axis, thus forming the **cruciform ligament of the atlas**. The transverse ligament embraces the narrow neck of the dens and prevents its backward dislocation. A synovial bursa is interposed between the transverse ligament and dens. It is said to be the large posterior part of the median atlantoaxial joint.
3. **Ligaments connecting the axis with the occipital bone**
 - (a) *Apical ligament of the dens* (Fig. 7.20) extends from tip of odontoid process to the upper surface of the basilar part of the occipital bone near the foramen magnum.

Morphologically it represents the remnant of the notochord (cf. Nucleus pulposus).

- (b) *Alar ligaments*, one on each side, extend from the upper part of the dens (on side of the tip) to the tubercle on the medial aspect of the occipital condyle. These ligaments are very strong and check excessive rotation and flexion of head. They are, therefore, called *check ligaments*.
- (c) *Membrana tectoria* (Fig. 7.20) is an upward continuation of the posterior longitudinal ligament. It lies posterior to the transverse ligament of the atlas. Inferiorly, it is attached to the posterior surface of the body of the axis and superiorly to the upper surface of the basilar part of the occipital bone above the attachment of upper band of the cruciform ligament.
- (d) *Cruciform or cruciate ligament* (see transverse ligament).

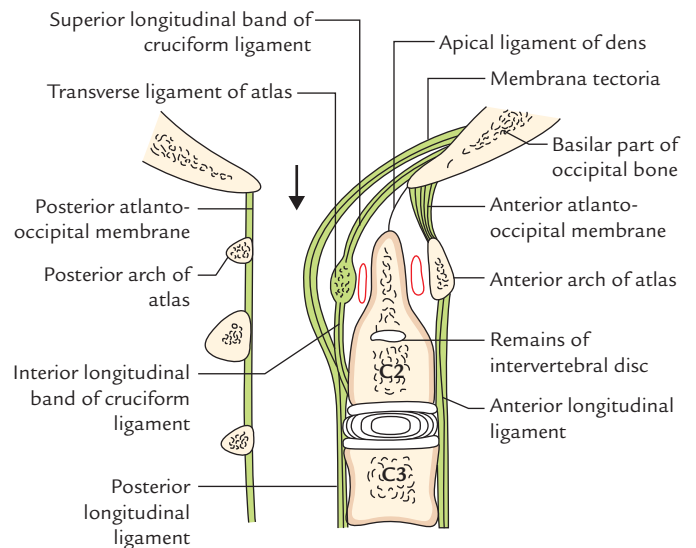


Fig. 7.20 Median sagittal section through the foramen magnum and 1st–3rd cervical vertebrae.

Lateral Atlantoaxial Joints

These are paired, one on each side.

Type

Synovial joint of **plane variety**.

Articular surfaces

Above: Inferior facet of the lateral mass of the atlas. It is flat.

Below: Superior articular facet of axis. It is also flat, thus superior and inferior articular facets are reciprocally curved.

Capsules: It is attached to the margin of articular surfaces. It is supported by anterior longitudinal ligament and ligamentum flavum.

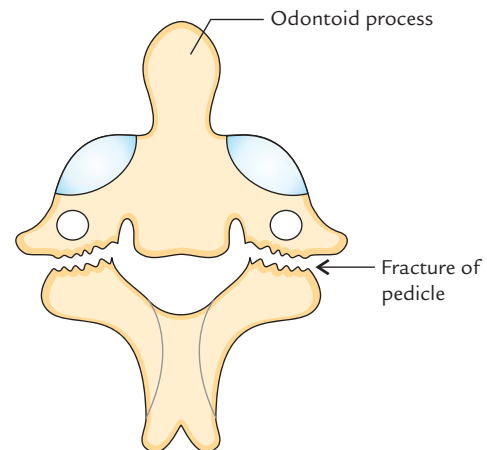


Fig. 7.21 Hangman's fracture.

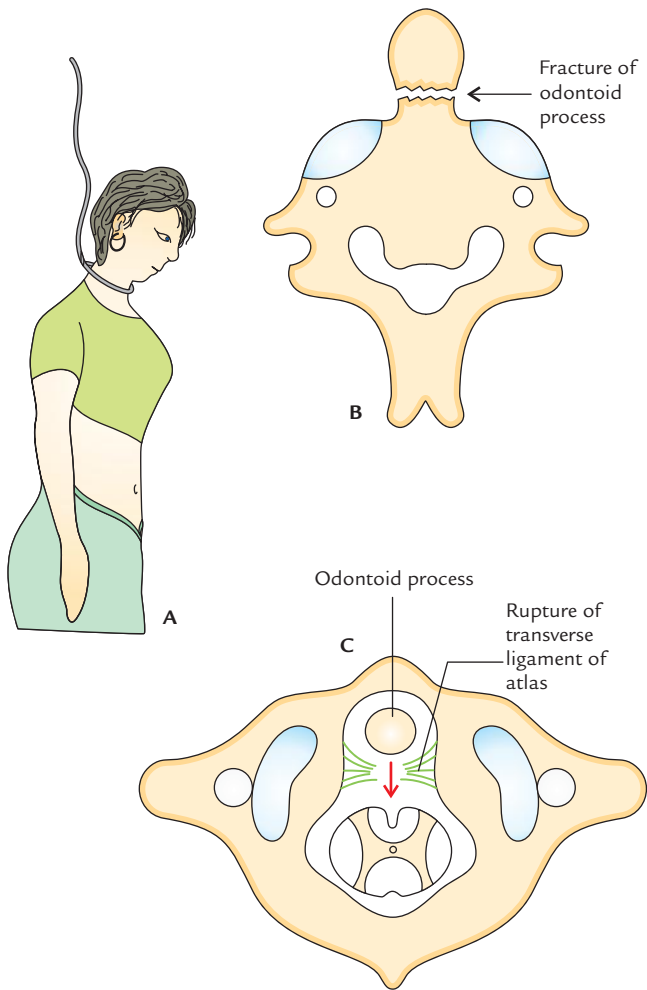


Fig. 7.22 Executive hanging: **A**, hanging; **B**, fracture of odontoid process; **C**, rupture of transverse ligament of atlas.

Movements

These are simultaneous at all the three atlantoaxial joints and consist almost exclusively of rotation of axis. In fact, the osseoligamentous ring of atlas supporting the atlas rotates around the central pivot formed by the odontoid process. The rotation is limited mainly by alar ligaments. Rotatory movements of atlas with head, around vertical axis are also called **No movements**.

Clinical correlation

- **Hangman's fracture** (Fig. 7.21): It is characterized by the fracture of the pedicles of the axis vertebra. It is a severe extension injury of the neck that occurs from automobile accident or a fall from height. Since in this injury the vertebral canal is enlarged due to forward displacement of the body of axis, the spinal cord is rarely compressed.

This injury is so named because during execution by hanging, the knot of Hangman's rope beneath the chin causes sudden severe extension injury of the neck.

Executive hanging can also cause fracture of odontoid process or separation of axis from the 3rd cervical vertebrae.

- The **fractures of odontoid process of axis vertebra** are relatively common, and usually occurs due to fall or blow on the head. Excessive mobility of the fractured odontoid process, particularly if associated with rupture of transverse ligament of atlas can cause compression of the spinal cord (Fig. 7.22).

N.B. In executing hanging, death occurs due to posterior dislocation of odontoid process (following rupture of transverse ligament of atlas) crushing the lower part of medulla oblongata which houses vital centres and adjoining part of the spinal cord.

Golden Facts to Remember

- ▶ Spinous process of cervical vertebra, which can be readily palpated on the back of the neck
 - ▶ Cervical vertebra with thickest spinous process
 - ▶ Largest superficial muscle on the back of the neck
 - ▶ Widest cervical vertebra
 - ▶ Thickest cutaneous nerve in the body
 - ▶ Rounded ridge at the side of the median furrow on the back of the neck is produced by
 - ▶ Intervertebral disc commonly involved in disc prolapse in cervical region
 - ▶ Hangman's fracture
 - ▶ No movements occur at
 - ▶ Yes movements occur at
 - ▶ Dislocation without fracture occurs only in cervical region because
- Spinous process of C7 vertebra (*vertebra prominens*)
 - Second cervical (axis) vertebra
 - Trapezius muscle
 - 1st cervical vertebra
 - Greater occipital nerve (dorsal ramus of C1 spinal nerve)
 - Semispinalis capitis (although it lies deep to trapezius and splenius)
 - Intervertebral disc between C5/C6 and C6/C7
 - Fracture of the pedicles of 2nd cervical (axis) vertebra
 - Median atlantoaxial joint of pivot variety
 - Atlanto-occipital joints of ellipsoid variety
 - The articular surfaces of articular processes are inclined horizontally

Clinical Case Study



A 59-year-old man visited his family physician and complained that he was suffering from pain on the back of his neck and over the lower part of deltoid region and lateral side of his arm on the right side. Sometimes he also felt tingling and numbness along the lateral aspect of his arm, forearm and thumb. The X-ray of cervical spine revealed reduced disc space between C4/C5 and C5/C6 vertebrae. The extensive formation of osteophytes (bony spurs) were also seen on the side of bodies of 4th, 5th, and 6th cervical vertebrae. He was told that he was suffering from **cervical spondylosis**.

Questions

1. What is cervical spondylosis?
2. Mention cause of pain, tingling, and numbness.
3. Name the discs commonly involved in cervical spondylosis.

Answers

1. Degenerative changes involving intervertebral discs, facet and uncovertebral joints (refer to page 105 for details).
2. Compression of C5 and C6 nerve roots.
3. Discs between C4/C5 and C5/C6 vertebrae.

Parotid Region

The parotid region is the area around the ear, bounded *anteriorly* by anterior border of masseter, *superiorly* by the zygomatic arch, *posteriorly* by mastoid process, and *inferiorly* by line joining the angle of the mandible to the mastoid process.

The principal structures in this area are **parotid gland** and **facial nerve**.

The facial nerve comes out of the cranial cavity through the stylomastoid foramen in this region and enters the parotid gland, where it divides into five terminal branches which emerge on the face, underneath the anterior margin of the parotid gland (Fig. 8.1).

The detailed knowledge of the anatomy of parotid region is important in clinical practice particularly while performing surgical procedures on parotid gland.

PAROTID GLAND

The parotid (para = around, otic = ear) gland is the largest of the three pairs of salivary glands, *viz.* parotid, submandibular, and sublingual. It is composed almost entirely of **serous alveoli**. It is lobulated, yellowish brown, and weighs about 25 g.

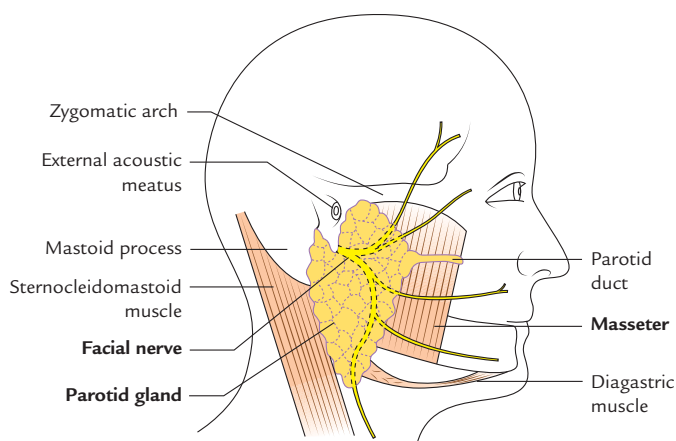


Fig. 8.1 Main features of the parotid region.

LOCATION

The parotid gland lies in the pyramidal fossa, posterior to the ramus of the mandible called **retromandibular fossa (parotid bed)**.

Boundaries of the Parotid Bed (Fig. 8.2)

It is bounded:

- Anteriorly:* by the posterior border of the ramus of mandible.
- Posteriorly:* by the mastoid process.
- Superiorly:* by the external acoustic meatus and posterior part of temporomandibular joint.
- Medially:* by styloid process.

The parotid bed is lined by muscles, probably to make it soft as under:

1. **Ramus** of the mandible is covered by two muscles: masseter laterally and the medial pterygoid medially.
2. **Mastoid process** is covered by two muscles: sternocleidomastoid laterally and posterior belly of digastric muscle medially.
3. **Styloid process** is enveloped by three slender muscles: styloglossus, stylopharyngeus, and stylohyoid.

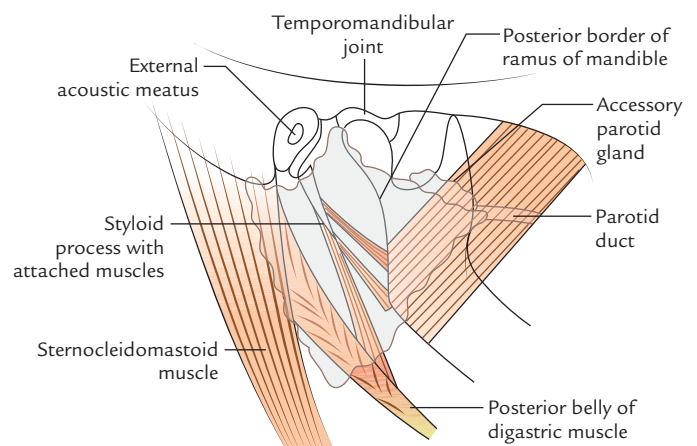


Fig. 8.2 Parotid bed and location of the parotid gland.

The parotid gland is too soft to be palpable in healthy individual but one can identify the bony boundaries of the parotid bed.

Extent

The parotid gland being soft is not confined only to the parotid bed but extends beyond it. The extent of parotid gland is as follows: it extends from external auditory meatus *above*, to the upper part of the carotid triangle *below*; *medially* it extends to the styloid process (close to the side wall of pharynx) and wraps around the neck of the mandible. *Posteriorly* it overlaps the sternocleidomastoid muscle and *anteriorly* it extends over the masseter for a variable distance. A part of this forward extension is often detached from the rest of the gland and is known as **accessory parotid gland**. The accessory parotid gland lies between the zygomatic arch above and the parotid duct below (Fig. 8.5). Several ducts from accessory gland open into the parotid duct.

PAROTID CAPSULE (OR PAROTID SHEATH)

The parotid gland is enclosed in a fibrous capsule called **parotid capsule** (Fig. 8.3).

It is formed by the tough investing layer of deep cervical fascia. This fascia splits in the region between the angle of the mandible and mastoid process to enclose the gland. The superficial lamina is thick, strong, unyielding, and adherent to the gland while deep lamina is thin. The superficial lamina blends with the epimysium of masseter to form a thick **parotidomasseteric fascia**, which is attached above to the zygomatic arch. The thin deep lamina is attached to the tympanic plate and styloid process of the temporal bone; it thickens to form **stylomandibular ligament**, which separates the parotid gland from the submandibular gland.

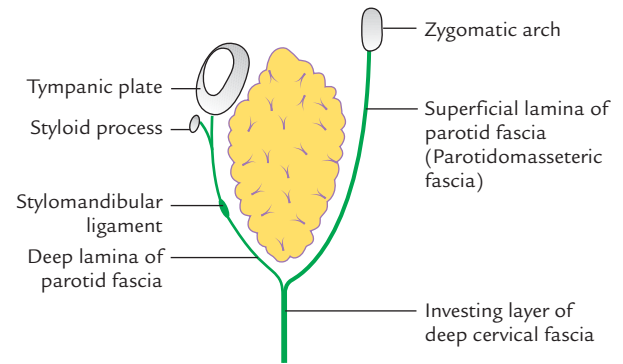


Fig. 8.3 Parotid capsule.

Clinical correlation

Infection of the parotid gland. The parotid gland is commonly infected by the *mumps virus* causing inflammation and swelling of the gland (**mumps**).

The **parotid swellings are very painful** due to unyielding nature of the parotid capsule, any inflammation or tension within the parotid gland will cause severe pain. This is caused by the stretching of the capsule and stimulation of branches of great auricular nerve. The pain is usually exacerbated at meal time when gustatory stimulus to gland results in increased parotid secretion enhancing further turgor within the capsule. However, patient is relieved of pain to some extent after taking meals due to release of secretions. This is seen routinely in patients suffering from mumps (also see Clinical correlation on page 117).

EXTERNAL FEATURES (Figs 8.4 and 8.5)

The gland resembles a three-sided pyramid with apex directed downwards. It presents the following features:

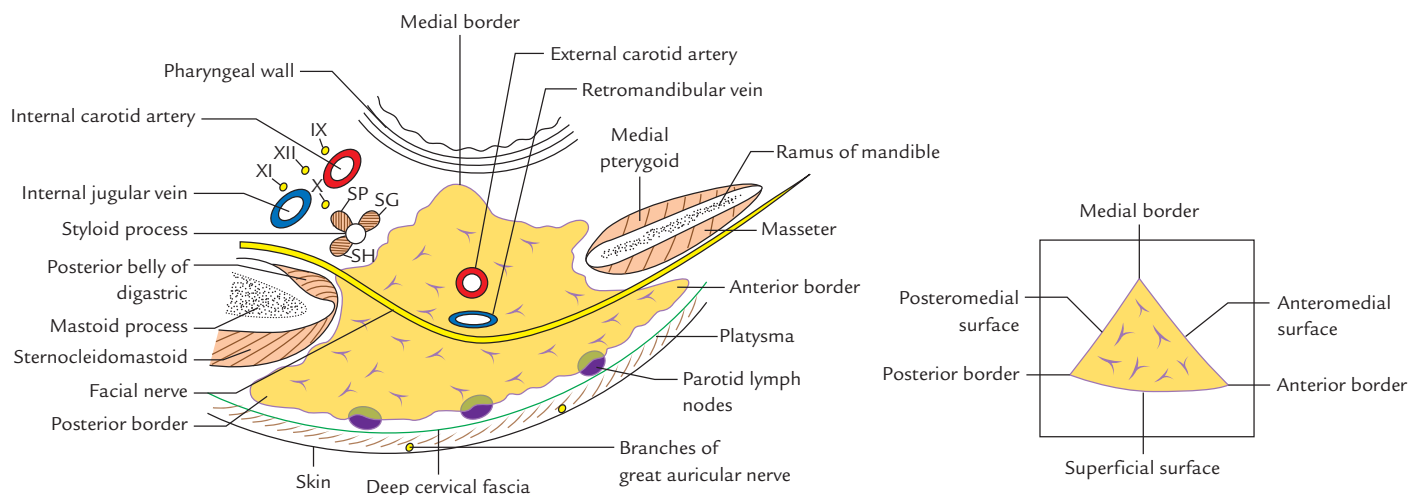


Fig. 8.4 Horizontal section through parotid gland showing its relations and the structures passing through it. The inset figure shows borders and surfaces of the parotid gland (SG = styloglossus muscle, SH = stylohyoid muscle, SP = stylopharyngeus muscle).

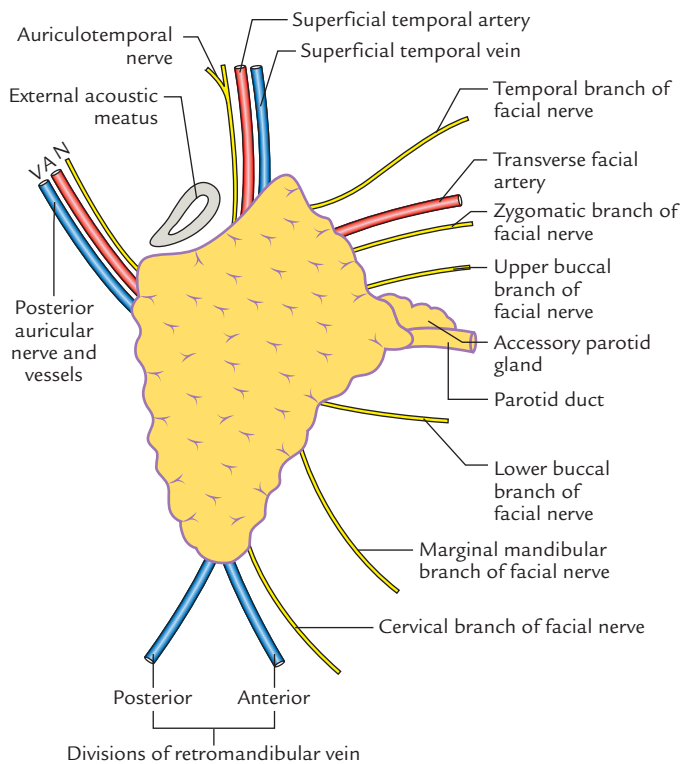


Fig. 8.5 The structures emerging at the periphery of the parotid gland.

- **An apex**
- **Four surfaces**
 - (a) Superior surface or base.
 - (b) Superficial surface.
 - (c) Anteromedial surface.
 - (d) Posteromedial surface.
- **Three borders**
 - (a) Anterior.
 - (b) Posterior.
 - (c) Medial.

RELATIONS

Apex

It projects downwards overlapping the posterior belly of digastric muscle and adjoining part of the carotid triangle.

The structures emerging through the apex include (Fig. 8.5):

1. Cervical branch of the facial nerve.
2. Anterior and posterior divisions of retromandibular vein.

Superior Surface or Base

It is concave and related to the external acoustic meatus and posterior aspect of temporomandibular joint.

The following structures emerge through it (Fig. 8.5):

1. Superficial temporal vessels.
2. Auriculotemporal nerve.

Superficial Surface

It is the largest of the four surfaces. It is covered from superficial to deep by (Fig. 8.4):

1. Skin.
2. Superficial fascia containing anterior branches of greater auricular nerve, superficial parotid (preauricular) lymph nodes, and platysma.
3. Parotid fascia.
4. Deep parotid lymph nodes embedded in the gland.

Anteromedial Surface

It is deeply grooved by the posterior border of the ramus of the mandible. It is related to (Fig. 8.4):

1. Masseter.
2. Medial pterygoid.
3. Posterior border of the ramus of the mandible.
4. Lateral aspect of the temporomandibular joint.

The branches of facial nerve emerge on face from underneath the anterior margin of this surface (Fig. 8.5).

Posteromedial Surface

It is moulded onto the mastoid and styloid processes and their covering muscles. Thus it is related to (Fig. 8.4):

1. Mastoid process, sternocleidomastoid, and posterior belly of digastric.
2. Styloid process and styloid group of muscles.

The styloid process and its muscles separate the gland from internal carotid artery, internal jugular vein, and last four cranial nerves.

The following structures enter the gland through this surface:

1. Facial nerve trunk in its upper part.
2. External carotid artery in its lower part.

Anterior Border

It separates the superficial surface from the anteromedial surface. The following structures (from above downwards) emerge in a radiating fashion underneath this border (Fig. 8.5):

- | | |
|---|--------------------------|
| <ol style="list-style-type: none"> 1. Temporal branch of the facial nerve. 2. Zygomatic branch of the facial nerve. 3. Transverse facial vessels. 4. Upper buccal branch of the facial nerve. | } Above the parotid duct |
| <ol style="list-style-type: none"> 5. Parotid duct. 6. Lower buccal branch of the facial nerve. 7. Marginal mandibular branch of the facial nerve. | } Below the parotid duct |

Posterior Border

It separates the superficial surface from the posteromedial surface.

The following structures emerge underneath this border (Fig. 8.5):

1. Posterior auricular vessels.
2. Posterior auricular branch of the facial nerve.

Medial Border

It separates the anteromedial surface from the posteromedial surface. It is related to the lateral wall of the pharynx.

STRUCTURES PRESENT WITHIN THE PAROTID GLAND

Three main structures either in part or in whole traverse the gland and branch within it (Figs 8.4 and 8.6). From superficial to deep these are:

1. Facial nerve.
2. Retromandibular vein.
3. External carotid artery.

N.B. Some members of the deep parotid lymph nodes and filaments of auriculotemporal nerve are also located within the gland.

The **facial nerve** (Fig. 8.6A) is most superficial. It enters the gland through the upper part of the posteromedial surface and divides into its terminal branches within the gland. The branches run horizontally and leave the gland through its anteromedial surface and appear on the face by passing underneath its anterior border.

The five terminal branches of the facial nerve radiate like a goose-foot through the anterior border of the gland and supply the muscles of facial expression. Such branching pattern of the facial nerve is termed **pes anserinus**.

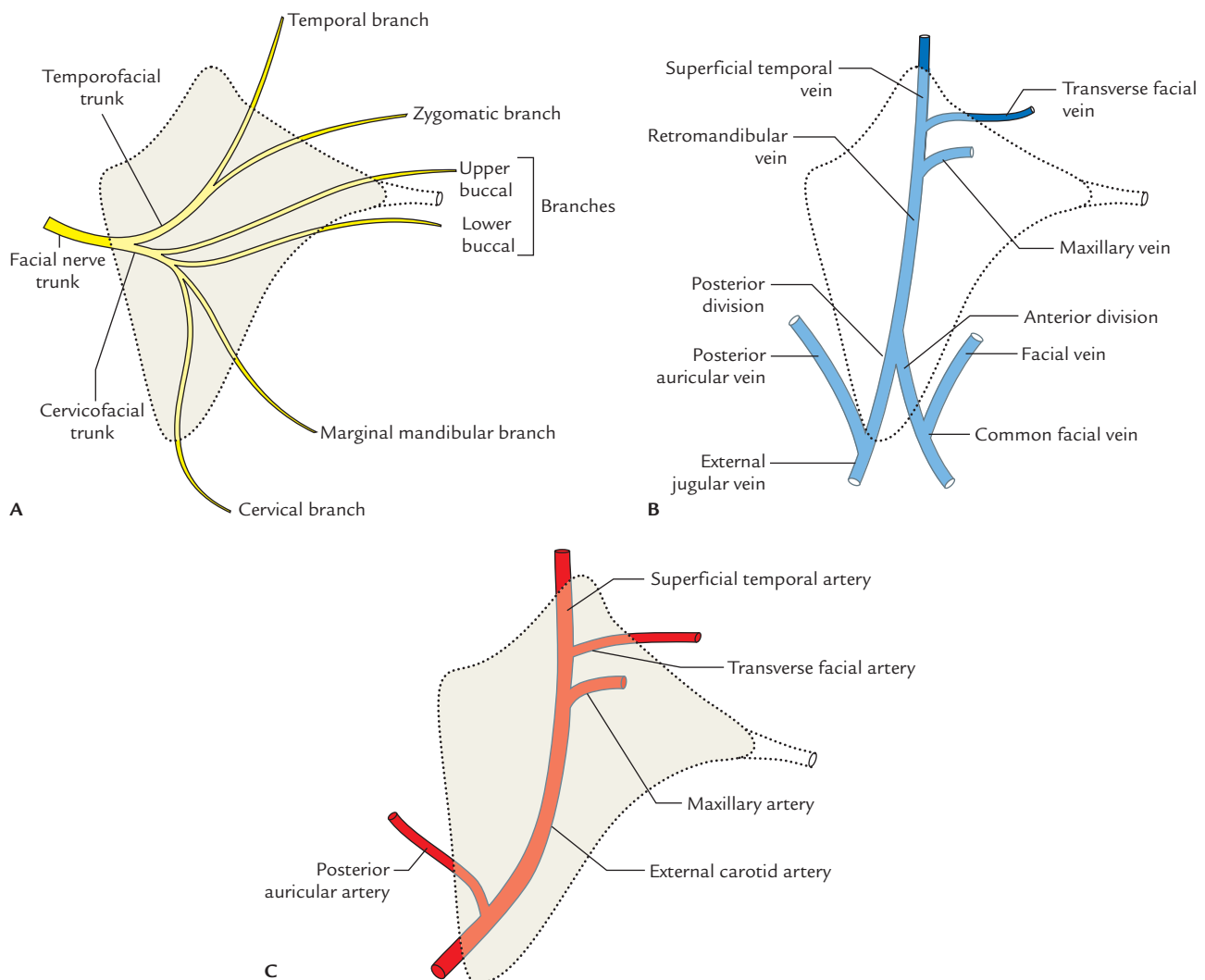


Fig. 8.6 The structures traversing the parotid gland: A, facial nerve; B, retromandibular vein; C, external carotid artery.

The **retromandibular vein** (Fig. 8.6B) occupies the intermediate zone of the gland and is formed by the union of the superficial temporal and maxillary veins. It ends below by dividing into anterior and posterior divisions. The anterior division joins the facial vein to form the **common facial vein** while posterior division joins the posterior auricular vein to form the **external jugular vein**.

The **external carotid artery** (Fig. 8.6C) pierces the lower part of the posteromedial surface to enter the gland where it occupies the deep zone of the gland. Within the gland it divides into superficial temporal and maxillary arteries. The transverse facial artery, branch of superficial temporal artery emerges through the anterior border of the gland.

Patey's Faciovenous Plane (Fig. 8.7)

The parotid gland is divided into large superficial and small deep parts or lobes. These lobes are connected by the isthmus of the glandular tissue, so that the gland appears H-shaped (shaped like a *collar stud*) in coronal section. The branches of facial nerve passes forward through the isthmus. The plane between the superficial and deep lobes in which nerves and veins lie has been designated by Patey as *faciovenous plane*. This plane helps the surgeons to remove the parotid tumor

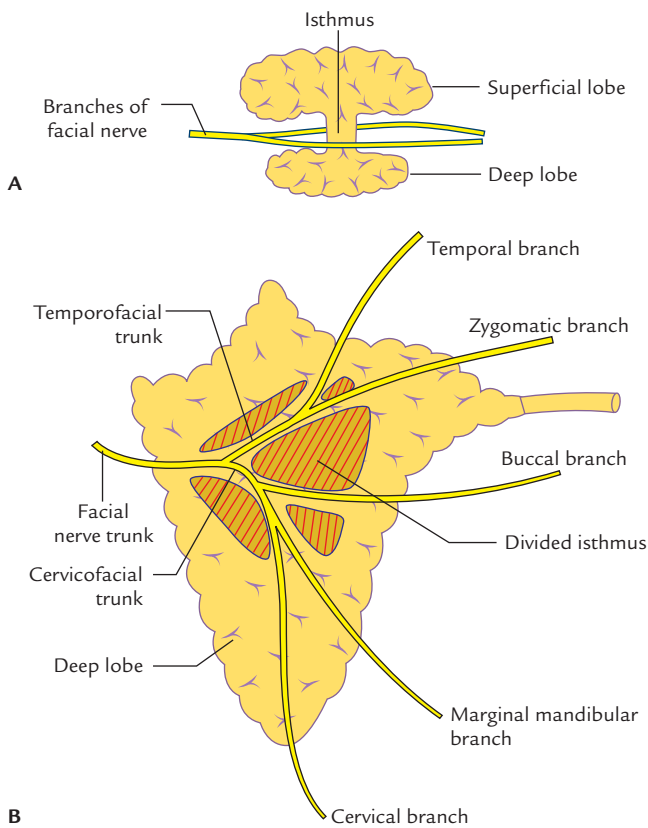


Fig. 8.7 Patey's faciovenous (neurovenous) plane in the parotid gland. The retromandibular vein is not shown for clarity: **A**, two lobes joined by an isthmus; **B**, superficial lobe is removed after dividing on isthmus leaving facial nerve and its branches intact.

(see clinical correlation given below) without damaging the nerve.

Clinical correlation

Mixed parotid tumor: It is slow-growing lobulated painless tumor of large superficial part of the parotid gland. It is so called because of its mixed histological appearance. Currently it is termed **pleomorphic adenoma**. After many years of slow benign growth, it may undergo a malignant change.

Parotid Duct (Stenson's Duct)

Parotid duct, about 5 cm long, emerges from the middle of the anterior border of the gland and opens into the vestibule of the mouth opposite the crown of upper second molar tooth (Fig. 8.8).

Course

The course taken by the duct is as follows: After emerging from the gland, it runs forward over the masseter between the upper and lower buccal branches of the facial nerve; at the anterior border of masseter, it abruptly turns inwards, almost at 90° (**first bend**) and pierces buccal pad of fat, buccopharyngeal fascia, and buccinator muscle.

After piercing the buccinator muscle, the parotid duct runs forwards (**second bend**) for about 1 cm between it and

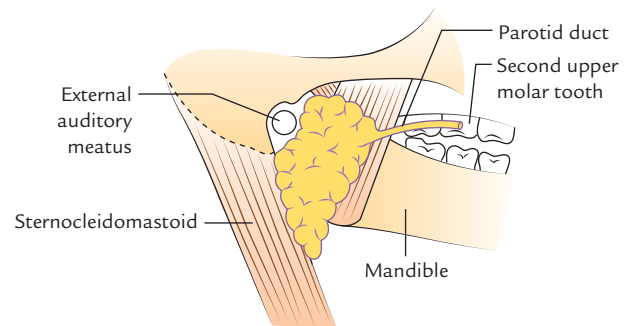


Fig. 8.8 Sites of origin and termination of the parotid duct.

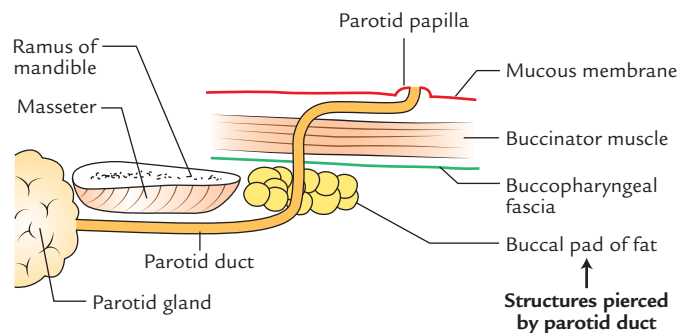


Fig. 8.9 Course of the parotid duct. Also note the structures pierced by it during its course from the parotid gland to the vestibule of the mouth.

the buccal mucosa. Finally, the duct turns medially (**third bend**) and opens into the vestibule of mouth opposite the crown of upper second molar teeth (Fig. 8.9). This tortuous course of the duct provides a valve-like mechanism to prevent the inflation of the duct system of parotid gland during excessive blowing of the mouth as in trumpet blowing.

Surface Anatomy of the Parotid Duct

On the face the parotid duct is represented by the middle third of the line extending from lower border of tragus to the midpoint between the ala of the nose and the red margin of the upper lip.

The accessory gland is drained by a small duct that opens into the upper aspect of the parotid duct.

Clinical correlation

- The probing of the parotid duct is difficult because of its tortuous course. The probe is held at the sharp bends of the duct.
- The parotid duct lies one finger's breadth below the zygomatic arch, and when the teeth are clenched, it may be rolled up and down against the tense masseter.
- The parotid duct being a superficial structure on the face, may be damaged in injuries to the face or may be cut inadvertently during surgical procedures on the face.
- The parotid duct and its ramifications can be demonstrated radiologically by injecting radio-opaque dye through a fine needle or canula inserted into the mouth of the duct in the vestibule of the oral cavity (**parotid sialogram**).
- Occasionally, calculi (stones) may form in the parotid gland and parotid duct. The calculi lodged in the distal portion of the gland may be removed by splitting up the duct from its opening in the mouth.

NERVE SUPPLY

The parotid gland is supplied by the parasympathetic, sympathetic, and sensory fibres:

1. **Parasympathetic (secretomotor) supply** (Fig. 13.10): It is provided through auriculotemporal nerve. The **preganglionic fibres** arise from the inferior salivatory nucleus in the medulla and pass successively through glossopharyngeal nerve, tympanic branch of glossopharyngeal (Jacobson's nerve), tympanic plexus and lesser petrosal nerve to relay into otic ganglion. **Postganglionic fibres** arise from the cells of the ganglion and pass through the auriculotemporal nerve to supply the parotid gland. The stimulation of parasympathetic supply produces watery secretion.
2. **Sympathetic supply**: It is derived from sympathetic plexus around external carotid artery formed by postganglionic fibres derived from superior cervical

sympathetic ganglion. The preganglionic sympathetic fibres arise from the lateral horn of T1 spinal segment. The sympathetic fibres are vasomotor and their stimulation produces thick sticky secretion.

3. **Sensory supply**: It is derived from:
 - (a) Auriculotemporal nerve.
 - (b) Great auricular nerve (C2 and C3). The C2 fibres are sensory to the parotid fascia.

Clinical correlation

Frey's syndrome (auriculotemporal nerve syndrome):

Sometimes penetrating wounds of the parotid gland may damage auriculotemporal and great auricular nerves. The auriculotemporal nerve contains parasympathetic (secretomotor), sensory, and sympathetic fibres. The great auricular nerve contains sensory and sudomotor fibres. When these nerves are cut, during regeneration the secretomotor fibres grow into endoneurial sheaths of fibres supplying cutaneous receptors for pain, touch and temperature, and sympathetic fibres supplying sweat glands and blood vessels. Thus a stimulus intended for salivation evokes cutaneous hyperesthesia, sweating, and flushing. The presenting features of Frey's syndrome are:

- (a) When a person eats, the ipsilateral cheek (parotid region) becomes red, hot, and painful. It is associated with beads of perspiration (gustatory sweating).
- (b) When a person shaves, there is cutaneous hyperesthesia in front of the ear.

VASCULAR SUPPLY

The **arterial supply** of parotid gland is derived from the external carotid and superficial temporal arteries.

The **venous drainage** of parotid gland takes place into retromandibular and external jugular veins.

LYMPHATIC DRAINAGE

The lymphatics from the parotid gland drain into the **superficial and deep parotid lymph nodes**, which in turn drain into **deep cervical lymph nodes**. The superficial parotid nodes lie in the superficial fascia over the gland and deep nodes, deep to parotid capsule. Few members of this group lie in the superficial zone of the parotid gland.

DEVELOPMENT

The parotid gland is ectodermal in origin. The parotid primordium develops during the 6th week of intrauterine life as a cord of cells by proliferation of ectodermal lining of the vestibule of the mouth near the angle of primitive oral fissure. It grows backwards towards the ear and branches repeatedly. The parotid bud and its branches canalize to form the duct system and acini.

N.B. All the salivary glands arise from proliferation of the oral epithelium. Out of the three pairs of large salivary glands only parotid glands develop from ectoderm, others (submandibular and sublingual) develop from endoderm.

FACIAL NERVE: AN EXTRACRANIAL COURSE

The facial nerve (Fig. 8.10) comes out of cranial cavity through the stylomastoid foramen at the base of the skull, between the styloid and mastoid processes of the temporal bone.

After emerging from the foramen, it curves forwards around the lateral aspect of the root of the styloid process and enters the posteromedial aspect of the parotid gland on the superficial plane. In the gland, it runs superficial to the retromandibular vein for about 1 cm and then divides into two trunks: (a) the temporofacial, and (b) the cervicofacial. The **temporofacial trunk** runs upwards and subdivides into temporal and zygomatic terminal branches. The **cervicofacial trunk** passes downwards and forwards, and divides into buccal, marginal mandibular, and cervical terminal branches.

BRANCHES

Below the base of the skull, the facial nerves give rise to the following branches:

1. **Posterior auricular nerve:** It arises just below the stylomastoid foramen and ascends between the mastoid process and the back of the external acoustic meatus. It

supplies occipital belly of occipitofrontalis, auricularis posterior, and auricularis superior (intrinsic muscles of the ear).

2. **Branch to the posterior belly of digastric:** It arises near the origin of the previous nerve and after a very short course supplies the muscle. It also gives a branch to the stylohyoid muscle.
3. **Terminal branches:** These are five in number, viz.:
 - (a) *Temporal branch*—run upwards and cross the zygomatic arch.
 - (b) *Zygomatic branches*—run below and parallel to the zygomatic arch.
 - (c) *Buccal branches*—are two in number. The upper buccal nerve runs above the parotid duct and the lower buccal nerve runs below the duct.
 - (d) *Marginal mandibular (also called mandibular) branch*—runs forwards below the angle of the mandible, deep to the platysma. It then crosses the body of the mandible to supply the muscles of the lower lip and chin.
 - (e) *Cervical branch*—runs downwards and forwards to reach the front of the neck, to supply the platysma.

N.B. The terminal branches communicate with the sensory branches of the trigeminal nerve.

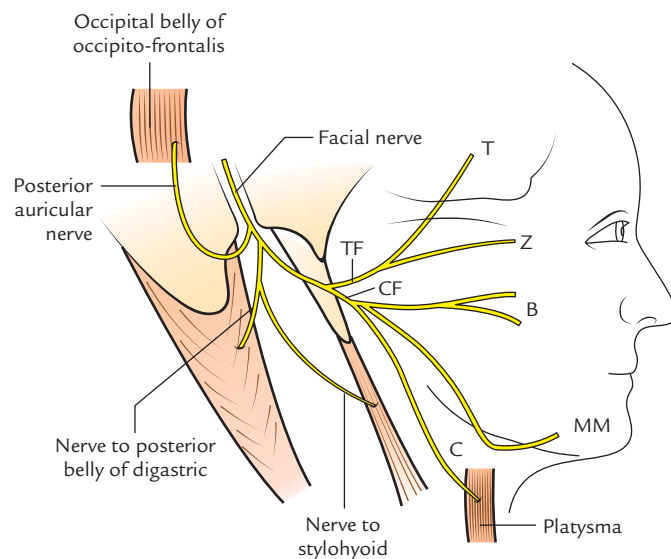


Fig. 8.10 Extracranial course of the facial nerve (TF = temporofacial trunk, CF = cervicofacial trunk. T, Z, B, MM, and C = temporal, zygomatic, buccal, marginal mandibular, and cervical branches of the facial nerve).

Clinical correlation

- **Mumps (viral parotitis):** It is a contagious disease caused by a specific virus called *mumps virus (myxovirus)*. It presents as an acute inflammation and swelling of the gland. There is diffuse enlargement of the parotid gland (parotid swelling) associated with pain and fever. The pain is accentuated by jaw movement as the part of the gland between the external auditory meatus and temporomandibular joint is compressed. The opening of parotid duct becomes swollen and congested. It mostly affects children below 15 years of age. The viral parotitis characteristically does not suppurate. The viremia associated with mumps can cause complications in the adults like *epididymo-orchitis*, *pancreatitis*, or *oophoritis*, etc.
- **Parotid abscess:** The parotid abscess may occur by spread of infection from the oral cavity. A parotid abscess may spread into parapharyngeal spaces or burst spontaneously on the cheek or into the external auditory meatus.
- **Drainage of the parotid abscess:** A preauricular incision is made in the skin at the root of the auricle and skin flap raised to expose the parotid fascia. The abscess is drained by a blunt horizontal incision in the parotid capsule, parallel to the branches of the facial nerve (*Hilton's method*).
- **Bell's palsy:** It is described in detail on page 57.

Golden Facts to Remember

▶ Largest salivary gland in the body	Parotid gland
▶ Commonest cause of parotitis/commonest infection of the parotid gland	Mumps virus
▶ Most common tumor of the parotid gland	Pleomorphic adenoma (mixed parotid tumor)
▶ Ducts of all the major salivary glands open into the oral cavity proper except that of	Parotid gland (parotid duct) which opens in the vestibule of the mouth
▶ Most superficial structure within parotid gland	Facial nerve and its terminal branches
▶ Deepest structure in the substance of parotid gland	External carotid artery
▶ Most preferred incision to drain the parotid abscess	Horizontal incision in the parotid fascia (Hilton's method)

Clinical Case Study



A 14-year-old boy presented with a complaint of rapidly growing painful swelling on face in front of ear on the right side. He also told that the pain increases while taking meals but subsides to some extent after finishing the meal. On examination the physician found that the ear lobule is lifted on the affected side. The examination of oral cavity revealed congestion in mucous membrane of vestibule of mouth opposite the second upper molar tooth on the right side. He was diagnosed as a case of *acute parotitis*.

Questions

1. What is the commonest cause of acute parotitis?
2. Why parotid swellings are painful?
3. Why does pain increase during meal-time and is relieved after taking meals?
4. Name the three structures present within the substance of the parotid gland?

Answers

1. Mumps (infection of the parotid gland by mumps virus).
2. Due to stretching of tough unyielding parotid capsule which is richly innervated by sensory nerve fibres.
3. Pain increases while taking meal because during mastication secretion accumulates in the acini due to parasympathetic stimulation and a part of inflamed gland between temporomandibular joint and external acoustic meatus is compressed. The pain is relieved after meals because pent-up secretion (saliva) within the gland is released for salivation, hence reducing pressure on the parotid capsule.
4. Facial nerve, retromandibular vein, and external carotid artery.

Submandibular Region

The submandibular region is below and under the cover of the body of the mandible. It extends upwards up to the mylohyoid line and below up to the hyoid bone. Superficially it includes both submandibular and submental triangles (Fig. 9.1).

The deep structures in this region include floor of the mouth and the root of the tongue. Clinically this region is very important because it is the common site for swellings due to enlargement of submandibular lymph nodes and submandibular salivary gland. The inflammatory edema of the floor of the mouth (called **Ludwig's angina**) spreads in this region to cause generalized swelling of the region. The surgical procedures are commonly performed in this region, hence students should study this region very carefully. The term *submandibular* often misleads the students as it gives the impression that the submandibular region deals with the structures below the mandible only.

SUPERFICIAL STRUCTURES IN THE SUBMANDIBULAR REGION

The submandibular region is crossed superficially by platysma in the superficial fascia. Deep to platysma, the marginal mandibular nerve (lowest branch of facial nerve) crosses the lower border of the mandible near the angle and runs below it across the submandibular region before turning upwards to reach the mental region of the face where it supplies depressors of the lower lip (depressor labii inferioris, depressor anguli oris) and mentalis muscle. The surgical incisions are, therefore, not made along the lower border of the mandible to avoid injury to this nerve. The great auricular nerve crosses the posterior belly of digastric on its way to supply the skin of face and auricle (Fig. 9.1).

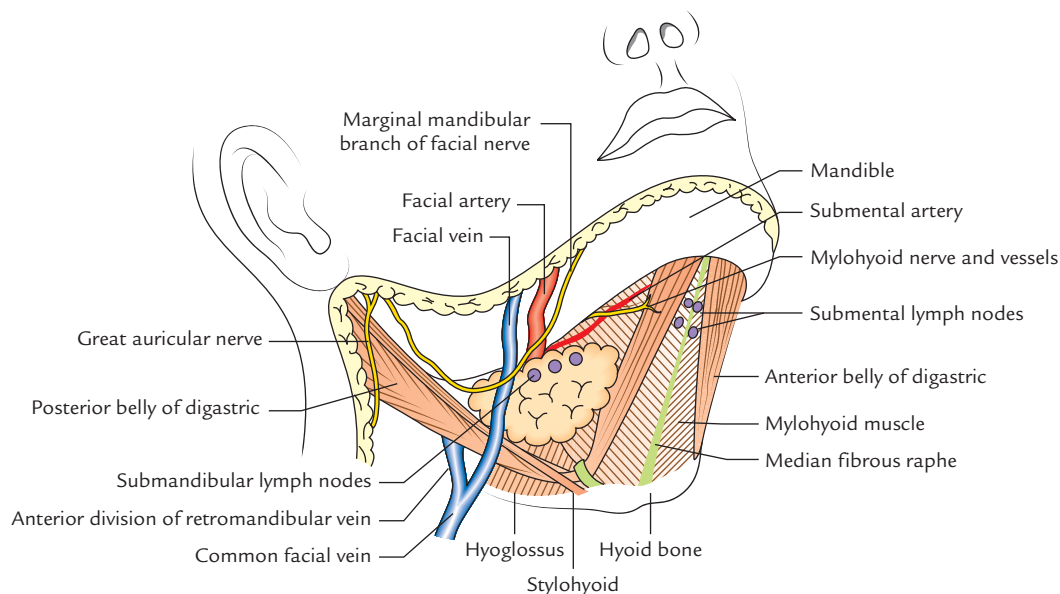


Fig. 9.1 Structures seen in the superficial dissection of the right submandibular region.

DEEP STRUCTURES IN THE SUBMANDIBULAR REGION

The deep structures in the submandibular region (also called *contents of the submandibular region*) are:

1. Suprahyoid muscles (all paired), viz. digastric, stylohyoid, mylohyoid, and geniohyoid.
2. Extrinsic muscles of the tongue (all paired), viz. hyoglossus, styloglossus, and genioglossus.
3. Submandibular and sublingual salivary glands.
4. Facial and lingual arteries.
5. Lingual, hypoglossal, and glossopharyngeal nerves.
6. Submandibular ganglion.

N.B. It is important to know that on either side of midline, the *submandibular salivary gland* is the most prominent structure and the *hyoglossus muscle* is the key muscle of the submandibular region.

MUSCLES OF THE SUBMANDIBULAR REGION

From the point of view of surgical procedures, the muscles in the submandibular region form four muscular planes; from superficial to deep, these are:

1. **First muscular plane:** formed by the digastric and stylohyoid muscles.
2. **Second muscular plane:** formed by the mylohyoid muscle.
3. **Third muscular plane:** formed by the geniohyoid, hyoglossus, and styloglossus muscles.
4. **Fourth muscular plane:** formed by the genioglossus and a part of superior constrictor of the pharynx.

MUSCLES OF FIRST MUSCULAR PLANE

Digastric Muscle (Fig. 9.2)

It is a strap-like muscle consisting of posterior and anterior bellies, united by an intermediate tendon. This muscle is so called because it has two bellies.

Origin

1. The *bipinnate posterior belly* arises from the mastoid notch of the temporal bone.
2. The *unipinnate anterior belly* arises from the digastric fossa on the lower border of the mandible close to the symphysis menti.

Insertion

1. Posterior belly passes downwards and forwards between the carotid triangle below and behind and digastric triangle above and in front and inserted into the intermediate tendon.

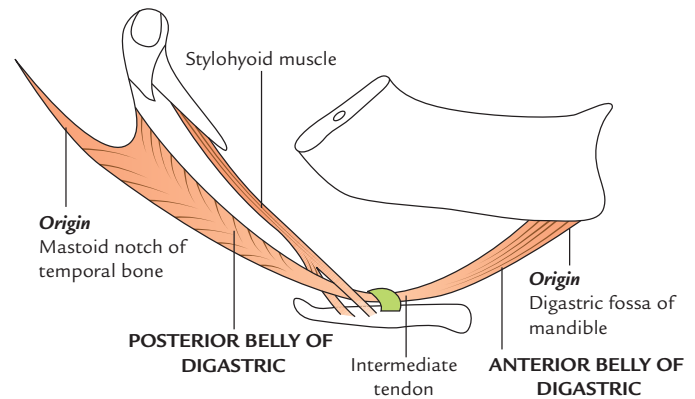


Fig. 9.2 Origin and insertion of the digastric muscle.

2. Anterior belly passes downwards and backwards on the mylohyoid to be inserted into the intermediate tendon.

The intermediate tendon is anchored to the junction of the body and greater cornu of hyoid bone by an inverted U-shaped facial sling of investing layer of deep cervical fascia. The tendon of digastric muscle passes between the two slips of tendon of stylohyoid muscle.

Nerve supply

1. The posterior belly develops from mesoderm of the 2nd pharyngeal arch and therefore, supplied by the facial nerve.
2. The anterior belly develops from the 1st pharyngeal arch and, therefore, supplied by the mylohyoid nerve, a branch of inferior alveolar nerve from mandibular nerve.

Actions

1. Helps to depress the mandible when the mouth is opened widely against resistance.
2. Pulls the hyoid bone upwards during deglutition.

Relations of the posterior belly of the digastric muscle

1. **Superficial:**
 - (a) Skin, superficial fascia, platysma, and investing layer of deep cervical fascia.
 - (b) Mastoid process and sternocleidomastoid muscle.
 - (c) Parotid gland and the angle of the mandible.
2. **Deep (Fig. 9.3):**
 - (a) Neurovascular bundle of neck consisting of internal jugular vein, external and internal carotid arteries 10th, 11th, and 12th cranial nerves.
 - (b) **Upper border:** Stylohyoid muscle and posterior auricular artery run along the upper border of the posterior belly of the digastric.

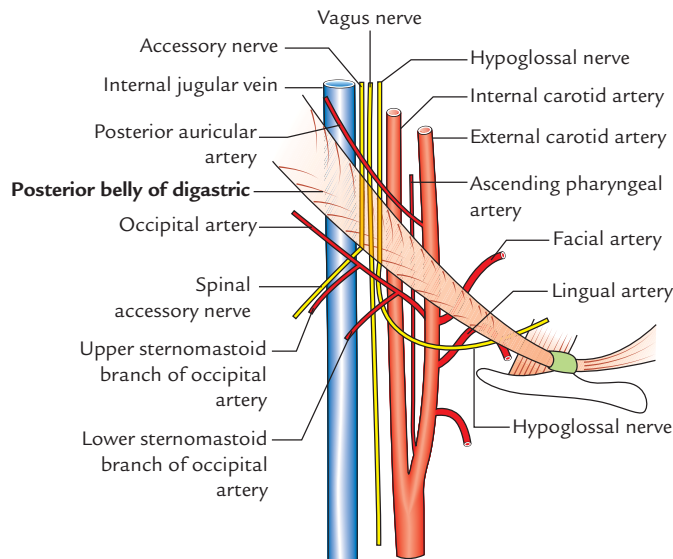


Fig. 9.3 Important deep relations of the posterior belly of the digastric muscle.

- (c) **Lower border:** Occipital artery runs along and under the cover of the lower border of digastric.

N.B. The relations of posterior belly of digastric are important because three cranial nerves: 10th, 11th, and 12th, and three great blood vessels of neck, viz. internal jugular vein, internal and external carotid arteries pass deep to it.

Differences between the posterior and anterior bellies of the digastric muscles are listed in Table 9.1.

Table 9.1 Differences between the anterior and posterior belly of the digastric muscle

Anterior belly	Posterior belly
Unipennate	Bipennate
Develops from 1st pharyngeal arch	Develops from 2nd pharyngeal arch
Supplied by mylohyoid nerve (nerve of 1st pharyngeal arch)	Supplied by facial nerve (nerve of 2nd pharyngeal arch)

Stylohyoid Muscle (Fig. 9.4)

It is a slender muscle that lies along the upper border of the posterior belly of the digastric muscle.

Origin

It arises from the posterior surface of the styloid process.

Insertion

It is inserted into the hyoid bone at the junction between the body and greater cornu. At the insertion, its tendon splits into two slips that pass one on either side of the intermediate tendon of the digastric muscle (Fig. 9.3).

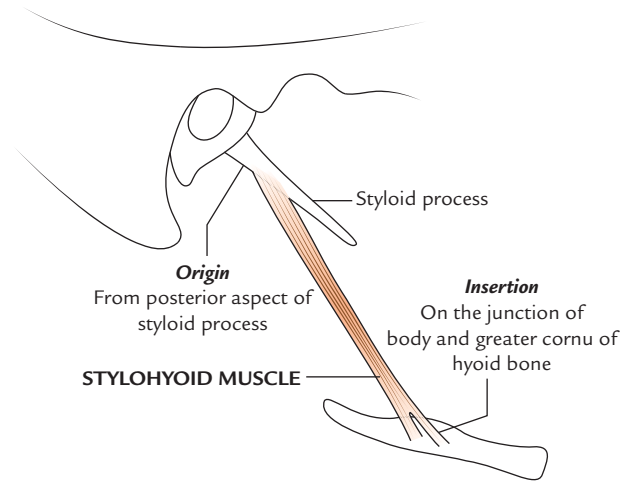


Fig. 9.4 Origin and insertion of the stylohyoid muscle.

Nerve supply

The stylohyoid muscle develops from the 2nd arch and, therefore, it is supplied by the facial nerve.

Actions

It draws the hyoid bone upwards and backwards, and elongates the floor of the mouth.

N.B. The stylohyoid muscle is considered as the delaminated portion of the posterior belly of the digastric muscle.

MUSCLES OF SECOND MUSCULAR PLANE

Mylohyoid Muscle (Fig. 9.5)

It is a flat, triangular muscle lying deep to the anterior belly of the digastric muscle. The right and left mylohyoid muscles join in the median fibrous raphe to form the gutter-shaped

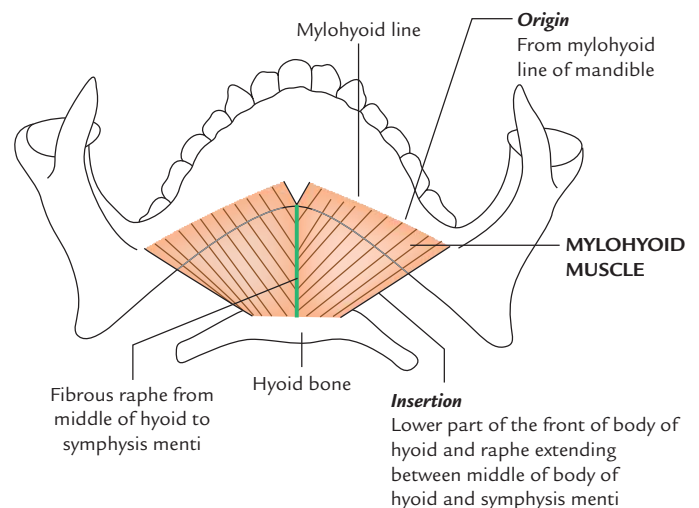


Fig. 9.5 Origin and insertion of the mylohyoid muscle (as seen from below).

floor of the mouth; over which lies the tongue, hence the floor of the mouth is also called **diaphragma oris**.

Origin

From the mylohyoid line of the mandible.

Insertion

The fibres run downwards and medially. The posterior fibres are inserted into the body of the hyoid bone. The middle and anterior fibres are inserted into the median fibrous raphe extending from symphysis menti to the hyoid bone.

Nerve supply

The mylohyoid muscle develops from the first pharyngeal arch, therefore it is supplied by mylohyoid nerve, a branch of inferior alveolar nerve from mandibular nerve.

Actions

1. The mylohyoid muscle elevates the floor of the mouth and hence the tongue during the first stage of the deglutition.
2. It also helps in the depression of the mandible against resistance.
3. It fixes or elevates the hyoid bone.

MUSCLES OF THIRD MUSCULAR PLANE

Geniohyoid Muscle (Fig. 9.6)

It is a narrow muscle that lies alongside the midline deep to the mylohyoid.

Origin

From inferior genial tubercle of the mandible.

Insertion

The fibres run backwards and downwards to be inserted into the anterior surface (front) of the body of the hyoid bone, above the medial part of the mylohyoid muscle.

Nerve supply

C1 fibres through hypoglossal nerve.

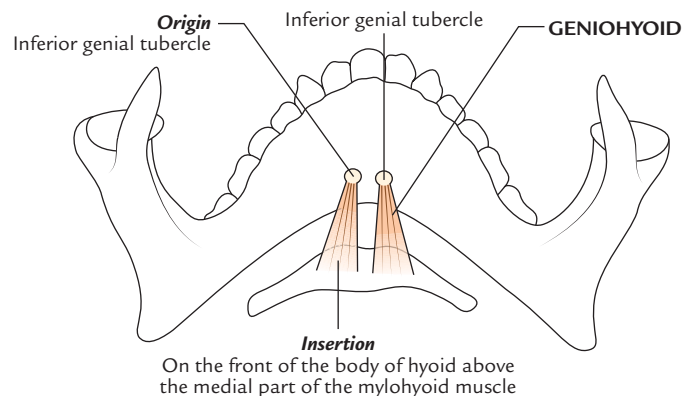


Fig. 9.6 Origin and insertion of the geniohyoid muscle.

Actions

1. The geniohyoid elevates the hyoid bone by pulling it upwards and forwards and thus shortens the floor of the mouth.
2. They may depress the mandible when the hyoid bone is fixed.

Hyoglossus Muscle (Fig. 9.7)

It is the flat quadrilateral muscle of the tongue.

Origin

From upper surface of the entire length of the greater cornu and adjacent part of the body of hyoid bone.

Insertion

Into the side of tongue between styloglossus laterally and inferior longitudinal medially. The fibres of hyoglossus from hyoid bone run upwards and slightly forward and decussate with the fibres of styloglossus.

N.B. A part of hyoglossus may be attached to the lesser cornu of the hyoid bone and form a separate muscle called *chondroglossus*.

Relations

The hyoglossus, a quadrilateral sheet of muscle, is the key muscle of the suprahyoid region because it serves as a landmark for neighboring structures in the region. Therefore, its relations are very important to surgeons.

Superficial relations (Fig. 9.8): The superficial relations of the hyoglossus are as follows:

1. Hypoglossal nerve, crosses the lower part of muscle from behind forwards.
2. Lingual nerve, crosses the upper part of muscle from behind forwards.

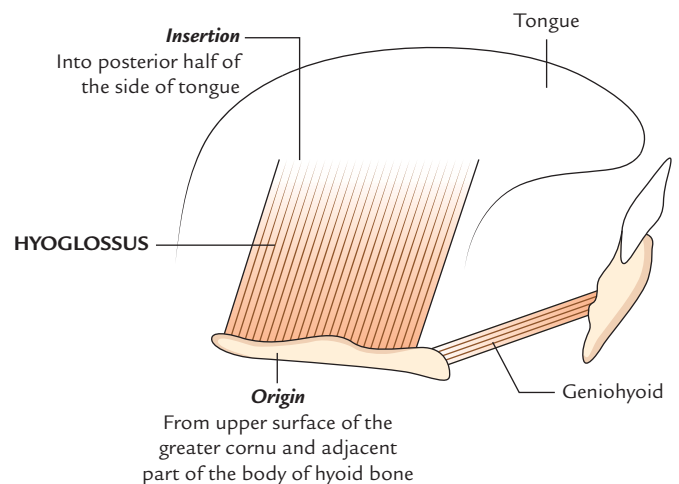


Fig. 9.7 Origin and insertion of the hyoglossus muscle.

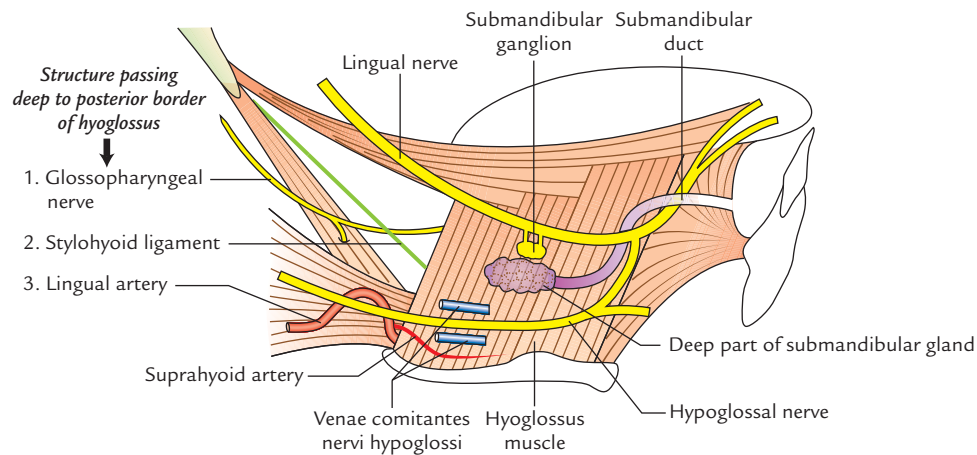


Fig. 9.8 Superficial relations of the hyoglossus muscle.

3. Deep part of the submandibular gland and submandibular duct. The gland lies in the middle of hyoglossus muscle and the duct lies between the gland and the muscle.
4. Submandibular ganglion lies between the lingual nerve and deep part of the submandibular gland.
5. Styloglossus muscle—interdigitates with hyoglossus.
6. Mylohyoid muscle overlaps the hyoglossus anterosuperiorly.

Deep relations (Fig. 9.22D): The deep relations of the hyoglossus are as follows:

1. Inferior longitudinal muscle of tongue.
2. Genioglossus muscle anteriorly.
3. Middle constrictor of pharynx posteriorly.
4. Glossopharyngeal nerve.
5. Stylohyoid ligament.
6. Lingual artery.

Structures passing deep to posterior border of hyoglossus

From above downwards, these are (Fig. 9.8) as follows:

1. Glossopharyngeal nerve.
2. Stylohyoid ligament.
3. Lingual artery.

Nerve supply

The hyoglossus muscle develops from **occipital myotomes**, therefore, it is supplied by hypoglossal nerve.

Actions

1. Depresses the side of tongue to make the dorsal surface of the tongue convex.
2. Helps in the retraction of the protruded tongue.

Styloglossus Muscle (Fig. 9.9)

Origin

From front of the tip of styloid process and adjoining part of stylohyoid ligament.

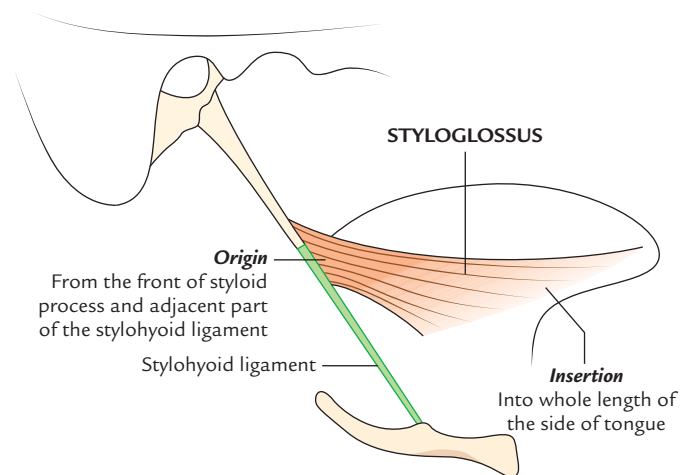


Fig. 9.9 Origin and insertion of the styloglossus muscle.

Insertion

The fibres run forwards to be inserted into the whole length of the side of tongue, interdigitating with the fibres of the hyoglossus muscle.

Nerve supply

It is supplied by hypoglossal nerve.

Actions

Retracts the tongue upwards and backwards, and thus it is antagonist to the genioglossus. Along with its counterpart of opposite side, it forms a median gutter on the dorsum of tongue for the passage of food.

MUSCLES OF FOURTH MUSCULAR PLANE

Genioglossus Muscle (Fig. 9.10)

It is a fan-shaped extrinsic muscle of tongue and along with its counterpart of the opposite side forms the most of the bulk of the tongue.

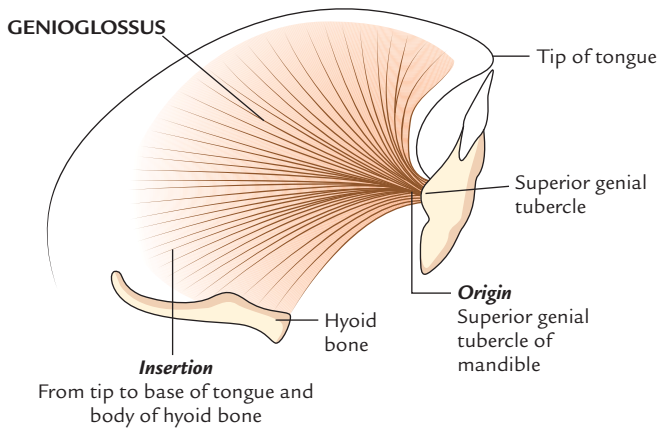


Fig. 9.10 Origin and insertion of the genioglossus muscle.

Origin

From superior genial tubercle of the mandible.

Insertion

The fibres radiate backwards fan-wise into the substance of the corresponding half of the tongue alongside the median septum, from the tip to the base, for insertion.

1. **Lower fibres** are inserted into the body of the hyoid and form the **root of the tongue**.
2. **Intermediate fibres** pass beneath the anterior border of the hyoglossus and extend backwards up to stylohyoid ligament and middle constrictor of the pharynx.
3. **Upper fibres** turn upwards and forwards to extend up to the tip of the tongue.

Nerve supply

It is supplied by hypoglossal nerve.

Actions

The muscles of both sides together protrude the tongue and make an elongated gutter on the dorsal surface of the tongue for the passage of food.

NERVES OF THE SUBMANDIBULAR REGION

LINGUAL NERVE

The lingual nerve arises from posterior division of the mandibular nerve, and descends between the ramus of the mandible and the medial pterygoid muscle. It then inclines forwards and enters the mouth by passing inferior to the lower border of the superior constrictor of the pharynx at its attachment near the posterior end of the mylohyoid line. Now it enters the submandibular region by passing just behind and inferior to the third molar tooth between medial surface of the mandible and the mucus membrane of the gum (Fig. 9.11).

In this position, it is liable to be injured by the clumsy extraction of the adjacent tooth, and is accessible to local

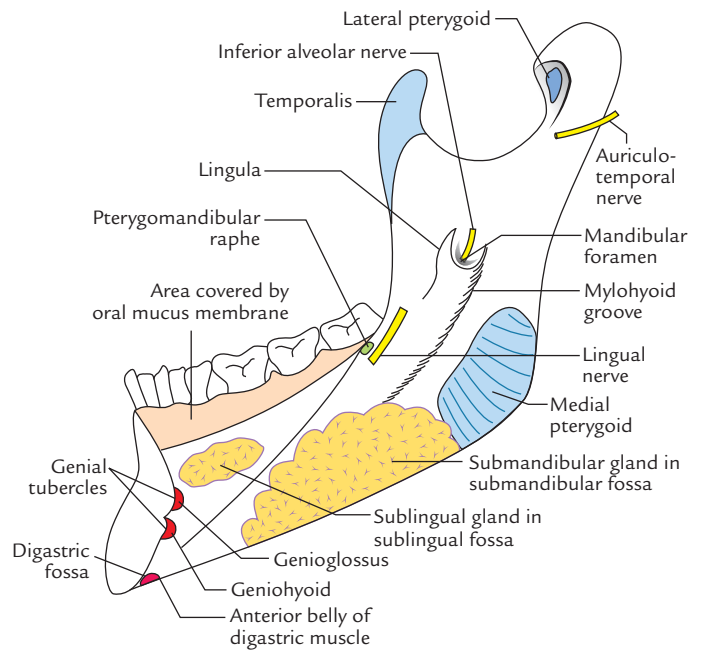


Fig. 9.11 Features of the internal aspect of the right half of the body of mandible.

anesthetics. In its further course, the lingual nerve lies close to the side of the tongue, crosses the styloglossus and upper part of the hyoglossus, and hooks beneath the submandibular duct. In the process, it crosses the submandibular duct superficially and then turns up deep to the duct (the double crossing).

Attached to the undersurface of the nerve is the submandibular ganglion, which lies on hyoglossus just above the deep part of the submandibular gland and supplies it secretomotor fibres that have synapse in the ganglion. Other postganglionic fibres re-enter the lingual nerve, which transports them to the sublingual gland.

The lingual nerve is itself sensory to the anterior two-third of the tongue and the inner (lingual) surface of the gums, but its content fibres belonging to the chorda tympani nerve carry taste sensations from the anterior two-third of the tongue except from vallate papillae.

Branches

The lingual nerve gives the following two sets of branches:

1. **Branches of communication (communicating twigs), viz.**
 - (a) Two or more to submandibular ganglion.
 - (b) One or two which descend along the anterior border of the hyoglossus to unite with the hypoglossal nerve.
2. **Branches of distribution, viz.**
 - (a) A gingival branch to the inner surface of the gum.
 - (b) Few twigs to the sublingual gland.
 - (c) Branches to the anterior two-third of the tongue.

HYPOGLOSSAL NERVE

The hypoglossal nerve runs forwards, crosses internal carotid artery, external carotid artery, and loop of lingual before it enters the submandibular region by passing deep to the posterior belly of the digastric muscle. It continues its course forwards and upwards on the hyoglossus (below the lingual) and then on the genioglossus to enter the tongue. Here it supplies all the muscles of the tongue (intrinsic and extrinsic), except palatoglossus, which is not really a muscle of the tongue.

GLOSSOPHARYNGEAL NERVE

The glossopharyngeal nerve before entering the submandibular region descends on the medial side of the stylopharyngeus muscle, curves around its lower border to run forward on its lateral side and supplies it. Then it runs parallel with the lower border of the styloglossus and passes deep to the stylohyoid ligament to disappear underneath the posterior border of the hyoglossus in order to reach the tongue.

Its lingual branches convey both general and taste sensations from the posterior one-third of the tongue.

BLOOD VESSELS OF THE SUBMANDIBULAR REGION

Arteries

The arteries supplying the submandibular regions are:

1. **Facial artery:** The facial artery enters the submandibular region by passing deep to digastric and stylohyoid muscles, turns forwards above these muscles to reach the deep aspect of the angle of the mandible. Now it first hooks round the posterosuperior aspect of the submandibular gland, descends between the lateral surface of the gland and medial pterygoid muscle (Fig. 9.16), then hooks round the lower border of the mandible to reach the face. Before hooking round the lower border of the mandible it gives rise to **submental branch**.
2. **Lingual artery:** The lingual artery after forming a U-shaped loop above the tip of greater cornu of hyoid bone runs forwards deep to the hyoglossus above the hyoid bone and gives rise to two dorsalis lingual arteries, which supply **posterior one-third of the tongue and tonsil**.

Then it ascends along the anterior border of hyoglossus and lies on the genioglossus. Here it gives rise to **sublingual artery**, which supplies the **sublingual salivary gland**.

N.B. Before entering deep to the hyoglossus, it gives off *suprahyoid artery*, which runs along the superior border of the hyoid bone, lateral to the hyoglossus.

Veins

The veins present in the submandibular region are as follows:

1. **Vena comitantes nervi hypoglossi:** These two veins run along the hypoglossal nerve.
2. **Vena comitantes:** These two veins accompany the lingual artery and run deep to the hyoglossus muscle.

All of the above four veins join to form the lingual vein, which drains into the common facial or internal jugular vein.

SALIVARY GLANDS IN THE SUBMANDIBULAR REGION

There are two pairs of large salivary glands in the submandibular region. These are submandibular and sublingual salivary glands. The first is located mainly below the floor of the mouth and the latter above the floor of the mouth (Fig. 9.12).

SUBMANDIBULAR GLAND

The submandibular gland is one of the three pairs of paired salivary glands. This large salivary gland, about the size of a walnut, is situated partly below and partly deep to the posterior half of the mandible. It is half the size of the parotid gland and weighs about 10–20 g. It is a mixed type of gland (that is both mucus and serous in nature) but predominantly serous.

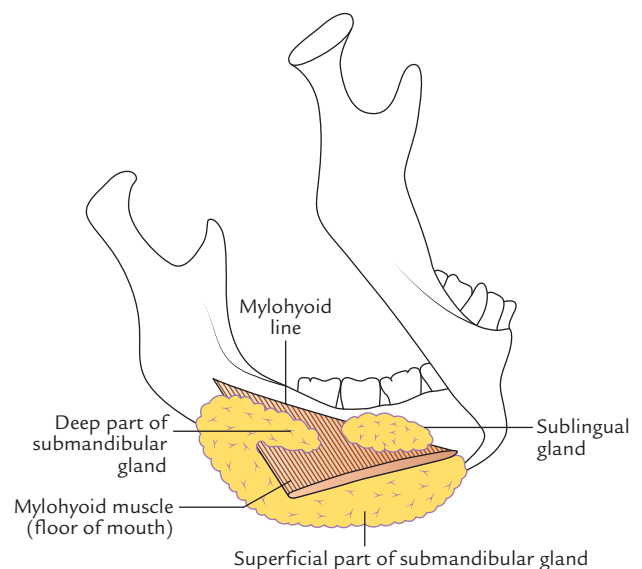


Fig. 9.12 Left submandibular and sublingual salivary glands.

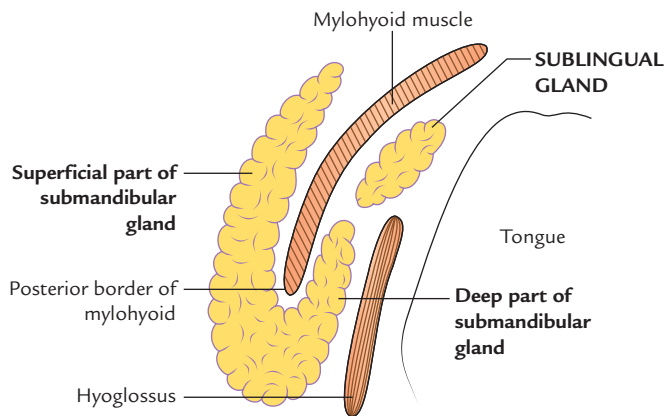


Fig. 9.13 Horizontal section through submandibular region showing the parts of submandibular gland. The sublingual salivary gland is also seen. Note the relationship of the sublingual gland with the deep part of the submandibular gland.

Parts

It consists of two parts: (a) a large superficial part and (b) a small deep part. The superficial part lies superficial to the mylohyoid muscle, while deep part lies deep to the mylohyoid muscle. The two parts are continuous with each other around the posterior border of the mylohyoid muscle (Fig. 9.13).

Superficial Part

This part of the gland is quite large and fills the anterior part of the digastric triangle extending upwards up to the mylohyoid line. The superficial part presents **two ends**—anterior and posterior and **three surfaces**—inferior, lateral, and medial.

The *anterior end* extends up to the anterior belly of the digastric muscle.

The *posterior end* extends up to the stylomandibular ligament, which separates the submandibular gland from the parotid gland. This end presents a groove produced by ascending limb of the cervical loop of the facial artery.

Fascial covering or capsule (Fig. 9.14)

The superficial part is partially enclosed between the two layers of investing layer of deep cervical fascia. At the greater cornu of hyoid bone the investing layer of deep cervical fascia splits into two laminae to enclose the superficial part. The superficial layer covers the inferior surface of the gland and is attached to the base of the mandible. The deep layer covers the medial surface of the gland and is attached to the mylohyoid line of the mandible.

Relations

The three surfaces of the superficial part have important relations:

- **Superficial surface** (inferior surface) from superficial to deep is covered by the following structures (Fig. 9.15):

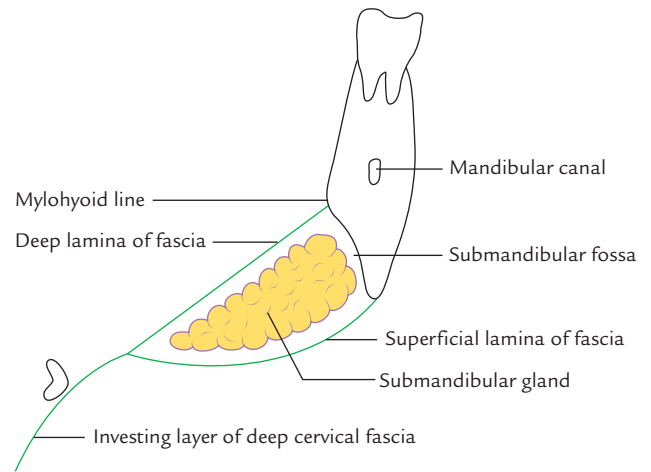


Fig. 9.14 Capsule of the superficial part of the submandibular gland.

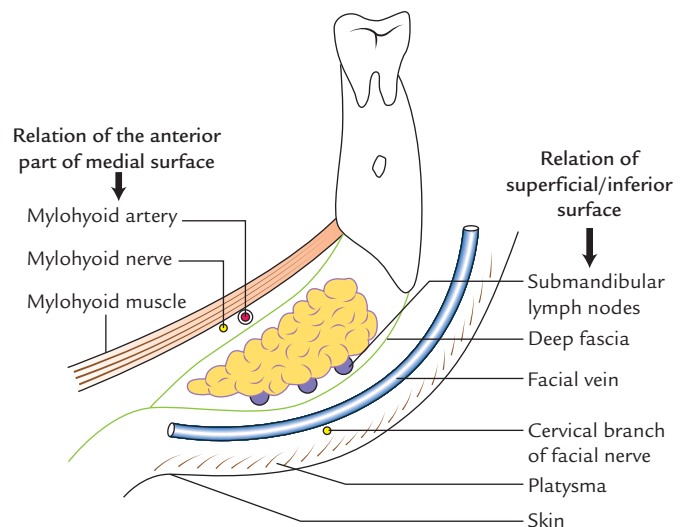


Fig. 9.15 Relations of the superficial (inferior) surface of the submandibular salivary gland. The relations of anterior part of the medial (deep) surface are also seen.

- Skin.
- Superficial fascia containing platysma and cervical branch of facial nerve.
- Deep fascia.
- Facial vein.
- Submandibular lymph nodes.
- **Lateral surface** is related to (Fig. 9.16):
 - Submandibular fossa on the inner aspect of the body of mandible.
 - Medial pterygoid muscle (near its insertion).
 - Facial artery.

It is important to note that the facial artery loops downwards and forwards between the bone and the gland, and then winds around the lower border of the body of the mandible at the anteroinferior angle of the mandible to reach the face (Fig. 9.16).

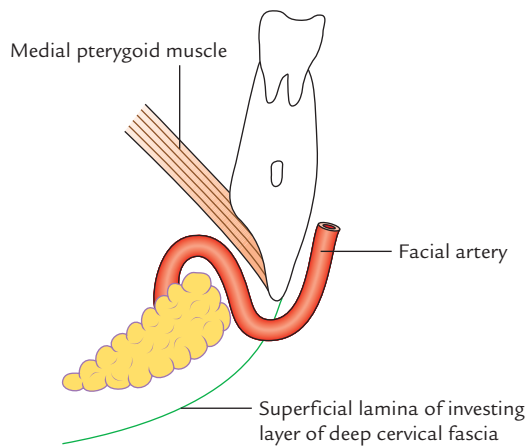


Fig. 9.16 Relations of the lateral surface.

- **Medial surface** is extensive and divided into three parts: anterior, middle, and posterior (Fig. 9.17):
 - (a) *Anterior part* is related to:
 - Mylohyoid muscle.
 - Submental branch of facial artery.
 - Mylohyoid nerve and vessels.
 - (b) *Middle (intermediate) part* is related to:
 - Hyoglossus muscle.
 - Styloglossus muscle.
 - Lingual and hypoglossal nerves.
 - Submandibular ganglion.
 - (c) *Posterior part* is related to:
 - Styloglossus muscle.
 - Stylohyoid ligament.
 - Glossopharyngeal nerve.
 - Wall of pharynx.

Deep Part

The deep part is small and lies on the hyoglossus muscle deep to the mylohyoid; *posteriorly* it is continuous with superficial part around the posterior border of the mylohyoid, and *anteriorly* it extends up to the sublingual salivary gland (Fig. 9.13).

Relations (Fig. 9.18)

Medial: Hyoglossus.

Lateral: Mylohyoid.

Superior: Lingual nerve and submandibular ganglion.

Inferior: Hypoglossal nerve accompanied by a pair of veins (Venae comitantes nervi hypoglossi).

Submandibular duct (Wharton's duct; Fig. 9.19)

The submandibular duct is about 5 cm long and emerges at the anterior end of the deep part. It runs forwards on the hyoglossus between the lingual and hypoglossal nerves. Near the anterior border of the hyoglossus, it is crossed by lingual nerve. It continues running forward between the sublingual gland and the genioglossus. Here it lies just deep to the mucus membrane of the oral cavity. Finally, it opens into the oral cavity on the summit of a *sublingual papilla* at the side of the frenulum of the tongue.

Blood supply

The gland is supplied by sublingual and submental arteries and drained by common facial and lingual veins.

Lymphatic drainage

The lymphatics from submandibular gland first drain into submandibular lymph nodes and subsequently into jugulo-digastric lymph nodes.

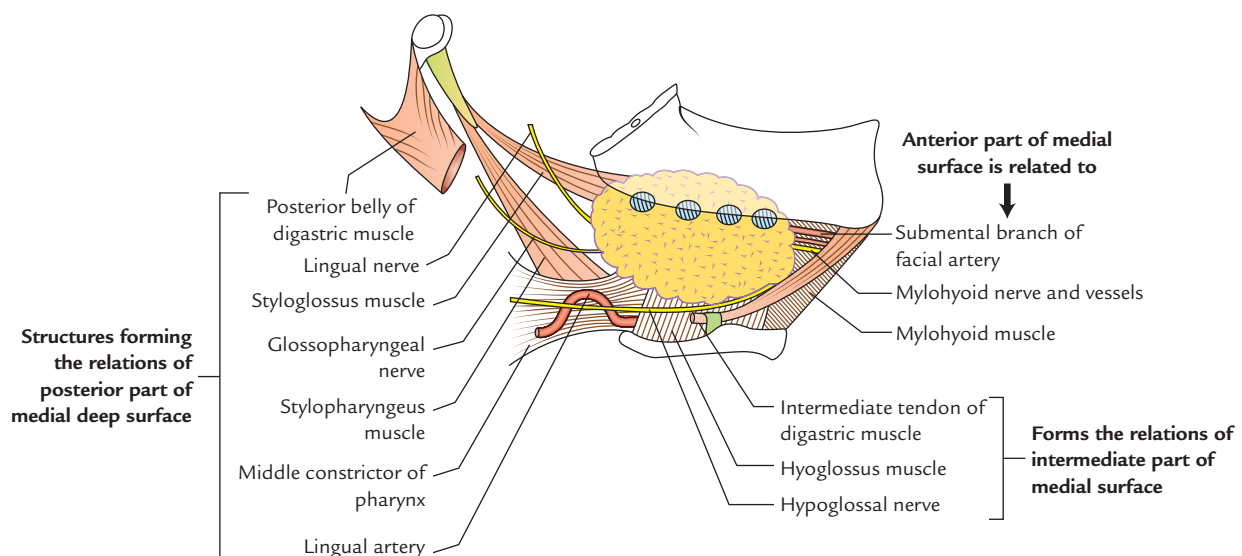


Fig. 9.17 Relations of the medial (deep) surface of the submandibular gland.

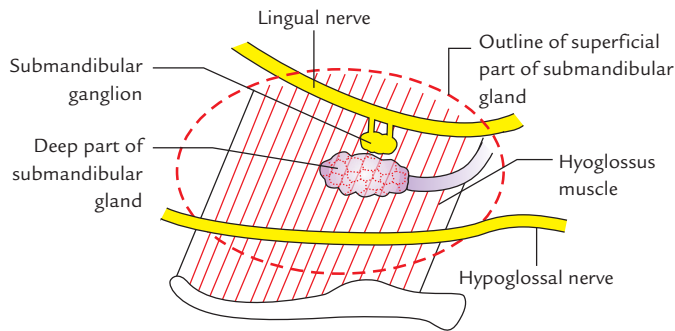


Fig. 9.18 Location and relations of the deep part of submandibular gland and submandibular ganglion. Red circle of broken line represents the superficial part of the submandibular gland.

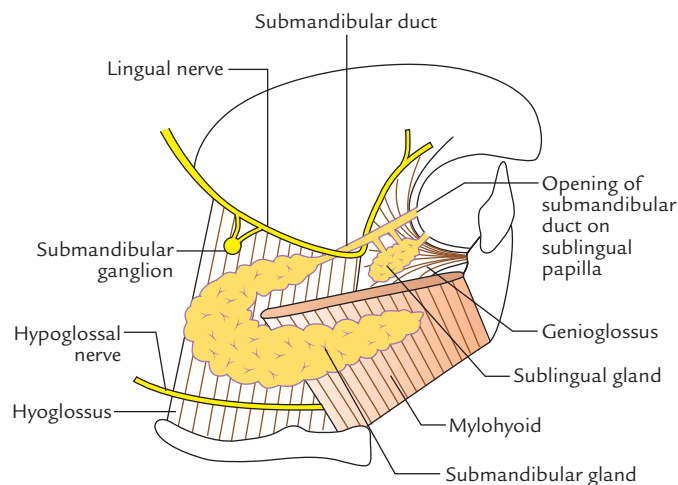


Fig. 9.19 Submandibular and sublingual ducts.

Nerve supply

The gland is supplied by parasympathetic, sympathetic, and sensory fibres (Fig. 9.21):

- Parasympathetic (secretomotor) supply:**
 - The preganglionic parasympathetic fibres arise from superior salivatory nucleus in the pons and pass successively through facial, chorda tympani, and lingual nerves; and terminate in the submandibular ganglion, which serves as a relay station.
 - The postganglionic fibres arise from this ganglion and directly supply the submandibular gland.
- Sympathetic supply:** The preganglionic fibres arise from T1 spinal segment and enter the cervical sympathetic trunk to relay in its superior cervical sympathetic ganglion. The postganglionic fibres arise from superior cervical sympathetic ganglion, form plexus around facial artery, and thus reach gland through this artery.
- Sensory supply:** The gland gets its sensory supply by the lingual nerve.

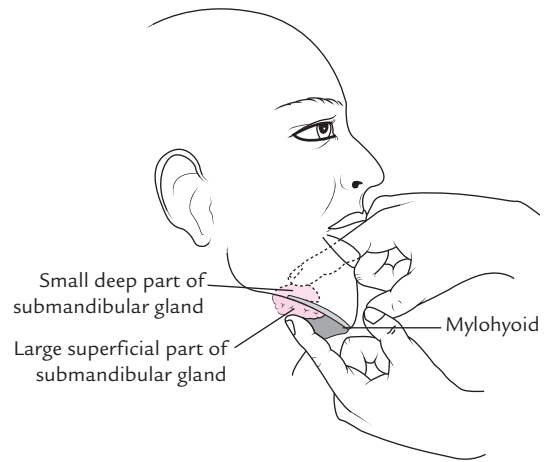


Fig. 9.20 Bimanual palpation of the submandibular gland. (Source: Fig. 6.7, Page 295, *Clinical and Surgical Anatomy, 2e*, Vishram Singh. Copyright Elsevier 2007, All rights reserved).

N.B. Earlier it was thought that only parasympathetic supply is secretomotor and sympathetic supply is vasomotor. Now it is established without doubt that both parasympathetic and sympathetic supplies are secretomotor. Parasympathetic stimulation produces watery secretion whereas sympathetic stimulation produces sticky mucus-rich secretion. In addition, sympathetic supply is vasomotor.

Clinical correlation

- The **formation of calculi in the submandibular gland and its duct** is more common than in the parotid duct for two reasons:
 - (a) Its secretion is more viscid.
 - (b) Its duct takes a tortuous and upward course, which hampers its smooth drainage (against gravity) into the floor of the mouth.
- The **excision of the submandibular gland** for calculus or tumor is done by skin incision below the angle of the mandible. Since the *marginal mandibular branch of facial nerve* passes one inch posteroinferior to the angle of the mandible before crossing its lower border, the incision therefore should be given 4 cm below the angle to avoid injury to this nerve.
- The **swellings of the submandibular gland can be palpated bimanually** by putting an index finger in the mouth and thumb below the angle of the jaw in relation to the position of gland (Fig. 9.20), because part of the gland lies in the oral cavity above the floor of the mouth and part outside the oral cavity below the floor of the mouth. The submandibular lymph nodes lying on the surface of the gland cannot be palpated bimanually as they lie below the floor of the mouth (oral diaphragm). Thus an enlarged submandibular gland can be differentiated from a mass of the submandibular lymph nodes by *bimanual palpation*.

- The stone in the submandibular duct can also be palpated manually within the mouth and can even be seen if sufficiently large.
- The stone is removed from within the mouth by incising the mucus membrane and duct over the stone.

SUBLINGUAL GLAND

This is smallest of the three pairs of large salivary glands. It lies in the floor of the mouth between the mucus membrane and the mylohyoid muscle. It is almond shaped and rests in the sublingual fossa of the mandible. It is separated from the base of the tongue by the submandibular duct. It is mostly mucus in nature and weighs about 3–4 g. The gland pours its secretion by a series of ducts, about 15 in number, into the oral cavity on the **sublingual fold**, but a few of them open into the submandibular duct.

N.B. The gland actually possesses about 20 ducts. Most of these ducts (*ducts of Rivinus*) open separately on the sublingual fold, while some ducts from anterior part of the gland unite to form the **sublingual duct (duct of Bartholin)**, which opens into the submandibular duct.

Nerve supply

It is similar to that of submandibular salivary gland.

Blood supply

The gland is supplied by the sublingual and submental arteries.

Lymphatic drainage

The lymphatics from the sublingual gland drain into submental and submandibular lymph nodes.

Clinical correlation

A **ranula** is a large mucus retention cyst in the floor of mouth arising from sublingual salivary gland. Sometimes it may arise from accessory salivary glands, called glands of Blandin and Nuhn, present in the floor of mouth. The swelling is soft, bluish in color, and transilluminates. It looks like the belly of frog (*Rana hexadactyla*), hence the name ranula.

DEVELOPMENT OF THE SUBMANDIBULAR AND SUBLINGUAL SALIVARY GLANDS

The submandibular and sublingual glands develop as outgrowths from the endodermal lining of the floor of the mouth (at alveololingual sulcus). The submandibular gland arises from a single large bud whereas sublingual gland arises from a series of small buds, which retain their connection with the floor of the mouth. As a result the submandibular gland pours its secretion by a single duct and sublingual gland by several ducts in the floor of the mouth.

N.B. The parotid gland develops as an outgrowth of ectodermal lining of the vestibule of the mouth.

To have a clear concept about three major salivary glands, they are compared in Table 9.2.

Table 9.2 Distinguishing features of the parotid, submandibular, and sublingual salivary glands

	Parotid gland	Submandibular gland	Sublingual gland
Location	Near the ear	Below the mandible	Below the tongue
Development	Ectodermal	Endodermal	Endodermal
Size	Largest (25 g)	Smaller (10–20 g)	Smallest (3–4 g)
Shape	Pyramidal shaped	J-shaped	Almond shaped
Duct and its site of opening in oral cavity	Parotid duct opens into vestibule of oral cavity opposite the second upper molar tooth	Submandibular duct opens into the floor of oral cavity proper on summit of sublingual papilla at the side of frenulum of the tongue	Series of ducts open into the floor of the oral cavity proper on the sublingual fold
Secretomotor nerve supply	<ul style="list-style-type: none"> • Through lesser petrosal nerve • Preganglionic fibres arise from inferior salivatory nucleus • Postganglionic fibres arise from otic ganglion 	<ul style="list-style-type: none"> • Through chorda tympani • Preganglionic fibres arise from superior salivatory nucleus • Postganglionic fibres arise from submandibular ganglion 	<ul style="list-style-type: none"> • Through chorda tympani nerve • Preganglionic fibres arise from superior salivatory nucleus • Postganglionic fibres arise from submandibular ganglion
Nature of secretion	Serous	Both serous and mucus	Mucus

COMPARISON OF THE THREE LARGE SALIVARY GLANDS

The comparative characteristics of the three salivary glands are presented in Table 9.2.

SUBMANDIBULAR GANGLION (LANGLEY'S GANGLION)

It is a parasympathetic ganglion, which serves as a relay station for secretomotor fibres supplying the submandibular and sublingual salivary glands.

Topographically, it is connected to the trigeminal nerve (lingual nerve) but *functionally* it is related to the facial nerve (through its chorda tympani branch).

Location

This ganglion is of the size of a pin-head and situated on the outer surface of the hyoglossus muscle. It is suspended from lingual nerve by two twigs. The proximal twig is afferent to the ganglion and distal root is efferent to the ganglion.

Relations (Fig. 9.18)

Above: Lingual nerve.

Below: Deep part of the submandibular gland.

Medial: Hyoglossus muscle.

Lateral: Submandibular gland (superficial part).

Roots (Fig. 9.21)

The submandibular ganglion has three roots, *viz.*: parasympathetic, sympathetic, and sensory.

1. **Parasympathetic root:** It is derived from lingual nerve. The preganglionic fibres arise from superior salivatory nucleus situated in pons and pass successively through facial nerve, chorda tympani, and lingual nerves to reach the ganglion where they relay. The postganglionic fibres arise from ganglion and directly supply the gland.

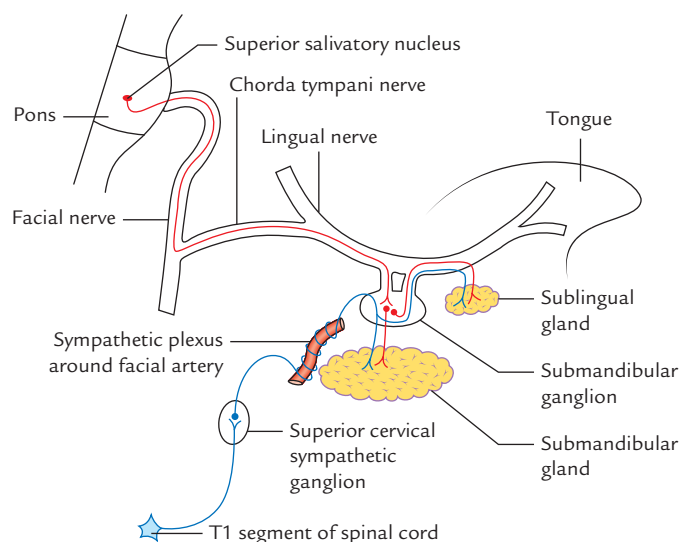


Fig. 9.21 Submandibular ganglion and its connections.

2. **Sympathetic root:** It is derived from sympathetic plexus around the facial artery. The preganglionic fibres arise from the first thoracic spinal segment (T1) and enter the cervical sympathetic chain to relay in superior ganglion. The postganglionic fibres arise from superior cervical sympathetic ganglion, form plexus around the facial artery to pass through the ganglion without relay and supply the blood vessels in the submandibular and sublingual salivary glands.
3. **Sensory root:** It is derived from lingual nerve.

Branches

The branches of the submandibular ganglion are:

1. Five to six branches, which supply the submandibular gland.
2. Other fibres join the lingual nerve to supply the sublingual and anterior lingual glands.

SURGICAL PLANES OF THE SUBMANDIBULAR REGION

During surgery in the submandibular region, the incision is given about 4 cm below the mandible. After giving incision, a surgeon must keep in mind that deep structures in this region are arranged in four muscular planes (Fig. 9.22). These structures are already described under the section on muscles of the submandibular region. However, for an overview and convenience of understanding these planes are summarized in the following text (Fig. 9.22).

First Muscular Plane (Fig. 9.22A)

The major structures in this are (a) digastric muscle and (b) most of the superficial part of the submandibular gland. The submandibular lymph nodes lie in close relation to the submandibular gland and are partly hidden under the body of the mandible. Note that superficial part of the submandibular gland partly overlaps both anterior and posterior bellies of the digastric muscle. The facial artery emerges on face by winding around the lower border of the mandible.

Second Muscular Plane (Fig. 9.22B)

The major structures in this plane are (a) mylohyoid muscle and (b) mylohyoid nerve and vessels emerge from under cover of the mandible. There is also a large submental branch of the facial artery. The hypoglossal nerve runs horizontally forward on hyoglossus accompanied by venae comitantes nervi hypoglossi.

Third Muscular Plane (Fig. 9.22C)

The major structures in this plane are (a) lingual and hypoglossal nerves, which communicate with each other near the anterior border of hyoglossus, (b) deep part of the

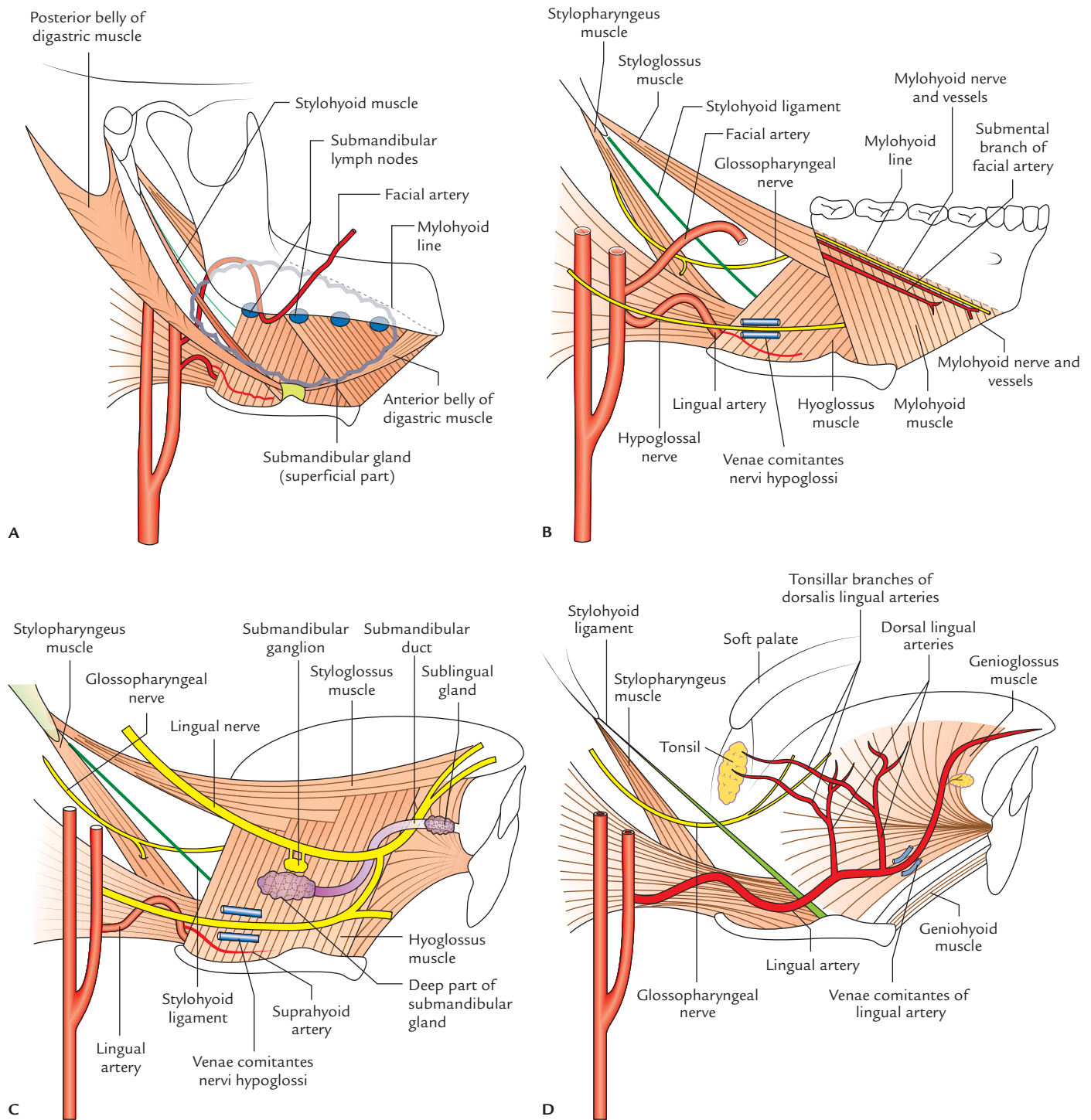


Fig. 9.22 Planes of the submandibular region: A, first muscular plane; B, second muscular plane; C, third surgical (muscular) plane; D, fourth surgical (muscular) plane.

submandibular gland and submandibular duct, (c) submandibular ganglion, and (d) styloglossus muscle being crossed superficially by the lingual nerve. Note the double crossing of submandibular duct by lingual nerve. The structures passing deep to posterior border of hyoglossus are also seen.

Fourth Muscular Plane (Fig. 9.22D)

The major structures in this plane are genioglossus muscle, middle constrictor of the pharynx, and lingual artery and its branches of distribution are the key features of this plane.

Golden Facts to Remember

- | | |
|--|---|
| ▶ Key muscle of the submandibular region | Hyoglossus |
| ▶ Smallest of the three pairs of large salivary glands | Sublingual salivary gland |
| ▶ Wharton's duct | Submandibular duct |
| ▶ Ducts of Rivinus | Ducts of sublingual salivary gland |
| ▶ Langley's ganglion | Submandibular ganglion |
| ▶ Most commonly damaged artery during surgical removal of the submandibular gland | Facial artery |
| ▶ Most commonly damaged major nerve during and surgical removal of submandibular gland | Lingual nerve is (inadvertently) damaged during ligation and division of the submandibular duct |

Clinical Case Study



A 35-year-old woman went to her family physician and complained that she felt pain and swelling beneath her right jaw each time she ate a meal. She also told the doctor that pain and swelling more or less completely resolves after taking meal for a time until she takes her next meal—when the same symptoms appear again. On examination the physician made following observations.

- Presence of swelling beneath the posterior portion of her right mandible.
- The swelling was bimanually palpable.

He referred the case to ENT surgeon who advised CT scan of the region. CT scan confirmed the presence of a large stone in the submandibular gland. He performed a surgery and removed her submandibular gland. After surgery she noticed a weakness at the corner of her mouth.

Questions

1. Why is formation of calculus more common in the submandibular gland as compared to the parotid gland?
2. Why is submandibular swelling bimanually palpable?
3. Why did the patient feel weakness at the corner of her mouth after surgery?

Answers

1. It is because secretion of the submandibular gland is more viscous than that of parotid gland. Secondly, the course of submandibular duct is upwards and tortuous, which hampers the efficient drainage of its secretion (also refer page 127).
2. Because it lies on both sides (i.e., above and below) of the floor of the mouth.
3. Due to traction on marginal mandibular branch of the facial nerve.

Infratemporal Fossa, Temporomandibular Joint, and Pterygo-palatine Fossa

INFRATEMPORAL FOSSA

The infratemporal fossa is the space beneath the base of the skull, between the side wall of the pharynx and ramus of the mandible. It communicates with the temporal fossa through a gap deep to the zygomatic arch. It is also referred to as the parapharyngeal space or lateral pharyngeal space.

BOUNDARIES

The boundaries of infratemporal fossa (Fig. 10.1) are:

- Roof:** Formed by the infratemporal surface of the greater wing of the sphenoid. It is pierced by foramen spinosum and foramen ovale.
- Medial wall:** Formed by lateral surface of the lateral pterygoid plate of the sphenoid. It is separated from the anterior wall by pterygomaxillary fissure.
- Lateral wall:** Formed by the ramus of the mandible.
- Anterior wall:** Formed by the infratemporal surface of the maxilla. It is separated from roof by inferior orbital fissure.
- Floor:** Open and extends up to the level of the base of the mandible.
- Posterior wall:** Formed by styloid process of the temporal bone.

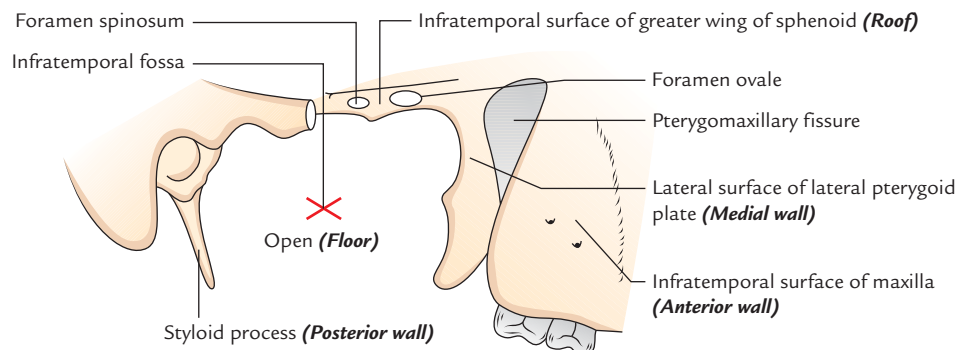


Fig. 10.1 Boundaries of the infratemporal fossa.

COMMUNICATIONS (Figs 10.2 and 10.3)

The infratemporal fossa communicates:

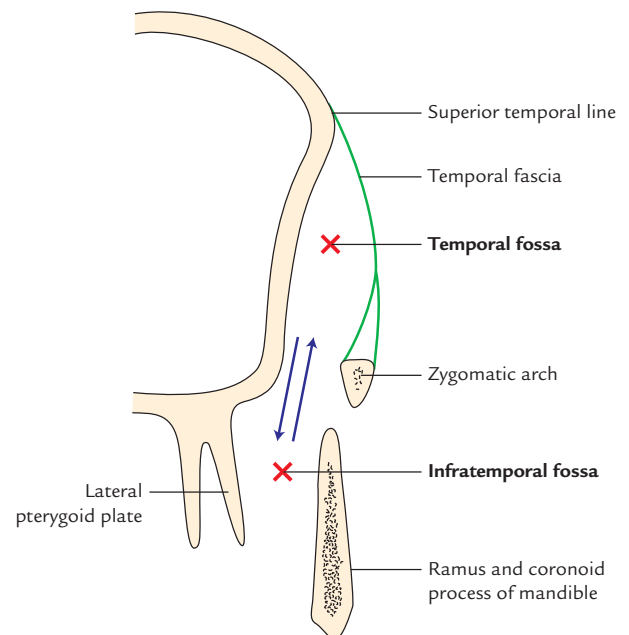


Fig. 10.2 Communication (arrows) between infratemporal and temporal fossae.

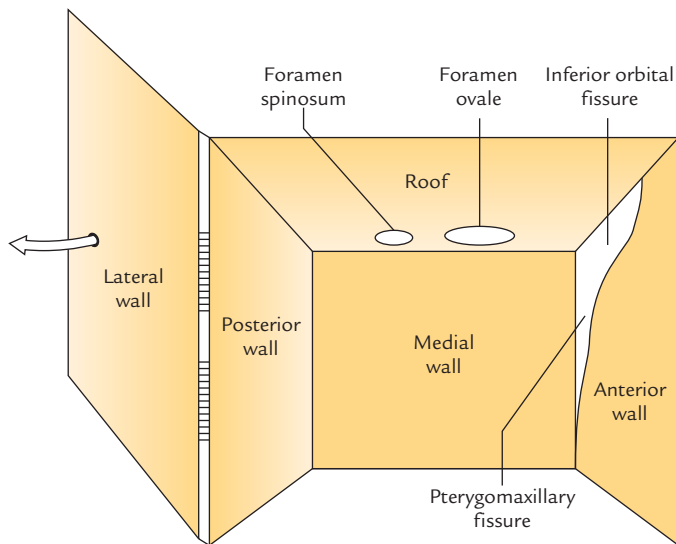
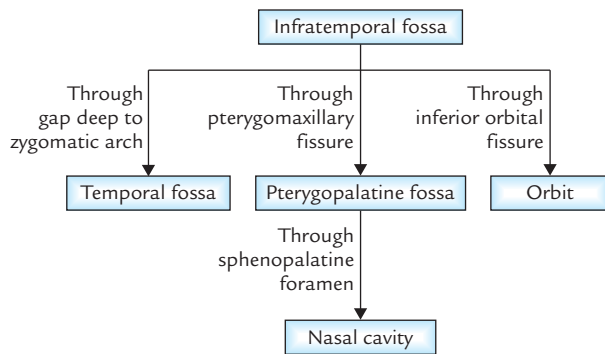


Fig. 10.3 Schematic diagram to show the boundaries and communications of the infratemporal fossa.

- above with the temporal fossa through a gap, deep to zygomatic arch; and middle cranial fossa through foramen ovale and foramen spinosum,
- below it is continuous with the tissue spaces of the neck lateral to the pharynx,
- with the pterygopalatine fossa through pterygomaxillary fissure, and
- with the orbit through inferior orbital fissure.

All communications are presented in Flowchart 10.1.



Flowchart 10.1 Communications of the infratemporal fossa.

N.B. The infratemporal fossa can be best visualized as a hollow cube without floor (Fig. 10.3).

CONTENTS

The major structures present in the infratemporal fossa are:

- Muscles:** Lateral pterygoid, medial pterygoid, and tendon of temporalis.

- Blood vessels:** Maxillary artery, maxillary vein, and pterygoid venous plexus.
- Neural structures:** Mandibular nerve, chorda tympani nerve, and otic ganglion.

MUSCLES

Lateral Pterygoid (Fig. 10.4)

It is a short, thick conical muscle with its apex pointing backwards. It passes backwards and slightly laterally from the roof and medial wall of the fossa to the neck of the mandible.

Origin

The lateral pterygoid consists of two heads, upper and lower:

- The **upper smaller head** arises from the infratemporal surface and crest of the greater wing of the sphenoid bone.
- The **lower larger head** arises from the lateral surface of the lateral pterygoid plate of the sphenoid bone.

Insertion

The fibres of two heads run backwards and laterally, and converge to form a thick tendon, which is inserted into:

- Pterygoid fovea on the front of the neck of the mandible.
- Articular disc and capsule of the temporomandibular joint.

Nerve supply

Lateral pterygoid is supplied by a branch of anterior division of the mandibular nerve.

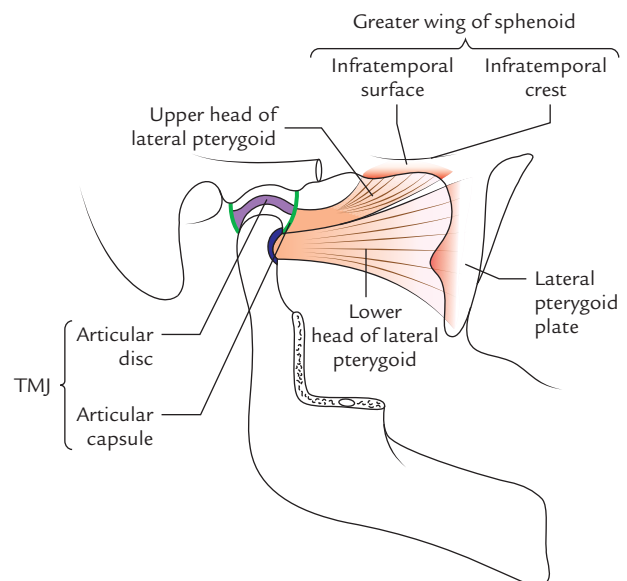


Fig. 10.4 Origin and insertion of the lateral pterygoid muscle.

Actions

1. Lateral pterygoids of two sides depress the mandible (opens the mouth) by pulling forward the condylar processes of the mandible and the articular discs of the temporomandibular joints.
2. Lateral and medial pterygoid muscles of two sides acting together protrude the mandible.
3. Lateral and medial pterygoid muscles of the two sides contract alternately to produce side-to-side movements of the lower jaw as in chewing.

N.B.

- The lower head of lateral pterygoid passes between the two heads of the medial pterygoid muscle.
- It is the only masticatory muscle, which opens the mouth.
- The articular disc of temporomandibular joint is developmentally a part of tendon of lateral pterygoid muscle.

Relations (Fig. 10.5)

The lateral pterygoid is regarded as the **key muscle of the infratemporal region** because its relations provide a fair idea about the layout of structures in this region. Its relations are:

Superficial:

1. Ramus of the mandible.
2. Masseter.
3. Tendon of temporalis.
4. Superficial head of medial pterygoid.
5. Maxillary artery and its temporal and masseteric branches.

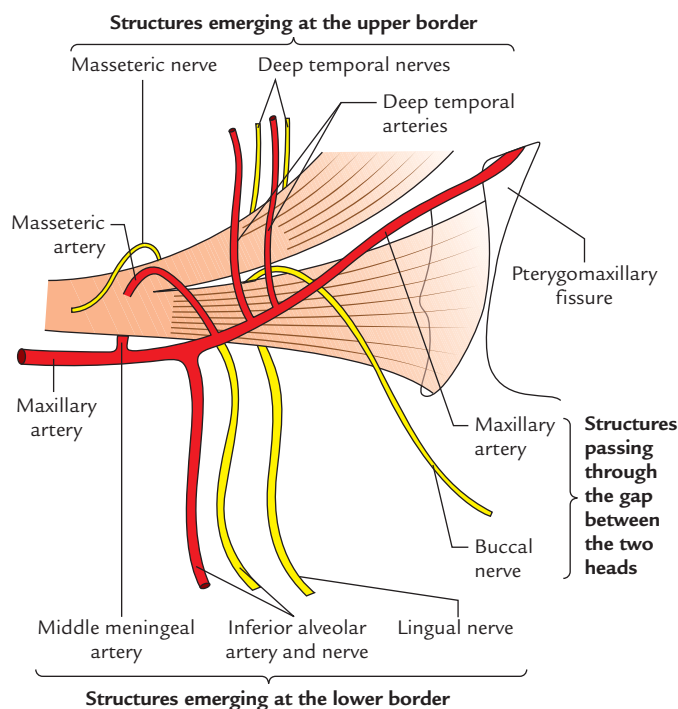


Fig. 10.5 Relation of the lateral pterygoid muscle.

Deep:

1. Mandibular nerve.
2. Middle meningeal artery.
3. Sphenomandibular ligament.
4. Deep head of medial pterygoid muscle.

Structures emerging at the upper border:

1. Deep temporal nerves (two in number).
2. Masseteric nerve.

Structures emerging at the lower border:

1. Inferior alveolar nerve and artery.
2. Lingual nerve.
3. Middle meningeal artery (it passes up deep to the lower border).

Structures passing through the gap between the two heads:

1. **Maxillary artery**, which enters the gap to reach the pterygopalatine fossa through pterygomaxillary fissure.
2. **Buccal nerve**, a branch of mandibular nerve. It comes out through the gap to provide sensory innervation to the skin and mucus membrane of the cheek.

Medial Pterygoid (Fig. 10.6)

The medial pterygoid is a thick quadrilateral muscle and consists of two heads: superficial and deep.

Origin

1. The small **superficial head** (a small slip of muscle) arises from maxillary tuberosity and lateral surface of the pyramidal process of palatine bone.
2. The **large deep head** (forming the bulk of muscle) arises from medial surface of the lateral pterygoid plate and grooved surface of the pyramidal process of palatine bone.

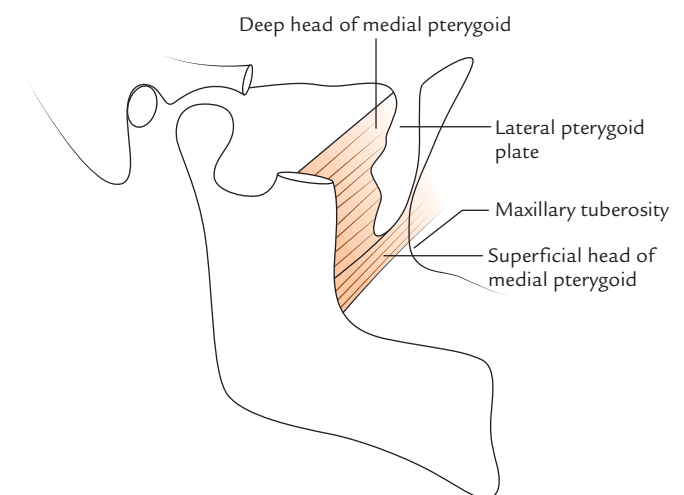


Fig. 10.6 Origin and insertion of the medial pterygoid muscle.

Insertion

The fibres run downwards, backwards, and laterally to be inserted by a strong tendinous lamina into a roughened area on the posteroinferior part of the medial surface and angle of ramus of mandible as high as the mandibular foramen and as forwards as the mylohyoid groove (Fig. 9.11).

Nerve supply

The medial pterygoid is supplied by a *nerve to medial pterygoid*, a branch from the main trunk of the mandibular nerve.

Relations

Superficial (Fig. 10.7):

1. Lingual nerve.
2. Inferior alveolar nerve.
3. Inferior alveolar vessels.

Deep:

1. Levator palati and tensor palati muscles.
2. Superior constrictor of pharynx.
3. Styloglossus and stylopharyngeus muscles.

Actions

1. Medial pterygoids of two sides elevate the mandible to help in closing of mouth.
2. Acting with lateral pterygoids, the medial pterygoids protrude the mandible.
3. When medial and lateral pterygoids of one side act together, the corresponding side of the mandible is rotated forwards and to the opposite side.
4. Lateral and medial pterygoids of two sides when contract alternately produce side-to-side movements, which are used to grind the food.

BLOOD VESSELS**MAXILLARY ARTERY (Figs 10.7 and 10.8)**

The maxillary artery is the larger terminal branch of the external carotid artery.

It arises behind the neck of the mandible, runs horizontally forward up to the lower border of lower head of lateral pterygoid. Now it turns upwards and forwards, crosses the lower head of lateral pterygoid superficially (sometimes deep). After emerging between the two heads of lateral pterygoid it enters the pterygopalatine fossa by passing

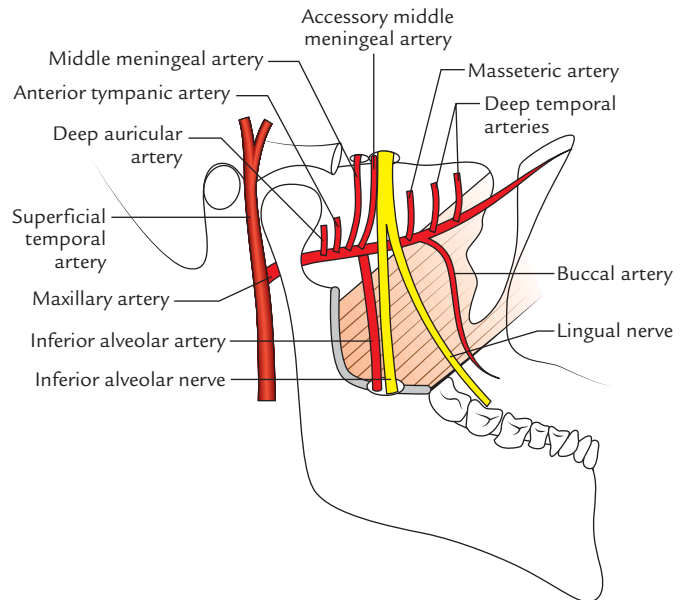


Fig. 10.7 Superficial relations of the medial pterygoid muscle.

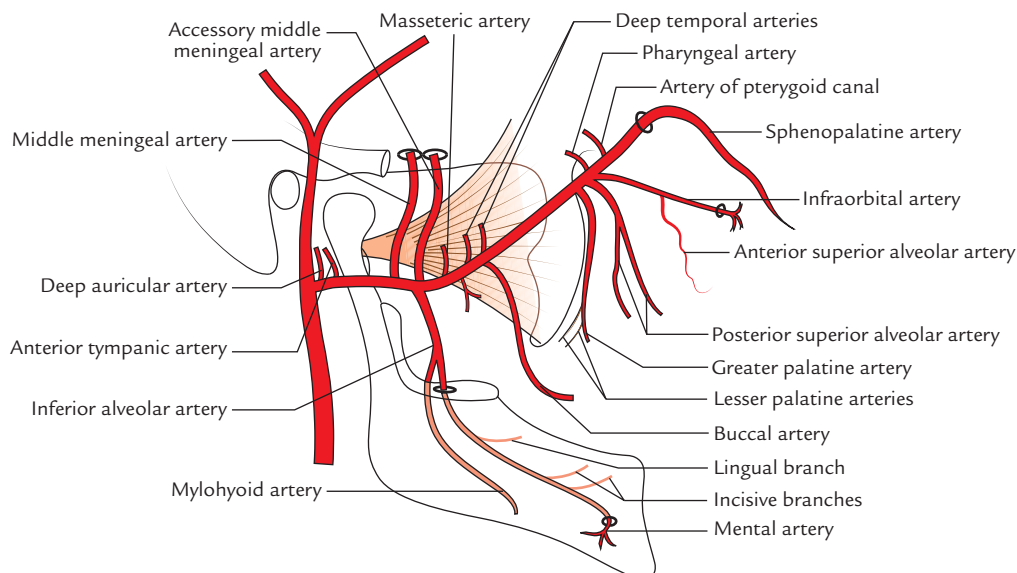


Fig. 10.8 Branches of the maxillary artery.

through pterygomaxillary fissure. Here it ends by giving its terminal branches.

The maxillary artery has a wide territory of distribution. It supplies:

- (a) upper and lower jaws,
- (b) muscles of temporal and infratemporal fossae,
- (c) nose and paranasal sinuses,
- (d) palate and roof of pharynx,
- (e) external and middle ear,
- (f) pharyngotympanic tube, and
- (g) dura mater.

N.B. The maxillary artery enters the infratemporal fossa by passing forwards, between the neck of mandible and the sphenomandibular ligament.

Parts and Relations

The maxillary artery is divided into three parts by the lower head of lateral pterygoid muscle. The parts are:

1. **First part (mandibular part):** From beginning (origin) to lower border of lateral pterygoid. It lies between the neck of the mandible laterally and sphenomandibular ligament medially. The auriculotemporal nerve lies above this part.
2. **Second part (pterygoid part):** From lower border to the upper border of the lower head of lateral pterygoid (i.e., second part lies on or deep to lower head of lateral pterygoid).
3. **Third part (pterygopalatine part):** From upper border of the lower head of lateral pterygoid to pterygopalatine fossa. In pterygopalatine fossa it lies in front of the pterygopalatine ganglion.

N.B.

- Most of the branches from the first and second parts of maxillary artery accompany the branches of the mandibular nerve.
- Branches from the third part of the maxillary artery accompany the branches of maxillary nerve and pterygopalatine ganglion.
- Branches from the second part of the maxillary artery are muscular only and supply muscles of mastication.
- All the branches (1st and 3rd part) of the maxillary artery pass through bony foramina and fissures except branches from its second part.

Branches of the Maxillary Artery (Fig. 10.8)

I. Branches from the First Part (Five Branches)

1. **Deep auricular artery**—passes upwards and backwards to enter the external acoustic meatus by piercing its floor and supplies:
 - (a) skin of external acoustic meatus, and
 - (b) outer surfaces of tympanic membrane.

2. **Anterior tympanic artery**—enters the tympanic cavity by passing through petrotympanic fissure and it supplies the **inner surface of the tympanic membrane**.

3. **Middle meningeal artery**—is the largest meningeal branch. It supplies **meninges** as well as the **skull bone**.

Clinically it is the most important branch of the maxillary artery.

The middle meningeal artery arises from the first part of the maxillary artery. It ascends upwards deep to the lateral pterygoid, behind the mandibular nerve. Passing between the two roots of the auriculotemporal nerve, to enter the cranial cavity through foramen spinosum in company with meningeal branch of mandibular nerve (nervus spinosus).

As it emerges in the cranial cavity, it courses laterally on the floor of the middle cranial fossa and turns upwards and forwards on the greater wing of the sphenoid, where it divides into frontal and parietal branches:

- (a) *Frontal (anterior) branch*, courses up towards the pterion and then curves backwards to ascend towards the vertex, lying over the precentral gyrus of the cerebral hemisphere. In the region of pterion the artery frequently lies in a bony tunnel in the parietal bone for a centimeter or more.
- (b) *Parietal (posterior) branches* arch backwards on the squamous part of the temporal bone, cross the lower border of the parietal bone in front of its mastoid angle; here it divides into branches, which spread out as far as lambda. It lies along the superior temporal gyrus.

Distribution: The middle meningeal artery and its branches lie outside the dura and deep to the inner surface of the skull. Both of these are supplied by the artery.

N.B. The middle meningeal artery and its branches are accompanied by corresponding veins, which lie between the artery and the bone.

4. **Accessory middle meningeal artery**—runs upwards and enters the cranial cavity through foramen ovale.

It supplies **meninges** and structures in the **infratemporal fossa**.

5. **Inferior alveolar/dental artery**—runs downwards between the sphenomandibular ligament and the ramus of the mandible, enters the mandibular foramen, runs through the mandibular canal, supplies molar and premolar teeth and adjoining gum. It then divides into mental and incisive branches.

The incisive branch supplies the **canine and incisor teeth**. The mental artery emerges through the mental foramen to supply the **skin of the chin**. Before entering the mandibular foramen the inferior alveolar artery gives off two branches, namely,

- (a) *Lingual branch*: accompanies the lingual nerve and supply the **mucous membrane of the cheek**.
- (b) *Mylohyoid branch*: pierces the lower end of the sphenomandibular ligament, passes downwards and forwards to run in the mylohyoid groove. It supplies the **mylohyoid muscle**.

II. Branches from the Second Part (Four Branches)

1. **Deep temporal arteries (usually two in number)**—ascend up on the lateral aspect of the skull deep to the temporalis muscle, which they supply.
2. **Pterygoid branches**—supply the medial and lateral pterygoid muscles.
3. **Masseteric artery**—passes laterally through the mandibular notch and supplies the masseter muscle from its deep surface.
4. **Buccal artery**—supplies buccinator muscle.

III. Branches from the Third Part (Six Branches)

1. **Posterior superior alveolar artery** arises from maxillary artery just before it enters the pterygomaxillary fissure. It divides into two or three branches, which enter the foramina on the posterior surface of the body of maxilla, runs into alveolar canals and supply the molar and premolar teeth and mucus membrane of maxillary air sinus.
2. **Infraorbital artery** also arises from maxillary artery just before it reaches the pterygopalatine fossa. The artery passes successively through inferior orbital fissure, infraorbital groove, and infraorbital canal, and appears on the face through the infraorbital foramen. It gives the following branches:

In the orbit:

- (a) Branches to orbital contents.
- (b) **Middle superior alveolar artery** to premolar teeth.
- (c) **Anterior superior alveolar artery**, which descends through canaliculus sinuosus in the anterior wall of the maxillary sinus. It supplies the maxillary air sinus, and canine and incisor teeth of the upper jaw.

In the face, It gives off branches to supply the lacrimal sac, medial angle of the eye, side of nose, and upper lip.

3. **Greater palatine artery** passes downwards in the greater palatine canal and appears in the oral cavity at the posterolateral corner of the hard palate through the greater palatine foramen. Now it runs forwards in the groove along the alveolar arch to the incisive fossa where it enters the lateral incisive canal to enter the nasal cavity. It supplies the roof of the mouth and adjoining gum, while in the greater palatine canal the artery gives off lesser palatine arteries that emerge through foramina of the same name and supply the soft palate and tonsil.
4. **Pharyngeal artery** passes backwards through the palatovaginal canal and supplies the mucus membrane of the nasopharynx, auditory tube, and the sphenoidal air sinus.
5. **Artery of pterygoid canal** runs backwards in the pterygoid canal and supplies the pharynx, auditory tube, and the tympanic cavity.
6. **Sphenopalatine artery** is considered as the continuation of the maxillary artery. It is the most important branch of the third part of the maxillary artery. It enters the nasal cavity in the posterior part of the superior meatus through sphenopalatine foramen. Here it divides into:
 - (a) posterior lateral nasal, and
 - (b) posterior septal branches.

The posterior lateral nasal branches supply the lateral wall of the nose and sphenoidal and ethmoidal air sinuses, the posterior septal branches cross the undersurface of the body of the sphenoid, and then pass forwards and downwards along the nasal septum. One of the branches of this group is long, runs in a groove on the vomer towards the incisive canal and anastomoses with the terminal branch of the greater palatine artery.

The branches of maxillary artery are summarized in Table 10.1.

Table 10.1 Branches of the maxillary artery

	First part	Second part	Third part
Branches	Five	Four	Six
1.	Deep auricular artery	Deep temporal	Posterior superior alveolar (dental) artery
2.	Anterior tympanic artery	Pterygoid branches	Infraorbital artery
3.	Middle meningeal artery	Masseteric artery	Greater palatine artery
4.	Accessory meningeal artery	Buccal artery	Pharyngeal artery
5.	Inferior alveolar artery		Artery of pterygoid canal
6.			Sphenopalatine artery

MAXILLARY VEIN AND PTERYGOID VENOUS PLEXUS

Maxillary Vein

It is a short venous trunk, which accompanies the first part of the maxillary artery. It is formed by the confluence of veins from the pterygoid venous plexus and passes backwards between the sphenomandibular ligament and the neck of the mandible. Within the parotid gland it unites with the superficial temporal vein to form the retromandibular vein.

Pterygoid Venous Plexus

It is a network of very small veins that lie around and within the lateral pterygoid muscle.

The pterygoid venous plexus communicates:

- with inferior ophthalmic vein via inferior orbital fissure,
- with cavernous sinus by emissary veins via foramen ovale or foramen of Vesalius, and
- with facial vein through the deep facial vein.

The plexus is drained by maxillary vein which is formed at the lower border of the lateral pterygoid muscle.

N.B. The pterygoid venous plexus is sometimes referred to as a **peripheral heart** for during yawning when the mouth is widely open due to contraction of lateral pterygoid muscle, the stagnant venous blood is pumped up into the cavernous sinus and maxillary vein. Possibly this is the reason why people yawn in the morning when they get up from sleep.

NEURAL STRUCTURES

The infratemporal fossa contains the mandibular nerve and its branches, chorda tympani nerve, and otic ganglion.

MANDIBULAR NERVE (Fig. 10.9)

The mandibular nerve is the largest of the three divisions of the trigeminal nerve. It is a mixed nerve, consisting of both sensory and motor fibres. It is a nerve of the first pharyngeal arch, hence supplies all the structures derived from this arch, e.g., muscles of mastication.

Course and Relations

The mandibular nerve is the largest of three divisions of trigeminal nerve. It begins in the middle cranial fossa as two roots: a larger sensory root and a smaller motor root. The **large sensory root** arises from lateral convex part of the trigeminal ganglion and immediately leaves the cranial cavity by passing through foramen ovale to enter the infratemporal fossa. The small motor root arises from the pons, lies deep to the trigeminal ganglion and the sensory root. It also passes through foramen ovale to join the sensory root just below the foramen ovale in the infratemporal fossa, thus forming the main trunk. The mandibular nerve trunk is short and after a short course divides into a small anterior and large posterior division.

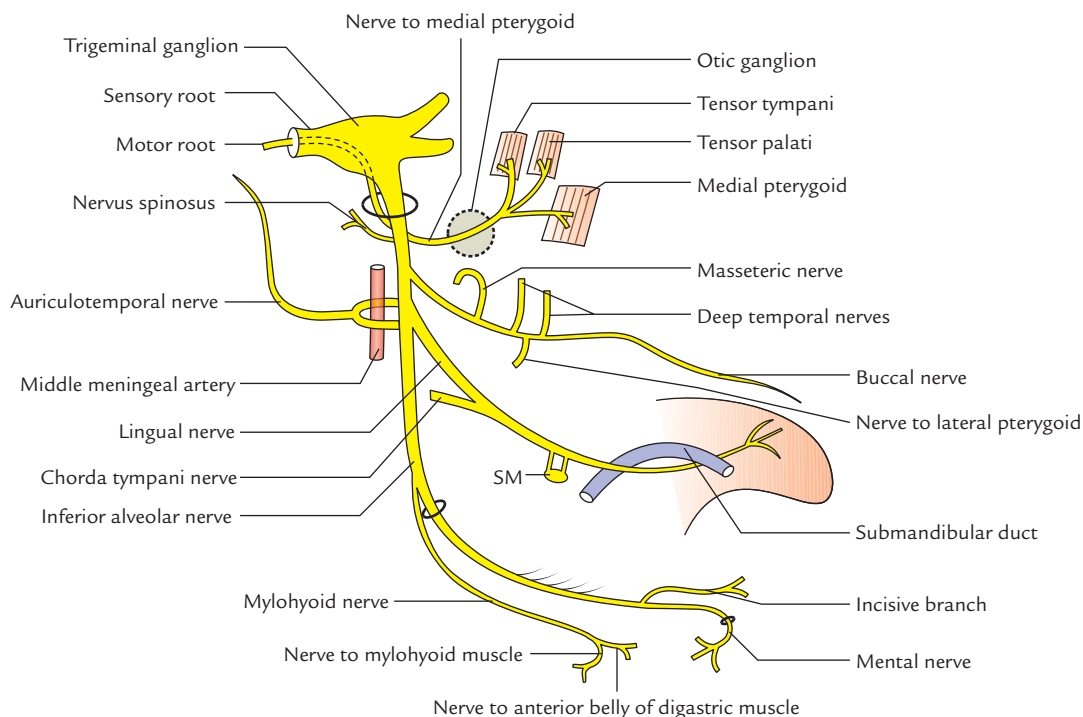


Fig. 10.9 Course and distribution of the mandibular nerve (SM = submandibular ganglion).

Relations of Trunk of Mandibular Nerve in the Infratemporal Fossa

Medial: Tensor palati muscle and otic ganglion.

Lateral: Upper head of lateral pterygoid muscle.

Posterior: Middle meningeal artery.

Anterior: Posterior border of lateral pterygoid plate.

Branches

From the Main Trunk

Two branches arise from the main trunk, a sensory branch (nervus spinosus) and a motor branch (nerve to medial pterygoid):

1. **Nervus spinosus (meningeal branch):** It takes a recurrent course to enter the cranial cavity through foramen spinosum with middle meningeal artery and supplies the dura mater of the middle cranial fossa.
2. **Nerve to medial pterygoid:** It arises from the medial aspect of the main trunk, close to the otic ganglion traverses through the ganglion and supplies the medial pterygoid from its deep aspect. In addition to medial pterygoid it also supplies tensor palati and tensor tympani muscles.

From the Anterior Division

The anterior division is mainly motor and gives branches to all muscles of mastication except medial pterygoid, which is supplied by nerve to medial pterygoid from the main trunk. The branches from the anterior divisions are as follows:

1. **Masseteric nerve:** It emerges at the upper border of the lateral pterygoid, just in front of the temporomandibular joint, passes laterally through the mandibular notch, along with masseteric artery to supply the masseter from its deeper aspect. It also supplies the temporomandibular joint.
2. **Deep temporal nerves:** These are usually two in number, anterior and posterior. The anterior and posterior temporal nerves emerge at the upper border of the lateral pterygoid and ascend up in the temporal fossa to supply the temporalis muscle from its deep aspect.
3. **Nerve to lateral pterygoid:** It runs with the buccal nerve and enters the deep surfaces of both the heads of lateral pterygoid muscle, which it supplies.
4. **Buccal nerve:** It contains all the sensory fibres of the anterior division. It emerges between the two heads of the lateral pterygoid and courses downwards and forwards onto the buccinator muscle, giving branches to the skin of the cheek. It then pierces the buccinator muscle and supplies the mucus membrane of the cheek and gum of the lower jaw opposite the molars and second premolar teeth.

N.B. All the branches of anterior division of the mandibular nerve are motor except buccal nerve which is sensory.

From the Posterior Division

The posterior division is mainly sensory. It gives the following three branches:

1. Auriculotemporal nerve: This nerve arises by two roots, which after encircling the middle meningeal artery unite to form the single trunk. It runs backwards between the neck of the mandible and the sphenomandibular ligament. Behind the neck of the mandible, it turns upwards and ascends over the root of zygoma to enter the temple behind the superficial temporal vessels.

Distribution:

- (a) Its *auricular branches* supply skin of the tragus, upper part of the pinna, external auditory meatus and tympanic membrane. The lower parts of these regions are supplied by great auricular nerve and auricular branch of the vagus nerve.
- (b) Its *articular branches* supply the temporomandibular joint.
- (c) Its *superficial temporal branches* supply the skin of the temple.
- (d) It also supplies *secretomotor fibres* to the parotid gland.

2. Lingual nerve: It is the smaller terminal branch of posterior division of the mandibular nerve. It is sensory to the mucus membrane of anterior two-third of the tongue *except vallate papillae*.

Course and relations: It begins about 1 cm below the skull. It runs first between tensor palati and lateral pterygoid and then between lateral and medial pterygoids. About 2 cm below the skull it is joined by the chorda tympani nerve. After emerging at the lower border of the lateral pterygoid, it first run downwards and forwards between the ramus of the mandible and medial pterygoid, comes in direct contact with the mandible where the bone is thinned to form a shallow groove below and medial to the last molar tooth, just above the posterior end of the mylohyoid line. This groove separates the attachments of pterygomandibular raphe above and mylohyoid muscle below. It enters the mouth on the superior surface of the mylohyoid, and then it crosses the styloglossus to reach the lateral surface of the hyoglossus. Finally it lies on the surface of the genioglossus. Here it winds round the submandibular duct (first above, then lateral, then below and finally medial to the duct) and divides into its terminal branches.

Distribution:

- (a) Provides sensory supply to floor of mouth, lingual surface of the gum and anterior two-third of the tongue;
- (b) Carries preganglionic secretomotor fibres to submandibular and sublingual salivary glands.

3. Inferior alveolar nerve: It is the larger terminal branch of the posterior division of mandibular nerve. It is a mixed nerve. It receives all the motor fibres of the trigeminal nerve.

Course: It emerges below the lower head of the lateral pterygoid and passes vertically downwards and forward on the medial pterygoid. The nerve lies anterior to inferior alveolar vessels between the sphenomandibular ligament and the ramus of the mandible. Then enters the mandibular foramen in company with inferior alveolar artery, traverses the mandibular canal as far as mental foramen, where it terminates by dividing into mental and incisive branches.

Branches:

- Nerve to mylohyoid* arises from the inferior alveolar nerve before it enters the mandibular canal. It pierces the sphenomandibular ligament to reach the mylohyoid groove. It supplies mylohyoid and anterior belly of digastric muscle.
- Dental branches* supply molar and premolar teeth.
- Mental nerve* emerges out through mental foramen to supply skin of the chin and skin and mucus membrane of the lower lip.
- Incisive branch*, supplies canine and incisor teeth.

The branches of the mandibular nerve are summarized in Table 10.2.

Table 10.2 Branches of the mandibular nerve

From main trunk	From anterior division	From posterior division
Nervus spinosus (meningeal branch)	Masseteric nerve	Auriculotemporal nerve
Nerve to medial pterygoid	Deep temporal nerves	Lingual nerve
	Nerve to lateral pterygoid	Inferior alveolar nerve
	Buccal nerve	

N.B. All the branches of posterior division of the mandibular nerve are sensory except nerve to mylohyoid, which is motor.

Clinical correlation

- Inferior alveolar nerve block (generally called inferior alveolar block or 1A block):** It is the most common nerve block performed in dentistry to carry out dental procedures on the mandibular teeth.

The anesthetic agent is injected slightly superior to the entry of inferior alveolar nerve into the mandibular foramen being overhung by the lingula. While performing inferior alveolar nerve block, if needle is inserted too far posteriorly, it may enter the parotid gland and damage the facial nerve leading to *transient facial palsy*.

- The lingual nerve is at great risk (10%) during surgical removal of the impacted third molar teeth. The nerve is also at risk during surgical removal of the submandibular salivary gland, during which the submandibular duct must be dissected out carefully from the nerve.
- Referred Pain:** It is the pain frequently referred from one branch of mandibular nerve to the other. Thus in patients suffering from tongue cancer, the pain radiates to the ear and to the temporal fossa in the area of distribution of auriculo-temporal nerve. The pain is relieved by dividing the lingual nerve below and behind the last molar tooth. At this site the nerve is in contact with the mandible and covered only by mucus membrane. Similarly, pain from teeth is also referred to the ear and temporal region.

CHORDA TYMPANI NERVE

The chorda tympani nerve is the slender branch of facial nerve. It is so named because of its intimate relationship to the middle ear (tympanum).

Function Components (Fig. 10.10)

The chorda tympani nerve contains:

- General visceral efferent fibres:* These are preganglionic parasympathetic (secretomotor) fibres to submandibular and sublingual salivary glands.
- Special visceral afferent fibres:* These fibres carry taste sensations from anterior 2/3rd of tongue (except vallate papillae).

Origin, Course, and Relations (Fig. 10.11)

It arises from facial nerve in the facial canal about 6 mm above the stylomastoid foramen, within the posterior wall of the tympanic (middle ear) cavity. It enters the middle ear through the posterior canaliculus of chorda tympani in the posterior wall, runs across the lateral wall (tympanic membrane). Here it crosses medial aspect of handle of malleus and lateral aspect of long process of incus. At the anterior margin of tympanic membrane it enters anterior canaliculus in the anterior wall of the middle ear passes through canaliculus and emerges at the base of skull through medial end of petrotympanic fissure. It then goes medially, forwards and downwards, grooves the medial side of the spine of the sphenoid, running anteroinferiorly deep to lateral pterygoid to join the posterior aspect of the lingual nerve about 2 cm below the base of the skull.

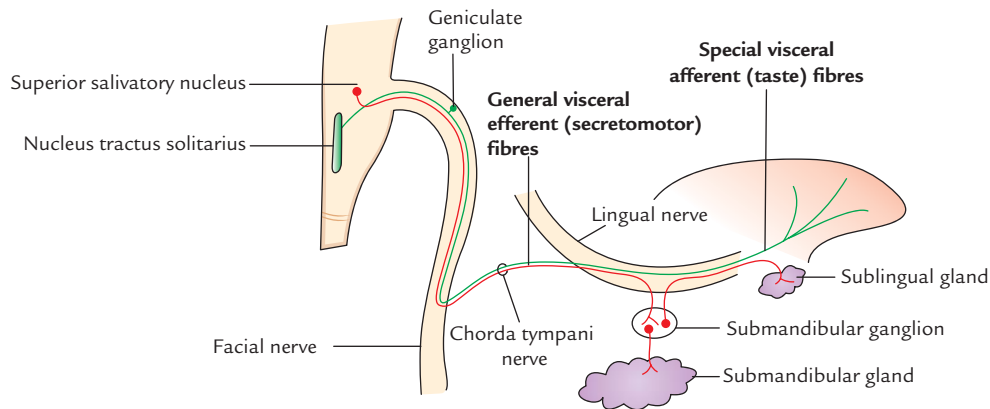


Fig. 10.10 Functional components of the chorda tympani nerve.

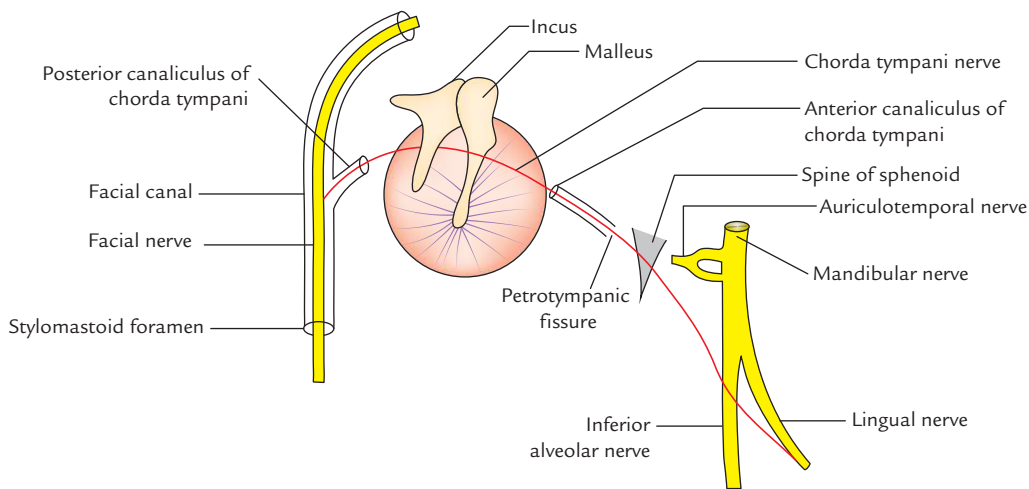


Fig. 10.11 Origin, course, and relations of the chorda tympani nerve.

Distribution

1. It supplies secretomotor fibres to submandibular and sublingual glands through the submandibular ganglion.
2. It carries taste sensations from anterior two-third of the tongue (except vallate papillae).

OTIC GANGLION (Fig. 10.12)

It is a small parasympathetic ganglion connected to the mandibular division of trigeminal nerve and provides a relay station to the secretomotor fibres to the parotid gland. Topographically, it is intimately related to the mandibular nerve but functionally it is related to glossopharyngeal nerve.

Size

Pinhead (2–3 mm in size).

Location

Infratemporal fossa, just below the foramen ovale.

Relations

Lateral: Mandibular nerve.

Medial: Tensor palati muscle.

Posterior: Middle meningeal artery.

Anterior: Medial pterygoid muscle.

Roots or Connections

1. **Parasympathetic motor (secretomotor):** From lesser petrosal nerve.

Preganglionic parasympathetic fibres arise from inferior salivatory nucleus; pass successively through glossopharyngeal nerve, tympanic branch of glossopharyngeal nerve (Jacobson's nerve), tympanic plexus, and lesser petrosal nerve to relay in the ganglion. *Postganglionic parasympathetic fibres* from ganglion cells pass through auriculo-temporal nerve to supply parotid gland.

2. **Sympathetic:** From sympathetic plexus around the middle meningeal artery.

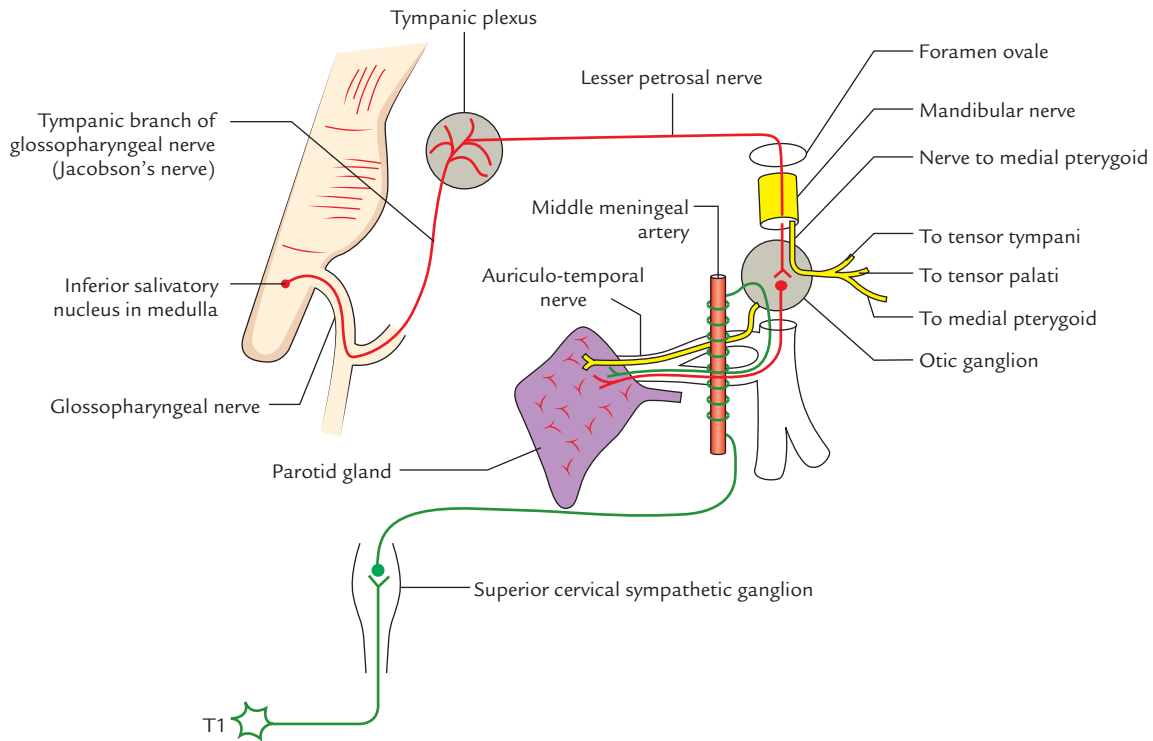


Fig. 10.12 Otic ganglion and its connections.

Preganglionic sympathetic fibres arise from T1 and T2 spinal segments, enter the cervical sympathetic chain at the level of its inferior ganglion and then ascend to relay in the superior cervical sympathetic ganglion. The postganglionic fibres arise from this ganglion and form plexus around the middle meningeal artery. They then pass through the ganglion without relay to reach the parotid gland via auriculotemporal nerve. They are vasomotor in nature and responsible for thick salivary secretion.

3. **Sensory:** From auriculotemporal nerve.
4. **Somatic motor:** Nerve to medial pterygoid. It passes through ganglion to supply medial pterygoid, tensor palati, and tensor tympani muscles.

Branches

- | | | |
|--|---|---|
| <ol style="list-style-type: none"> 1. Postganglionic parasympathetic 2. Postganglionic sympathetic 3. Sensory | } | All supply parotid gland through auriculotemporal nerve |
|--|---|---|

N.B.

- In humans, the *chorda tympani* nerve is connected to the otic ganglion and nerve to pterygoid canal. These

connections provide an alternative pathway of taste sensations from anterior two-third of the tongue.

- Clinical evidence suggests that in humans the parotid gland also receives secretomotor fibres through chorda tympani nerve.

TEMPOROMANDIBULAR JOINT

The temporomandibular joint (TMJ), one on each side of the head, is a joint between temporal bone and mandible that allows the movements of the mandible for speech and mastication.

The mandible is a single bone having two heads, which articulate on each side with temporal bone of cranium. The cranium, with which the mandible articulates, is also, mechanically a single component. The movement cannot take place at one temporomandibular joint without a concomitant movement occurring at the joint on the opposite side. Therefore, temporomandibular joints are the bilateral components of a single **craniomandibular articulation/joint**. The temporomandibular joints are often involved in various disease processes. Therefore medical students, particularly dental students need to understand the anatomy of TMJ, including movements and disorders associated with the joint.

Type: It is a synovial joint of condylar variety.

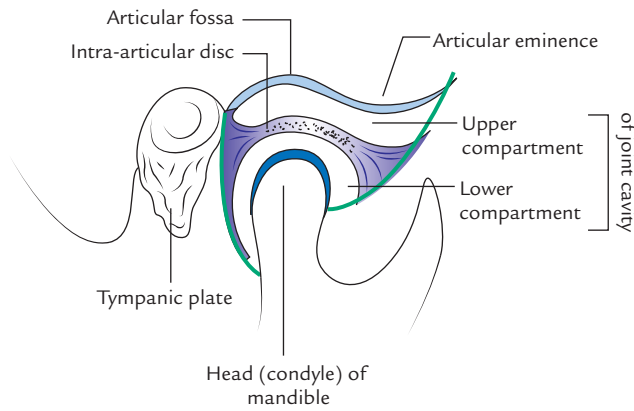


Fig. 10.13 Articular surfaces of the temporomandibular joint.

Articular Surface

The **upper articular surface** is formed by the (a) *articular fossa*, and (b) *articular eminence* of the temporal bone. This surface is concavo-convex from behind forwards (Fig. 10.13).

The **lower articular surface** is formed by the head (condyle) of the mandible. This surface is elliptical in shape.

The articular surfaces are **covered by fibrocartilage** and not by hyaline cartilage, hence temporomandibular joint is an *atypical synovial joint* (Fig. 10.13).

JOINT CAVITY (Fig. 10.14)

The cavity of temporomandibular joint is divided into *upper menisco-temporal* and *lower menisco-mandibular compartments* by an intra-articular disc of fibrocartilage.

The upper compartment permits gliding movements, whereas lower compartment permits gliding as well as rotational movements.

Articular Disc

The articular disc is an oval plate of fibrocartilage. Though termed *fibrocartilage*, it consists mainly of collagen fibres with few cartilage cells. It is congruent with both the articular surfaces. Thus its upper surface is concavo-convex (from before backwards) and its inferior surface is concave. The concavo-convex superior surface fits against the articular eminence and the concavity of the articular fossa. The lower concave surface fits with convex head of the mandible.

The periphery of the disc is attached firmly to the fibrous capsule.

The disc has a thick margin, the *peripheral annulus* and a central depression on its inferior surface. In sagittal section, the disc appears to possess a thin *intermediate zone* and thickened anterior and posterior bands (Fig. 10.14). The anterior band extends anteriorly through the capsule to be

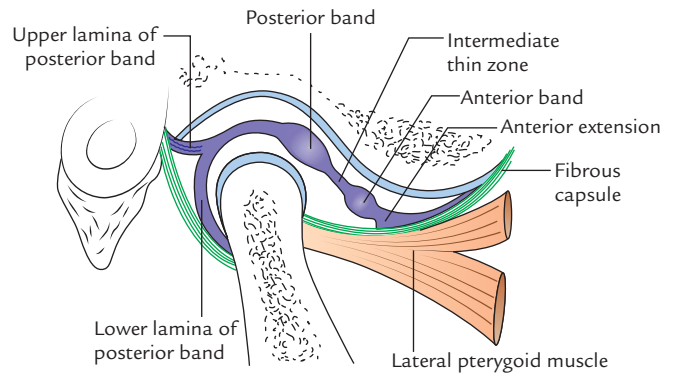


Fig. 10.14 Parts of the intra-articular disc.

continuous with the tendon of lateral pterygoid. The posterior band splits into two laminae: upper and lower. The upper lamina composed of fibroelastic tissue is attached to the squamotympanic fissure. The lower lamina composed of fibrous non-elastic tissue is attached to the back of the condyle. The bilaminar region contains a venous plexus. The central part of the disc is avascular.

The elastic fibres in the posterior part of the disc bring back the disc in the articular fossa when the open mouth is closed.

N.B. Parts of articular disc (Fig. 10.14): In sagittal section, the articular disc of TMJ presents five different parts, from before backwards these are: (a) **anterior extension**, (b) **anterior thick band**, (c) **intermediate zone**, (d) **posterior thick band**, and (e) **posterior bilaminar zone**.

LIGAMENTS

The ligaments are the fibrous capsule, temporomandibular, sphenomandibular, and stylomandibular ligaments. The latter two are accessory ligaments (Fig. 10.15A and B).

1. **Fibrous capsule:** It is a fibrous sac to enclose the joint cavity. It is attached above to the articular tubercle, the circumference of articular fossa, and the squamotympanic fissure; and below to the neck of mandible.

The capsule is loose above the intra-articular disc and tight below it.

The synovial membrane lines the inner aspect of the fibrous capsule and the neck of the mandible.

2. **Lateral (temporomandibular) ligament:** It is a true ligament and formed as a result of thickening on the lateral aspect of the capsular ligament. Its fibres are directed downwards and backwards. It is attached above to the articular tubercle on the root of zygoma and below to the posterolateral aspect of the neck of the mandible. The lateral ligament strengthens the lateral aspect of the capsule.

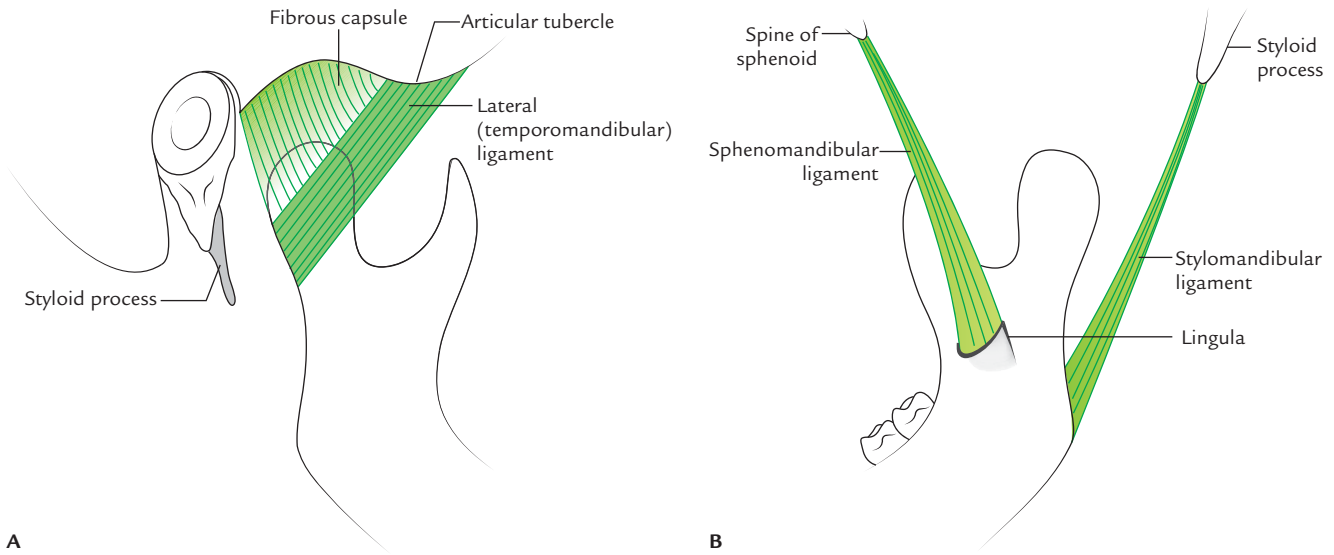


Fig. 10.15 Ligaments of the temporomandibular joint: A, fibrous capsule and lateral ligament; B, accessory ligaments.

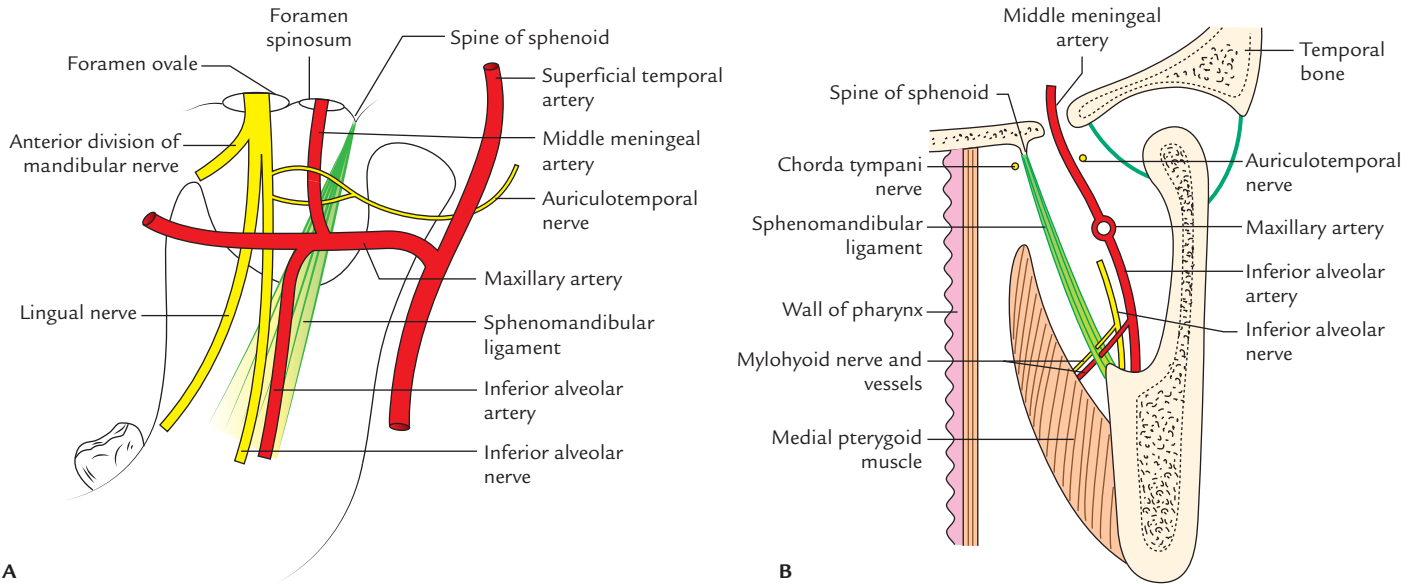


Fig. 10.16 Relations of the sphenomandibular ligament: A, superficial relations; B, deep relations.

3. **Sphenomandibular ligament:** It is attached above to the spine of the sphenoid and below to the lingula and lower margin of the mandibular foramen of the mandible. It lies on a deeper plane away from the joint capsule. The sphenomandibular ligament represents the unossified intermediate part of the sheath of the Meckel’s cartilage of the first pharyngeal arch. It becomes accentuated and taut when the mandible is protruded.

Relations of sphenomandibular ligament (Fig. 10.16A and B) are as under:

Laterally, it is related to: (a) lateral pterygoid muscle, (b) auriculo-temporal nerve, (c) maxillary artery, and (d) inferior alveolar nerve and vessels.

Medially, it is related to: (a) medial pterygoid, (b) chorda tympani nerve and (c) wall of the pharynx.

N.B. Near its lower end the sphenomandibular ligament is pierced by mylohyoid nerve and vessels.

Clinical correlation

The sphenomandibular ligament is an important landmark for administration of local anesthetic during inferior alveolar nerve block.

4. **Stylomandibular ligament:** It is attached above to the lateral surface of the styloid process and below to the

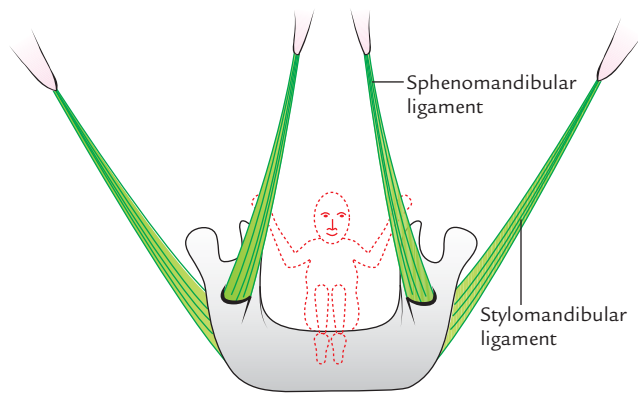


Fig. 10.17 'Swing' formed by the mandible and accessory ligaments of TMJs.

angle and adjoining posterior border of the ramus of the mandible.

The stylohyoid ligament is formed due to thickening of the investing layer of deep cervical fascia, which separates the parotid and submandibular glands.

This ligament also becomes taut when the mandible is protruded.

N.B. The **accessory ligaments of temporomandibular joints** control range of motion (ROM) of TMJs and with mandible form a 'swing' (Fig. 10.17).

RELATIONS

Lateral:

- (a) Skin and fasciae.
- (b) Parotid gland.
- (c) Temporal branches of the facial nerve.

Medial:

- (a) Tympanic plate separating it from internal carotid artery.
- (b) Spine of sphenoid.
- (c) Auriculotemporal nerve.
- (d) Middle meningeal artery.
- (e) Sphenomandibular ligament.
- (f) Chorda tympani nerve.

Anterior:

- (a) Tendon of lateral pterygoid.
- (b) Masseteric nerve and vessels.

Posterior:

- (a) Postglenoid part of parotid gland separating it from external auditory meatus.
- (b) Superficial temporal vessels.
- (c) Auriculotemporal nerve.

NERVE SUPPLY

1. *Auriculotemporal nerve:* Its articular twigs enter the joint from its posterior aspect.
2. *Masseteric nerve:* Its articular twigs enter the joint from its anterior aspect.

BLOOD SUPPLY

1. Maxillary artery.
2. Superficial temporal artery.

The articular twigs of these arteries enter the posterior aspect of the capsule.

LYMPHATIC DRAINAGE

The lymph from temporomandibular joint is drained into:

1. Superficial parotid (preauricular) nodes.
2. Deep parotid nodes.
3. Upper deep cervical nodes.

STABILITY

The joint is much more stable when the mouth is closed (i.e., when the teeth are in occlusion) than when the mouth is open. In occlusion, the teeth themselves stabilize the mandible on maxilla and no strain is thrown on the joints when an upward blow is received on the mandible. Further in the occluded position, the forward movement of condyle is discouraged by the articular eminence and by the contraction of the posterior fibres of the temporalis muscle, while the backward movement of the condyle is prevented by the lateral ligament and the contraction of the lateral pterygoid muscle.

MOVEMENTS OF THE MANDIBLE

When the TMJ of two sides are in *position of rest* a small free space exists between the upper and lower teeth but lips are in contact. The various movements of mandible occur in this position.

The lower jaw can be depressed, elevated, protruded retracted and moved from side-to-side, by movements at temporomandibular joints.

Mechanism

All of the above mentioned movements of lower jaw involve two basic movements, which occur at TMJ, of course with the help of muscles:

1. Gliding movement.
2. Rotational movement.

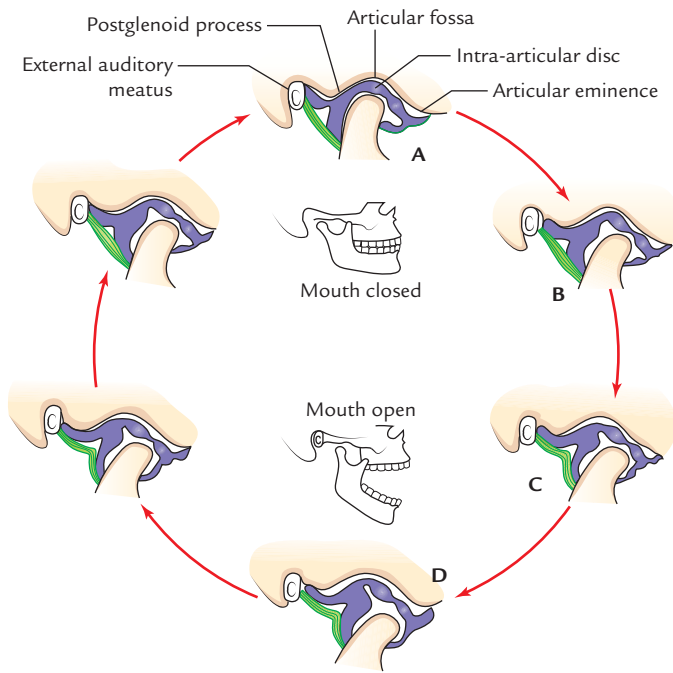


Fig. 10.18 Movements of the lower jaw related to temporomandibular joint to show the opening and closing of the mouth. Note the changing relation of the condyle of the mandible.

The *upper menisco-temporal compartment* of TMJ permits gliding movements, during protrusion (protrusion), retraction, and chewing.

The *lower menisco-temporal compartment* permits rotation around two axes (a) a transverse axis, during depression and elevation and (b) a vertical axis during side-to-side/chewing movements.

With these two types of movements, gliding and rotation, and with right and left TMJs working together, most of the movements of the lower jaw can be accomplished perfectly as desired. These include opening and closing the jaws and shifting the lower jaw to one side (Fig. 10.18).

The movements occurring at the temporomandibular joints are:

1. Depression
 2. Elevation
 3. Protraction
 4. Retraction
 5. Side to side (Chewing) movements
1. **Depression (lowering of jaw to open mouth):** During depression, the head of mandible along with an articular disc glide forward in the upper meniscotemporal compartment on both the sides by the contraction of lateral pterygoid muscle. At the same time head rotates forward underneath the articular disc by the contraction

of suprahyoid muscles, *viz.* digastric geniohyoid, and mylohyoid. The gravity also helps in opening the mouth.

2. **Elevation (elevating of jaw to close the mouth):** During elevation the movements take place in a reverse order to that of depression, i.e., first the head of mandible along with an articular disc glide backward in the upper meniscotemporal compartment by temporalis, masseter, and medial pterygoid, and then head rotates backward on the lower surface of the disc by posterior fibres of temporalis.
3. **Protrusion/Protraction:** During this movement, mandibular teeth move forward in front of maxillary teeth. In this act, head of mandible along with articular disc glide forwards in the upper meniscotemporal compartment on both sides by simultaneous action of medial and lateral pterygoids of both sides.
4. **Retraction:** During this movement, the head of mandible along with articular disc glide backwards in the upper meniscotemporal compartment by the contraction of the posterior fibres of temporalis muscle and bring the joint in the resting position. The forceful retraction is assisted by deep fibres of masseter, digastric, and geniohyoid muscles. At the end of this movement the head of the mandible comes to lie underneath the articular tubercle.
5. **Side-to-side (Chewing) movements:** These movements occur alternately in the right and left temporomandibular joints. In chewing movements, the head of the mandible on one side glides forwards along with the disc (as in protraction), but the head of the mandible on the opposite side merely rotates on the vertical axis. As a result, the chin moves forwards and to one side, i.e., towards the side on which no gliding has taken place.

During this movement, the medial and lateral pterygoids of one side contract alternatively with those of opposite sides.

The alternate movements of this kind on the two sides result in side-to-side movements of the lower jaw.

Muscles Producing Movements

Depression (Opening of Mouth)

It is produced mainly by lateral pterygoid helped by gravity. The digastric, geniohyoid, and mylohyoid muscles help when the mouth is opened widely or against resistance.

Elevation (Closing the Mouth)

It is caused by medial pterygoid, masseter, and temporalis (vertical fibres).

N.B. Closing the mouth is stronger action than the opening the mouth. Therefore, when attacked by a street dog, it is advisable to keep the mouth of dog closed, if possible.

Protraction

It is done by lateral and medial pterygoids and masseter.

Retraction

It is done by posterior fibres of temporalis. It may be assisted by middle and deep fibres of the masseter, the digastric and geniohyoid muscles.

Side-to-side (Chewing) Movements

These movements are performed by alternate contraction of medial and lateral pterygoids on each side.

Movements of the temporomandibular joint and muscles producing them are summarized in Table 10.3.

Table 10.3 Movements of the mandible and muscles producing them

Movement	Muscle
Depression	Lateral pterygoid Digastric Geniohyoid Mylohyoid Gravity
Elevation	Masseter Medial pterygoid Temporalis
Protrusion (Protraction)	Medial pterygoid Lateral pterygoid
Retraction	Posterior fibres of temporalis
Side-to-side (chewing) movement	Medial and lateral pterygoids of one side contracting alternatively with that of opposite side

Clinical correlation

- **Palpation of the temporomandibular joint and associated muscles:** The bilateral palpation is must to assess the entire joint and its associated muscles. First, the patient is asked to open and close the mouth several times. Then he is asked to move the opened jaw to left, and to right, and finally he is asked to move the jaw forward. For digital palpation of condyle of moving mandible place a finger into the outer portion of the external auditory meatus.
- **Dislocation of the mandible (Fig. 10.19):** The mandible is dislocated only anteriorly. When the mouth is open, the mandibular condyles move forward and lie underneath the articular eminences. This is the most unstable position of the temporomandibular joint. In this position, if there is excessive opening of mouth as during yawning, sudden violence or convulsive spasm of lateral pterygoid muscles, the head of mandible of one or both sides may slip anteriorly and get locked into the infratemporal fossa; as a result the mouth cannot be closed anymore and any passive effort to do that will invariably fracture the neck of the mandible on one or both sides.

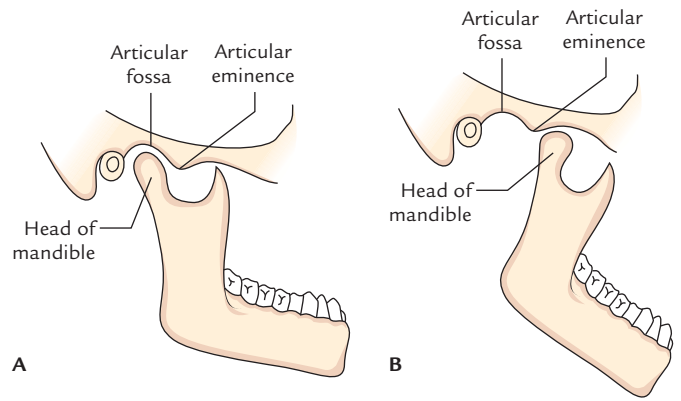


Fig. 10.19 Temporomandibular joint: A, normal; B, in anterior dislocation.

To reduce dislocation, the condyle must be lowered and pushed back behind the summit of articular eminence into the articular fossa. Thus the reduction is done by depressing the jaw with thumb placed on the last molar teeth, and simultaneously elevating the chin.

- **Temporomandibular joint syndrome:** This syndrome consists of group of symptoms arising from temporomandibular joints and their associated masticatory muscles. The typical presenting symptoms are:
 - *Diffuse facial pain*, due to spasm of masseter muscle.
 - *Headache*, due to spasm of temporalis muscle.
 - *Jaw pain*, due to spasm of lateral pterygoid.

These symptoms may be associated with clicking and pain in the joint. The clicking is often audible when the patient is chewing. It occurs when the posterior attachment of the disc becomes stretched or detached, allowing the disc to become temporarily or permanently trapped anteriorly. The derangement of articular disc results from an overclosure or malocclusion.

- During surgery of temporomandibular joints, the facial nerve should be preserved with utmost care.

MUSCLES OF MASTICATION

The muscles of mastication are concerned with movements of mandible at the temporomandibular joints during mastication (Fig. 10.20).

They are divided into two groups:

1. **Principal muscles**
 - (a) Temporalis
 - (b) Masseter
 - (c) Lateral pterygoid
 - (d) Medial pterygoid.
2. **Accessory muscles**
 - (a) Digastric
 - (b) Buccinator
 - (c) Mylohyoid
 - (d) Geniohyoid.

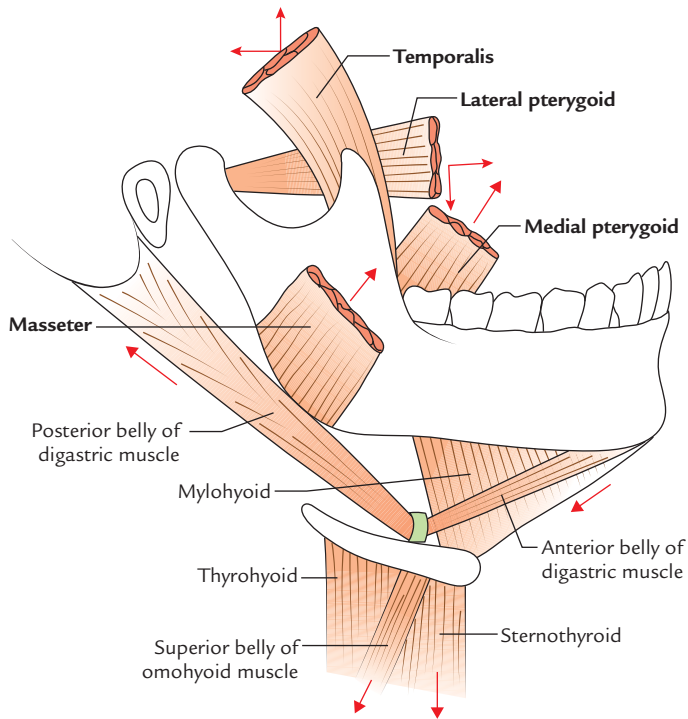


Fig. 10.20 Muscles of mastication producing movements of the temporomandibular joint. The arrows indicate the direction of their actions. Chief muscles of mastication are labelled in bold.

Principal Muscles of Mastication

The characteristic features of the principal muscles of mastication are as follows:

1. All are located in or around the infratemporal fossa.
2. All are inserted into the ramus of the mandible.
3. All are innervated by the mandibular division of the trigeminal nerve.
4. All are concerned with movements of the mandible on the temporomandibular joints.
5. All develop from mesoderm of the first pharyngeal arch.

Temporalis (Fig. 10.21)

It is a fan-shaped muscle located in the temporal fossa. It is covered by tough temporal fascia which is attached above to the temporal line and below to the zygomatic arch.

Origin

It arises from:

1. Whole of the floor of temporal fossa except the part formed by the zygomatic bone.
2. Deep surface of the temporal fascia.

Insertion

The fibres converge and descend to form a tendon, which passes through the gap between the zygomatic arch and the side of the skull. The muscle is inserted into:

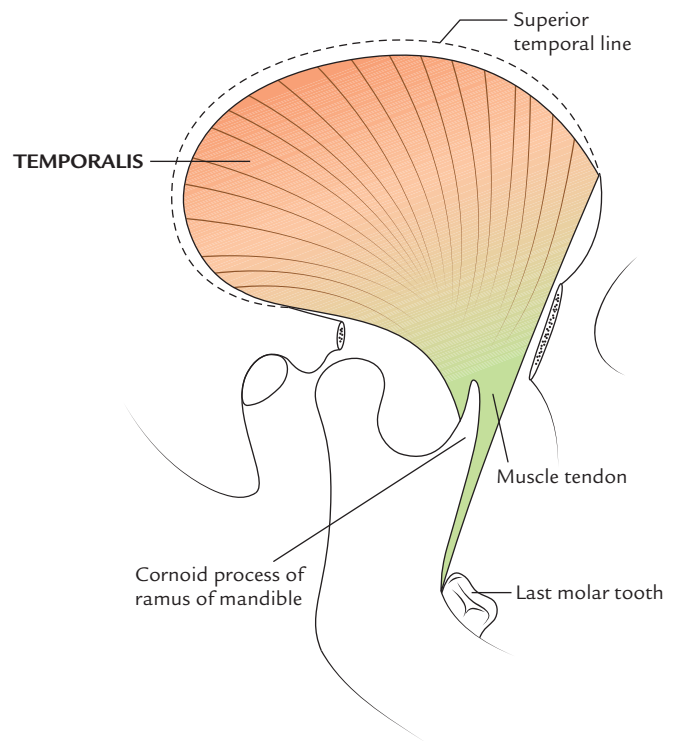


Fig. 10.21 Origin and insertion of the temporalis muscle.

1. The medial surface, apex, anterior, border of the coronoid process of ramus of mandible.
2. The anterior border of the ramus of mandible, almost up to the last molar tooth.

N.B. The temporalis muscle is fan shaped. The anterior fibres are oriented vertically, the posteriormost fibres are disposed almost horizontally and intervening intermediate fibres are placed obliquely.

Nerve supply

The temporalis is supplied by the *anterior and posterior deep temporal nerves*, the branches of the anterior division of the mandibular nerve.

Actions

The temporalis muscle **elevates the mandible** and so closes the mouth and approximates the teeth. This movement requires both the upward pull of the anterior fibres and backward pull of the posterior fibres.

Posterior fibres retract the mandible after it has been protruded.

Masseter (Fig. 10.22)

The masseter (Greek: masseter = a chewer) is a thick quadrilateral muscle covering the lateral surface of the ramus of the mandible including its coronoid process. The condylar process is left uncovered.

Origin

The masseter consists of the following three layers:

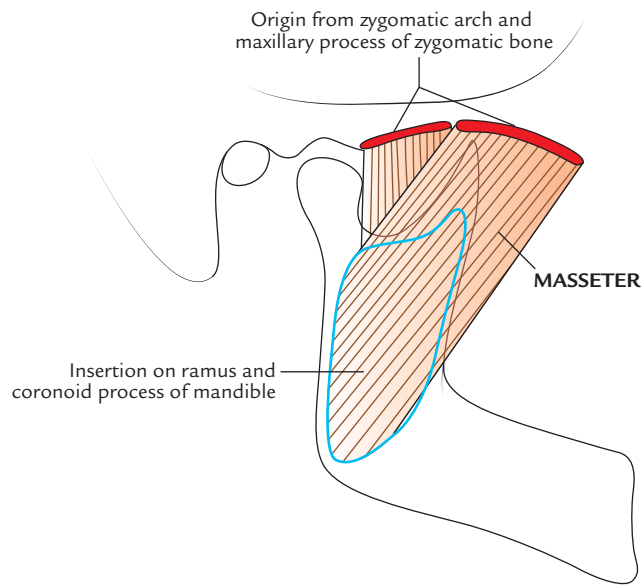


Fig. 10.22 Origin and insertion of the masseter muscle.

1. Superficial layer.
2. Middle layer.
3. Deep layer.

Superficial layer is largest of the three layers of masseter and arises by a thick aponeurosis from: maxillary process of zygomatic bone and anterior two-third of the inferior border of the zygomatic arch.

Middle layer arises from lower border of the posterior one-third of the zygomatic arch.

Deep layer arises from deep surface of the zygomatic arch.

Insertion

1. **Superficial fibres** pass downwards and backwards at 45° to be inserted into the angle and lower posterior half of the lateral surface of the ramus of the mandible.
2. **Middle fibres** pass vertically downwards to insert into the central part of the ramus.
3. **Deep fibres** pass vertically downwards to insert into the upper part of the mandibular ramus and its coronoid process.

N.B.

- Intramuscular tendinous septa in the superficial layer are responsible for producing ridges on the ramus of the mandible.
- Middle and deep fibres together constitute the deep part of the masseter.

Nerve supply

The masseter is supplied by a **masseteric nerve**, a branch from anterior division of the mandibular nerve.

Actions

The masseter muscle **elevates the mandible** to close the mouth.

Lateral Pterygoid

It is described on page 134.

Medial Pterygoid

It is described on page 135.

Accessory Muscles of Mastication

They are described in detail in Chapter 9.

The origin, insertion, nerve supply, and actions of chief muscles of mastication are summarized in Table 10.4.

N.B. The chief muscles of mastication are often termed *muscles of mastication*.

Clinical correlation

The muscles of mastication and their motor innervation can be tested clinically by asking the patient to clench his teeth repeatedly and then palpating the temporalis and masseter in the temporal fossa and over the ramus of mandible, respectively.

PTERYGOPALATINE FOSSA

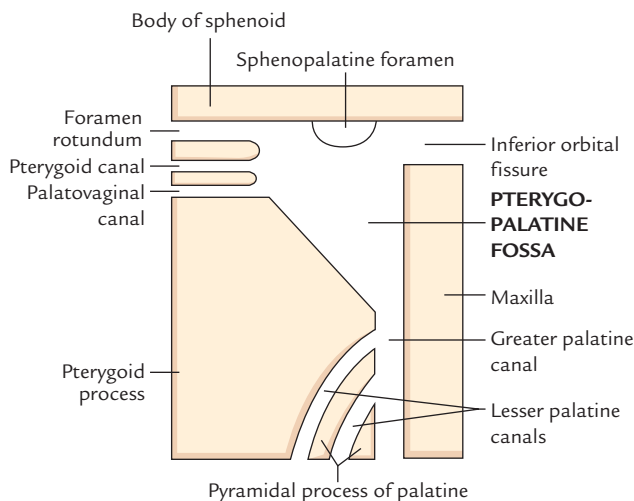
The pterygopalatine fossa is a pyramidal space situated deeply below the apex of the orbit, between the pterygoid process of sphenoid behind and the perpendicular plate of palatine in front. More laterally, the back of maxilla replaces the palatine bone as the anterior boundary of the entrance of the fossa—the pterygomaxillary fissure.

BOUNDARIES (Fig. 10.23)

- Anterior:** Perpendicular plate of the palatine and posterior surface of the maxilla (superomedial part).
- Posterior:** Pterygoid process and adjoining part of the anterior surface of the greater wing of the sphenoid.
- Medial:** Upper part of the perpendicular plate of palatine orbital and sphenoidal process of the palatine.
- Lateral:** The fossa opens into the infratemporal fossa through pterygomaxillary fissure.
- Superior:** Under surface of the body of the sphenoid and orbital process of the palatine. The lateral part of the roof is open and here fossa opens into the orbit through inferior orbital fissure.
- Inferior:** Pyramidal process of the palatine bone in the angle between the maxilla and the pterygoid process.

Table 10.4 Origin, insertion, nerve supply, and actions of the muscles of the mastication

Muscles	Origin	Insertion	Nerve supply	Actions
Temporalis (fan shaped)	<ul style="list-style-type: none"> Floor of temporal fossa Temporal fascia 	<ul style="list-style-type: none"> Tip, anterior border, and medial surface of coronoid process Anterior border of ramus of mandible 	Mandibular division of trigeminal nerve	<ul style="list-style-type: none"> Elevation of mandible by anterior and middle fibres Retraction of mandible by posterior fibres
Masseter (quadrilateral)	Zygomatic arch adjoining part of zygomatic process of maxilla	<ul style="list-style-type: none"> Lateral surface of ramus of mandible Coronoid process 	Mandibular division of trigeminal nerve	Elevation of mandible to occlude the teeth for forceful bite
Lateral pterygoid (Short, thick conical)	<ul style="list-style-type: none"> Upper head from infratemporal surface and crest of greater wing of sphenoid Lower head from lateral surface of lateral pterygoid plate 	<ul style="list-style-type: none"> Pterygoid fovea on anterior surface of neck of mandible Articular disc and capsule of TMJ 	Mandibular division of trigeminal nerve	<ul style="list-style-type: none"> Depression of mandible by pulling the neck of mandible forward Protraction
Medial pterygoid (quadrilateral)	<ul style="list-style-type: none"> Superficial head from tuberosity of maxilla Deep head from medial surface of lateral pterygoid plate 	Medial surface of angle adjoining ramus of mandible	Mandibular division of trigeminal nerve	<ul style="list-style-type: none"> Elevation of mandible Protraction

**Fig. 10.23** Boundaries of the pterygopalatine fossa.

COMMUNICATIONS

Anteriorly: With the orbit through the medial end of the inferior orbital fissure.

Posteriorly:

1. With the middle cranial fossa through foramen rotundum.
2. With the foramen lacerum through the pterygoid canal.

3. With the pharynx through palatovaginal canal.

Medially: With the nose through sphenopalatine foramen.
Laterally: With the infratemporal fossa through pterygomaxillary fissure.

Inferiorly: With the oral cavity through greater and lesser palatine canals.

CONTENTS

The following are the main contents of the pterygopalatine fossa:

1. Maxillary nerve.
2. Pterygopalatine ganglion.
3. Third part of the maxillary artery.

MAXILLARY NERVE (Fig. 10.24)

The maxillary nerve, the second division (V₂) of the trigeminal nerve is purely sensory.

Course and Relations

It arises from the convex anterior border of the trigeminal ganglion, pierces the trigeminal cave of dura to reach the lower part of the lateral wall of the cavernous sinus. The nerve leaves the middle cranial fossa through foramen rotundum to reach the pterygopalatine fossa. It traverses

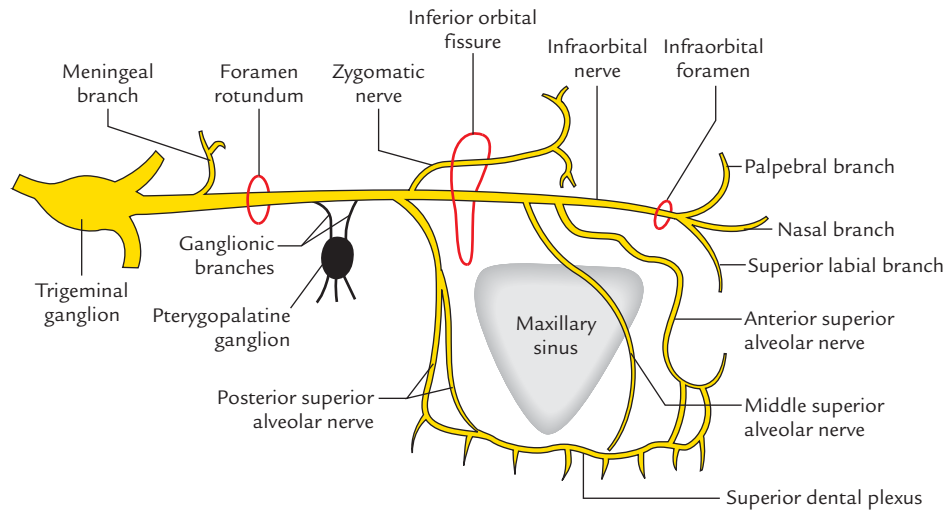


Fig. 10.24 Origin, course, and branches of the maxillary nerve.

straight in the upper part of the fossa and enters the orbit through inferior orbital fissure, hence it is called *infraorbital nerve*. The infraorbital nerve (in fact a continuation of maxillary nerve) runs forward along the floor of the orbit in the infraorbital groove and canal in succession and appears on the face, through infraorbital foramen. Therefore in its course the maxillary nerve traverses four regions in succession: the middle cranial fossa, the pterygopalatine fossa, the orbit and the face.

N.B. In the pterygopalatine fossa the pterygopalatine ganglion is suspended from the maxillary nerve by two roots.

Branches and Distribution

The maxillary nerve gives off the following branches:

A. In the Middle Cranial Fossa

1. **Meningeal branch**, which supplies the dura mater of the middle cranial fossa.

B. In the Pterygo-palatine Fossa

1. **Ganglionic (communicating) branches**, two in number to pterygopalatine ganglion.
2. **Zygomatic nerve** enters the orbit through inferior orbital fissure and divides on the lateral wall of the orbit into:
 - (a) a zygomaticotemporal branch, which passes through a foramen in the zygomatic bone to supply the skin of the temple, and
 - (b) a zygomaticofacial branch, which passes through the foramen in the zygomatic bone to supply the skin of the face.
3. **Posterior superior alveolar nerve** enters the one or two foramina on the posterior surface of the body of maxilla

and supplies the mucus membrane of the maxillary air sinus. Then it breaks up to form superior dental plexus, which supplies the molar teeth and adjoining part of the gum.

C. In the Orbit (infraorbital canal)

1. **Middle superior alveolar nerve** passes downward and forward along the lateral wall of the maxillary sinus, joins superior dental plexus and supplies the premolar teeth.
2. **Anterior superior alveolar nerve** runs in the anterior wall of the maxillary sinus through a bony canal called *canalis sinuosus* and divides into dental and nasal branches:
 - (a) The dental branches join the superior dental plexus and supply the canine and incisor teeth.
 - (b) The nasal branches appear in the lateral wall of the inferior meatus and supply the mucus membrane of the lateral wall and floor of the nasal cavity.

D. On the Face

1. **Palpebral branches** turn upwards and supply the skin of the lower eyelid.
2. **Nasal branches** supply the skin of the side of nose and the mobile part of the nasal septum.
3. **Superior labial branches** supply the skin and mucus membrane of the upper lip.

N.B. The superior dental plexus is formed by *posterior, middle, and anterior superior alveolar nerves*. It is situated in the alveolar process of the maxilla above the sockets of the teeth.

The branches of maxillary nerve are summarized in the Table 10.5.

Table 10.5 Summary of branches of the maxillary nerve

Region	Branches
In the middle cranial fossa	Meningeal branch
In the pterygopalatine fossa	<ul style="list-style-type: none"> • Ganglionic branches • Posterior superior alveolar nerves • Zygomatic nerve
In the infraorbital canal	<ul style="list-style-type: none"> • Middle superior alveolar nerve • Anterior superior alveolar nerve
On the face	<ul style="list-style-type: none"> • Palpebral branch • Nasal branch • Labial branch

PTERYGOPALATINE GANGLION

The pterygopalatine ganglion (**ganglion of hay fever**) is the *largest parasympathetic peripheral ganglion*. It serves as a relay station for the secretomotor fibres to the lacrimal gland and mucus glands of the nose, palate, pharynx, and paranasal sinuses. Topographically, it is related to the maxillary nerve, but functionally it is connected to the facial nerve through greater petrosal nerve (Fig. 10.25).

Location

It is located deeply in the upper part of the pterygopalatine fossa, suspended from maxillary nerve by two short roots.

Size

Head of a small pin.

Relations

Behind: Pterygoid canal.

Medial: Sphenopalatine foramen.

In front: Perpendicular plate of palatine.

Above: Maxillary nerve.

Roots

The roots of pterygopalatine ganglion are as follows:

1. **Motor or parasympathetic root:** It is derived from the nerve of pterygoid canal. It carries preganglionic parasympathetic fibres from superior salivatory nucleus (located in the lower part of the pons). These fibres relay in the ganglion. The postganglionic fibres arise from the cells in the ganglion and supply secretomotor fibres to the lacrimal gland, glands of the nose, palate, nasopharynx, and paranasal sinuses.
2. **Sympathetic root:** It is derived from sympathetic plexus around internal carotid artery via nerve of pterygoid canal. It contains postganglionic fibres from superior cervical sympathetic ganglion. These fibres pass through the ganglion without relay and provide vasomotor supply to the mucus membrane of the nose, palate, pharynx, and paranasal air sinuses.

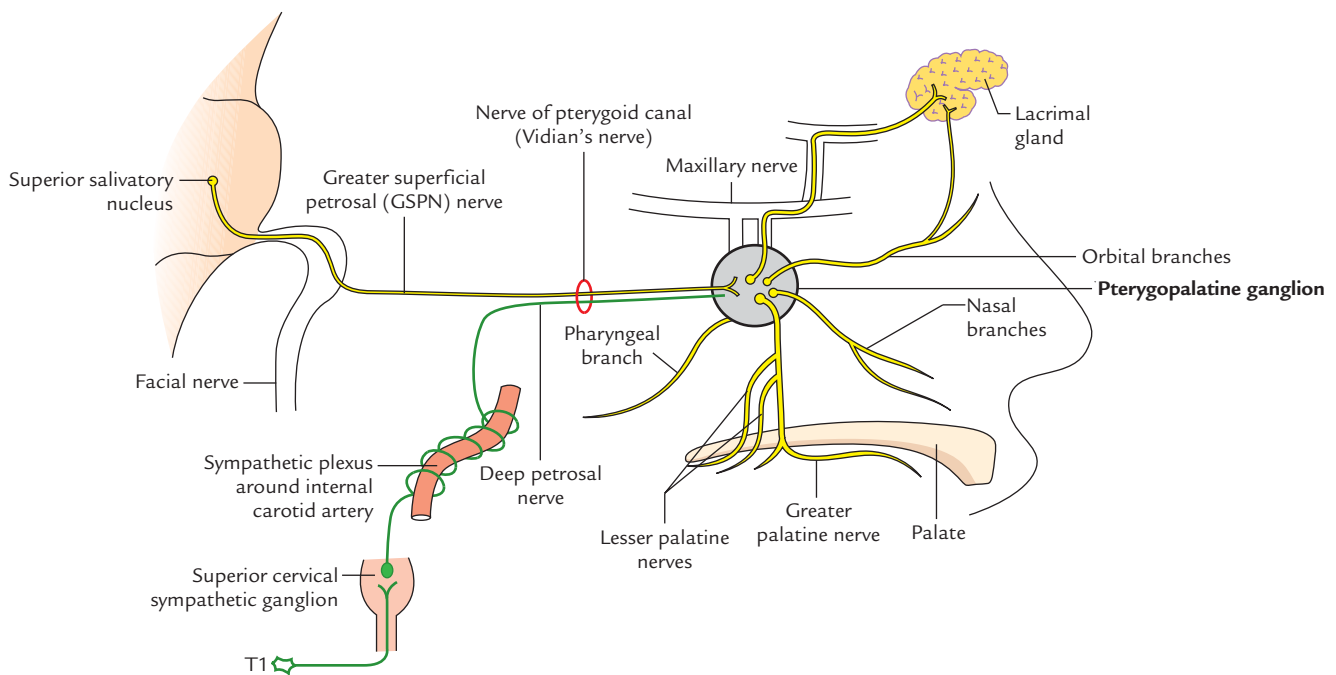


Fig. 10.25 Pterygopalatine ganglion, its roots and branches.

3. **Sensory root:** It is derived from maxillary nerve and passes through the ganglion without interruption to be distributed through the branches of the ganglion.

Branches of Distribution

The branches of the ganglion are actually the branches of maxillary nerve, which passes through the ganglion without relaying. While passing through the ganglion, they incorporate the parasympathetic and sympathetic fibres of the ganglion.

The ganglion provides the following four sets of branches:

1. Orbital.
2. Palatine.
3. Nasal.
4. Pharyngeal.

The **orbital branches** (2 or 3 in number) enter the orbit through inferior orbital fissure and supply orbital periosteum, ethmoidal air sinuses, and secretomotor fibres to the lacrimal gland.

The **palatine branches** include *greater* and *lesser palatine nerves*. The **greater palatine nerve** passes through greater palatine canal and foramen to supply posteroinferior quadrant of the lateral wall of the nose. The **lesser palatine nerves** pass through lesser palatine canals and foramina to supply secretomotor fibres to mucus membrane and glands on the inferior surface of soft palate and hard palate.

The **nasal branches** pass through sphenopalatine foramen to enter the nasal cavity. These are called *posterior superior nasal nerves*. These are divided into two sets lateral and medial. The nerves of lateral set supply lateral wall of the

nasal cavity while those of medial set supply roof and nasal septum.

The longest branch of medial set is called *nasopalatine/sphenopalatine nerve*. It runs anteroinferiorly in a groove on the nasal septum and leaves the nasal cavity through the incisive foramen to enter the oral cavity where it supplies the anterior part of hard palate.

The **pharyngeal branch** passes through palatovaginal canal and supply the nasopharynx.

Clinical correlation

The allergic conditions, viz. hay-fever or cold, cause irritation of nerve of pterygoid canal/pterygopalatine ganglion, which causes congestion of glands of the nose and palate, and lacrimal gland. Consequently the individual suffers from running nose and eyes, for this reason the nerve of pterygoid canal is called *nerve of hay fever* and the pterygopalatine ganglion is termed *ganglion of hay fever*.

THIRD PART OF THE MAXILLARY ARTERY

The third part of the maxillary artery enters the pterygopalatine fossa by passing first between the upper and lower heads of lateral pterygoid and then through the pterygomaxillary fissure. Within the fossa it lies in front of the pterygopalatine ganglion and divides into its terminal branches. The branches of the third part of the maxillary artery and its distribution are described in detail on page 138 of this chapter.

Golden Facts to Remember

▶ Key muscle of the infratemporal fossa	Lateral pterygoid muscle
▶ All the principal muscles of mastication close the mouth <i>except</i>	Lateral pterygoid, which opens the mouth
▶ Clinically the most important branch of maxillary artery is	Middle meningeal artery
▶ Peripheral heart in the region of head and neck	Lateral pterygoid muscle
▶ Chief elevator of the lower jaw	Masseter
▶ All the branches of anterior division of mandibular nerve are motor <i>except</i>	Buccal nerve, which is sensory and supplies mucus membrane and skin of the cheek
▶ All the branches of posterior division of mandibular nerve are sensory <i>except</i>	Mylohyoid nerve, which is motor and supplies mylohyoid muscle and anterior belly of digastric muscle
▶ Most common nerve block given in dentistry	Inferior alveolar nerve block
▶ Most common dislocation of temporomandibular joint	Anterior dislocation
▶ Ganglion of hay fever	Pterygopalatine ganglion
▶ Most common cause of dislocation of temporomandibular joint	Blow to the chin when mouth is widely open (as in laughing or yawning)

Clinical Case Study



A medical student was yawning in the anatomy lecture. The young lecturer walked to the student and hit him on the chin when he yawned widely again. Following a blow on chin the student got up immediately and wanted to say sorry to the teacher, but he could not say so because he failed to close his jaws. He kept standing with mouth open widely as his jaw got stuck. The lecturer immediately realized that student's temporomandibular joints are dislocated. He took him to the orofacial surgeon who reduced the dislocation and the student was relieved of his agony.

Questions

1. Mention the type of temporomandibular joint and name the bones taking part in its formation.
2. What are the unique features of TMJ?
3. Name the parts of intra-articular disc?
4. Name the commonest variety of TMJ dislocation and how is it reduced?

Answers

1. It is a condylar type of synovial joint. The bones taking part are head (condyle) of the mandible and mandibular fossa and articular eminence of squamous part of the temporal bone.
2. (a) Articular surfaces are covered by plates of articular fibrocartilages.
(b) Joint cavity is divided into two compartments by an intra-articular disc.
(c) Joints of two sides function together concomitantly to accomplish the movements of the lower jaw.
3. From anterior to posterior the parts of the intraarticular disc are: (a) anterior extension, (b) anterior thick band, (c) thin intermediate zone, (d) posterior thick band, and (e) bilaminar posterior extension.
4. Anterior dislocation. It is reduced as follows: The mandible is depressed posteriorly by exerting pressure on last molar teeth with thumbs and simultaneously the assistant elevates the chin (also refer to page 148).

Thyroid and Parathyroid Glands, Trachea, and Esophagus

The thyroid and parathyroid glands and cervical parts of the trachea and esophagus are closely related structures.

In the region of neck, thyroid and trachea are routinely examined by clinicians to diagnose their disorders, e.g., goitre, tracheal tug, etc. The surgical procedures are commonly performed on these structures, e.g., thyroidectomy, tracheostomy, etc. Therefore, detailed knowledge of anatomy and relations of these structures is extremely important.

THYROID GLAND (G. THYREOS = SHIELD; EDIDOS = FORM)

The thyroid gland is the largest endocrine gland of the body. The hormones secreted by the thyroid gland include **triiodothyronine (T3)**, **tetraiodothyronine (T4**; commonly called *thyroxine*), and **calcitonin**, which subserve the following functions:

1. Regulate the basal metabolic rate.
2. Stimulate the psychosomatic growth of the body.
3. Play an important role in calcium metabolism.

Special Features

The special features of the thyroid gland are:

1. It is the only endocrine gland, which is located superficially in the body, hence accessible for physical examination.
2. It is the only endocrine gland that depends on external environment for raw material, iodine, to synthesize its hormones.
3. It is the only endocrine gland, which does not pour its hormones into blood immediately after formation but stores them and then releases them in blood for use as and when required.
4. It is one of the organ of the body having a very rich blood flow.

LOCATION

The thyroid gland is located in the lower part of the front and side of the neck opposite to the C5, C6, C7, and T1 vertebrae (Figs 11.1 and 11.2), clasping the upper part of the trachea.

Parts and Features

- It is H-shaped and consisting of vertical right and left lateral lobes and a horizontal isthmus connecting them across the midline. Sometimes a small **pyramidal lobe** projects upwards from the isthmus usually to the left of the midline. Not infrequently, it is connected to the body

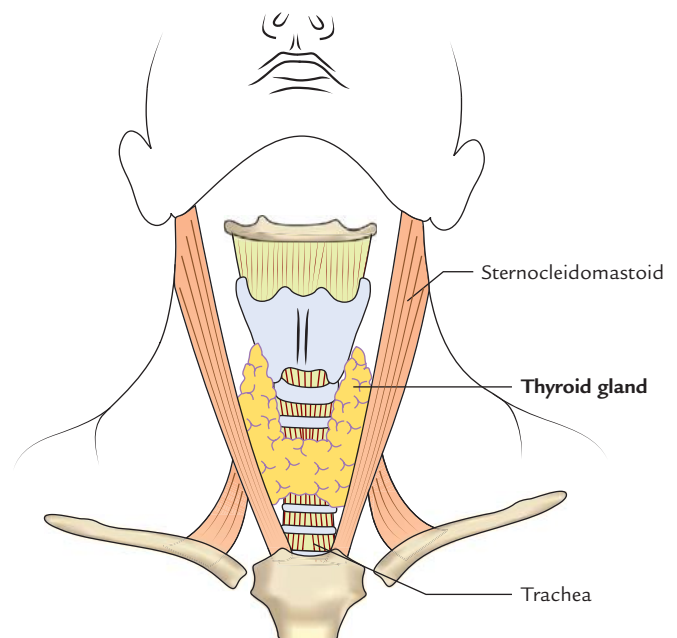


Fig. 11.1 Location of the thyroid gland.

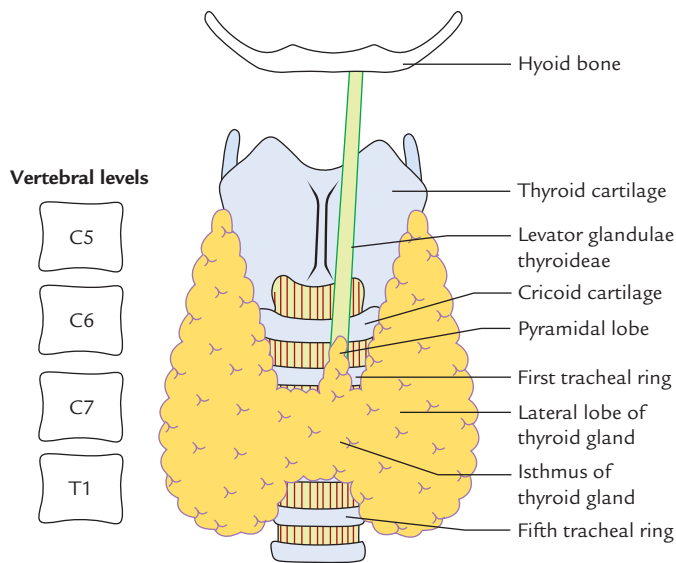


Fig. 11.2 Parts and extent of the thyroid gland.

of the hyoid bone by a fibrous or fibromuscular band called **levator glandulae thyroideae**.

- Each lateral lobe of the gland extends upwards to the oblique line of the thyroid cartilage and below up to the 5th or 6th tracheal ring.
- The isthmus extends across the midline in front of the 2nd, 3rd, and 4th tracheal rings.

Weight and Dimensions

The thyroid gland weighs about 25 g. Each lobe of the thyroid gland is 5 cm long, 3 cm wide, and 2 cm thick (5 × 3 × 2 cm). The isthmus measures about 1.25 cm in both, vertical and transverse diameters.

N.B. The thyroid gland is usually larger in females and further increases in size during menstruation and pregnancy.

Capsule of the Thyroid Gland (Fig. 11.3)

The thyroid gland is invested by two capsules: an inner true capsule and an outer false capsule.

1. **True capsule:** It is formed by the peripheral condensation of the fibrous stroma of the gland.
2. **False capsule:** It is derived from the splitting of the pretracheal fascia. The important features of the false capsule are:
 - (a) It is thin along the posterior border of the lateral lobe.
 - (b) It is thick on the medial surface of the lateral lobe.
 - (c) Traced above, the pretracheal fascia after enclosing the thyroid gland is attached to the oblique lines of the thyroid cartilage, and the body of the hyoid bone in the midline. On the medial surface of thyroid lobe it thickens to form the **suspensory ligament of**

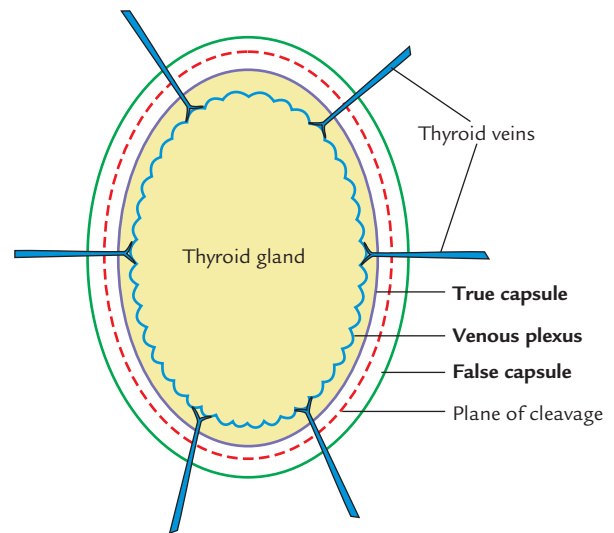


Fig. 11.3 Capsules of the thyroid gland.

Berry, which connects the lobe to the cricoid cartilage.

The dense venous plexus unlike that of the prostate gland lies deep to true capsule (Fig. 11.3). Therefore, to avoid hemorrhage during thyroidectomy, the thyroid gland is removed along with the true capsule.

N.B. In case of prostate gland, the venous plexus lies between its true and false capsules and, therefore, during surgical removal of prostate gland (prostatectomy), prostate gland is removed; leaving behind both the capsules.

Clinical correlation

- Sometimes the thyroid tumor extends backwards, as the capsule is thin along the posterior borders of the lateral lobes, compressing the adjacent structures without forming a visible swelling on the front of the neck.
- The **thyroid gland moves up and down during swallowing** because its capsule is attached to laryngeal cartilages and hyoid bone, which moves up and down during swallowing. Thus thyroid swellings can be distinguished clinically from other swellings in the region of the neck.

RELATIONS

Relations of the Thyroid Lobe (Fig. 11.4, 11.5, and 11.6)

Each lobe of the thyroid gland is roughly pyramidal (conical) and presents **apex**, **base**, **three surfaces** (lateral, medial, and posterolateral), and **two borders** (anterior and posterior):

- **Apex:** The apex is directed upwards and slightly laterally. It extends up to the oblique line of thyroid cartilage where

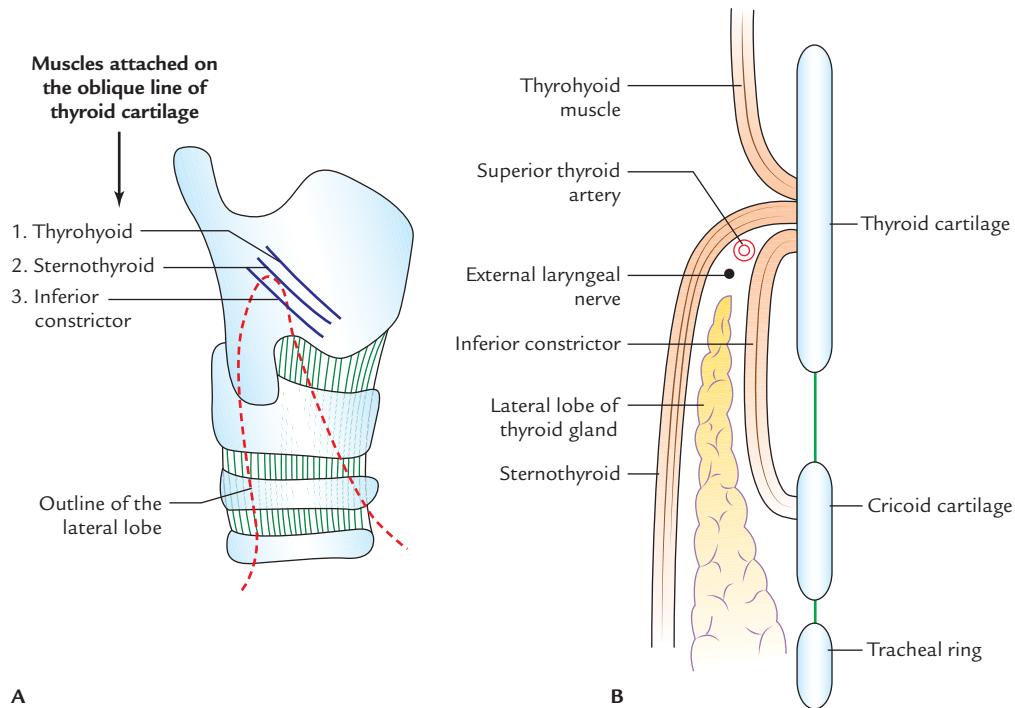


Fig. 11.4 Relations of the lateral lobe of the thyroid gland: A, upward extension of the thyroid lobe and muscles attached to the oblique line of the thyroid cartilage; B, the apex is sandwiched between the inferior constrictor and sternothyroid.

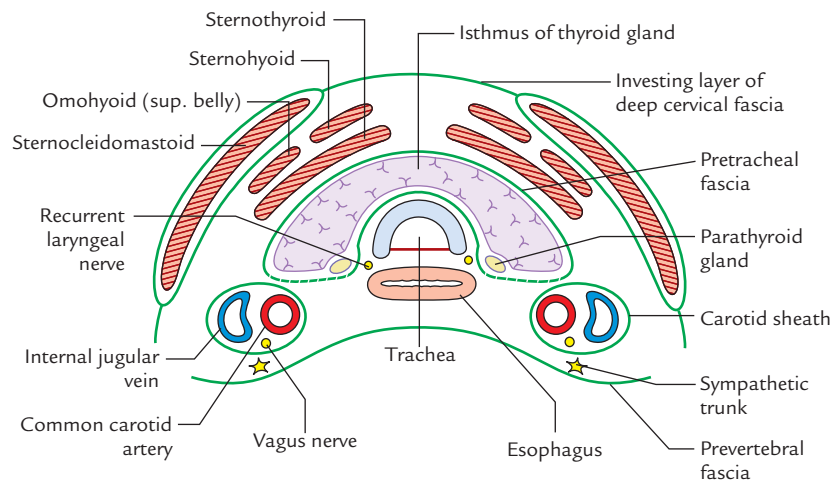


Fig. 11.5 Transverse section of the anterior part of the neck at the level of thyroid isthmus, showing relations of the thyroid gland.

it is limited above by the attachment of sternothyroid muscle. The apex is sandwiched between the inferior constrictor medially and sternothyroid laterally (Fig. 11.4).

- **Base:** The base extends up to the 5th or 6th tracheal ring. It is related to inferior thyroid artery and recurrent laryngeal nerve.
- **Lateral (superficial) surfaces:** It is convex and is covered by (Fig. 11.5):

- three strap muscles (sternothyroid, sternohyoid, and superior belly of omohyoid), and
- anterior border of sternocleidomastoid overlapping it inferiorly.

- **Medial surface** is related to (Fig. 11.6):

- two tubes: trachea and esophagus,
- two muscles: inferior constrictor and cricothyroid, and
- two cartilages: cricoid and thyroid.

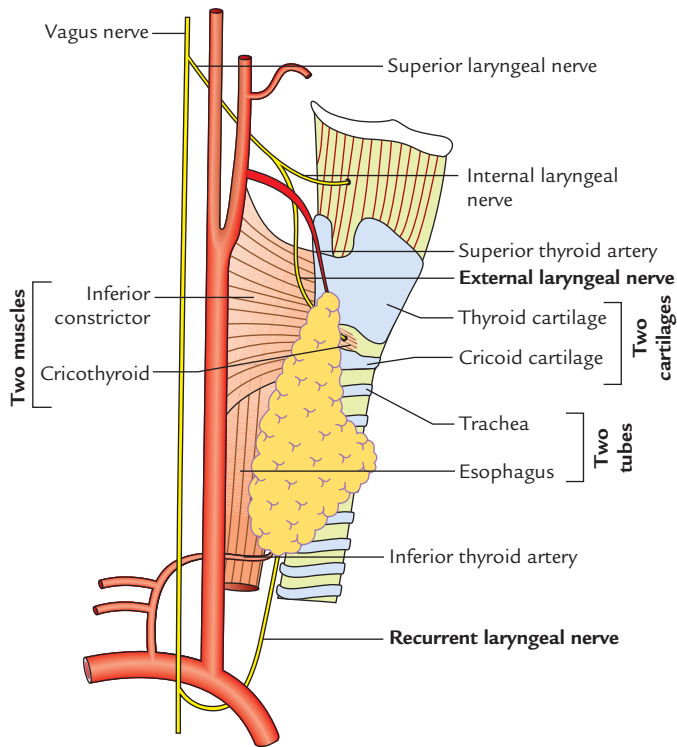


Fig. 11.6 Medial relations of the lateral lobe of the thyroid gland. The figure also shows intimate relationship of the external and recurrent laryngeal nerves with the superior and inferior thyroid arteries, respectively.

- **Posterolateral surface** is related to (Fig. 11.5) carotid sheath and its contents (common carotid artery, internal jugular vein, and vagus nerve). The ansa-cervicalis is embedded in the anterior wall of the sheath while cervical sympathetic chain lies posterior to sheath in front of prevertebral fascia.
- **Anterior border** is thin and separates superficial and medial surfaces. It is related to anterior branch of the superior thyroid artery.
- **Posterior border** is thick and rounded. It separates the medial and the posterior surfaces. It is related to (a) longitudinal arterial anastomosis between superior and inferior thyroid arteries, and (b) parathyroid glands.

Relations of Isthmus

The isthmus is horizontal and presents **two surfaces**—anterior and posterior and **two borders**—superior and inferior.

- **Anterior surface** is related to: (a) strap muscles (sternohyoid and sternothyroid) and (b) anterior jugular veins.
- **Posterior surface** is related to 2nd, 3rd, and 4th tracheal rings.

- **Superior border** is related to anastomosis between the anterior branches of two superior thyroid arteries.
- **Inferior border.** Along this border inferior thyroid vein emerge and thyroidea ima artery (when present) enters.

ARTERIAL SUPPLY

The gland is highly vascular and is supplied by the following arteries (Fig. 11.7):

1. **Superior thyroid artery:** It is a branch of the external carotid artery. It runs downwards and forwards in company with the external laryngeal nerve, which it leaves near the upper pole of the thyroid lobe. At the apex of the lobe, it divides into anterior and posterior branches. The anterior branch first descends along the anterior border of the lobe and then continues along the upper border of the isthmus to anastomose with its fellows of opposite side. The posterior branch descends along the posterior border of the lobe to anastomose with the ascending branch of the inferior thyroid artery. Superior thyroid artery supplies the **upper one-third of the lobe and upper half of the isthmus**.

2. **Inferior thyroid artery:** It is a branch of thyrocervical trunk from the first part of the subclavian artery. It first runs upwards along the medial border of scalenus anterior, and then passes medially behind the carotid sheath to reach the back of the thyroid lobe, where it is intimately related to the recurrent laryngeal nerve. The *recurrent laryngeal nerve presents a variable relationship with the artery*. It may pass behind or in front of the loop of the artery or between the branches of the artery (Fig. 11.8). The artery gives 4 or 5 branches. One

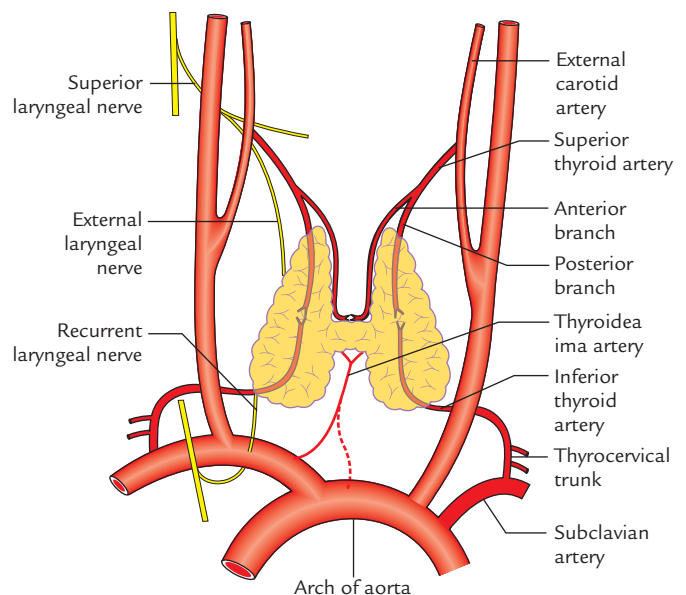


Fig. 11.7 Arterial supply of the thyroid gland.

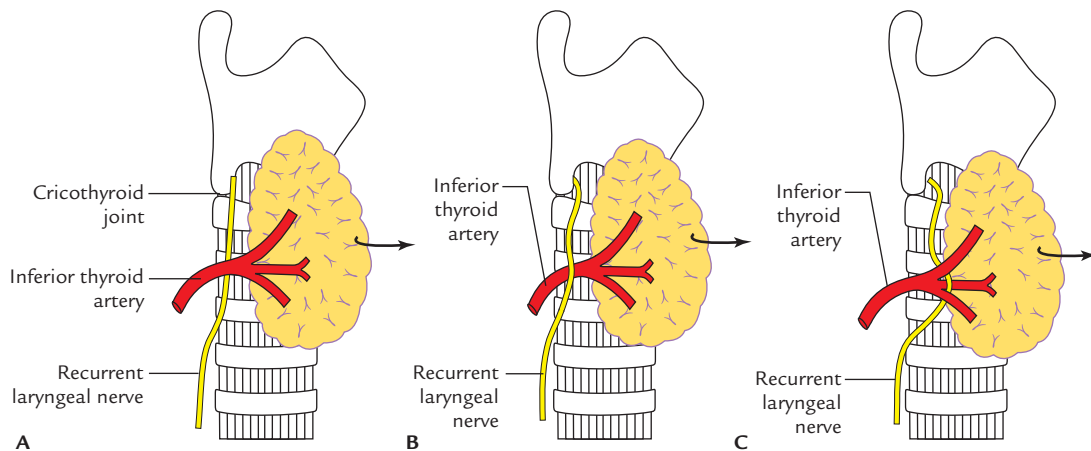


Fig. 11.8 Variable relationship of recurrent laryngeal nerve with the inferior thyroid artery.

ascending branch anastomoses with the posterior branch of the superior thyroid artery.

The inferior thyroid artery supplies lower two-third of the lobe and lower half of the isthmus.

3. **Thyroidea ima artery (in 30% cases):** It is a branch of the brachiocephalic trunk or may arise directly from the arch of aorta. It enters the isthmus from below.
4. **Accessory thyroid arteries:** They arise from tracheal and esophageal arteries.

VENOUS DRAINAGE

The venous blood from the thyroid gland is drained by three set of veins (Fig. 11.9), viz.

1. **Superior thyroid vein:** It emerges at the upper pole of the thyroid lobe, runs upwards and laterally, and drains into the internal jugular vein.

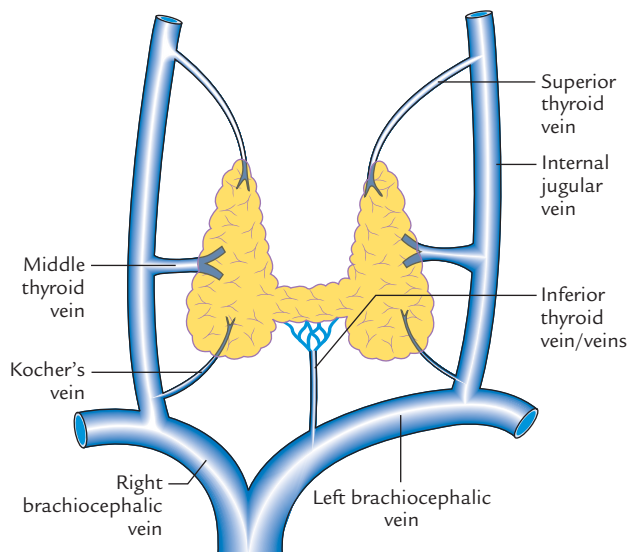


Fig. 11.9 Venous drainage of the thyroid gland.

2. **Middle thyroid vein:** This short, wide venous channel emerges at the middle of the lobe to soon enter the internal jugular vein.
3. **Inferior thyroid vein/veins:** They emerge at the lower border of the isthmus, form plexus in front of the trachea and then run downwards to drain into the left brachiocephalic vein.
4. Sometimes a fourth vein, the **thyroid vein (of Kocher)** emerges between the middle and inferior thyroid veins to drain into the internal jugular vein.

LYMPHATIC DRAINAGE (Fig. 11.10)

The lymph vessels draining the thyroid gland are arranged into two groups, upper and lower, and they follow the arteries:

1. The **upper group** drains into the prelaryngeal (lying in front of the larynx) and upper deep cervical (jugulo-digastric) lymph nodes.
2. The **lower group** drains into pretracheal and lower deep cervical lymph nodes and group of lymph nodes along the recurrent laryngeal nerves. Those from lower part of isthmus drain into retrosternal or brachiocephalic nodes lying in the superior mediastinum.

The upper lymphatics follow superior thyroid artery and lower lymphatics follow the inferior thyroid arteries.

NERVE SUPPLY

The thyroid gland is supplied by both sympathetic and parasympathetic nerve fibres:

1. The **parasympathetic supply** is derived from the vagus and recurrent laryngeal nerves.
2. The **sympathetic supply** is derived from the superior, middle, and inferior cervical sympathetic ganglia, but mainly from the middle one.

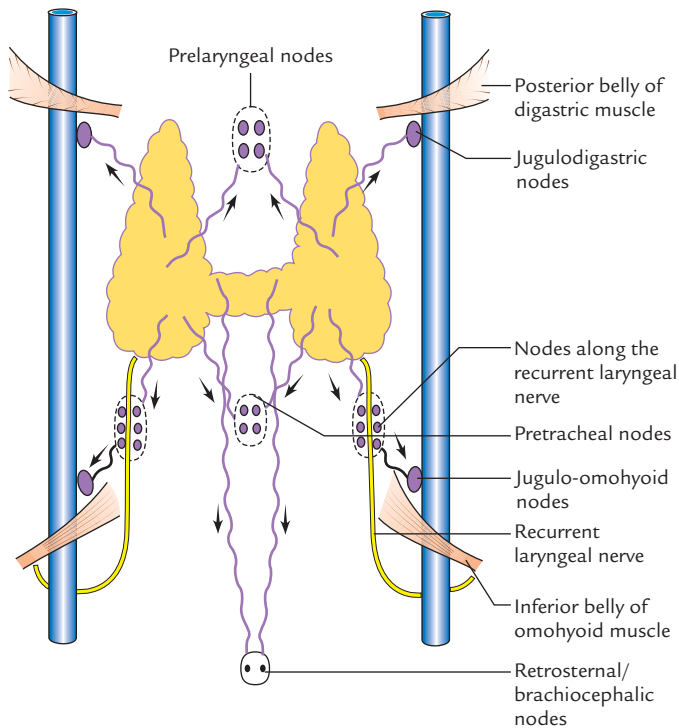


Fig. 11.10 Lymphatic drainage of the thyroid gland.

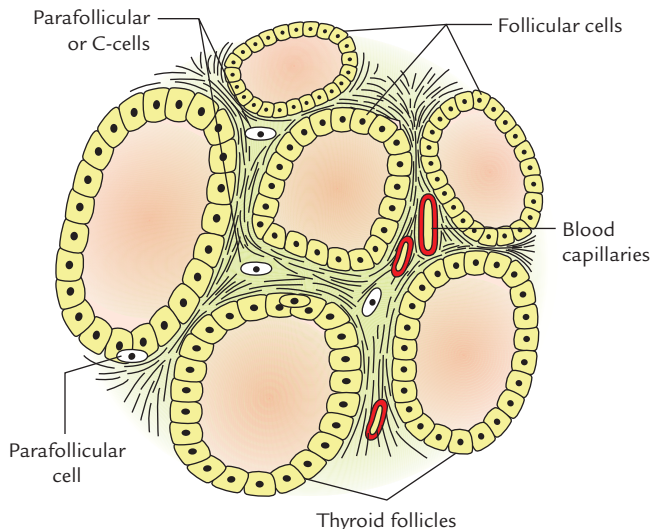


Fig. 11.11 Microscopic structure of the thyroid gland.

MICROSCOPIC STRUCTURE (Fig. 11.11)

The thyroid gland consists of two types of secretory cells: follicular and parafollicular.

The **follicular cells** are cuboidal epithelial cells forming the wall of spherical thyroid follicles. They secrete two hormones: thyroxine and triiodothyronine.

These hormones are essential for normal growth and development, specially of the skeletal and nervous system.

The **parafollicular cells** or **C-cells** lie mainly between the basement membrane and the follicular cells. Some of them also lie in the spaces between the follicles. They secrete a hormone called **thyrocalcitonin** (also called **calcitonin**). It plays an important role in calcium metabolism. It reduces the blood calcium level by reducing the reabsorption of the calcium by the renal tubules. Its effects are opposite to that of parathormone.

Clinical correlation

- **Goitre:** Any enlargement of the thyroid gland *except* that during menstruation and lactation is called *goitre*. It may be associated with hypofunction or hyperfunction of the gland.

Hypothyroidism occurs when there is insufficient secretion of the T3 and T4. The decreased levels of T3 and T4 cause increased secretion of TSH.

Hypothyroidism causes *cretinism* in children and *myxedema* in adults (for details see *General Anatomy* by Vishram Singh).

Hyperthyroidism (or *thyrotoxicosis*) occurs due to excess secretion of T3 and T4. The thyrotoxicosis clinically presents as: tachycardia, tremors, and systolic bruit. The main effects are due to increased BMR.

- **Simple goitre/puberty goitre:** It is an enlargement of the thyroid gland without signs of hyperthyroidism. It occurs due to deficiency of iodine in diet. Remember iodine is essential for synthesis of thyroid hormone. The decreased levels of T3 and T4 lead to increased secretion of TSH from the pituitary gland. The TSH causes hyperplasia of the thyroid gland. Simple goitre commonly occurs in females at the age of puberty, hence it is also called *puberty goitre*.

- **Effects of massive enlargement of thyroid gland (goitre; Fig. 11.12):** The thyroid gland can enlarge backwards or downwards but it cannot enlarge upwards due to attachment of its fascial sheath and sternothyroid muscle to the thyroid cartilage.

The backward enlargement is common because the thyroid capsule is relatively thin posteriorly. In backward enlargement, the gland buries itself around the sides of trachea and esophagus.

This results in three characteristic pressure symptoms, *viz.*

- **Dyspnea** (difficulty in breathing), due to pressure on trachea.
- **Dysphagia** (difficulty in swallowing), due to pressure on esophagus.
- **Dysphonia** (hoarseness of voice), due to pressure on the recurrent laryngeal nerve, which lies in the tracheoesophageal groove.

Mnemonic = 3D

The downward expansion behind the sternum is called *retrosternal goitre*. It can compress trachea leading to dangerous dyspnea.

It can also cause severe venous compression leading to venous congestion (Fig. 19.10).

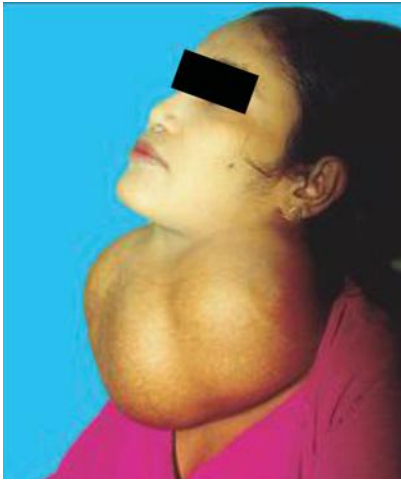

Fig. 11.12 Massive enlargement of the thyroid gland. (Source: Page 267, *Short Cases in Clinical Medicine*, 5e, ABM Abdullah, Copyright Elsevier 2013, All rights reserved.)

- **Ligation of thyroid arteries during thyroidectomy:** The superior thyroid artery and the external laryngeal nerve diverge from each other near the apex, the artery lies superficial and the nerve lies deep to the apex. Therefore, during thyroidectomy, the superior thyroid artery should be ligated as close to the apex of thyroid lobe as possible to avoid injury to the external laryngeal nerve.

The recurrent laryngeal nerve lies very close to the inferior thyroid artery near the base of the thyroid lobe. Therefore, during thyroidectomy, the inferior thyroid artery should be ligated as away from the base of the thyroid lobe as possible to avoid injury to the recurrent laryngeal nerve.

- **Benign tumors** may compress or also displace the neighboring structures whereas *malignant growth* tends to invade surrounding structures.

DEVELOPMENT (Fig. 11.13)

The thyroid gland begins to develop as endodermal thickening in the midline of the floor of the pharynx immediately behind the tuberculum impar during 3rd week of intrauterine life. This thickening is soon depressed below the surface to form a diverticulum called **thyroglossal duct**. This duct grows downwards across the tongue, then descends in front of the neck. In the neck, it passes in front of hyoid bone, binds around its lower border to become retrohyoid and finally descends below the hyoid with slight inclination to one side, usually to left to reach its definitive position (by the end of the 7th week) where its tip bifurcates and proliferates to form the bilateral terminal swellings, which expand to form the thyroid gland. A portion of the duct near its tip sometimes forms the **pyramidal lobe**. The remaining duct disappears. The site of origin of thyroglossal duct is, however, marked by **foramen caecum** at the junction of the anterior two-third and posterior one-third of the tongue in adults (Fig. 11.13). The thyroid is the

earliest glandular tissue to develop and becomes functional during the 3rd month.

N.B. The ultimobranchial bodies from 5th pharyngeal pouches and neural crest cells become incorporated secondarily into thyroid gland and form parafollicular cells or C-cells.

Clinical correlation

Congenital anomalies: The development of the thyroid gland may account for the following common congenital anomalies:

- **Thyroglossal cyst/fistula:** Thyroglossal duct may persist and lead to formation of *thyroglossal cyst* and *fistula*.
- **Ectopic thyroid:** The Thyroid gland (thyroid tissue) may be found at an abnormal position anywhere along the course of thyroglossal duct
 - (a) at the base of the tongue (*lingual thyroid*). In lingual thyroid, the mass of thyroid tissue is located within the tongue just beneath the foramen caecum, and if large, it may cause difficulty in swallowing by the infant.
 - (b) above, behind or below the hyoid bone (*suprahyoid, retrohyoid, or infrahyoid thyroid*).
- One of the lobes may be absent.
- Isthmus may be absent.
- Descent of the thyroglossal duct may go beyond the definitive position in the neck to superior mediastinum (*retrosternal thyroid*).
- Thyroid tissue may be situated away from the normal course of the thyroglossal duct, *viz.* in relation to carotid sheath, in the mediastinum, in the pericardium (*aberrant thyroid*).

PARATHYROID GLANDS

These are two pairs (superior and inferior) of small endocrine glands located along the posterior borders of the thyroid lobes within the thyroid capsule (Fig. 11.14). They appear as small yellowish-brown bodies.

The parathyroid glands secrete *parathormone* (a hormone), which maintains blood calcium level by mobilizing the calcium from the bones. Its action is opposite to that of *calcitonin* secreted by the thyroid.

Location

The **superior parathyroid** lies at the middle of the posterior border of the thyroid lobe above the level at which inferior thyroid artery crosses the recurrent laryngeal nerve. They develop from the fourth pharyngeal pouch and hence also termed as *parathyroid-IV*.

The **inferior parathyroid** lies on the posterior border of the thyroid lobe near its lower pole, below the inferior thyroid artery. They develop from the third pharyngeal pouch, hence also termed as *parathyroid-III*.

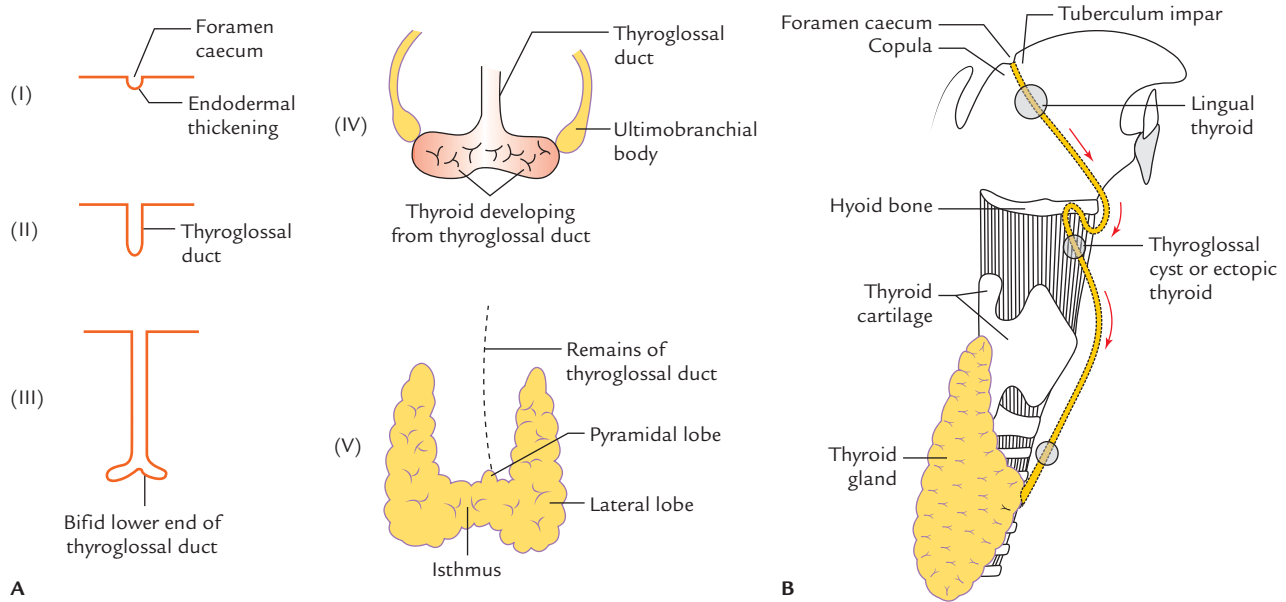


Fig. 11.13 Development of the thyroid gland: A, different stages in the development; B, shows the path taken by thyroglossal duct as it migrates inferiorly.

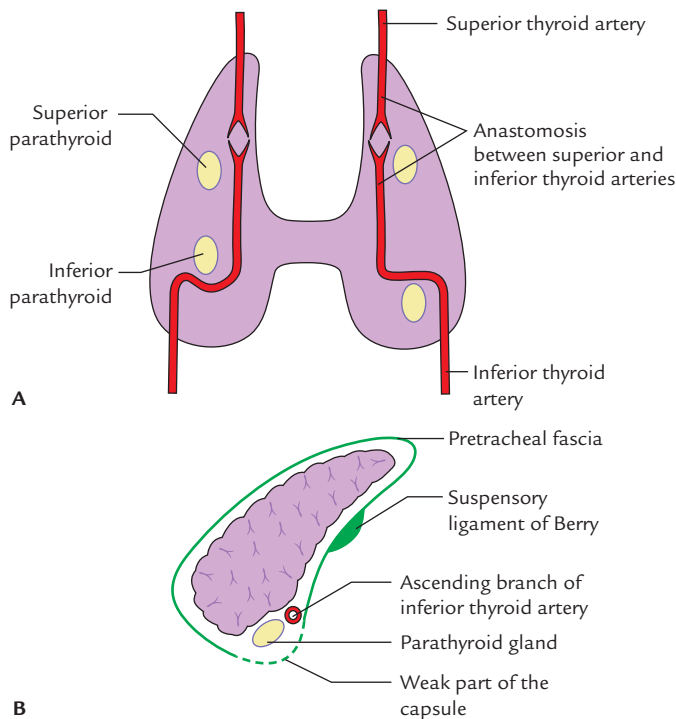


Fig. 11.14 Location of the parathyroid glands: A, posterior aspect of the thyroid gland; B, section through thyroid lobe along with its capsule.

N.B.

- The **superior parathyroid** is fairly constant in position and usually lies at the middle of the posterior border of the thyroid gland.

- The **inferior parathyroid** is more variable in position. It may lie: (a) within the thyroid capsule, below the loop of the inferior thyroid artery, (b) outside the capsule, above the loop of the thyroid artery, or (c) within the substance of the thyroid gland.

Size and Shape

They are small, oval or lentiform in shape. Each gland measures about 6 mm in length, 4 mm in breadth and 2 mm in thickness, the size of a split pea and weighs about 50 mg.

BLOOD SUPPLY

The parathyroid glands have rich blood supply.

The **superior parathyroid** is supplied by the superior parathyroid artery, a branch from anastomotic artery joining the superior and the inferior thyroid arteries, or from inferior thyroid artery.

The **inferior parathyroid** is supplied by the inferior parathyroid artery, a branch of inferior thyroid artery. The inferior parathyroid artery is a good guide to locate the parathyroid gland especially if it lies below the thyroid gland.

NERVE SUPPLY

The parathyroid glands are supplied by the sympathetic fibres, derived from the superior and middle cervical sympathetic ganglia or sympathetic plexus around the inferior thyroid artery. These fibres are vasomotor in nature.

The secretory activity of the gland is controlled by blood calcium level; low level of calcium stimulates secretion whereas high levels of calcium inhibit the secretion.

MICROSCOPIC STRUCTURE AND FUNCTIONS

The parenchymal cells of the gland form irregular anastomosing cords or groups of cells. The parenchymal cells are of two types: **principal or chief cells** and **oxyphil cells**. The chief cells form the major population and secrete parathyroid hormone called **parathormone**.

The oxyphil cells form minor population and their function is not known.

The parathyroid hormone plays an important role in calcium metabolism.

It maintains the blood calcium level by:

1. Enhancing the mobilization of calcium from bones by osteoclastic activity.
2. Increasing the reabsorption of calcium by proximal renal tubules.
3. Promoting the absorption of dietary calcium from small intestine.

Clinical correlation

- **Hypoparathyroidism** may occur spontaneously or due to inadvertent removal of parathyroid glands during thyroidectomy. It results in *tetany* due to low blood calcium level. Clinically the tetany presents as increased neuromuscular excitability, causing convulsions and carpopedal spasms (Fig. 11.15).
- **Hyperparathyroidism** is seen in the tumors of the parathyroid glands. The increased amount of parathormone: (a) removes excessive calcium from bones, which makes the bones soft due to decalcification leading to a clinical condition called *generalized osteitis fibrosa*, and (b) may cause *formation of stones in the kidney*.

DEVELOPMENT (Fig. 11.16)

The inferior parathyroid gland develops from the third pharyngeal pouch along with thymus. As the thymic diverticulum migrates inferiorly in the neck, it pulls inferior parathyroid with it. Consequently, the inferior parathyroid comes to lie finally on the posterior surface of the thyroid lobe near the lower pole.

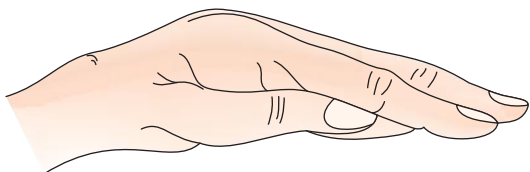


Fig. 11.15 Hand spasm in tetany.

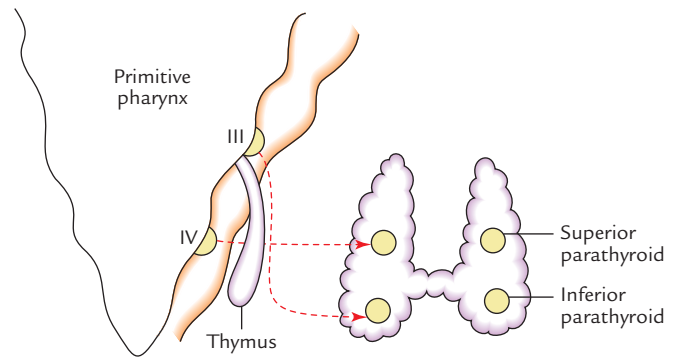


Fig. 11.16 Development of the parathyroid gland: sites of development and final positions taken by them.

The superior parathyroid gland develops from the fourth pharyngeal pouch and finally lies on the posterior surface of the thyroid lobe at the level of the isthmus.

TRACHEA

The trachea is a non-collapsible membrano-cartilaginous tube forming the beginning of lower respiratory passage.

EXTENT

Trachea extends from the lower border of cricoid cartilage at the lower border of the C6 vertebra to the lower border of T4 vertebra in supine position, where it terminates by dividing into right and left principal bronchi.

DIMENSIONS

The trachea is a 4–6 inch (10–11 cm) long tube. The upper half of trachea is located in the neck (**cervical part**) whereas the lower half lies in the superior mediastinum of the thoracic cavity (**thoracic part**).

The external diameter of trachea is 2 cm in males and 1.5 cm in females.

The lumen is smaller in living human than that in cadavers. It is about 3 mm in newborns and remains so up to the third year of life; thereafter the lumen increases by 1 mm each year up to 12 years, after which it remains fairly constant.

This knowledge is very important for the anesthetists to select the appropriate size of tracheal tube to be inserted into the trachea in children during general anesthesia.

STRUCTURE

The trachea is composed of about 16–20 C-shaped rings of hyaline cartilage lying one above the other. The cartilages are deficient posteriorly where the gap is filled by connective tissue and involuntary muscle called **trachealis**. The absence of cartilages on the posterior aspect allows expansion of

esophagus during deglutition. In cross section the trachea appears D-shaped or horseshoe-shaped. The following text deals with cervical part in detail. For thoracic part see *Textbook of Anatomy: Upper Limb and Thorax*, Vol. I by Vishram Singh.

CERVICAL PART OF TRACHEA

The cervical part of the trachea is about 7 cm in length and extends from the lower border of cricoid cartilage to the upper border of manubrium sterni. It extends downwards and slightly backwards in front of the esophagus following curvature of the cervical spine and enters the thoracic cavity in the median plane with slight deviation on the right side.

Relations of the Cervical Parts of Trachea

In the neck, the trachea is relatively superficial and has following relations:

Anteriorly, from superficial to deep it is related to:

- skin,
- superficial fascia containing anterior jugular veins and jugular venous arch (crossing in the suprasternal space of Burns),
- investing layer of deep cervical fascia,
- sternothyroid and sternohyoid muscles,
- isthmus of thyroid gland in front of the 2nd, 3rd, and 4th tracheal rings,
- inferior thyroid veins and arteria thyroidea ima (occasional),
- left brachiocephalic vein in children may rise in the neck,
- thymus gland (in children), and
- brachiocephalic artery (sometimes) in children.

Posteriorly it is related to:

- esophagus, and
- recurrent laryngeal nerve in the tracheoesophageal groove (on each side).

On each side it is related to:

- lobe of thyroid gland extending up to the 5th or 6th tracheal ring, and
- common carotid artery in the carotid sheath.

BLOOD SUPPLY AND LYMPHATIC DRAINAGE

The **arterial supply** of the cervical part of trachea is derived mainly from branches of the inferior thyroid arteries.

The **veins from trachea** drain into the left brachiocephalic vein.

The lymph from trachea drains into pre- and paratracheal nodes.

NERVE SUPPLY

This is by sympathetic and parasympathetic fibres.

The **parasympathetic fibres** are derived from vagus through the recurrent laryngeal nerve. They are secretomotor and sensory to the mucus membrane and motor to the trachealis muscle.

The **sympathetic fibres** are derived from the middle cervical sympathetic ganglion. They are vasomotor in nature.

Clinical correlation

Tracheostomy: It is a life-saving surgical procedure done in cases of laryngeal obstruction. The tracheostomy is commonly done in the retrothyroid region after displacing the isthmus of the thyroid gland upwards or downwards.

After displacing the isthmus the trachea is opened by a vertical incision in the region of the 3rd and 4th or 2nd and 3rd tracheal rings. This is then converted into circular opening and tracheostomy tube is inserted.

If the tracheostomy is performed above the isthmus it is called *high tracheostomy* and if it is performed below the isthmus it is called *low tracheostomy*.

The low tracheostomy is risky in children owing to shortness of the neck and presence of thymus and left brachiocephalic vein and sometimes brachiocephalic artery. These structures, if injured, will cause alarming hemorrhage.

ESOPHAGUS

The esophagus is 25 cm long muscular tube, which connects pharynx with the stomach. The esophagus is kept collapsed anteroposteriorly between trachea and vertebral column. Its expansion occurs only when bolus of food passes through it.

The esophagus begins as a continuation of pharynx at the lower border of cricoid cartilage opposite the lower border of C6 vertebra.

It passes downwards in front of the vertebral column behind trachea, traverses superior and posterior mediastina of thorax, passes through the esophageal opening of the diaphragm and ends at the cardiac orifice of the stomach in the abdomen about 2.5 cm to the left of the median plane.

The esophagus is divided into three parts: **cervical**, **thoracic**, and **abdominal**.

N.B. The pharyngoesophageal junction is the narrowest part of the digestive tube *except* that of the vermiform appendix.

CERVICAL PART OF THE ESOPHAGUS

It extends from the lower border of cricoid cartilage to the superior border of manubrium sterni. It begins in the midline but inclines slightly to the left as it descends.

Relations of the Cervical Part of the Esophagus

Anteriorly, it is related to:

- (a) trachea and
- (b) recurrent laryngeal nerve.

Posteriorly, it is related to:

- (a) prevertebral fascia,
- (b) longus colli muscles, and
- (c) vertebral column.

N.B. The prevertebral layer of deep cervical fascia forms a movable base on which the trachea and esophagus move up and down during swallowing and phonation.

On each side, it is related to:

- (a) lobe of the thyroid gland,
- (b) common carotid artery, and
- (c) thoracic duct on the left side.

BLOOD SUPPLY AND LYMPHATIC DRAINAGE

The cervical part of the esophagus is supplied by the **inferior thyroid arteries**.

The **veins** from this part drain into inferior thyroid veins and left brachiocephalic vein.

The lymph vessels from the cervical part of esophagus drain into pretracheal and deep cervical lymph nodes.

Clinical correlation

- The left margin of the esophagus projects laterally from behind the trachea in the region of the neck. Therefore the cervical part of esophagus can be mobilized and exposed surgically more easily from the left side.
- The interior of the esophagus can be examined in vivo by esophagoscope. This procedure helps to obtain tissue biopsy or removal of swallowed foreign body.

For the thoracic and abdominal part of the esophagus, see *Textbook of Anatomy: Upper Limb and Thorax*, Vol. I by Vishram Singh.

Golden Facts to Remember

▶ Largest endocrine gland of the body	Thyroid gland
▶ Earliest glandular tissue to develop and become functional	Thyroid tissue
▶ Most vascular endocrine gland in the body	Thyroid gland (adrenal medulla is also equally vascular)
▶ Most common form of incomplete descent of thyroid	Lingual thyroid
▶ Most common site of thyroglossal cyst	Subhyoid
▶ Most common cause of hypercalcemia in adult	Primary hyperparathyroidism
▶ Most common mode of clinical presentation of hyperparathyroidism	Renal stones
▶ Most common cause of hypoparathyroidism	Inadvertent removal during surgery, e.g., thyroidectomy
▶ Most preferred site of the tracheostomy	2nd or 3rd tracheal rings
▶ Commonest site of the cancer esophagus	Middle one-third of esophagus
▶ Most common site of the adenocarcinoma of esophagus	Lower one-third

Clinical Case Study



A 55-year-old woman complained of midline nodular swelling on the front of her neck, which moved up and down during swallowing. On physical examination, it was found that she had slight tremors on outstretched hands, her pulse rate was 11 per minute, B.P. 150/100 mmHg and there was slight bulging of her eyes. She also told that she had lost weight and felt feverish. She was diagnosed as a case of *toxic goitre*.

Questions

1. What is goitre?
2. Why thyroid swellings move up and down during swallowing?
3. Mention the anatomical basis of high body temperature, weight loss, high blood pressure, and exophthalmos.

Answers

1. Any enlargement of the thyroid gland except that during menstruation and lactation is called goitre.
2. The thyroid gland is enclosed in pretracheal fascia which anchors the gland with laryngeal cartilages (e.g., thyroid and cricoid). Since larynx moves up and down during swallowing, hence thyroid swelling also moves with it.
3. Toxic goitre is associated with hypersecretion of the thyroid hormones, which increases the rate of metabolism leading to high body temperature, weight loss, high blood pressure, and exophthalmos.

Pre- and Paravertebral Regions and Root of the Neck

The prevertebral region of the neck extends from first cervical vertebra to the upper two thoracic vertebrae. The upper two thoracic vertebrae are included because they are visible in the background of the root of the neck due to forward slope of the superior thoracic aperture. The paravertebral region lies on either side of prevertebral region and extends from transverse process of first cervical vertebra to the first rib. The root of the neck is defined as the area of the neck immediately above the thoracic inlet (Fig. 12.1). The structures encountered in these regions include anterior and lateral vertebral muscles, cervical plexus, cervical sympathetic chain, and large vessels.

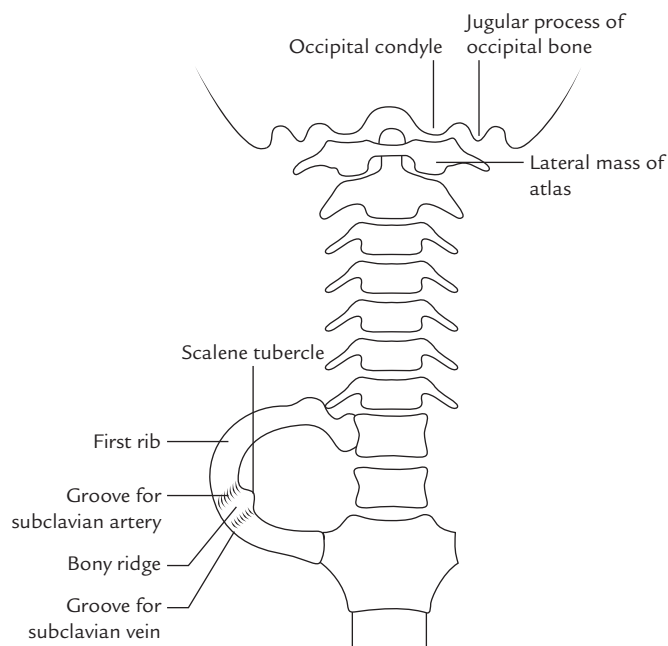


Fig. 12.1 Bony features in the pre- and paravertebral regions and the root of the neck.

PREVERTEBRAL (ANTERIOR VERTEBRAL) MUSCLES

The anterior vertebral muscles lie in front of the cervical part of the vertebral column. All of them are covered by prevertebral fascia and supplied by ventral rami of cervical nerves. They form the posterior boundary of the retropharyngeal space. As a group, they flex the neck and the head on the neck.

The anterior vertebral group of muscles include (Figs 12.2 and 12.3):

1. Rectus capitis anterior.
2. Rectus capitis lateralis.

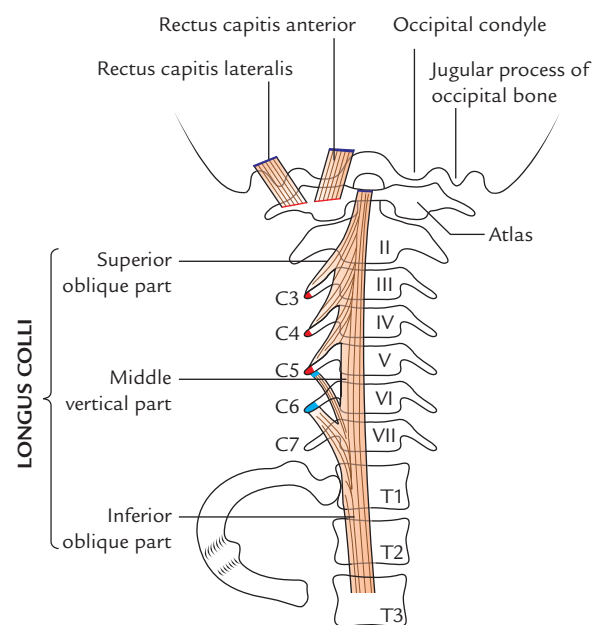


Fig. 12.2 Attachments of the anterior vertebral muscles.

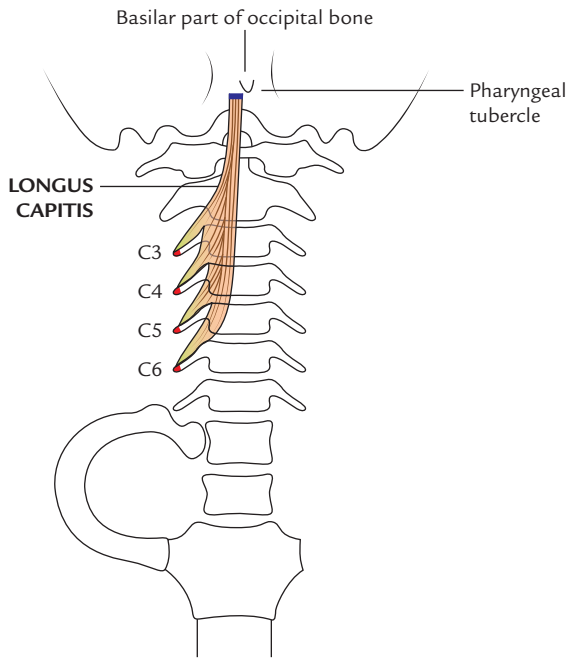


Fig. 12.3 Attachment of the longus capitis muscle.

3. Longus cervicis (longus colli).
4. Longus capitis.

Rectus capitis anterior (Fig. 12.2)

It arises from the anterior surface of the lateral mass of the atlas, extends upwards and slightly medially to be inserted on the inferior surface of the basiocciput just in front of the occipital condyle.

Rectus capitis lateralis (Fig. 12.2)

It arises from the upper surface of the transverse process of the atlas, runs upwards and laterally to be inserted on the inferior surface of the jugular process of the occipital bone. It is separated from rectus capitis anterior by the *ventral ramus of the 1st cervical nerve*, which supplies both these muscles.

Longus cervicis (longus colli; Fig. 12.2)

This is the longest and medial of the prevertebral muscles. It extends from anterior tubercle of the atlas to the anterior aspect of the 3rd thoracic vertebra.

The longus colli consists of three parts, *viz.*

1. Upper oblique part.
2. Lower oblique part.
3. Middle vertical part.

The **upper oblique part** arises from anterior tubercles of transverse processes of C3, C4, and C5 vertebrae, passes upwards and medially to be inserted on the anterior arch of the atlas to the side of the anterior tubercle.

The **middle vertical part** arises from the front of bodies of the upper three thoracic and lower three cervical vertebrae

and ascends up, to be inserted on the front of the bodies of the 2nd, 3rd, and 4th cervical vertebrae.

The **inferior oblique part** is the smallest. It arises from front of the bodies of the upper 2 or 3 thoracic vertebrae, runs upwards and laterally to be inserted onto the anterior tubercles of the transverse processes of the 5th and 6th cervical vertebrae.

Nerve supply: The longus colli is supplied segmentally by branches from anterior primary rami of C2 to C6 spinal nerves.

Actions: It bends the neck forwards. In addition, upper oblique part may flex the neck laterally and lower oblique part rotates the neck to the opposite side.

Longus capitis (Fig. 12.3)

It arises from anterior tubercles of the transverse processes of C3, C4, C5, and C6 vertebrae, corresponding to the origin of scalenus anterior muscle and inserted on the inferior surface of the basilar part of the occipital bone along the side of pharyngeal tubercle. It is narrow below and thick above, and overlaps the longus colli (cervicis) muscle.

Nerve supply: It is supplied by branches of anterior primary rami of C1, C2, and C3 spinal nerves.

Actions: Longus capitis flexes the head.

PARAVERTEBRAL (LATERAL VERTEBRAL) MUSCLES

The paravertebral muscles extend from transverse processes of cervical vertebrae to the upper two ribs. They can, therefore, either elevate these ribs or bend the cervical part of the vertebral column laterally.

These muscles form a thick mass behind the prevertebral fascia and supplied by twigs from ventral rami of the lower 5 or 6 cervical spinal nerves.

The lateral vertebral group of muscles consists of scalene muscles.

The scalene muscles, usually three in number, are as follows:

1. Scalenus posterior.
2. Scalenus medius.
3. Scalenus anterior.

N.B. The scalenus medius is the largest and scalenus posterior is the smallest.

Scalenus Posterior (Fig. 12.4)

It is **smallest** and most deeply situated.

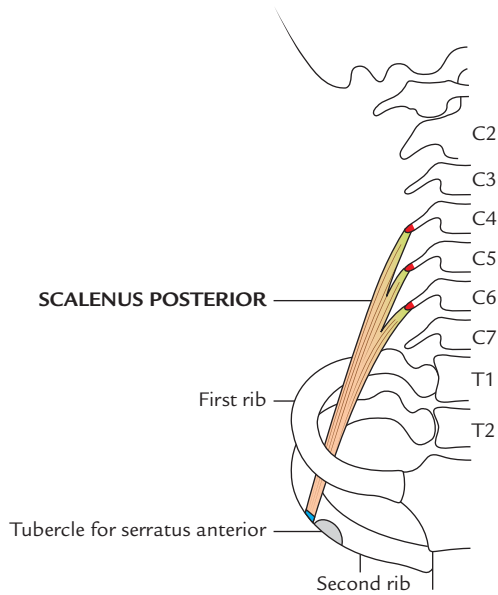


Fig. 12.4 Attachments of the scalenus posterior muscle.

Origin

From posterior tubercles of the transverse processes of C4, C5, and C6 vertebrae.

Insertion

On to the outer surface of second rib, behind the tubercle for serratus anterior.

Nerve supply

By ventral rami of the lower three cervical (C6, C7, and C8) spinal nerves.

Actions

1. When the 2nd rib is fixed, it bends the cervical vertebral column to the same side.
2. When upper attachment is fixed, it helps to elevate the 2nd rib and thus acts as an accessory muscle of respiration.

Scalenus Medius (Fig. 12.5)

It is longest and largest of all the scalene muscles.

Origin

From posterior tubercles of the transverse processes of C2–C6 cervical vertebrae.

Insertion

On to the upper surface of the first rib between the tubercle of the rib and groove for subclavian artery.

Nerve supply

By ventral rami of C3–C8 spinal nerves.

Actions

1. When first rib is fixed, it bends the neck to the same side.

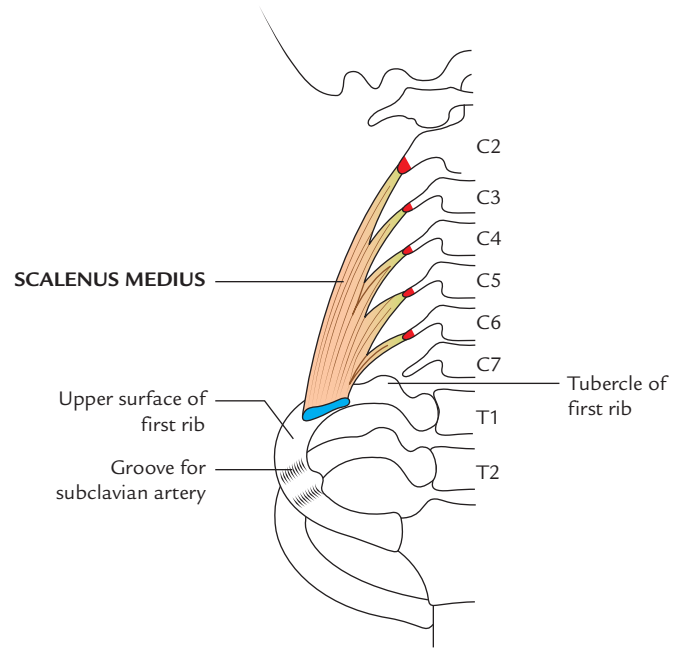


Fig. 12.5 Attachments of the scalenus medius muscle.

2. When upper end is fixed, it elevates the first rib and thus acts as an *accessory muscle of respiration*.

Scalenus Anterior (Fig. 12.6)

It is **most superficial** and lies deep to sternocleidomastoid muscle. It is the *key muscle at the root of neck* because of its intimate relations to many structures in this region. It provides a useful *surgical landmark*.

Origin

From anterior tubercles of transverse processes of C3, C4, C5, and C6 vertebrae (i.e., all typical vertebrae).

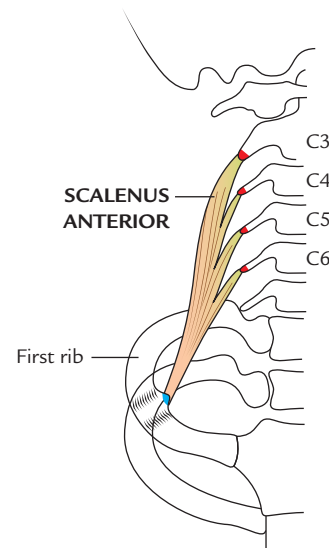


Fig. 12.6 Attachments of the scalenus anterior muscle.

Insertion

The fibres converge and descend almost vertically to be inserted by a narrow, flat tendon to the scalene tubercle on the inner border of the 1st rib and to the ridge on the upper surface of the rib anterior to the groove for the subclavian artery.

Nerve supply

By ventral rami of C4, C5, and C6 spinal nerves.

Actions

1. Acting from below, it bends the neck forwards and laterally and rotates it to the opposite side.
2. Acting from above, it helps to elevate the 1st rib and thus acts as an accessory muscle of respiration.

Relations of the scalenus anterior muscle (Fig. 12.7)

The scalenus anterior muscle forms an important landmark at the root of the neck because phrenic nerve passes superficial to it, subclavian artery deep to it and brachial plexus lies at its lateral border.

Therefore the relations of scalenus anterior muscle are very important.

Anterior relations:

1. **Phrenic nerve** runs downward across the anterior surface of the muscle deep to prevertebral fascia.
2. **Two arteries**—transverse cervical and suprascapular—cross the anterior surface of muscle from medial to lateral side.
3. **Two veins**
 - (a) *Anterior jugular vein* crosses the muscle from above downwards.
 - (b) *Subclavian vein* crosses the anterior surface near insertion from lateral to medial side.

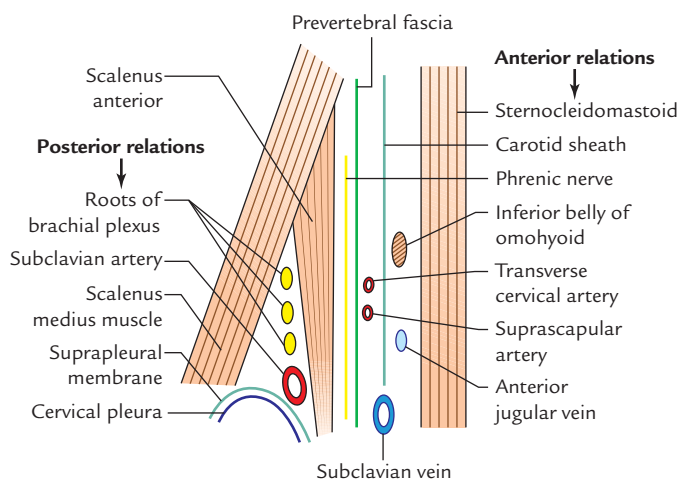


Fig. 12.7 Schematic sagittal section to show the anterior and posterior relations of the scalenus anterior muscle.

4. Two muscles

- (a) *Inferior belly of omohyoid* crosses the anterior surface from medial to lateral side.
 - (b) *Sternocleidomastoid (clavicular head)* overlaps the muscle.
5. **Carotid sheath** lies vertically in front of the muscle.
 6. **Clavicle** crosses from medial to lateral side.

Posterior relations:

1. **Roots of brachial plexus** separates the scalenus anterior from scalenus medius.
2. **Subclavian artery** passes deep to scalenus anterior near its insertion from medial to lateral side, separating it from scalenus medius.
3. **Scalenus medius muscle (medial part).**
4. **Cervical pleura.**
5. **Suprascapular membrane.**

Other relations:

1. The **medial border** of scalenus anterior forms the lateral boundary of the **scalenovertbral triangle or triangle of the vertebral artery**. The contents of this triangle form the medial relations of the scalenus anterior.
2. The **lateral border** of the scalenus anterior is related to trunks of brachial plexus, which emerge underneath it.
3. The **upper part of scalenus anterior** is separated from longus capitis by the ascending cervical artery.

SCALENE (SUBCLAVIAN) TRIANGLE (Fig. 12.8)

It is a narrow triangular gap above the 1st rib between scalenus anterior and scalenus medius. The subclavian artery and brachial plexus pass through this space.

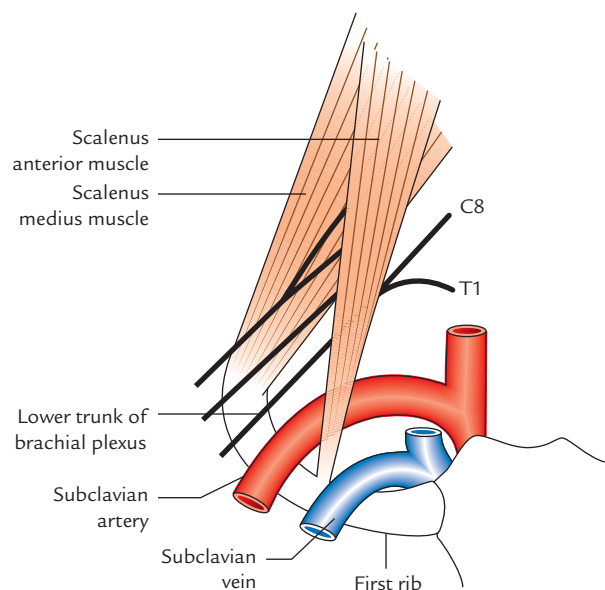


Fig. 12.8 Scalene triangle.

Clinical correlation

Scalene syndrome: It consists of group of signs and symptoms produced due to compression of lower trunk of brachial plexus (C8 and T1) and subclavian artery in the scalene triangle either due to raising of its base by the cervical rib, if present, or due to spasm of scalene muscles. Clinically, this syndrome presents as:

- tingling sensation and numbness along the inner border of forearm and hand, i.e., along the distribution of C8 and T1 spinal nerves,
- progressive paresis and wasting of intrinsic muscles of the hand (most of them are supplied by C8 and T1 spinal nerves), and
- ischemic pain and absence of radial pulse due to compression of subclavian artery.

SCALENOVERTEBRAL TRIANGLE (TRIANGLE OF VERTEBRAL ARTERY; Fig. 12.9)

It is a deeply placed triangular space at the root of the neck between scalenus anterior laterally and longus colli (cervicis) medially. The cervical pleura and apex of lung project upward into this space.

Boundaries:

- Medial:** Lower oblique part of the longus colli.
Lateral: Medial border of scalenus anterior.
Apex: Transverse process of C6 vertebra.
Base: First part of the subclavian artery.
Floor (posterior wall): From above downwards, it is formed by:

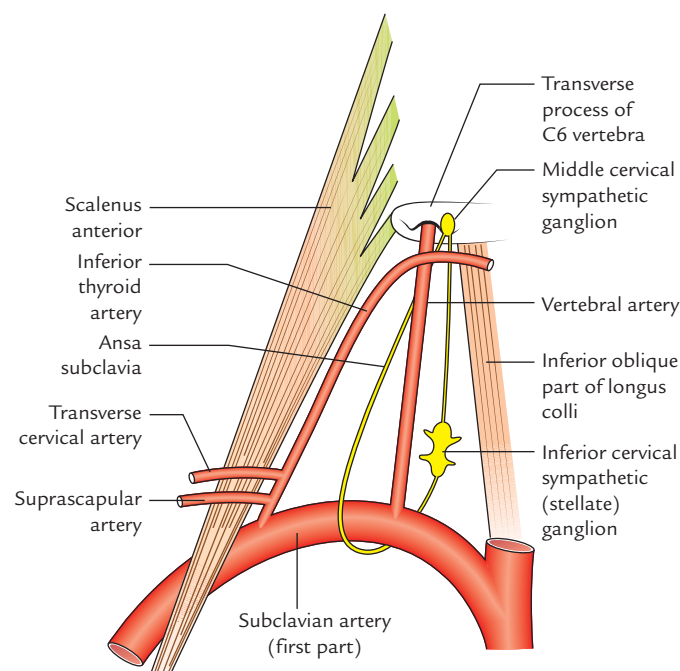


Fig. 12.9 Boundaries and contents of triangle of vertebral artery.

- transverse process of C7 vertebra,
- ventral ramus of C8 spinal nerve, which passes laterally above the neck of first rib,
- neck of first rib, and
- cupola of cervical pleura.

Roof:

It is formed by carotid sheath.

Contents:

- First part of vertebral artery and accompanying veins.** The artery extends upwards vertically from the base to enter the foramen transversarium of C6 at the apex.
- Thyrocervical trunk and inferior thyroid artery;** the later arches medially across the apical part of the triangle.
- Sympathetic chain with stellate ganglion** lies posterolateral to vertebral artery.
- Thoracic duct** on the left side arches laterally at the level of transverse process of C7 vertebra.
- Ansa subclavia.**

N.B. *Scalenus minimus (pleuralis):* The scalenus minimus is the fourth rudimentary scalene muscle.

It arises from the anterior border of the transverse process of C7 vertebra and inserted to the inner border of the 1st rib behind the groove for the subclavian artery and to the dome of the cervical pleura.

The *suprapleural membrane* is regarded as the flattened tendon of this muscle.

The contraction of scalenus minimus pulls up the dome of pleura to make it tense.

CERVICAL PLEXUS

Formation

It is formed by ventral rami of the upper four cervical nerves. The position of rami of cervical spinal nerves in relation to paravertebral muscles is shown in Figure 12.10. The ventral

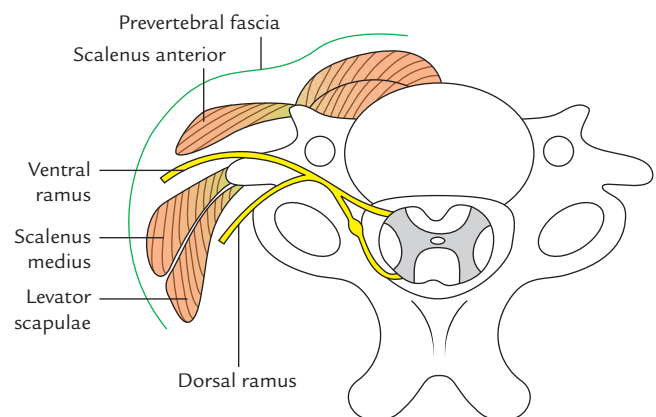


Fig. 12.10 Position of rami of cervical spinal nerve in relation to prevertebral muscles.

rami of C2–C4 divide into upper and lower branches. The ventral ramus of C1 and branches of C2–C4 ventral rami are connected with one another to form three loops, hence cervical plexus is also called **plexus of loops**. The *first loop* is directed forwards in front of the transverse process of atlas and the remaining two loops are directed backwards (Fig. 12.11).

Position and relations

The cervical plexus lies on levator scapulae and scalenus medius muscles deep to prevertebral fascia, internal jugular vein, and sternocleidomastoid.

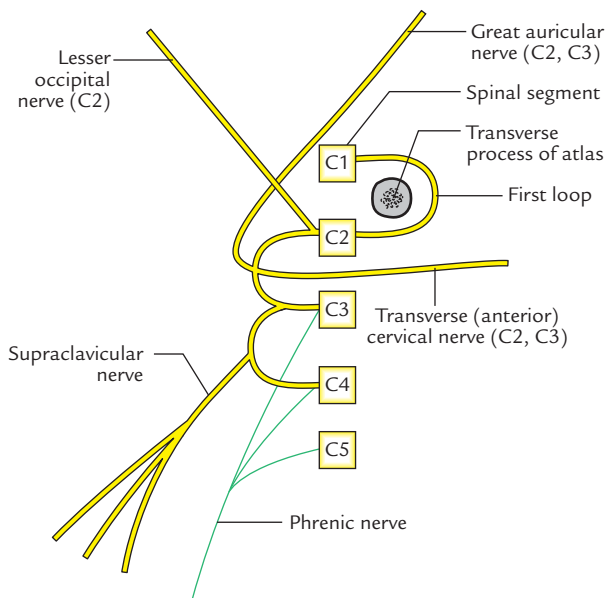


Fig. 12.11 Cervical plexus with loops and its cutaneous branches.

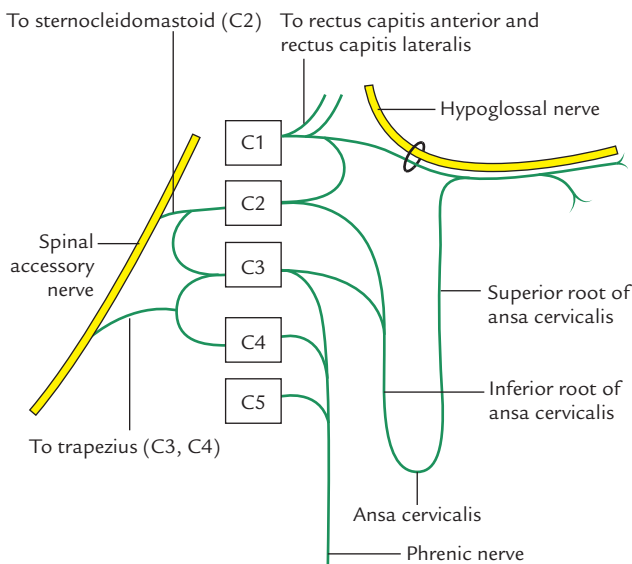


Fig. 12.12 Cervical plexus with its communicating branches.

Branches (Figs 12.11 and 12.12)

The cervical plexus supplies skin and muscles of the neck, and the thoracoabdominal diaphragm. Its branches are arranged into superficial and deep groups.

Superficial (cutaneous) branches are as follows:

1. Lesser occipital nerve (C2).
2. Great auricular nerve (C2, C3).
3. Transverse (anterior) cervical nerve (C2, C3).
4. Supraclavicular nerve (C3, C4).

Deep branches are as follows:

1. **Communicating branches, viz.:**
 - (a) Grey rami communicantes from superior cervical sympathetic ganglion to all the 4 roots.
 - (b) A branch of C1 joins the hypoglossal nerve.
 - (c) A branch from C2 to sternocleidomastoid and branches from C3–C4 to trapezius communicate with spinal accessory nerve.
2. **Muscular branches:** The following muscles are supplied by cervical plexus:
 - (a) Rectus capitis anterior (C1).
 - (b) Rectus capitis lateralis (C1, C2).
 - (c) Longus capitis (C1–C3).
 - (d) Longus colli (C2–C4).
 - (e) Strap muscles (C1–C3).
 - (f) Sternocleidomastoid (C2).
 - (g) Trapezius (C3, C4).
 - (h) Levator scapulae (C3, C4).
 - (i) Scalene muscles (C3, C4).
 - (j) Diaphragm (C3, C4).

ANSA CERVICALIS

It is described in detail on page 92.

PHRENIC NERVE

Origin

It arises from ventral rami of C3, C4, and C5 but chiefly from C4.

Course

It runs vertically downwards on the anterior surface of the scalenus anterior, which it crosses obliquely from lateral to medial side. Then it runs downwards on the cervical pleura to enter the thorax behind first costal cartilage.

Distribution

The phrenic nerve provides:

- (a) sole motor supply to the diaphragm (muscle of respiration), and
- (b) sensory innervation to diaphragmatic pleura, pericardium, and subdiaphragmatic pleura.

Accessory phrenic nerve

It is the branch from *nerve to subclavius* containing C5 fibres. It runs lateral to phrenic nerve and descends behind or sometimes in front of the subclavian vein to join the main phrenic nerve near the 1st rib.

N.B. In case of accessory phrenic nerve, the fibres of C5 nerve in spite of joining the phrenic nerve at its commencement runs through, nerve to subclavius and then leaves it as accessory nerve to join the main phrenic nerve at the thoracic inlet.

Clinical correlation

Phrenic crush/avulsion: Before the advent of modern antitubercular treatment, phrenic crush used to be done to produce paralysis of the corresponding half of the diaphragm in order to provide rest to the diseased lung and thus promote healing.

In *phrenic crush* the accessory phrenic nerve, if present, should also be crushed, otherwise C5 fibres will escape and diaphragm will continue to function.

CERVICAL PART OF THE SYMPATHETIC TRUNK (Fig. 12.13)

The two sympathetic trunks (right and left) extend from the base of the skull to the base of coccyx, where they join to form **ganglion impar**.

The **cervical part of sympathetic trunk**, one on either side of cervical part of the vertebral column lies in front of the transverse processes of cervical vertebrae and neck of the 1st rib behind the carotid sheaths and in front of prevertebral fascia.

Each trunk is continuous upwards into the cranial cavity as the **internal carotid nerve** accompanying the internal carotid artery. Inferiorly, it becomes continuous with the thoracic part of the sympathetic chain at the neck of the 1st rib.

The cervical part of sympathetic trunk does not receive the preganglionic fibres through white rami communicantes from the cervical segments of the spinal cord, but it does give grey rami communicantes to all the cervical spinal nerves. Each trunk receives preganglionic fibres from lateral horn cells of T1–T4 spinal segments.

CERVICAL SYMPATHETIC GANGLIA

There are three cervical sympathetic ganglia: superior, middle, and inferior. They are formed by the fusion of eight primitive ganglia, corresponding to eight cervical nerves. The characteristics of these ganglia are as follows:

- Superior cervical ganglion**
 - It is the largest of the cervical sympathetic ganglion.

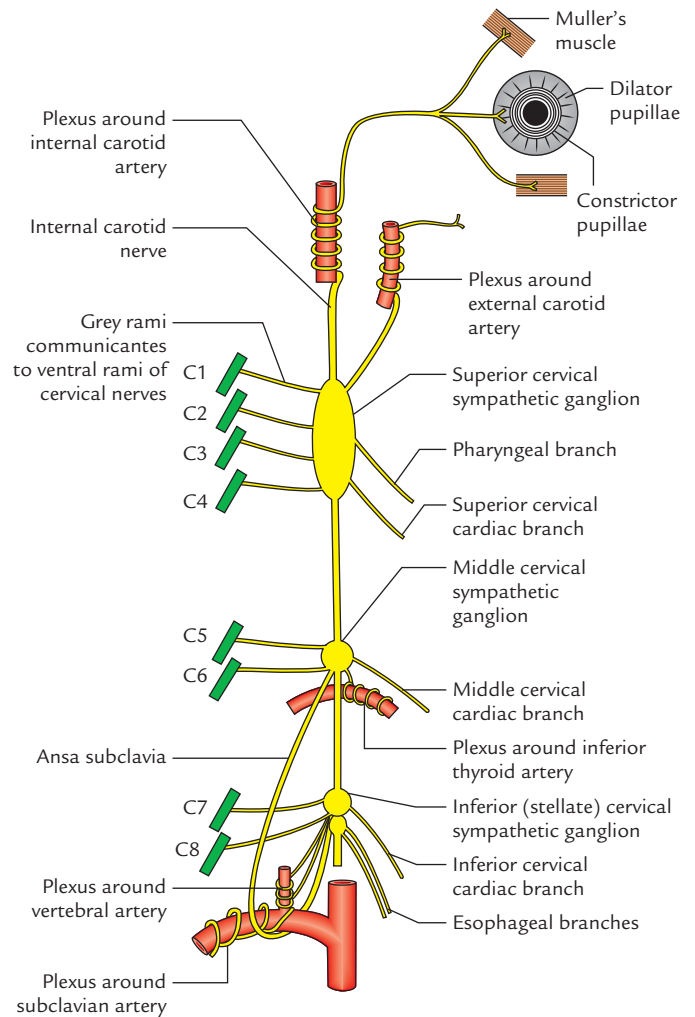


Fig. 12.13 Cervical sympathetic trunk and its branches.

- It is spindle-shaped and about 2.5 cm long.
 - It lies just below the skull, in front of transverse processes of C2 and C3 vertebrae, behind the carotid sheath and in front of the prevertebral fascia.
 - It is formed by the fusion of four primitive cervical ganglia.
- Middle cervical ganglion**
 - It is very small and often absent.
 - It lies in the lower part of the neck, in front of transverse process of C6 just above the inferior thyroid artery.
 - It is formed by the fusion of the 5th and 6th primitive cervical ganglia.
 - Inferior cervical ganglion**
 - It is formed by the fusion of the 7th and 8th primitive cervical ganglia.
 - It is generally fused with the 1st thoracic ganglion to form the **cervicothoracic ganglion**; it is also called **stellate ganglion** because of its star-shaped appearance.

- (c) It lies between transverse process of C7 and the neck of the rib.

Branches

Each of the three ganglia gives three common types of branches, *viz.*

1. Grey rami communicantes to cervical nerves.
2. A cardiac branch/nerve.
3. A branch/branches to form a plexus around an artery.

Branches of Superior Ganglion

These are as follows:

1. Grey rami communicantes to ventral rami of upper four cervical nerves.
2. Superior cardiac nerve.
3. Carotid branches form sympathetic plexus around internal and external carotid arteries.

In addition to the above mentioned branches, superior ganglion also gives rise to a *pharyngeal branch*, which takes part in the formation of pharyngeal plexus of nerves.

Branches from Middle Ganglion

These are as follows:

1. Grey rami communicantes to ventral rami of C5 and C6 spinal nerves.
2. Thyroid branches to form a plexus around the inferior thyroid artery.
3. Middle cervical cardiac nerve.

In addition to the above mentioned branches, the middle cervical ganglion also gives rise to **tracheal and esophageal branches**.

Branches from Inferior Ganglion

These are as follows:

1. Grey rami communicantes to ventral rami of C7 and C8 spinal nerves.
2. Inferior cervical cardiac nerve.
3. Vertebral and subclavian branches, which form plexus around vertebral and subclavian arteries, respectively.

N.B. *Ansa subclavia* is a nerve loop around subclavian artery connecting middle and inferior cervical ganglia.

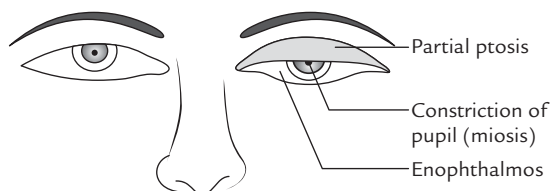


Fig. 12.14 Horner's syndrome (left side).

Clinical correlation

Horner's syndrome: The head and neck region is supplied by the sympathetic fibres, which arise in the upper thoracic spinal segments. These preganglionic fibres pass through stellate ganglion to relay in the superior cervical sympathetic ganglion. The postganglionic fibres arise from cells of this ganglion and supply the structures in the head and neck.

An injury to cervical sympathetic trunk produces a clinical condition called *Horner's syndrome*.

Characteristic features (Fig. 12.14)

- *Partial ptosis* (partial drooping of upper eyelid), due to paralysis of smooth part of levator palpebrae superioris muscle (Muller's muscle).
- *Miosis*, i.e., constriction of the pupil, due to paralysis of dilator pupillae.
- *Anhydrosis*, i.e., loss of sweating on that side of face, due to sudomotor and vasoconstrictor denervation.
- *Increased temperature and redness*.
- *Enophthalmos*, i.e., sunken eyeball, not confirmed by ophthalmometry.
- *Loss of ciliospinal reflex*, i.e., pinching the skin of the back of neck does not produce dilation of the pupil, which in healthy person takes place.

ROOT OF THE NECK

The root of the neck is defined as the area of the neck immediately above the thoracic inlet. The thoracic inlet is a space bounded by 1st thoracic vertebra, 1st rib, and manubrium sterni. The structures pass both into and out of the thoracic cavity through this space (Fig. 12.15).

The clinical importance of this area is that the numerous important structures, such as carotid and subclavian arteries, the trachea and esophagus, and large veins are all packed together into this relatively small space. Therefore, any further decrease in this space may lead to dire consequences. The reduction in space may be caused by a number of clinical conditions such as tumor of apex of lung (**Pancoast tumor**), enlarged thyroid gland, cervical rib, etc. The students should read this region very carefully.

The following structures merit description in detail:

1. Scalenovertbral triangle/triangle of vertebral artery (see page 172).
2. Scalene/subclavian triangle (see page 171).
3. Cervical pleura.

CERVICAL PLEURA

The cervical pleura covers the apex of the lung at the root of the neck. It rises into the root of the neck about 3.4 cm above the 1st costal cartilage but not above the neck of the first rib due to obliquity of the 1st rib. It rises 2.5 cm above the medial third of the clavicle.

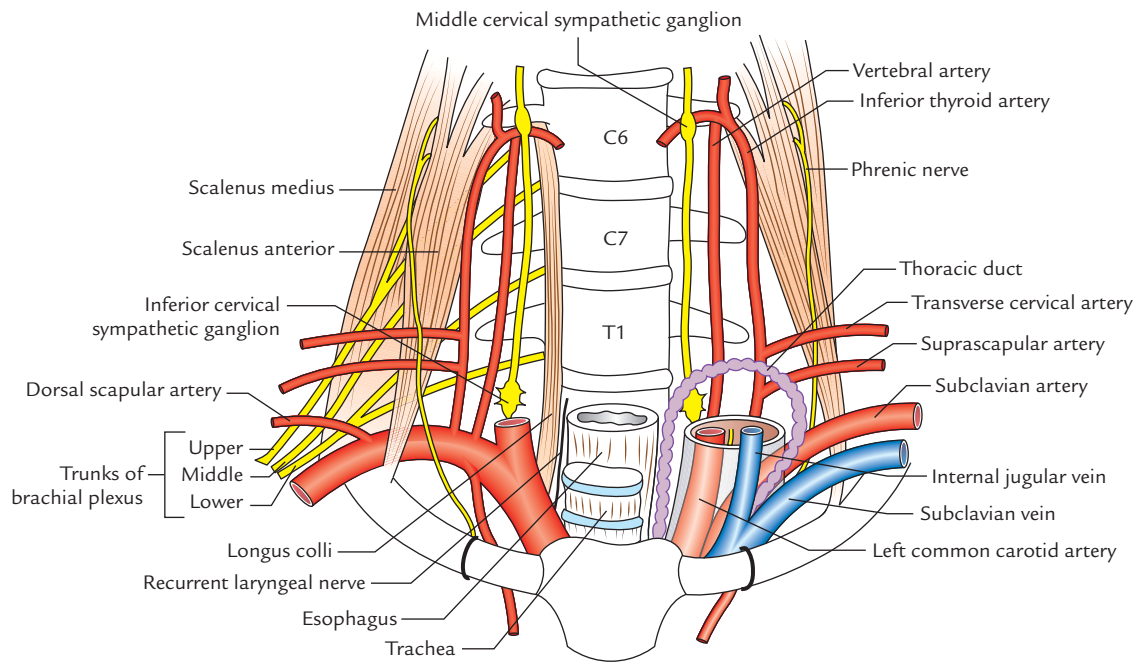


Fig. 12.15 Deep structures at the root of the neck.

The cervical pleura is strengthened by the suprapleural membrane (also called *Sibson's fascia*) so that the root of the neck is not puffed up and down during respiration.

Relations

Anterior:

1. Subclavian artery.
2. Scalenus anterior.

Posterior:

Neck of first rib and structures crossing in front of it.

Lateral:

1. Scalenus medius.
2. Lower trunk of brachial plexus.

Medial:

1. Vertebral bodies.
2. Trachea and esophagus.
3. Recurrent laryngeal nerve in the tracheoesophageal groove.
4. Thoracic duct on the left side.
5. Large blood vessels of the neck.

N.B. Structures crossing in front of the neck of 1st rib from medial to lateral side are:

- Sympathetic chain.
- First posterior intercostal vein.

- Superior intercostal artery.
- First thoracic nerve (large ascending branch of its ventral ramus).

LYMPH TRUNKS AT THE ROOT OF THE NECK

The lymph from head and neck region is returned to the venous blood via left and right lymph trunks, which converge at the root of neck at the junction of internal jugular and subclavian veins. The various lymph trunks which converge on the right and left side of the root of the neck are as described in the following text:

On the right side of neck—the three trunks that converge are as follows:

1. **Right jugular trunk** extends along the ventrolateral aspect of the internal jugular vein. It drains lymph from right half of the head and neck.
2. **Right subclavian trunk** extends along the axillary and subclavian veins and draws lymph from the right upper limb and superficial tissues of the right half of the thoracoabdominal wall down to the umbilicus anteriorly and iliac crest posteriorly.
3. **Right bronchomediastinal trunk** ascends over the trachea. It drains lymph from right lung, bronchi and trachea, and right half of the mediastinum.

The right jugular and subclavian trunks may unite to form *right lymphatic duct*, which ends in a similar way to that of the thoracic duct (see page 177).

On the left side—the four trunks that converge are as follows:

1. **Left Jugular trunk** drains lymph from left half of the head and neck. Its course and termination is similar to that on the right side.
2. **Left subclavian trunk** drains the lymph from the left upper limb and left half of thoracoabdominal wall in the same way as that of right subclavian trunk.
3. **Left bronchomediastinal trunk** is similar to that of the right trunk but drains more of the heart and esophagus.
4. **Thoracic duct** begins in the abdomen as an upward continuation of cisterna chyli at the lower border of the 12th thoracic vertebra. It enters the thoracic inlet along the left border of the esophagus. In the neck, it arches laterally at the level of the transverse process of the 7th cervical vertebra.

Its arch rises 3 or 4 cm above the clavicle and curves anteriorly in front of the vertebral system (i.e., vertebral artery and vertebral vein) and left sympathetic trunk and behind the carotid system (i.e., left common carotid artery, left internal jugular vein and left vagus nerve). Finally, the duct descends in front of the arched (first part) subclavian artery and ends by opening into the junction of the left subclavian and internal jugular veins (Fig. 12.15).

Relations of the thoracic duct

The relations of the thoracic duct arch in the neck (Fig. 12.16) are as follows:

Anterior:

1. Left common carotid artery.
2. Left vagus nerve.
3. Left internal jugular vein.

Posterior:

1. Vertebral artery and vein.
2. Sympathetic trunk.
3. Thyrocervical trunk and its branches.
4. Prevertebral fascia.
5. Phrenic nerve.
6. Scalenus anterior muscle.

The thoracic duct is the longest and largest lymphatic trunk in the body. It drains the lymph from whole of the body except the right upper quadrant (for details see pages 166 and 167 of *General Anatomy* by Vishram Singh).

Tributaries in the neck

Apart from the tributaries in the thorax and abdomen, the thoracic duct receives the following tributaries in the neck:

1. Left jugular trunk.
2. Left subclavian trunk.
3. Left bronchomediastinal trunk.

RECURRENT LARYNGEAL NERVE

It runs on either side in the tracheo-esophageal groove.

TRACHEA AND ESOPHAGUS

The trachea extends from the lower border of the cricoid cartilage at the level of the lower border of C6 vertebra to the level of sternal angle at the level of lower border of T4. It can be palpated in the midline just above the jugular notch. This part of trachea is crossed by the isthmus of thyroid gland, inferior thyroid veins, the thyroidea ima artery (if present), and jugular venous arch.

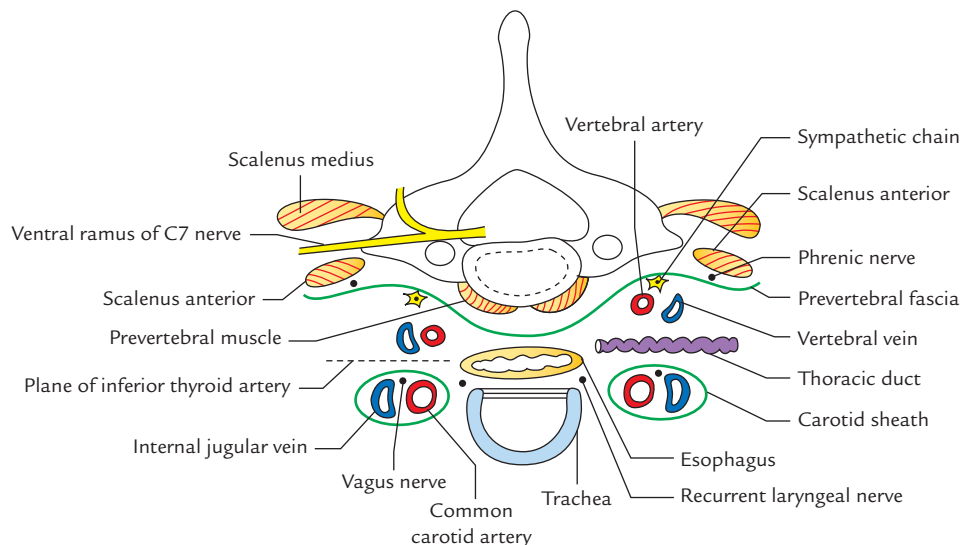


Fig. 12.16 Transverse section of the root of neck showing relationship of various structures in this region.

The esophagus begins in the neck just below the cricopharyngeus at the lower border of C6 vertebra. It lies on longus colli behind the trachea. The thoracic duct lies on its left lateral border before arching over the triangle of the vertebral artery on the left side (for details see chapter 10).

BRACHIOCEPHALIC VEINS

These veins collect blood from the head and neck, upper limbs, thoracic wall, and anterior abdominal wall. Each vein is formed by the union of corresponding internal jugular and subclavian veins behind the medial end of the clavicle. They end by joining to form superior vena cava behind the

lower border of the right first costal cartilage at the margin of the sternum.

The **right brachiocephalic vein** descends almost vertically. In the neck, it lies on the cervical pleura lateral to the brachiocephalic trunk. The phrenic nerve and internal thoracic artery lie posterior to it whereas anterior to it lie sternohyoid and sternothyroid muscles.

The **left brachiocephalic vein** runs obliquely to pass behind the upper part of the manubrium sterni to join the right brachiocephalic vein and is therefore much longer.

Both veins receive the vertebral, highest intercostal and inferior thyroid veins. The right lymphatic duct, right jugular trunk, and right subclavian trunk enter the right vein. The thoracic duct and left superior intercostal vein enter the left vein.

Golden Facts to Remember

- | | |
|---|---|
| ▶ Longest prevertebral muscle | Longus cervicis |
| ▶ Longest and largest scalene muscle | Scalenus medius |
| ▶ Scalenus medius arises from the transverse processes of all cervical vertebrae except | Transverse process of 1st cervical vertebra |
| ▶ Key muscle at the root of the neck | Scalenus anterior |
| ▶ Largest cervical sympathetic ganglion | Superior cervical sympathetic ganglion |
| ▶ Cervical rib | Enlarged costal element of transverse process of C7 vertebra |
| ▶ Root of the neck | Area of neck immediately above the thoracic inlet |
| ▶ Stellate ganglion | Cervicothoracic ganglion (p. 174) |
| ▶ Smallest prevertebral muscle | Scalenus posterior |
| ▶ Accessory phrenic nerve | A branch of nerve to subclavius containing C5 fibres, which join the main phrenic nerve |

Clinical Case Study



A 19-year-old dental student complained of pain, tingling, and numbness along the medial side of her right forearm and hand. She also had difficulty in gripping the instruments firmly by the right hand. The physical examination revealed weak right radial pulse. The examining physician suspected the presence of cervical rib and performed Adson's test, which turned out to be positive. The presence of cervical rib was confirmed by plain X-ray. She was diagnosed as a case of *scalene syndrome*. She completely recovered of her symptoms after the surgical removal of the cervical rib.

Questions

1. What is cervical rib?
2. What are the boundaries of scalene triangle?
3. Name the structures passing through scalene triangle.
4. Mention the cause of symptoms told by the patient.
5. What is Adson's test?
6. What precautions should be taken when cervical rib is removed surgically?

Answers

1. It is an enlarged costal element of the transverse process of the 7th cervical vertebra.
2. It is a narrow triangular space bounded anteriorly by scalenus anterior, posteriorly by scalenus medius and inferiorly by the upper surface of the first rib.
3. Subclavian artery and lower trunk of the brachial plexus.
4. Compression of lower trunk of brachial plexus (C8 and T1) and subclavian artery.
5. This test is performed to assess the functional status of the arterial supply of the upper limb. The patient sitting on a stool is asked to take a deep breath and at the same time turn his/her face towards the affected side. Now the physician can feel the radial pulse. If the radial pulse becomes feeble or absent the test is said to be positive.
6. The periosteum of the rib must be removed to prevent the regeneration of the rib.

Oral Cavity

The oral cavity (mouth) is the first part of digestive tube. It extends anteroposteriorly from lips to the oropharyngeal isthmus, commonly used for ingestion of food and fluids.

It is divided into two parts (Fig. 13.1), *viz.*

1. A smaller slit-like space between lips/cheeks and teeth/gingivae (gums) called **vestibule**.
2. A larger space inside the teeth and gums called **oral cavity proper**.

VESTIBULE OF THE MOUTH

The vestibule of the mouth is a narrow space that lies outside the teeth and gums, and inside the lips and cheeks. It is limited above and below by the reflection of mucus membrane from the lips and cheeks to the gums. When the mouth is open, it freely communicates with the oral cavity proper but when it is closed, i.e., when the teeth are occluded, it communicates on each side with the oral cavity proper through a small gap behind the third molar teeth and ramus of the mandible called **retromolar region**. Except teeth, the entire vestibule is lined by mucus membrane.

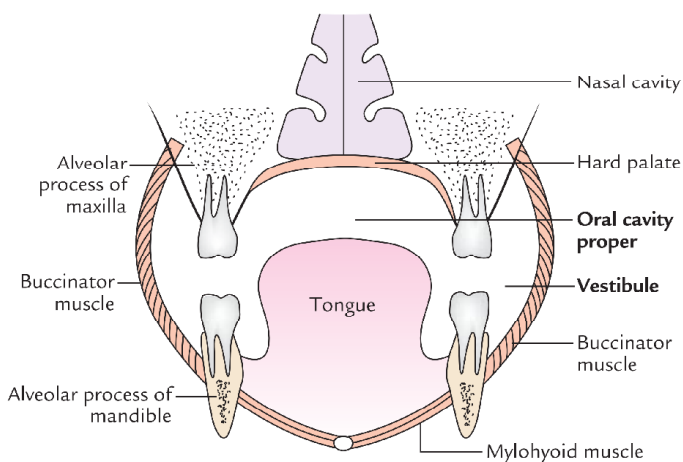


Fig. 13.1 Subdivisions of the oral cavity as seen in its coronal section.

The lateral wall of the vestibule is formed by cheek made up of buccinator muscle. The tone of buccinator muscle and muscles of lips keep the walls of the vestibule in contact with the teeth and gums. In facial palsy, due to paralysis of these muscles, the lips and cheeks fall away from the teeth and gums, and food tends to collect in the vestibule of the mouth.

The openings in the vestibule of the mouth are as follows:

1. Opening of parotid duct; the parotid duct opens into the vestibule opposite the crown of the upper second molar tooth.
2. Openings of labial and buccal mucus glands.
3. Openings of 4 or 5 molar glands (mucus) situated on the buccopharyngeal fascia.

LIPS

The lips are two mobile musculofibrous folds that surround the opening of the mouth. The upper and lower lips meet laterally at an angle of the mouth, usually in front of first premolar tooth.

The lips are lined externally by the skin and internally by the mucus membrane. The mucocutaneous junction lines the edge of the lip. Only a part of the mucosal surface is normally seen. The red portion of lip is called **vermillion zone**, the red hue is due to rich vascular bed visible through the thin moist epithelium. The skin and vermillion zone meet at the **vermillion border**. The internal aspect of each lip is connected to the corresponding gum by a median fold of the mucus membrane called **frenulum of the lip**.

Structure

From superficial to deep, the lip is composed of the following structures:

1. Skin.
2. Superficial fascia.
3. Orbicularis oris muscle.
4. Submucosa containing mucus glands.
5. Mucus membrane.

Blood Vessels

Each lip is supplied by labial branches of facial artery. Each lip has an **arterial arch** formed by the end-on anastomosis between labial branches of the facial arteries. When this arterial arch is cut, blood spurts from both ends with equal force. The veins correspond to the arteries and drain into the facial vein.

Lymphatics

The lymphatics from the central part of the lower lip drain into submental lymph nodes. The lymphatics from lateral parts of lower lip and whole of upper lip drain into submandibular lymph nodes.

Nerve Supply

The lips have rich sensory supply from trigeminal nerve. The upper lip is supplied by labial branches of the infraorbital nerve (a branch of maxillary division) and lower lip by the mental nerve (a branch of mandibular division of the trigeminal nerve). The red portions of lip are highly sensitive and represented by a large area in the sensory cortex of cerebral hemisphere.

CHEEKS

The cheeks are fleshy flaps forming a large part of the face. Each cheek is continuous in front with the lip. The junction between the two is marked by the **nasolabial sulcus** or the nasolabial furrow, which extends from the side of the nose to the angle of the mouth. Like the lips, the cheeks are lined externally by the skin and internally by the mucus membrane.

Structure

The cheek is largely composed of buccinator muscle. In addition, it contains buccal glands, blood vessels, and nerves. The buccinator muscle is covered by **buccopharyngeal fascia**. The buccal pad of fat is best developed in infants, overlies the buccopharyngeal fascia and extends posteriorly deep to masseter muscle.

Layers of the Cheek

From superficial to deep, the layers of the cheek are as follows:

1. Skin.
2. Superficial fascia containing some muscles of facial expression, *viz.* zygomaticus major, risorius.
3. Buccal pad of fat.
4. Buccopharyngeal fascia.
5. Buccinator muscle between the alveolar processes of both jaws.
6. Submucosa containing buccal (mucus) glands.
7. Mucus membrane.

The last five layers of the cheek are pierced by the parotid duct. The lymphatics from cheek drain into the submandibular and preauricular lymph nodes.

Mucus lining of the cheek

The inner aspect of the cheek is lined by stratified squamous epithelium. It is pierced by parotid duct opposite the maxillary upper molar tooth at a small **parotid papilla**.

A hyperkeratinized line (the *linea alba*) may be seen at a position related to the occlusal plane of the teeth.

Clinical correlation

In the retromolar region a fold of mucus membrane containing pterygomandibular raphe extends between the upper and lower alveoli. The entrance to the *pterygomandibular space*, which contains inferior alveolar and lingual nerves, lies lateral to pterygomandibular fold and medial to the ridge produced by site for injection of anesthetic agent in *inferior alveolar nerve block*.

GUMS (GINGIVA)

The gums are composed of fibrous tissue covered with a smooth vascular mucous membrane. They envelop the alveolar processes of the jaws and the necks of the teeth. At the necks of the teeth, the fibrous tissue of gum becomes continuous with the periodontal membrane, which attaches the teeth to their sockets.

Parts of Gum

The gum/gingiva has three parts, *viz.*

1. **Free part (free gingiva)**, which surrounds the neck of tooth like a collar.
2. **Attached part (attached gingiva)**, which is firmly attached to the alveolar process.
3. **Interdental part (interdental gingiva)**, which is the extension of the attached gingiva between the teeth.

Nerve Supply

Upper gums on:

- (a) the labial aspect are supplied by the posterior, middle, and anterior-superior alveolar nerves, and
- (b) the lingual aspect are supplied by the greater palatine and nasopalatine nerves.

Lower gums on:

- (a) the labial aspect are supplied by buccal branch of mandibular nerve, and incisive branch of mental nerve, and
- (b) the lingual aspect are supplied by the lingual nerves.

Lymphatic Drainage

Upper gums: The lymphatics from upper gums drain into submandibular lymph nodes.

Lower gums: The lymphatics from anterior part (i.e., gums of lower central incisors) drain into submental lymph nodes while those from remaining part drain into submandibular lymph nodes.

Clinical correlation

- **Gingivitis:** The improper oral hygiene may cause inflammation of gums (*gingivitis*) and suppuration with formation of pockets of pus between teeth and gums leading to clinical condition called *pyorrhoea*, which clinically present as: (a) discharge of pus at the margins of gums and (b) foul smell during breathing.
- **Scurvy:** In *scurvy* due to deficiency of vitamin C the gums become swollen, spongy, and bleed on touch.

TEETH

The teeth are mineralized bone-like structures projecting from the alveolar processes of the jaws.

Functions of Teeth

The functions of teeth are as follows:

1. Incise and grind the food material during mastication.
2. Perform (sometimes) the role of weapon for defense or attack.
3. Provide beauty to the face and means for facial expression.

N.B. The study of teeth, strictly speaking, forms the subject of *odontology* whereas the science concerned with the diagnosis and treatment of diseases of the teeth and associated structures is called *dentistry* (L. *dens*, *dentis* = tooth).

Number of Teeth

In an adult there are 16 permanent teeth in each jaw.

The humans are **diphyodont**, i.e., two sets of teeth develop in a person's lifetime. The first set of teeth is **primary or deciduous teeth**. They begin to form prenatally about 14 weeks in intrauterine life and completed postnatally at about 3 years of age. The deciduous teeth remain intact up to about 6 years of age. At about that time the **permanent teeth** begin to erupt in the mouth.

The first of milk teeth (lower central incisors) erupt approximately 6 months after birth and the last (second milk molars) at approximately 2 years. The first permanent tooth (first molar) erupts at approximately 6 years and continues until about 17 years of age. The wisdom teeth are less predictable and if they do erupt, it is between the ages 17 and 25. Because jaws are formed by this time and other

teeth have already well-occupied their place, the eruption of wisdom teeth may fail to occur properly causing a clinical condition called **impaction of tooth**.

Eruption of Teeth

Most of the teeth in an adult are **successional**, i.e., they have succeeded a corresponding number of milk teeth. The permanent molars, however, are **accessional**, as they have been added later on and have no corresponding milk teeth.

Eruption of Deciduous Teeth (Fig. 13.2A)

The deciduous teeth begin to erupt at **about 6 months** and all are erupted by the end of 2nd year (or soon after).

The teeth of lower jaw erupt somewhat before the corresponding teeth in the upper jaw.

The approximate **age of eruption** of deciduous teeth is as follows (Fig. 13.2A):

- Lower central incisors: 6 months
- Upper central incisors: 7 months
- Lateral incisors: 8–9 months
- First molar: 12 months (1 year)
- Canines: 18 months (1 year 6 months)
- Second molars: 24 months (2 years)

Eruption of Permanent Teeth (Fig. 13.2B)

The permanent teeth begin to erupt at about 6 years and all get erupted by 18–24 years. The approximate age of eruption of permanent teeth is as follows:

- First molar: 6 years
- Medial incisors: 7 years
- Lateral incisors: 8 years
- First premolar: 9 years
- Second premolar: 10 years
- Canines: 11 years
- Second molars: 12 years
- Third molar (Wisdom tooth): 18–24 years

Clinical correlation

Eruption of teeth: The time of eruption of the teeth is a useful stepping stone in a child's development. The time of eruption is also important in forensic medicine to estimate the age at the time of death from the skeletonized remains as a rough guide. The time of eruption of teeth can be thought of in '6' or multiples of '6' as follows:

- 1st lower deciduous incisor appears at: 6 months.
- All the deciduous teeth complete eruption by: 24 months.
- Permanent 1st molar appears at: 6 years.
- Permanent 1st incisor appears at: 6 years.
- Permanent 2nd molar appears at: 12 years.
- Permanent 3rd molar appears at: 18–24 years.

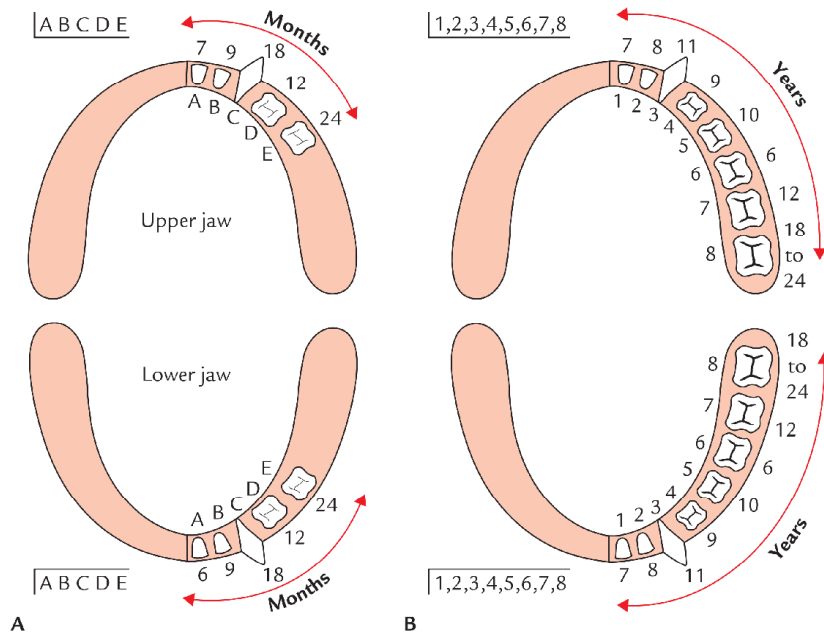


Fig. 13.2 Schematic diagram showing approximate age of eruption of teeth: A, deciduous teeth; B, permanent teeth. The teeth are numbered according to Zsigmondy system.

Parts of a Tooth (Fig. 13.3)

Each tooth consists of the following three parts:

1. A **crown**, the *anatomical crown* is the part of a tooth that is covered by enamel, whereas *clinical crown* is the part that projects into the oral cavity.
2. A **root**, which is embedded within the socket of jaw beneath the gum.
3. A **neck**, which is the constricted part of the tooth between the crown and root. It is encircled by the gum.

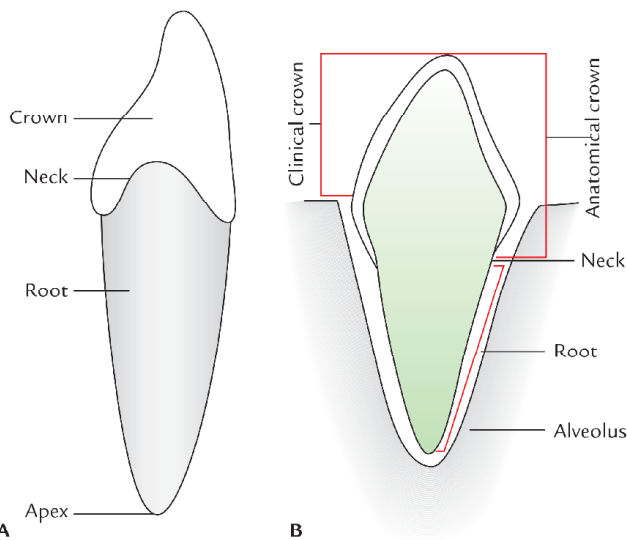


Fig. 13.3 Parts of the tooth: A, extracted upper right canine tooth; B, showing clinical and anatomical crowns.

Structure of Tooth (Fig. 13.4)

Each tooth is composed of a specialized connective tissue. It essentially consists of a pulp covered by three calcified tissues: dentine, enamel, and cementum.

1. **Pulp:** It is the **inner core** containing soft tissue, blood vessels, nerve, and lymphatics. The pulp is covered by a

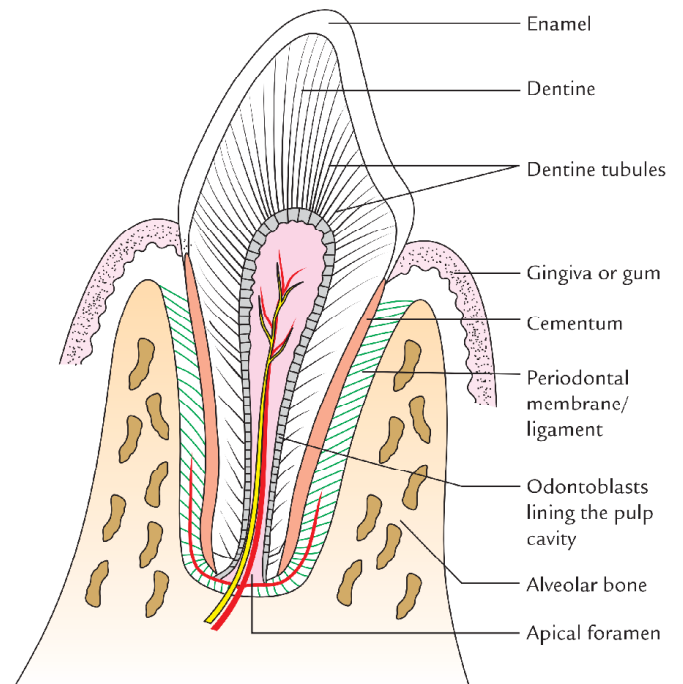


Fig. 13.4 Structure of the tooth.

layer of tall columnar cells called **odontoblasts**. The space occupying the pulp is called **pulp cavity**.

- Dentine:** It is a **calcified material** surrounding the pulp cavity. It forms the basis of the tooth and contains **spiral tubules** radiating from the pulp cavity. Each tubule is occupied by a protoplasmic process from the odontoblast. In dentine the **calcium** and **organic matter** are in same proportion as the bone.
- Enamel:** It is the **densely calcified white material** covering the crown of the tooth. It is the **hardest** substance in the body and is made up of **crystalline prisms**. The prisms lie at right angle to the surface of the tooth.
- Cement:** It is the **bony covering** over the neck and root of the tooth. It commonly overlaps the lower part of the enamel.
- Periodontal membrane:** It is present between the cementum and the socket, both of which act as periosteum. It holds the tooth in the socket and therefore, often termed **periodontal ligament**.

Clinical correlation

- Medicolegal importance of teeth:** The tooth is the hardest and chemically most stable tissue in the body. Hence, they are presented or fossilized after death for medicolegal purpose to identify the unrecognizable dead bodies.
- The gradual decalcification and destruction of enamel and dentine leads to *dental caries*.
- Eye tooth:** The upper canine tooth is often referred to as *eye tooth* because sometimes its long root may extend up to the medial angle of the eye. The infection from its root may reach the facial vein, which may lead to *cavernous sinus thrombosis*.

Nerve Supply (Fig. 13.5)

The **upper teeth** are supplied by the **posterior, middle, and anterior-superior alveolar nerves**, which form a plexus above the apices of the teeth, called *superior dental plexus*.

The **lower teeth** are supplied by the **inferior alveolar (dental) nerve**. The molars and premolars are supplied by the main trunk while canine and incisors by its incisive branch.

Clinical correlation

Dental anesthesia: It is required to carry out various dental procedures.

- Anesthesia of upper teeth:** Alveolar bone of the maxilla is relatively porous, hence anesthetic solution deposited in the gingivae opposite a root of tooth will readily penetrate the bone to anesthetize the tooth to carry out dental procedures.

Infiltration on buccal aspect is sufficient for painless drilling of the tooth but for extraction of tooth the palatal aspect must be infiltrated as well.

- Anesthesia of lower teeth:** The infiltration anesthesia is usually effective for the incisor teeth only. The infiltration anesthesia does not work for other mandibular teeth because they are embedded in the bone, which is dense, hence does not allow the sufficient penetration of anesthetic agent. Therefore, for those teeth the *inferior alveolar nerve block* is required.

Arterial Supply

The **upper teeth** are supplied by **posterior, middle, and anterior-superior alveolar arteries** which are branches of the maxillary artery.

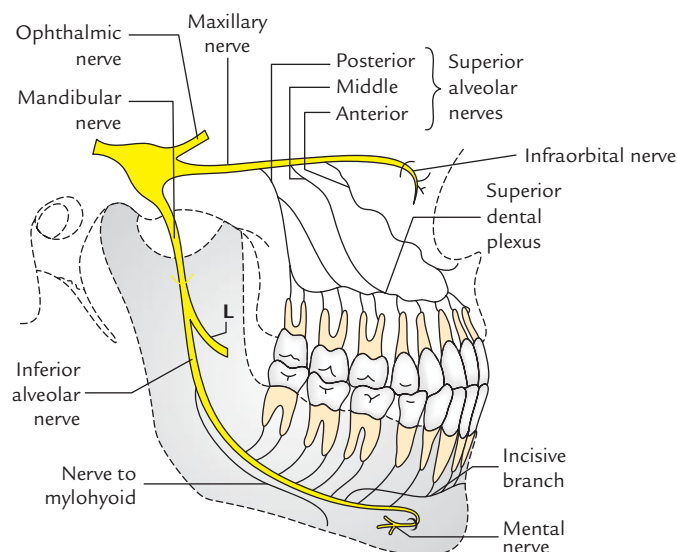


Fig. 13.5 Nerve supply of the teeth (L = lingual nerve).

The lower teeth are supplied by the inferior alveolar (dental) artery, a branch of first part of maxillary artery.

N.B.

- The blood vessels and nerves enter the pulp cavity of the tooth through the apical foramen.
- The pulp and periodontal membrane have the same nerve supply but is different from that of the overlying gum.

Lymphatic Drainage

The lymph from teeth is usually drained into ipsilateral submandibular lymph nodes. Lymph from the mandibular incisors, however, drains into submental lymph nodes.

Clinical correlation

Sometimes the extraction of tooth may lead to osteomyelitis (inflammation of the bone) of the jaw. It usually occurs in the lower jaw and not in the upper jaw. This is because the lower jaw is supplied only by a single inferior alveolar artery. Therefore, damage of this artery at extraction produces bone necrosis.

The upper jaw on the other hand receives segmental supply by three arteries: posterior, middle, and anterior-superior alveolar arteries. Therefore, ischemia does not occur following injury to an individual artery.

Types of Teeth (Fig. 13.6)

The human beings have heterodont dentition, i.e., the teeth vary structurally and are adapted to handle food in different ways. The teeth are, therefore, classified as: incisors, canines, premolars, and molars.

Incisors

They are four in each jaw, two on each side of the median plane. They are arranged in two groups: two medial incisors and two lateral incisors.

The four upper incisors are carried by the premaxillary portion of the maxilla. As the name suggests, the incisors cut the food by their cutting edges. They are chisel like. The upper and lower incisors do not meet edge to edge but by a sliding overlap like the blades of a pair of scissors.

Canines

There are two canines on each jaw, one on each side, lateral to the incisors. They are so named because they are prominent in dogs (carnivorous animals). The canines are holding and tearing teeth with conical and rugged crowns. They are sometimes referred to as cuspids (or eye-teeth). They are long teeth and usually the last deciduous teeth to be lost.

Premolars

There are four premolars in each jaw, two on each side. The premolars assist in crushing the food. They have two cusps and are therefore also called bicuspid teeth.

Molars

There are six molars (L. *molar* (*es*) *m* = grinders) in each jaw, three on each side. They crush and grind the food. They possess 3–5 tubercles, i.e., cusps on their crowns. Usually the upper molars have four and lower molars have five cusps on their crown.

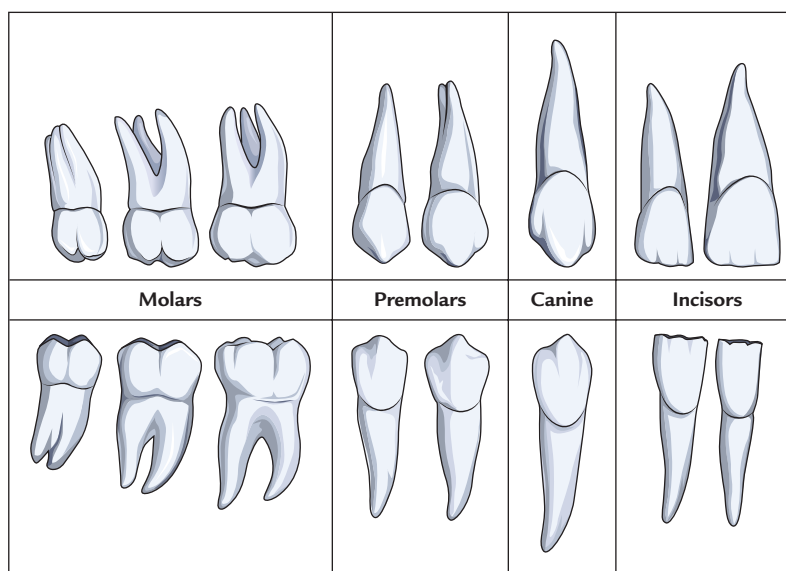


Fig. 13.6 Types of the permanent teeth (upper and lower teeth of the right side).

Table 13.1 Number of roots in all types of teeth

Teeth	Number of roots
• Upper molars	3 roots each (2 lateral and 1 medial)
• Lower molars	2 roots each (1 anterior and 1 posterior)
All other teeth except first upper premolar*	1 root

*First upper premolar usually has a bifid root.

N.B.

- The first premolars are usually the largest teeth.
- The third molar is often known as the *wisdom tooth*. Nowadays, they may be lacking or impacted.
- The permanent molars have no deciduous predecessors.

Number of Roots in Different Types of Teeth

The different types of teeth and number of their roots are enumerated in Table 13.1.

Clinical correlation

The teeth can be distinguished from one another by the characteristics of their roots and crowns.

Dental Formula

A dental formula is a graphic representation of the types, number and position of teeth in the oral cavity. The humans being heterodont, the dental formulae for deciduous and permanent teeth are as follows:

Dental formula for deciduous teeth

$$\frac{I\ 2/2, C\ 1/1, M\ 2/2}{I\ 2/2, C\ 1/1, M\ 2/2} = 20\ \text{teeth}$$

Dental formula for permanent teeth

$$\frac{I\ 2/2, C\ 1/1, P\ 2/2, M\ 3/3}{I\ 2/2, C\ 1/1, P\ 2/2, M\ 3/3} = 32\ \text{teeth}$$

I = Incisor, C = Canine, P = Premolar, M = Molar

Clinical Notation System (Fig. 13.2)

In clinical practice, the dental doctors follow a definite system to note the various teeth. There are many systems. As an example, one of the systems called *Zsigmondy numbering system* is given as follows. For details of other system consult dental anatomy books.

Permanent teeth

They are identified by assigning a numbers from 1 to 8 from anterior to posterior in each quadrant, *viz.* central incisor = 1, lateral incisor = 2, canine = 3, first premolar = 4, second premolar = 5, First molar = 6, Second molar = 7, and third molar = 8 (Fig. 13.7).

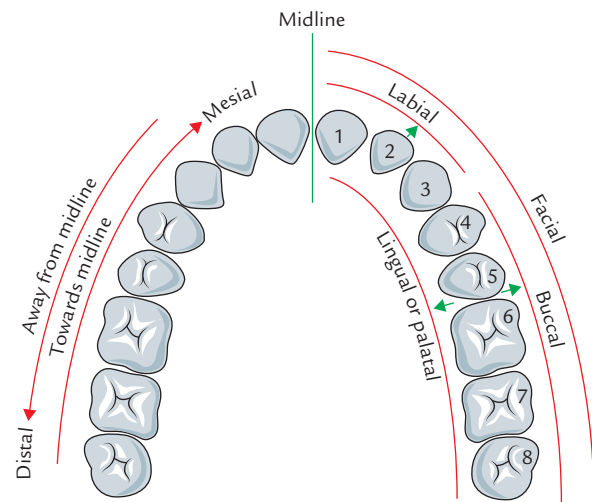


Fig. 13.7 Dental terminology used for surfaces: 1 = central incisor; 2 = lateral incisor; 3 = canine; 4 = first premolar; 5 = second premolar; 6 = first molar; 7 = second molar; 8 = third molar.

The quadrant symbols are as follows:

Maxillary right = \lrcorner
 Maxillary left = \llcorner
 Mandibular right = \lrcorner
 Mandibular left = \llcorner

The complete set of permanent teeth in all quadrants is noted as follows:

Maxillary right quadrant	Maxillary left quadrant
8 7 6 5 4 3 2 1	1 2 3 4 5 6 7 8
8 7 6 5 4 3 2 1	1 2 3 4 5 6 7 8
Mandibular right quadrant	Mandibular left quadrant

Deciduous (primary) teeth

They are identified by assigning letters from A to E, from anterior to posterior in each quadrant, *viz.* central incisor = A, lateral incisor = B, canine = C, first molar = D, and second molar = E.

The complete set of deciduous teeth is noted as follows:

Maxillary right quadrant	Maxillary left quadrant
E D C B A	A B C D E
E D C B A	A B C D E
Mandibular right quadrant	Mandibular left quadrant

Variations in the Number of Teeth

The variation in number of teeth is rare in deciduous teeth but not uncommon in permanent teeth. One or more teeth may fail to develop, the condition is called **hypodontia**. Conversely additional or supernumerary teeth may develop producing a condition called **hyperdontia**.

N.B. The third permanent molar is the most frequently missing tooth in most of the races.

Dental Terminology

Special Terms Used to Describe the Surfaces of Teeth (Fig. 13.6)

The surfaces named according to their position:

- For incisors and canines, the surfaces towards the lips are called **labial surfaces**.
- For premolars and molars, the surfaces towards the cheek are called **buccal surfaces**.

N.B.

- All labial and buccal surfaces are collectively called *facial surfaces*.
- The surfaces of upper jaw teeth facing palate are called *palatal surfaces*.
- The surfaces of lower jaw teeth facing tongue are called *lingual surfaces*.
- The surfaces of all the teeth towards the midline are called *medial surfaces*.
- The surfaces of all teeth away from the midline are called *distal surfaces*.

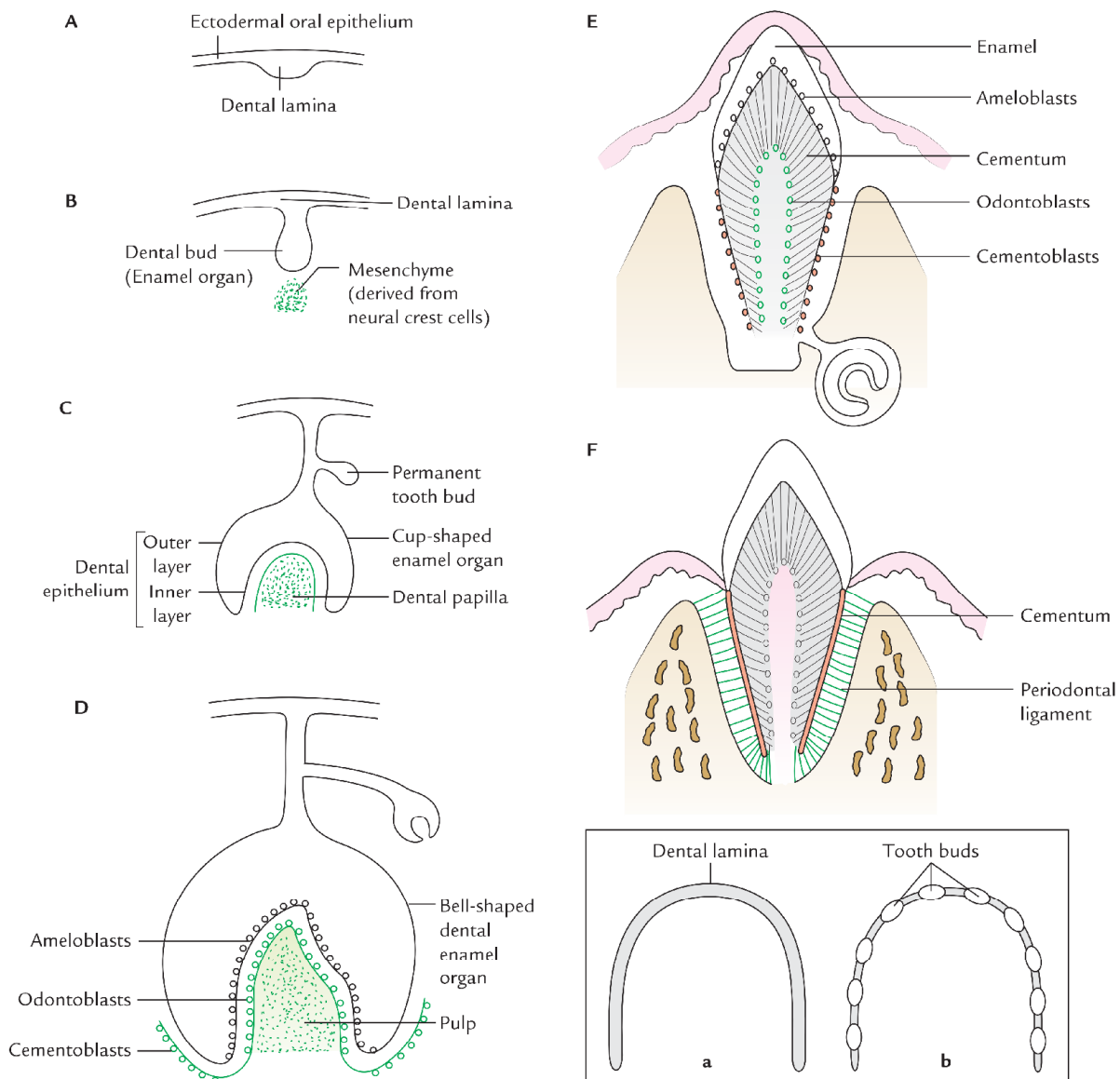


Fig. 13.8 Stages in the development of teeth: A, formation of dental lamina; B, development of tooth bud (enamel organ); C, cap-stage; D, bell-stage; E, early tooth eruption; F, fully erupted deciduous tooth. The figures in the inset show formation of dental lamina (a) and tooth buds of all deciduous teeth (b).

- The surfaces of incisors and canines that come in contact for cutting are called *incisive surfaces*.
- The surfaces of premolars and molars that come in contact for grinding and crushing are called *occlusal surfaces*.

Terms Used to Describe the Ridges of Teeth

Their description is beyond the scope of this book. (For details consult dental anatomy book.)

The central and lateral incisors and canines as a group are called **anterior teeth** whereas premolars and molars as a group are called **posterior teeth**.

Development of the Teeth (Fig. 13.8)

The teeth develop from **ectoderm** and an underlying layer of **neural crest cells**.

The broad stages in the development of teeth are as follows:

1. The oral epithelium (ectoderm) along the alveolar process thickens to form the **dental lamina**, which proliferates at various sites to form down growths called **tooth buds** (*enamel organs*).
2. The **enamel organs** develop first for 20 deciduous teeth and then for permanent teeth. They give rise to **ameloblasts**, which produce enamel.
3. The underlying neural crest cells proliferate to form **dental papilla**, which is covered by the bottom of enamel organ like a cap. This stage of development is called **cap-stage**. The dental papilla gives rise to the **odontoblasts**, which produce dentine and pulp.
4. As the dental papilla further grows, it invaginates the enamel organ. The surface layers of dental papilla condense to form **dental sac**, which surrounds the enamel organ. This stage of development is called **bell stage**. The dental sac gives rise to **cementoblasts** (which produce cementum) and **periodontal ligaments**. The rest of the neural crest cells form the **pulp of the tooth**.

Thus the tissues of tooth are derived from two embryological sources. These are summarized in Table 13.2.

Clinical correlation

The irregular dentition is common in children suffering from rickets and often associated with notching of upper permanent incisors.

Table 13.2 Origin of various tissues of tooth

Ectoderm	Neural crest cells
Enamel	<ul style="list-style-type: none"> • Dentine • Dental pulp • Cementum • Periodontal ligaments

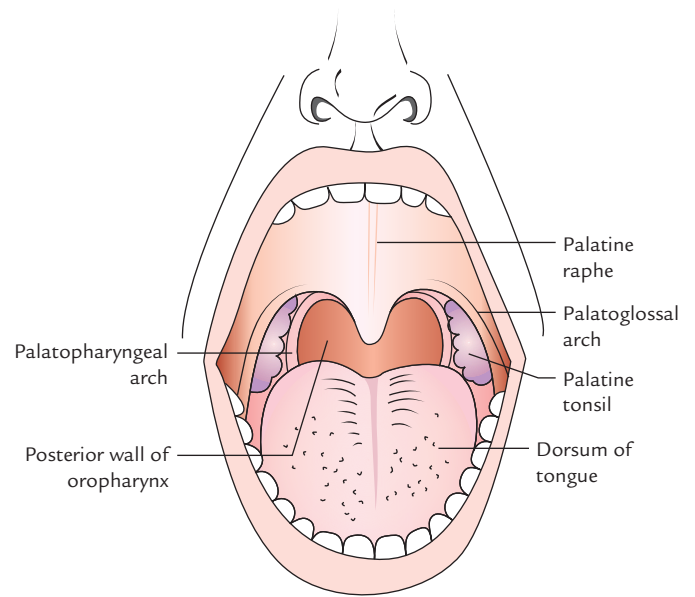


Fig. 13.9 The fauces and its isthmus seen through the widely open mouth.

ORAL CAVITY PROPER

BOUNDARIES

The oral cavity proper has a roof and a floor. Posteriorly the oral cavity communicates with the oropharynx through **oropharyngeal isthmus** (also called *isthmus of fauces*), which is bounded superiorly by the soft palate, inferiorly by the tongue and on each side by the palatoglossal arches. The approximation of these arches shuts off the mouth from oropharynx and is essential to deglutition (Fig. 13.9).

FLOOR OF THE MOUTH

The floor of the mouth is a small horseshoe-shaped region situated beneath the anterior two-third of the tongue and above the muscular diaphragm formed by **two mylohyoid muscles**. The surface of the floor is formed by mucus membrane, which connects the tongue to the mandible. Laterally the mucus membrane passes from the side of the tongue onto the mandible.

Anteriorly the mucus membrane stretches from one half of the mandible to the other. The anterior part of the floor is called **sublingual region**, which intervenes between the ventral surface of the anterior two-third of the tongue and the floor of the mouth.

The sublingual region presents following features (Fig. 13.10):

1. The lower surface of the tongue is connected to the floor of the mouth by a median fold of the mucus membrane called **frenulum linguae**.

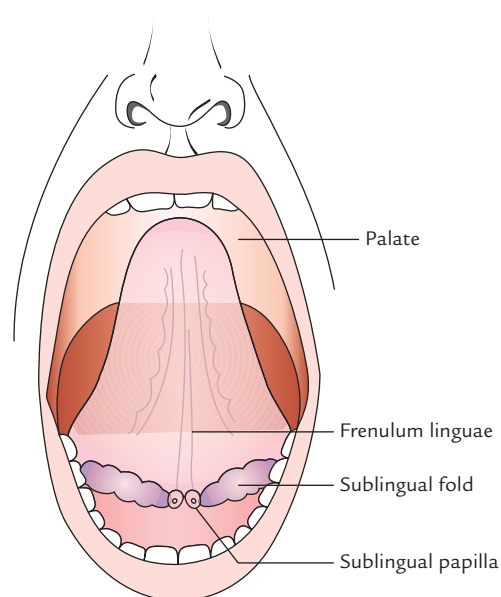


Fig. 13.10 Sublingual region seen when the tongue is turned upwards. Features on inferior surface of the tongue also seen.

- On each side of the lower end of frenulum, there is an elevation called **sublingual papilla**, on the summit of which opens the submandibular duct.
- The sublingual gland projects up into the floor of the mouth and produces an elevation in the mucus membrane on each side of the frenulum called **sublingual fold**. Most of the sublingual ducts open on this fold.

Many structures in the oral cavity are termed by their relationship to the tongue, palate, cheeks, and lips (Fig. 13.10). The structures closest to the tongue are termed **lingual**, those closest to palate **palatal**, those closest to cheeks **buccal**, and those closest to lips **labial**.

Clinical correlation

Ludwig's angina is a cellulitis of the floor of the mouth, usually due to infection from a carious molar tooth, causing inflammatory edema of the floor of the mouth. It spreads to the submandibular and submental regions producing diffuse swelling in these regions also. The tongue is pushed upwards due to edema of the floor of the mouth, resulting in difficulty in swallowing.

ROOF OF THE MOUTH

The roof of the mouth is formed by palate. The anterior two-third of palate, made up of bones is called **hard palate**, while posterior one-third made of soft issue is called **soft palate**. From the posterior-free margin of the soft palate a small conical projection called **uvula** hangs down in the median region. A poorly marked median raphe extends

from uvula to the **incisive papilla**—a slight elevation behind the incisive fossa.

The mucus membrane in the anterior part of the hard plate is thrown into 3 or 4 **transverse palatine folds** but posteriorly it is comparatively smooth. The palate is described in detail with pharynx in Chapter 14.

TONGUE

The tongue is a mobile muscular organ in the oral cavity, which bulges upwards from the floor of the mouth and its posterior part forms the anterior wall of the oropharynx.

It is essentially a mass of skeletal muscle covered by mucus membrane. The muscle mass is separated into right and left halves by a midline fibrous septum. The tongue is separated from teeth by a deep **alveololingual sulcus**, which is filled in by palatoglossal fold/arch posterior to the last molar tooth.

Functions

The tongue performs the following functions:

- Taste.
- Speech.
- Mastication.
- Deglutition.

Shape

The tongue is conical in shape being elongated postero-anteriorly and flattened dorsoventrally.

External Features

The tongue exhibits the following external features:

- A root.
- A tip.
- A body.

Root

The root of the tongue is attached to the mandible and hyoid bone by muscles. It is because of these attachments that the tongue is not swallowed during deglutition. The nerve and vessels of the tongue enter through its root.

Tip

It is the anterior free end of the tongue, which comes into contact with the central incisors.

Body

The bulk of tongue between the root and tip is called *body*. It has dorsal and ventral surfaces and right and left lateral margins.

Dorsal surface (Fig. 13.11)

The dorsal surface is convex on all the sides. It is divided by a V-shaped sulcus, the **sulcus terminalis** into two parts, *viz.*

- Anterior two-third or **oral part**.
- Posterior one-third or **pharyngeal part**.

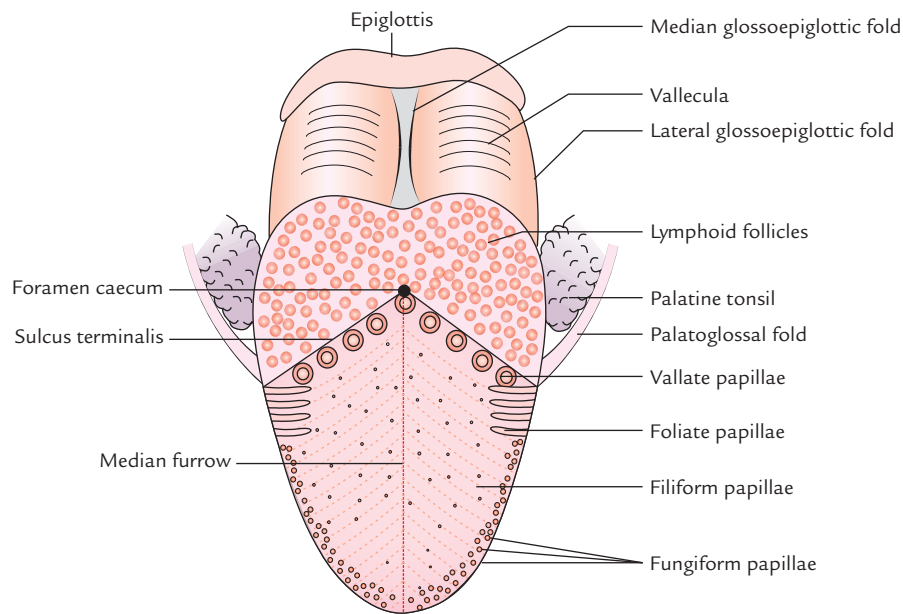


Fig. 13.11 Features on the dorsal surface of the tongue.

The apex of the sulcus terminalis is marked by a blind foramen, the **foramen caecum**, which indicates the point of origin of the median thyroid diverticulum (thyroglossal duct) in the embryonic life.

The features differ markedly in the oral and pharyngeal parts.

The **oral part** presents the following features:

1. A median furrow, representing the bilateral origin of the tongue.
2. Large number of papillae.

The **pharyngeal part** presents the following features:

1. A large number of lymphoid follicles, which together constitute the **lingual tonsil**.
2. A large number of mucus and serous glands.

N.B. The oral and pharyngeal parts of the tongue are different in their embryological origin for mucosa of oral two-third develops from the 1st and 2nd pharyngeal arches while that of pharyngeal part develops from the 3rd or 4th pharyngeal arches.

Oral part: The dorsum of oral part presents a shallow median furrow/groove. The mucus membrane is moist and pink and appears velvety due to the presence of numerous papillae.

Clinical correlation

The furring or coating of tongue bears no relation to digestive disturbances as generally thought, but is usually due to smoking, respiratory tract infection, fever, or oral infection.

Papillae of the tongue (Lingual papillae): They are projections of lamina propria (corium) of mucus membrane covered with epithelium (Figs 13.11 and 13.12). The following four chief types of papillae are found:

1. **Vallate papillae:** The vallate papillae (known formerly as *circumvallate papillae*) are largest (1–2 mm in diameter) and vary in number from 8–12 and are arranged in a V-shaped row in front of **sulcus terminalis**. Each papilla is like a truncated cone surrounded by a circular sulcus, which is bounded on its periphery by a wall or **vallum**. The duct of serous glands open into the sulcus (moat) and taste buds are found in the papilla and its vallum.

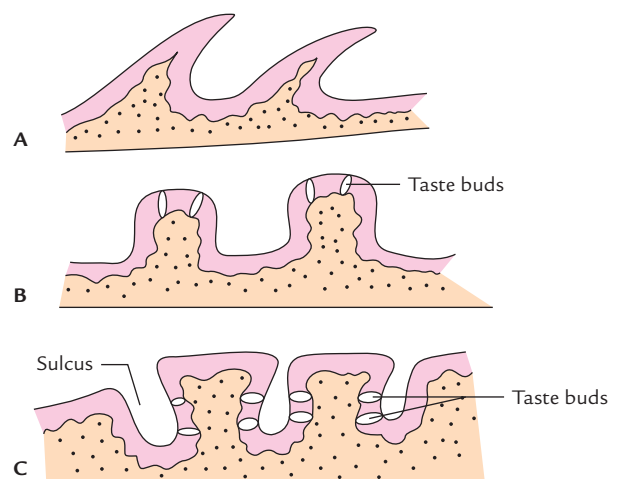


Fig. 13.12 Characteristic features of different types of lingual papillae: A, filiform; B, fungiform; C, vallate.

2. **Filiform papillae:** These are narrowest and most numerous. They are minute conical projections with sharply pointed tips. Filiform papillae are located abundantly on the dorsum of tongue and are largely responsible for its velvety appearance.
3. **Fungiform papillae:** They have a red rounded head (about 1 mm in diameter) and a narrower base, mostly at the apex and margins of the tongue, while some are scattered over the dorsum of the tongue. They are visible as discrete pink pinheads.
4. **Foliate papillae:** They consist of inconstant vertical grooves and ridges near the margin in front of sulcus terminalis. Foliate papillae are more prominent in the tongue of rabbits. They are rudimentary in humans.

N.B. Another type of papillae, called *papillae simplex*, are known. These are surface projections and can be seen only under the microscope.

Pharyngeal part: The dorsum of pharyngeal part faces posteriorly and forms the base of tongue.

The base of tongue constitutes the anterior wall of the oropharynx and can be inspected only by the use of a mirror or by a downward pressure on the tongue with a tongue spatula.

The mucus membrane over the dorsum of pharyngeal part is devoid of papillae. It, however, appears uneven due to the presence of numerous lymphatic follicles in the underlying submucosa. These follicles are collectively termed **lingual tonsil**.

The mucus membrane in this part is continuous with mucus membrane covering the palatine tonsils and the pharynx. Posteriorly, it is reflected onto the front of the epiglottis as the median **glossoepiglottic fold** and onto the lateral wall of pharynx as **lateral glossoepiglottic folds**. The space on each side of the median glossoepiglottic fold is termed **epiglottic vallecula**.

Ventral (inferior) surface of the tongue (Fig. 13.13)

The inferior surface of tongue is situated in the oral cavity only. The mucus membrane lining this surface is thin, smooth, and purplish. It is reflected onto the floor of the mouth. The under aspect of the tongue presents the following features:

1. **Frenulum linguae**, a median-fold of mucus membrane connecting the tongue to the floor of the mouth.
2. **Deep lingual veins**, may be seen through mucous membrane on either side of frenulum linguae (the lingual nerve and lingual artery are medial to the vein but not visible).
3. **Plica fimbriata**, a fringed fimbriated fold of mucous membrane lateral to the lingual vein directed forwards and medially towards the tip of the tongue.

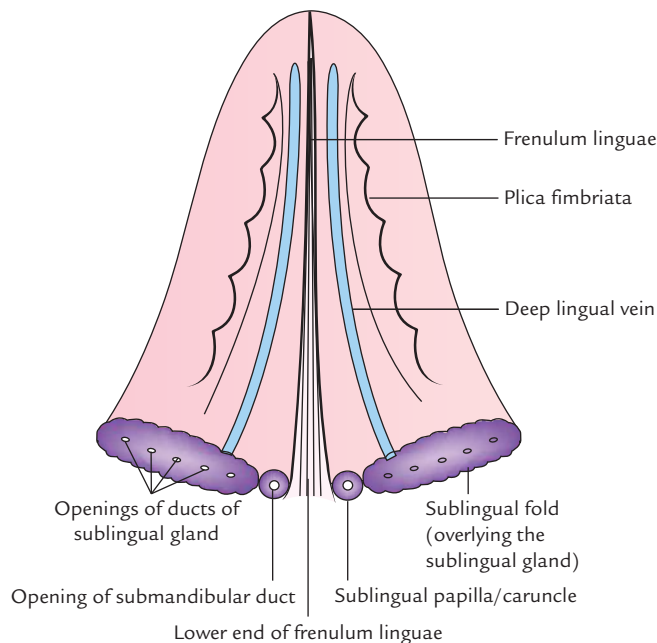


Fig. 13.13 Features on the ventral (inferior) surface of the tongue and floor of the mouth.

Clinical correlation

- **Tongue tie:** If frenulum extends too far towards the tip of the tongue, it is called *tongue tie*. It inhibits normal movements of the tongue and may interfere with normal speech. This can be corrected by cutting the frenulum surgically.
- Certain drugs, which are lipid soluble can diffuse through the thin mucous membrane lining the sublingual region of oral cavity and can be quickly absorbed into the circulation. A leading example is nitroglycerin (Sorbitrate), a vasodilator used in cases of *angina pectoris*. The drug (tablet) is placed under the tongue, where in less than 1 minute, it dissolves and passes through the thin oral mucosa into the lingual veins.
- **Carcinoma of the tongue:** The tongue is a common site of carcinoma. It mostly involves lateral margins of anterior two-thirds of the tongue. The relative frequency of various sites of involvement is as follows:
 - *Anterior two-thirds:* 64% (lateral margin, 47%; ventral surface and frenulum linguae, 9%; dorsum, 6.5%; tip, 11.5%)
 - *Posterior one-third:* 20%
 - *Posteriormost (faciolingual) part:* 6%

Muscles of the Tongue

The musculature of tongue consists of extrinsic and intrinsic muscles. The intrinsic muscles are within the tongue and have no attachment outside the tongue whereas extrinsic muscles take origin from structures outside the tongue and enter the

tongue to be inserted in it. The intrinsic muscles change the shape of tongue whereas extrinsic muscles move the tongue (such as protrusion, retraction and side-to-side movements) as well as alter its shape.

The tongue is divided into symmetrical right and left halves by a medial fibrous septum, which separates the muscles of two sides. Each half of the tongue contains four intrinsic and four extrinsic muscles. These are as follows:

Intrinsic muscles

1. Superior longitudinal.
2. Inferior longitudinal.
3. Transverse.
4. Vertical.

Extrinsic muscles

1. Genioglossus.
2. Hyoglossus.
3. Styloglossus.
4. Palatoglossus.

Intrinsic muscles (Fig. 13.14): They are confined to the tongue and are not attached to the bone. They occupy the upper part of the tongue and alter its shape. The intrinsic muscles are arranged in several planes. They run in three directions: longitudinal, horizontal, and vertical. The complex interlacing of fibres of these muscles is responsible for the astonishing way in which the tongue can change its shape, becoming wide and flat, narrow and thick, or rolled up laterally to become gutter shaped. The latter shape cannot be achieved by a small number of people and this inability is genetically determined. Intrinsic muscles occupy the upper part of the tongue and are attached to the submucous fibrous layer and to the median fibrous

Table 13.3 Features of the intrinsic muscles

Intrinsic muscle	Location	Actions
Superior longitudinal	Beneath the mucous membrane	<ul style="list-style-type: none"> • Shortens the tongue • Makes the dorsum concave
Inferior longitudinal	Close to inferior surface between genioglossus and hyoglossus	<ul style="list-style-type: none"> • Shortens the tongue • Makes the dorsum convex
Transverse	Extends from median septum to the margin	Makes the tongue narrow and elongated
Vertical	At the border of the anterior part of the tongue	Makes the tongue broad and flattened

septum. Their location and actions are enumerated in the Table 13.3.

Extrinsic muscles (Fig. 13.15): They attach the tongue to the mandible (genioglossus), the hyoid (hyoglossus), the styloid process (styloglossus), and the palate (palatoglossus) on each side. They are described in detail in submandibular region (Chapter 9). The summary of their origin, insertion, and actions is presented in Table 13.4.

Movements of the Tongue (Fig. 13.16)

The movements of tongue and muscles producing them are listed in Table 13.5.

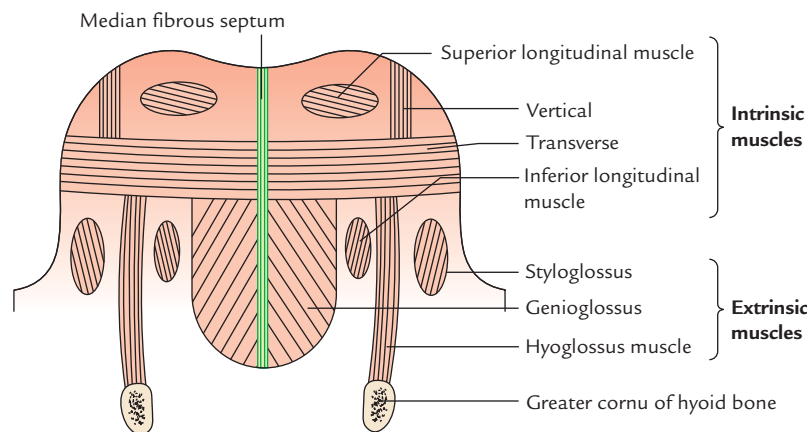


Fig. 13.14 Coronal section of the tongue showing arrangement of intrinsic and extrinsic muscles of the tongue.

Table 13.4 Origin, insertion, and actions of the extrinsic muscles of the tongue

Muscle	Origin	Insertion	Actions
Genioglossus (a fan-shaped muscle)	Superior genial tubercle	<ul style="list-style-type: none"> Whole of the tongue (fibres radiate from the tip to the base) Hyoid bone (lowest fibres) 	Protrudes the tongue when acting together with its counterpart of opposite side
Hyoglossus (a flat quadrilateral muscle)	Greater cornu and adjacent part of the body of hyoid	Side of tongue (posterior half) between styloglossus laterally and inferior longitudinal muscle medially	<ul style="list-style-type: none"> Depresses the sides of the tongue Makes the dorsal surface convex
Styloglossus (an elongated slip)	Tip of styloid process and adjacent part of the stylohyoid ligament	Side of tongue (whole length), interdigitating posteriorly with the fibres of hyoglossus	Draws the side of the tongue upwards and backwards
Palatoglossus (a slender slip)	Oral surface of palatine aponeurosis of palate	Side of tongue (at the junction of its oral and pharyngeal parts)	<ul style="list-style-type: none"> Pulls up the root of the tongue Approximates palatoglossal arches

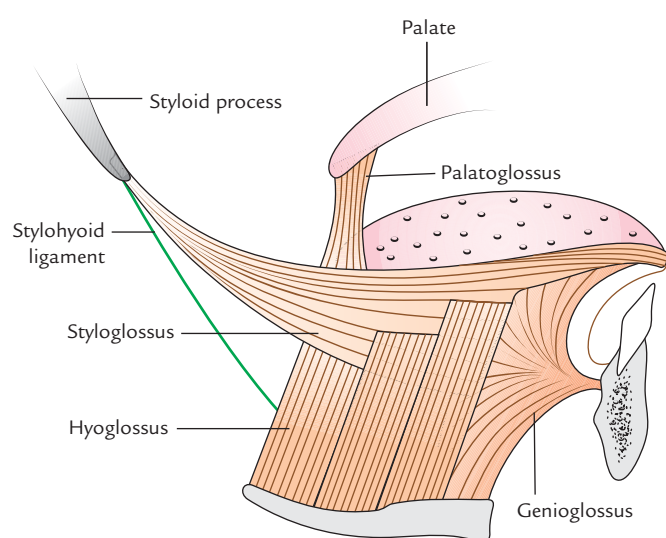


Fig. 13.15 Extrinsic muscles of the tongue.

Table 13.5 Movements of the tongue and muscles producing them

Movements of tongue	Muscles
Protrusion (most important movement)	Genioglossus muscles (of both side acting together)
Retraction	Styloglossus muscles (of both sides acting together)
Depression	Hyoglossus muscles (of both sides acting together)
Elevation (of posterior one-third)	Palatoglossus muscles (of both sides acting together)
Changes in shape	Intrinsic muscles

Clinical correlation

- **Safety muscle of tongue:** The genioglossus is called *safety muscle of the tongue*, because two genioglossi

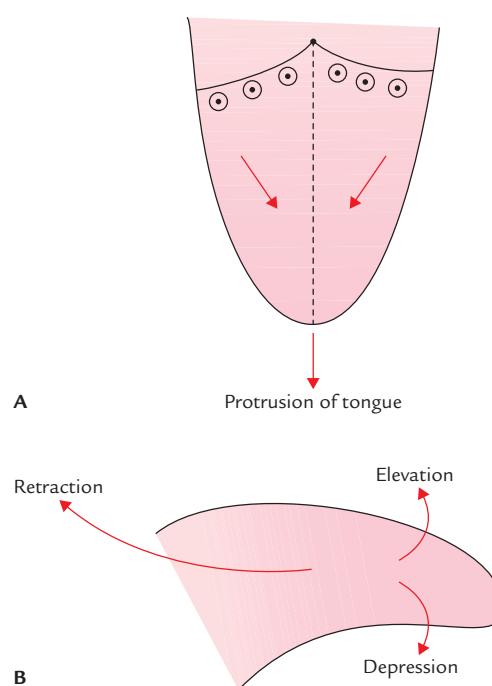


Fig. 13.16 Movements of the tongue: A, showing protrusion of the tongue; B, showing elevation, depression and retraction.

form the bulk of the tongue and are responsible for the protrusion of the tongue. If these muscles are paralyzed, the tongue will fall back into the oropharynx and obstruct the air passage causing choking and death. For the same reason during anesthesia, the tongue is pulled forwards to clear the air passage.

- The genioglossi are commonly used for **clinical testing of the hypoglossal nerve**. The muscles of both sides acting together protrude the tongue whereas single muscle deviate the tongue to the opposite side. Therefore when patient is asked to protrude his tongue, the tongue deviates to the paralyzed side (i.e., the side of lesion of the hypoglossal nerve; Fig. 13.17).

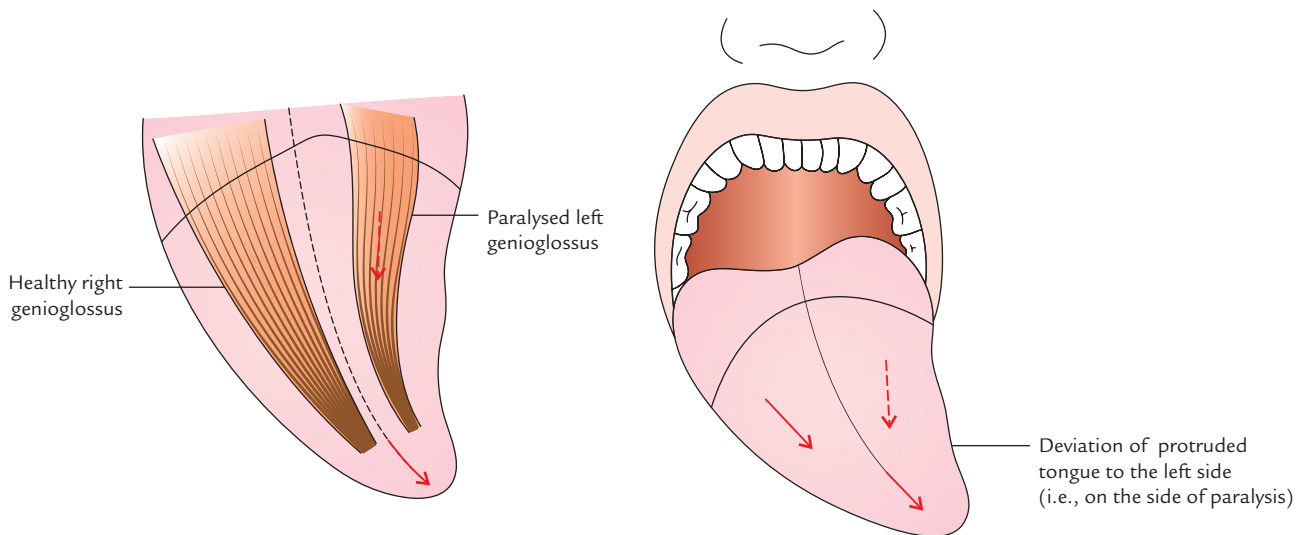


Fig. 13.17 Effect of paralysis of the hypoglossal nerve (left). A. Paralysis of the genioglossus on the left side. B. Deviation of the tongue on the left side i.e. on the paralysed side.

Arterial Supply (Fig. 13.18)

The tongue is supplied by the following arteries:

1. Branches of lingual artery (chief artery of tongue); the deep lingual arteries to the anterior part and dorsal lingual arteries to the posterior part.
2. Tonsillar branch of the facial artery.
3. Ascending pharyngeal artery.

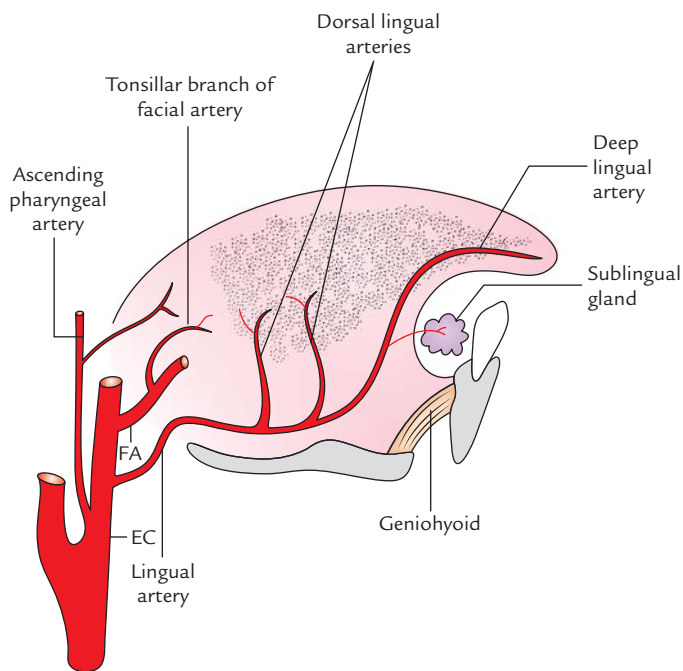


Fig. 13.18 Arterial supply of the tongue (FA = facial artery, EC = external carotid artery).

N.B. The deep lingual artery anastomoses with its fellow of the opposite side near the tip of the tongue. It is the only significant anastomoses across the midline of the tongue.

Venous Drainage

It is by the following veins:

1. **Deep lingual vein** is the *principal vein of the tongue* and is visible on the inferior surface of the tongue near the median plane through thin mucous membrane in life.
2. **Venae comitantes** accompanying the lingual artery. They are joined by *dorsal lingual veins*.
3. **Venae comitantes** accompanying the hypoglossal nerve.

These veins unite at the posterior border of the hyoglossus to form the **lingual vein**, which drains into either common facial vein or internal jugular vein.

Lymphatic Drainage

The lymphatics emerging from the tongue are grouped into the following four sets (Fig. 13.19):

1. **Apical vessels:** They drain the tip and inferior surface of the tongue into submental lymph nodes after piercing the mylohyoid muscle. Their efferents go to the submandibular nodes mainly, some cross the hyoid bone to reach the jugulo-omohyoid nodes.
2. **Marginal vessels:** They drain the marginal portions of the anterior two-third of the tongue—unilaterally into submandibular lymph nodes and then to the lower deep cervical lymph nodes, including jugulo-omohyoid.
3. **Central vessels:** They drain the central portion of the anterior two-third of the tongue (i.e., area within 0.5 inch on either side of midline). They pass vertically

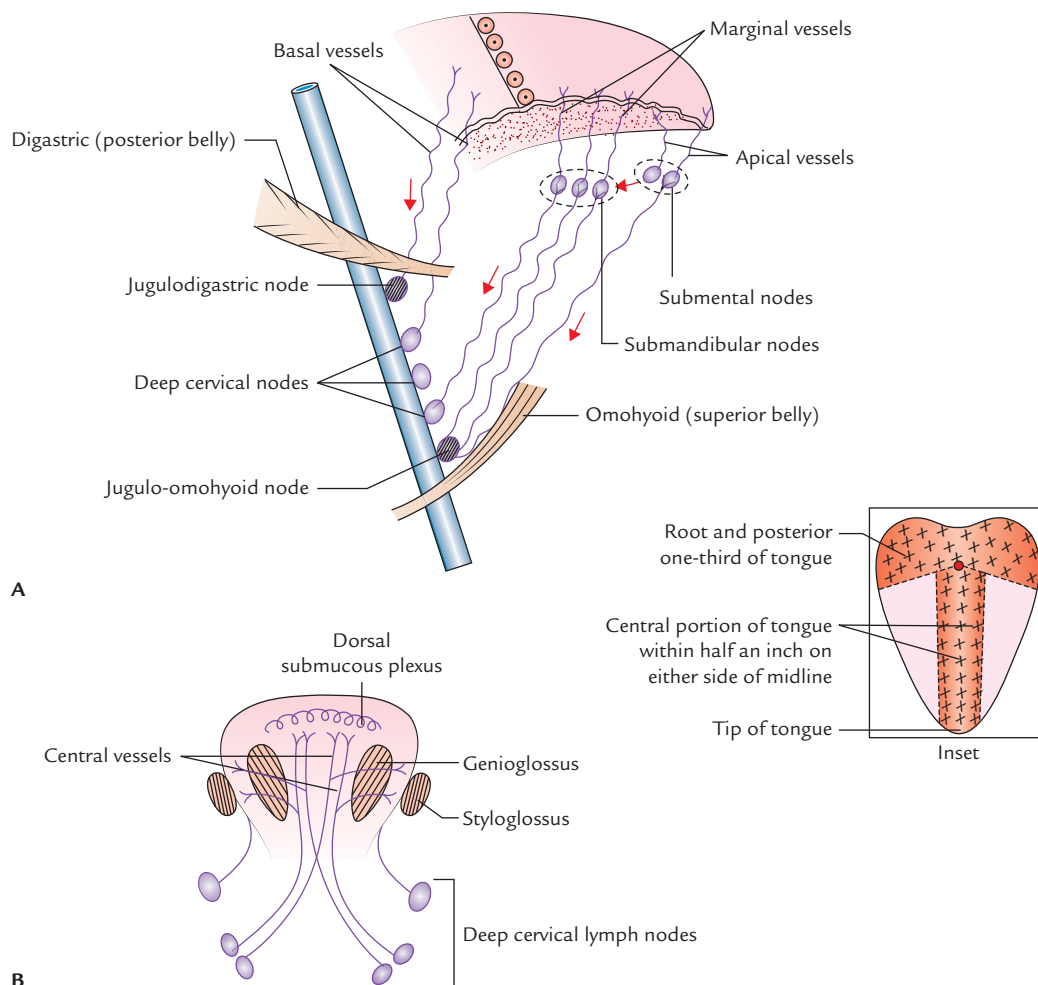


Fig. 13.19 Lymphatic drainage of the tongue: **A**, showing course and direction of apical, marginal, and basal lymph vessels; **B**, showing course and direction of central lymph vessels. Figure in the inset shows areas (in red) having bilateral lymphatic drainage.

downwards in the midline of the tongue between the genioglossus muscles and then drain bilaterally into the deep cervical lymph nodes.

4. **Basal vessels:** They drain the root of the tongue and posterior one-third of the tongue bilaterally into upper deep cervical lymph nodes, including jugulodigastric.

Clinical correlation

Prognosis of tongue cancer: There is rich anastomosis across the midline between the lymphatics of the posterior one-third of the tongue; therefore, a cancer on one side readily metastasizes to ipsilateral as well as the contralateral lymph nodes. In contrast, there is little cross communication of lymphatics of the anterior two-third of the tongue where cancer, more than 0.5 inches (12 mm) away from the midline, does not metastasize to the contralateral lymph nodes till very late stage. For this reason, cancer in the posterior one-third of the tongue has poor prognosis.

Nerve Supply (Fig. 13.20)

The nerves supplying the tongue are as follows:

Motor supply: All the muscles of tongue (intrinsic and extrinsic) are supplied by the hypoglossal nerve *except* palatoglossus which is supplied by cranial root of accessory via pharyngeal plexus.

Sensory supply: Anterior two-third of the tongue is supplied by:

- (a) lingual nerve carrying general sensations, and
- (b) chorda tympani nerve carrying special sensations of taste.

Posterior one-third of the tongue is supplied by:

- (a) glossopharyngeal nerve, carrying both general and special sensations of taste, and
- (b) posteriormost part (base of the tongue), supplied by the internal laryngeal branch of the superior laryngeal carrying special sensations of taste.

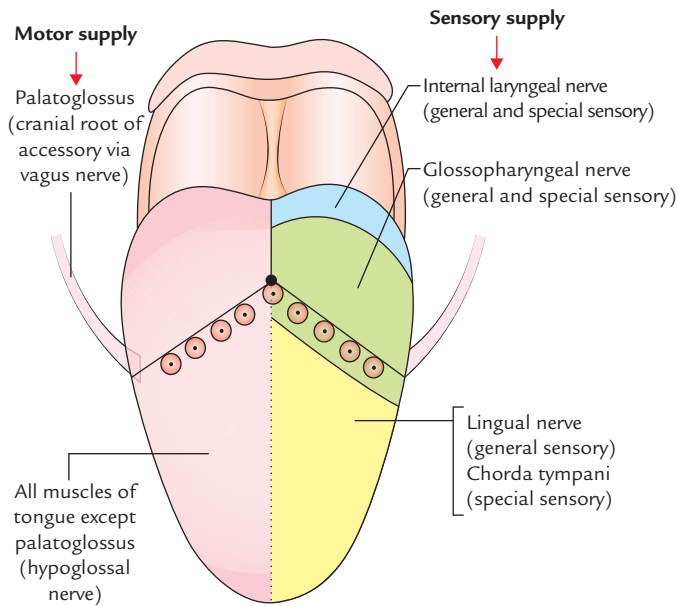


Fig. 13.20 Nerve supply of the tongue. Right half of the figure shows motor supply and left half shows sensory supply.

N.B. Nerves carrying taste sensations from the tongue are as follows (Fig. 13.21):

- *Chorda tympani* nerve (a branch of the facial nerve) from anterior two-third of the tongue.
- *Glossopharyngeal* from posterior one-third of the tongue.
- *Internal laryngeal* nerve from superior laryngeal branch of the vagus nerve, from posteriormost part of the tongue.

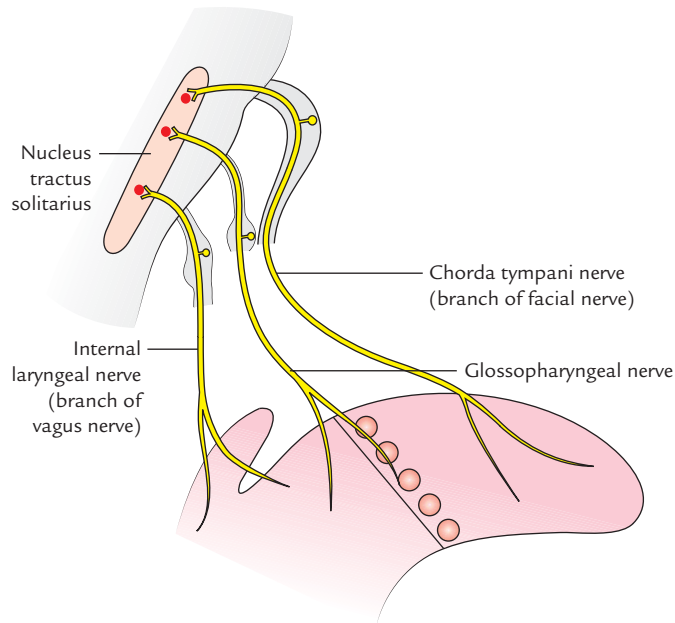


Fig. 13.21 Nerves carrying taste sensations from the tongue.

Clinical correlation

Referred pain of cancer tongue: The patients with cancer tongue often complain of pain in ear, temporomandibular joint, temporal fossa, and/or lower teeth.

This is due to *referred pain*. It is important to note that pain is frequently referred from one branch of the mandibular nerve to the other. Carcinoma commonly involves anterior 2/3rd of tongue. Thus if the sensations carried from anterior 2/3rd of the tongue by the lingual nerve are referred to auriculotemporal nerve, the patient feels pain in the ear, TMJ, and temporal fossa. On the other hand, if the pain from lingual nerve is referred to the inferior alveolar nerve, the pain is felt in the lower teeth.

Development of the Tongue (Fig. 13.22)

The tongue develops from the floor of the primitive pharynx in relation to the pharyngeal arches.

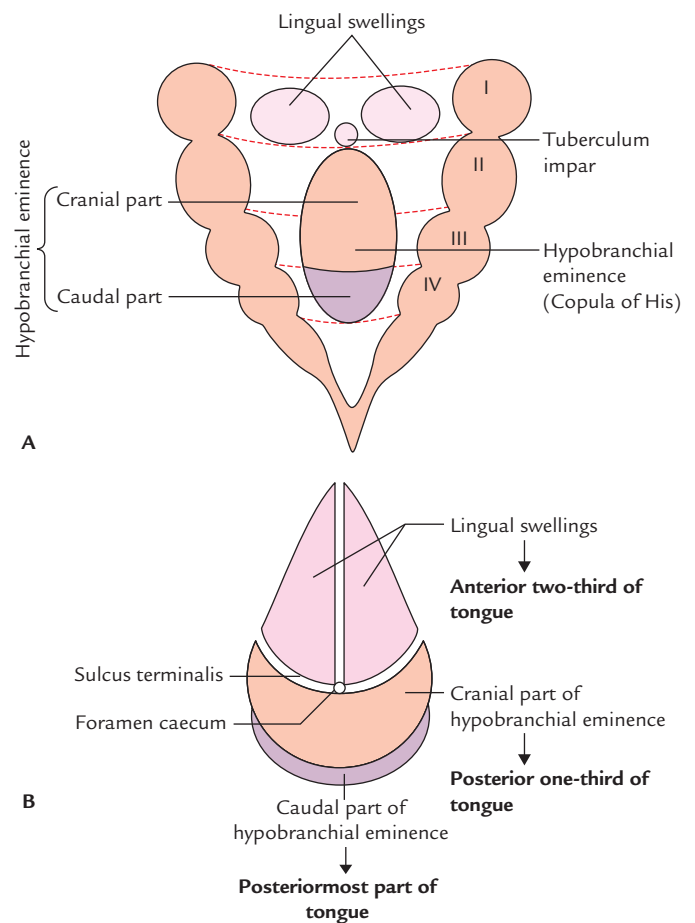


Fig. 13.22 Development of the tongue: A, appearance of four swellings in the floor of primitive pharynx; B, showing formation of anterior two-third by the growth and fusion of two lingual swellings and posterior one-third by the growth and fusion of cranial part of the hypobranchial eminence.

Table 13.6 Correlation of nerve supply of the tongue with its development

Structures	Source of development	Nerve supply
Muscles	Occipital myotomes	Hypoglossal nerve
Mucous membrane		
(a) Anterior two-third of tongue	First arch	<ul style="list-style-type: none"> • Lingual nerve (post-trematic nerve of 1st arch) • Chorda tympani nerve (pre-trematic nerve of 1st arch)
(a) Posterior one-third of tongue	Third arch	Glossopharyngeal nerve (nerve of 3rd arch)
(c) Posterioormost part of tongue	Fourth arch	Internal laryngeal nerve (nerve of 4th arch)

Development of Mucous Membrane of the Tongue

The mucous membrane of the anterior two-third of tongue develops from the fusion of a pair of **lingual swellings** with the **tuberculum impar**. The lingual swellings appear as endodermal thickenings at the anterior ends of the first pharyngeal arches. The tuberculum impar appears as a median swelling just behind the lingual swellings between the 1st and 2nd pharyngeal arches. The tuberculum impar soon disappears; thus the oral part is mostly bilateral in origin.

The lingual swellings fuse in the midline forming a median sulcus. The mucous membrane of posterior one-third of the tongue develops from the cranial part of **hypobranchial eminence**. The hypobranchial eminence (*copula of His*) appears as a median swelling due to thickening of endoderm connecting the ventral ends of 2nd, 3rd, and 4th pharyngeal arches. It soon divides into two parts: a cranial part related to the 2nd and 3rd arches and a caudal part related to the 4th arch.

The 3rd arch endoderm grows forwards over the 2nd arch to fuse with the lingual swellings and tuberculum impar and gives rise to the mucous membrane of the posterior one-third of the tongue. The 3rd arch grows forwards in a V-shaped manner and fuses with the anterior two-third of the tongue. The line of fusion is indicated by **sulcus terminalis**.

The mucous membrane of the posterioormost part of the tongue is derived from the 4th pharyngeal pouch.

The foramen caecum represents the site of development of thyroglossal duct forming thyroid gland in the embryo.

Development of Muscles of the Tongue

The muscles of tongue develop from **occipital myotomes**, which at first are closely related to developing hindbrain and later migrates anteroinferiorly around the pharynx and enter the tongue. The migrating myotomes carry with them their nerve supply—the 12th cranial nerve.

Correlation of Nerve Supply of the Tongue with its Development

Motor innervation: Muscles of the tongue are supplied by the hypoglossal nerve because they develop from occipital myotomes (occipital myotomes are formed by the fusion of precervical somites).

Sensory innervation:

1. **Anterior two-third** develops from the 1st pharyngeal arch, and therefore, supplied by:
 - (a) *lingual nerve*, the **post-trematic nerve** of the 1st arch, and
 - (b) *chorda tympani nerve*, the **pre-trematic nerve** of the 1st arch.
2. **Posterior one-third** develops from the 3rd pharyngeal arch, hence supplied by the **glossopharyngeal nerve**, the nerve of the 3rd arch.
3. **Posterioormost part** develops from the 4th arch, hence supplied by the **internal laryngeal nerve**, the nerve of the 4th arch.

The correlation between nerve supply of the tongue with its development is also presented in Table 13.6.

Golden Facts to Remember

- ▶ Hardest substance/structure in the body
 - ▶ Most sensitive part of the tooth
 - ▶ Wisdom tooth
 - ▶ Eye tooth
 - ▶ First deciduous teeth to erupt
 - ▶ First permanent teeth to erupt
 - ▶ Last permanent teeth to erupt
 - ▶ Last deciduous teeth to fall
 - ▶ Most commonly impacted teeth
 - ▶ Safety muscles of the tongue
 - ▶ Most common site of cancer tongue
 - ▶ Principal lymph node of the tongue (lymph node of the tongue)
- Enamel of the tooth
 - Dentine
 - Third molar
 - Upper canine
 - Mandibular central incisors (6 months)
 - First mandibular molars (6 years)
 - Third molars
 - Canines
 - Mandibular third molars
 - Genioglossus
 - Lateral margin of anterior two-third of tongue
 - Jugulo-omohyoid

Clinical Case Study



A 67-year-old chronic tobacco chewer complained to his family physician about a sore on the side of his tongue for 6 months. He stated that he first thought that it was a simple sore and then he became worried because it now enlarged in size and looked different. On examination the physician found an ulcerated and indurated (L. *indurare* = to harden) lesion on the lateral margin of the patient's tongue. The palpation of lymph nodes in the region of the neck revealed enlarged hard submandibular and lower deep cervical lymph nodes. He was referred to an ENT surgeon, who advised biopsy. The biopsy report revealed *squamous cell carcinoma*.

Questions

1. What is the commonest site of cancer of tongue?
2. What is lymphatic drainage of the side of anterior two-third of tongue?
3. In which location does cancer of tongue have poor prognosis and why?
4. Which lymph node is called lymph node of the tongue?
5. What is most common cause of fatal hemorrhage in tongue cancer?

Answers

1. Lateral margin of the anterior two-third of tongue.
2. Lymph from side of anterior two-third of tongue is drained into submandibular and lower deep cervical lymph nodes.
3. Posterior one-third of tongue because of bilateral spread of cancer. (Note that lymph from posterior one-third of tongue is drained bilaterally.)
4. Jugulo-omohyoid lymph node.
5. Erosion of deep lingual artery.

Pharynx and Palate

PHARYNX

The pharynx is a funnel-shaped fibromuscular tube, extending from the base of the skull to the esophagus (Fig. 14.1). It is lined throughout with mucous membrane. The pharynx acts as a common channel (Fig. 14.2) for both food (deglutition) and air (respiration).

MEASUREMENTS

Length: 12–14 cm,
Width: 3.5 cm at its base, and
 1.5 cm at pharyngoesophageal junction.

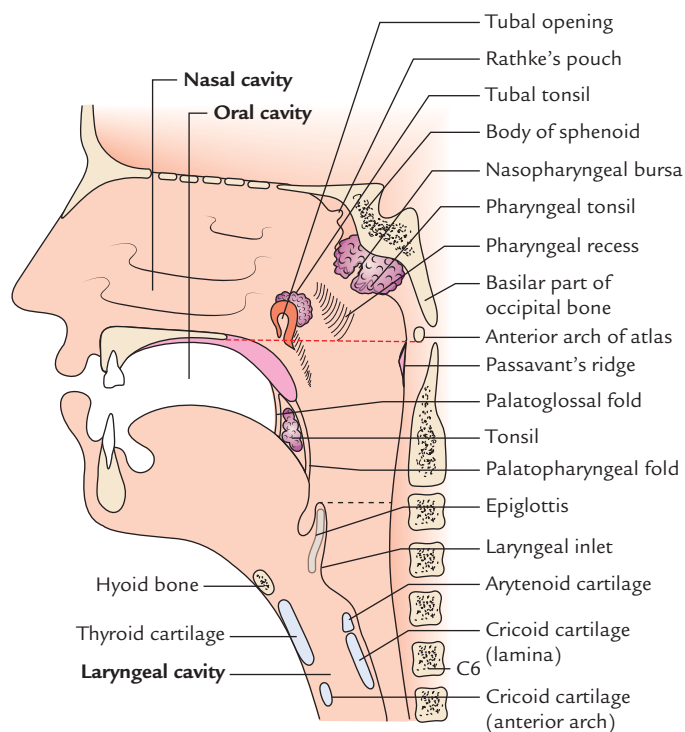


Fig. 14.1 The sagittal section through the nose, mouth, pharynx, and larynx.

LOCATION

It is situated behind the cavities of nose, mouth, and the larynx with which it communicates (Fig. 14.1).

BOUNDARIES AND RELATIONS

- Superior:** Base of skull including the posterior part of the body of sphenoid and basilar part of occipital bone in front of pharyngeal tubercle.
- Inferior:** Continuous with the esophagus at the level of lower border of cricoid cartilage anteriorly and lower border of C6 vertebra posteriorly.
- Posterior:** Prevertebral fascia in front of cervical spine. The pharynx is separated from prevertebral fascia only by a layer of loose areolar tissue, which allows the pharynx to slide freely on this fascia during swallowing.
- Anterior:** Opens into nasal cavities, mouth, and larynx.
- Lateral:** Neurovascular bundle of neck and styloid process with its attached muscles and ligaments.

SUBDIVISIONS (Figs 14.2–14.4)

The pharynx is divided into three parts. From above downwards these are as follows:

1. *Nasopharynx*, lying behind the nose.
2. *Oropharynx*, lying behind the oral cavity.
3. *Laryngopharynx*, lying behind the larynx.

NASOPHARYNX

The nasopharynx lies behind the nasal cavities and above the soft palate.

Boundaries

Roof: It is formed by:

- (a) Body of sphenoid.
- (b) Basilar part of the occipital bone.

Floor: It is formed by:

- Soft palate (sloping upper surface).
- Pharyngeal isthmus, an opening in the floor between the free edges of soft palate and posterior pharyngeal wall.

Anterior wall: It is formed by posterior nasal apertures separated by the posterior edge of nasal septum.

Posterior wall: It forms continuous sloping surface with roof. It is supported by anterior arch of C1 vertebra.

Lateral wall: Medial pterygoid plate of sphenoid.

Features

The features seen in the nasopharynx are:

- Nasopharyngeal (pharyngeal) tonsil:** It is a collection of lymphoid tissue beneath the mucous membrane at

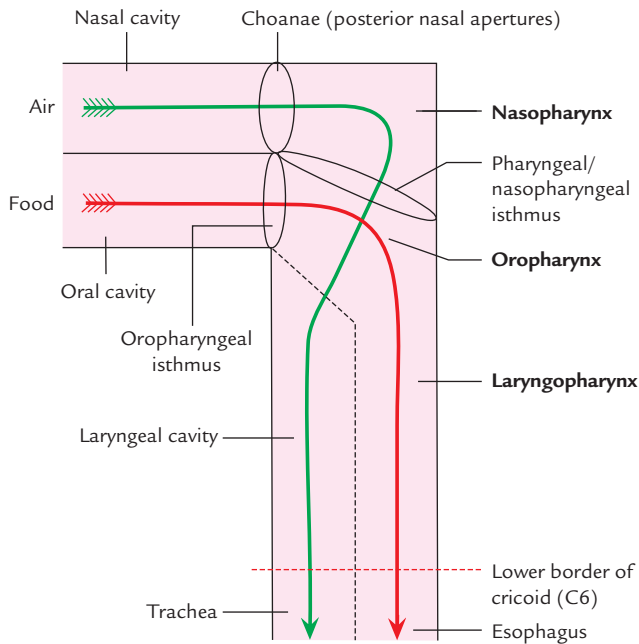


Fig. 14.2 Pathways for food (red arrow) and air (green arrow) through the pharynx.

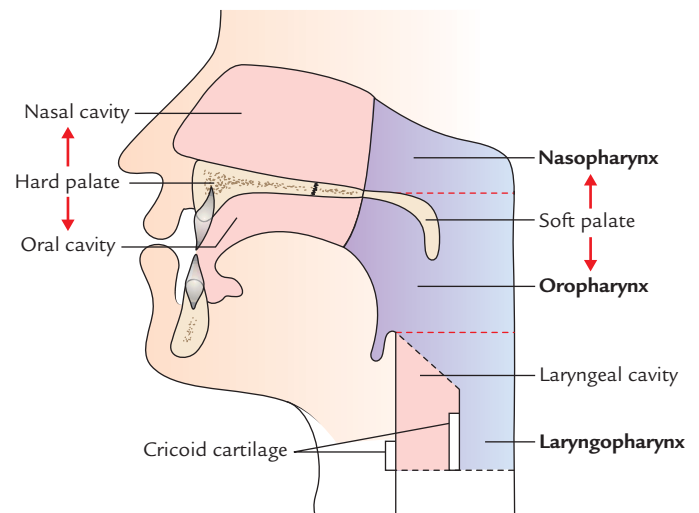


Fig. 14.3 Subdivisions of the pharynx.

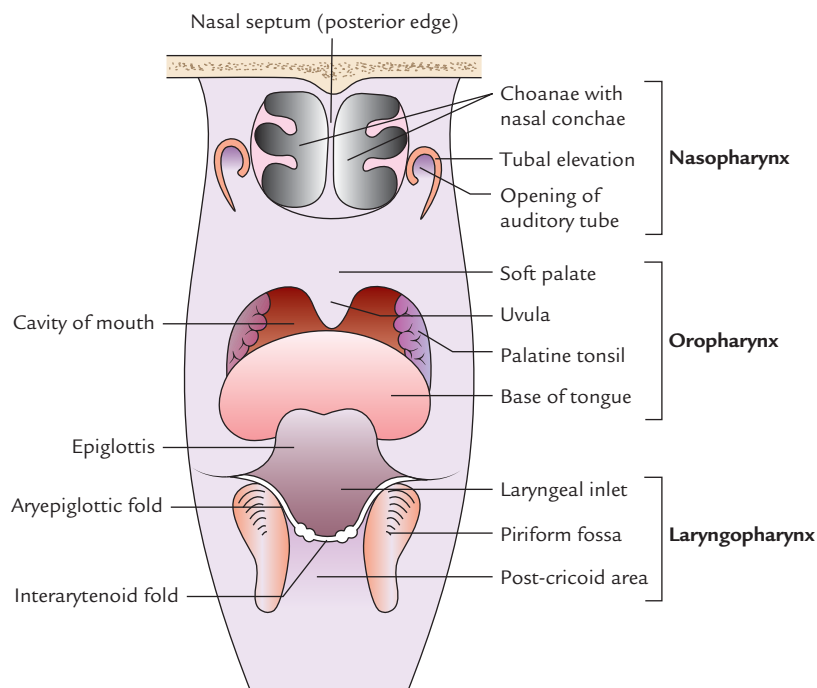


Fig. 14.4 The pharynx opened from behind showing features in the anterior walls of the nasopharynx, oropharynx, and laryngopharynx.

the junction of the roof and posterior wall of the nasopharynx.

A mucous diverticulum called *nasopharyngeal bursa* (*pouch of Luschka*) extends upwards into the substance of nasopharyngeal tonsil from its apex. It is provided with mucous glands. This bursa develops due to adhesion of notochord to the dorsal wall of the pharyngeal part of the foregut. Sometimes a small dimple is seen in the mucous membrane above the pharyngeal tonsil. It represents the remains of Rathke's pouch. A *craniopharyngioma* may arise from it.

- (b) **Orifice of the pharyngotympanic tube or auditory tube (eustachian tube):** This lies on the lateral wall at the level of the inferior nasal concha and 1.25 cm behind it.

The upper and posterior margins of this opening are bounded by a tubal elevation, which is produced by the collection of lymphoid tissue called **tubal tonsil**. Two mucous folds extend from this elevation:

- (i) *Salpingopharyngeal fold* extends vertically downwards and fades on the side wall of the pharynx. It contains salpingopharyngeus muscle.
 - (ii) *Salpingopalatine fold* extends downwards and forwards to the soft palate. It contains the levator palati muscle.
- (c) **Pharyngeal recess:** It is a deep depression behind the tubal elevation; it is called **pharyngeal recess (fossa of Rosenmüller)**.

N.B. Structurally and functionally the nasopharynx resembles the nose. It is respiratory in function and lined by pseudostratified ciliated columnar epithelium. Its walls are rigid and non-collapsible to keep the air passage patent.

Clinical correlation

Adenoids: The nasopharyngeal tonsils are prominent in children up to the 6 years of age, then gradually undergo atrophy till puberty and almost completely disappear by the age of 20.

The nasopharyngeal tonsils when enlarge due to infection are known as *adenoids*, which block the posterior nares making 'mouth breathing obligatory'.

The affected children present the following clinical features:

- Nasal obstruction
- Nasal discharge
- Mouth breathing with protrusion of tongue
- Toneless voice (due to absence of nasal tone)
- Small nose
- Epistaxis (i.e., nose-bleeding).

The infection from pharynx can easily pass into middle ear through pharyngotympanic tube.

Nasopharyngeal Isthmus and Passavant's Ridge

Some fibres of the palatopharyngeus muscle (arising from palatine aponeurosis) sweep horizontally backwards and join the upper fibres of the superior constrictor muscle to form a **U-shaped muscle-loop** in the posterior pharyngeal wall underneath the mucosa, which is pulled forward during swallowing to form the *Passavant ridge*. During swallowing the pharyngeal isthmus (the opening between the free edges of soft palate and posterior wall) is closed by the elevation of the soft palate and pulling forward of posterior pharyngeal wall (Passavant ridge). This U-shaped muscle loop thus acts as a palatopharyngeal sphincter.

OROPHARYNX (Figs 14.1, 14.2, and 14.3)

It lies behind the oral cavity and extends from the lower surface of the soft palate above to the upper border of epiglottis below.

Boundaries

Roof: It is formed by:

- (a) Soft palate (under surface).
- (b) Pharyngeal isthmus through which it communicated with the nasopharynx.

Floor: It is formed by:

- (a) Posterior 1/3rd of the tongue.
- (b) Interval between the tongue and epiglottis.

Anterior wall: It is incomplete and formed by:

- (a) Oropharyngeal isthmus (through which it opens into the oral cavity).
- (b) Pharyngeal part of the tongue.

Posterior wall: It is formed by body of C2 vertebra and upper part of the body of C3 vertebra.

Lateral wall: On each side, it is supported by pterygo-mandibular raphe, mandible, tongue, and hyoid bone.

The oropharynx provides common path for the food and air.

Features

The features seen in the oropharynx are:

- (a) **Lateral wall presents palatine tonsils**, one on either side. It is located into a triangular fossa (tonsillar fossa) bounded anteriorly by palatoglossal arch and posteriorly by palatopharyngeal arch.

The palatoglossal arch runs downwards and forwards from palate to the lateral margin of the tongue. The palatopharyngeal arch runs downwards and backwards to the pharyngeal wall where it fades out (for details of palatine tonsil, see page 208).

(b) Anterior wall presents:

- (i) *Lingual tonsil*, formed by numerous nodules of lymphoid tissue underneath the mucous lining of the pharyngeal part of the dorsum of the tongue.
- (ii) *Upper free end of epiglottis*, behind the tongue.
- (iii) *Median and lateral glossoepiglottic folds*, connecting the anterior surface and edges of the epiglottis, respectively to the tongue.
- (iv) *Epiglottic valleculae* are shallow fossae between the median and lateral glossoepiglottic folds.

Oropharyngeal Isthmus (Fig. 14.5)

It is an arched opening between the two palatoglossal folds through which the oral cavity communicates with the oropharynx. Its boundaries are as under:

Above: Soft palate.

Below: Dorsal surface of the posterior one-third of the tongue.

Lateral: Palatoglossal fold/arch on either side containing palatoglossus muscle.

The oropharyngeal isthmus is closed during deglutition to prevent regurgitation of food from the pharynx to the mouth.

Clinical correlation

Since the pathways for food and air cross each other in the oropharynx, the food sometimes may enter into the respiratory tract and cause choking. Similarly the air often enters the digestive tract producing gas in the stomach, which results in eructation (*belching*).

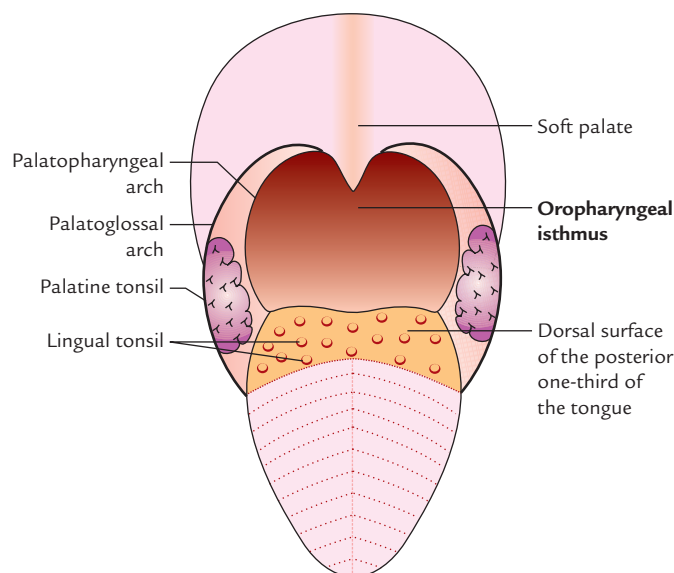


Fig. 14.5 Boundaries of the oropharyngeal isthmus.

LARYNGOPHARYNX

The laryngopharynx lies behind the laryngeal inlet and posterior wall of the larynx. It lies behind the larynx and extends from the upper border of the epiglottis to the lower border of cricoid cartilage anteriorly and lower border of C6 vertebra posteriorly. It communicates anteriorly with the laryngeal cavity through **laryngeal inlet** and inferiorly with the esophagus at the pharyngoesophageal junction (the narrowest part of the GIT except appendix).

Boundaries

Anterior wall: It is formed by:

- (a) Laryngeal inlet.
- (b) Posterior surface of the larynx.

Posterior wall: It is supported by the bodies of C3, C4, C5, and C6 vertebrae.

Lateral wall: It is supported by thyroid cartilage and thyrohyoid membrane.

Features

The features seen in the laryngopharynx are:

- (a) **Anterior wall** presents laryngeal inlet and below the inlet it is supported by cricoid and arytenoid cartilages.
- (b) **Lateral wall** presents piriform fossa one on each side of laryngeal inlet. The piriform fossa is described in detail below.

PIRIFORM FOSSA

It is a deep recess broad above and narrow below in the anterior part of lateral wall of the laryngopharynx, on each side of the laryngeal inlet. These recesses are produced due to bulging of larynx into laryngopharynx.

Boundaries (Fig. 14.6)

Medial: Aryepiglottic fold and quadrangular membrane of larynx.

Lateral: Mucous membrane covering the medial surface of the lamina of thyroid cartilage and thyrohyoid membrane.

The internal laryngeal nerve and superior laryngeal vessels pierce the thyrohyoid membrane and traverse underneath the mucous membrane of the floor of the fossa to reach the medial wall.

Above: Piriform fossa is separated from epiglottic vallecula by lateral glossoepiglottic fold.

N.B.

- The piriform fossa is deep in ruminating animals in which it acts as *lateral food channel* to convey the bolus of food during deglutition by the side of closed laryngeal inlet.

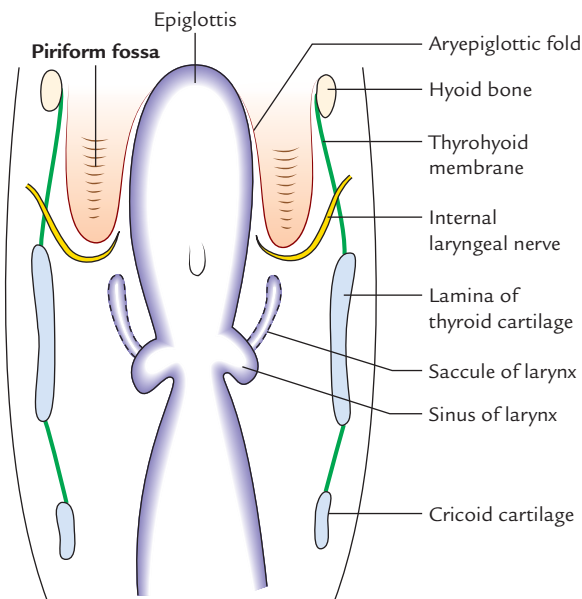


Fig. 14.6 Schematic coronal section through larynx showing the location and boundaries of the piriform fossa.

- It is sometimes, artificially deepened by smugglers using lead balls to hide precious materials such as diamonds. For this reason, the piriform fossa is also called *smuggler's fossa*.

Clinical correlation

- The piriform fossae are dangerous sites for perforation by an endoscope.
- A malignant tumor of the laryngopharynx (hypopharynx) may grow in the space provided by the piriform fossa without producing symptoms until the patient presents with metastatic lymphadenopathy.
- The ingested foreign bodies (for example, fish bones, safety pins) are sometimes lodged into the piriform fossa. If care is not taken, the removal of foreign bodies may damage the internal laryngeal nerve leading to anesthesia in the supraglottic part of the larynx and subsequent loss of *protective cough reflex*.

PHARYNGEAL WALL (Fig. 14.7)

The wall of the pharynx consists of four layers; from within outwards these are as follows:

1. Mucous membrane/mucous coat.
2. Pharyngobasilar fascia (pharyngeal aponeurosis).
3. Muscular coat (pharyngeal muscles).
4. Buccopharyngeal fascia (loose areolar sheath).

Mucous membrane/mucous coat: The mucous membrane lining the pharynx contains a considerable amount of elastic tissue and is continuous with the mucous lining of

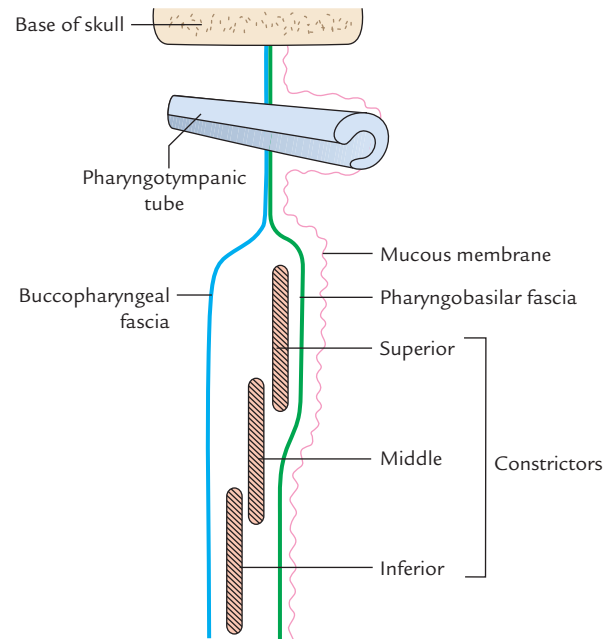


Fig. 14.7 Structure of the pharyngeal wall.

eustachian tubes, nasal cavities, mouth, larynx, and esophagus. It is lined by non-keratinized stratified squamous epithelium except in the region of the nasopharynx, where it is lined by ciliated columnar epithelium (respiratory epithelium).

N.B. There are many subendothelial collections of lymphoid tissue around the commencement of food and air passages, into which epithelium tends to invaginate in the form of narrow clefts (crypts).

These collections of lymphoid tissue form pharyngeal and tubal tonsils in the nasopharynx and palatine, and lingual tonsils in the oropharynx.

Pharyngobasilar fascia: It is a fibrous thickening of the submucosa. It lines the muscular coat and is thick near the base of the skull but thin and indistinct inferiorly. The pharyngobasilar fascia is thickest:

- (a) in the upper part where it fills the gap between the upper border of superior constrictor and the base of the skull, and
- (b) posteriorly where it forms the *pharyngeal raphe*.

Muscular coat: The muscular coat consists of the following two layers of striated muscles:

- (a) The **outer layer** comprises three pairs of circular muscles called *constrictors*.
- (b) The **inner layer** comprises three pairs of longitudinal muscles.

The pharyngeal muscles are described in detail under the heading 'muscles of the pharynx'.

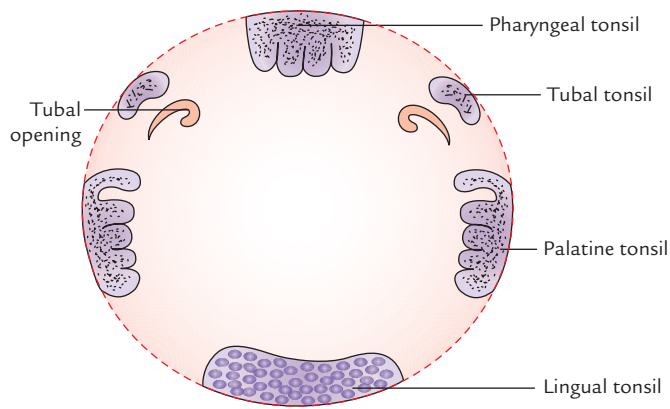


Fig. 14.8 Waldeyer's ring (an interrupted 'circle of tonsils' at the upper end of the respiratory and alimentary tracts).

Buccopharyngeal fascia: It is an inconspicuous fascia, which covers the outer surface of constrictor muscles. In the upper part, it is also prolonged forwards to cover the buccinator muscles, hence the name *buccopharyngeal fascia*. Above the upper border of the superior constrictor, it blends with the pharyngobasilar fascia.

Clinical correlation

Waldeyer's ring: The aggregations of lymphoid tissue underneath the epithelial lining of pharyngeal wall called tonsils, surround the commencement of air and food passages. These aggregations together constitute an interrupted circle called *Waldeyer's ring*, which forms the special feature of the interior of the pharynx.

The Waldeyer's ring is formed by (Fig. 14.8):

1. Pharyngeal tonsil (nasopharyngeal tonsil), postero-superiorly.
2. Lingual tonsil, anteriorly.
3. Tubal and palatine tonsils, laterally.

It is thought that, Waldeyer's ring prevents the invasion of microorganisms from entering the air and food passages and this helps in the defense mechanism of the respiratory and alimentary systems.

MUSCLES OF THE PHARYNX

CONSTRICTOR MUSCLES (Figs 14.9 and 14.10)

The *three constrictor muscles of the pharynx* (superior, middle, and inferior) are arranged like a flowerpot without base, placed one above the other and open in front for communication with the nasal, oral, and laryngeal cavities. Thus inferior constrictor overlaps the middle, which in turn overlaps the superior constrictor (Fig. 14.9 inset).

The **constrictor muscles** form bulk of the muscular coat of the pharyngeal wall. They arise in front from the margins of posterior openings of the nasal, oral, and laryngeal cavities. The fibres pass backwards, in a fan-shaped manner into the lateral and posterior walls of the pharynx to be inserted into the median fibrous raphe on the posterior aspect of the pharynx, extending from the base of the skull (pharyngeal tubercle of occipital bone) to the esophagus. The origin and insertion of constrictors of the pharynx is shown in Figure 14.10.

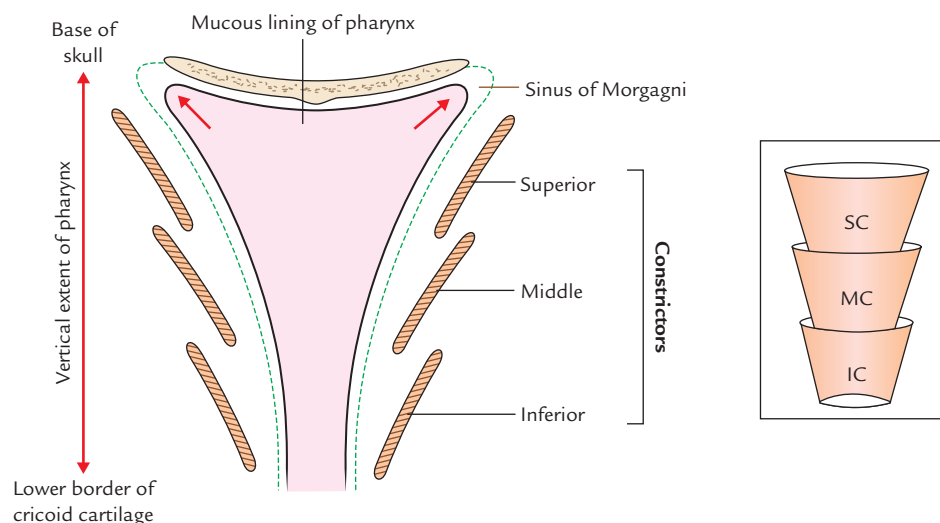


Fig. 14.9 Overlapping arrangement of the constrictor muscles of the pharynx. The figure in the inset shows flowerpot arrangement of the constrictors (SC = superior constrictor, MC = middle constrictor, IC = inferior constrictor).

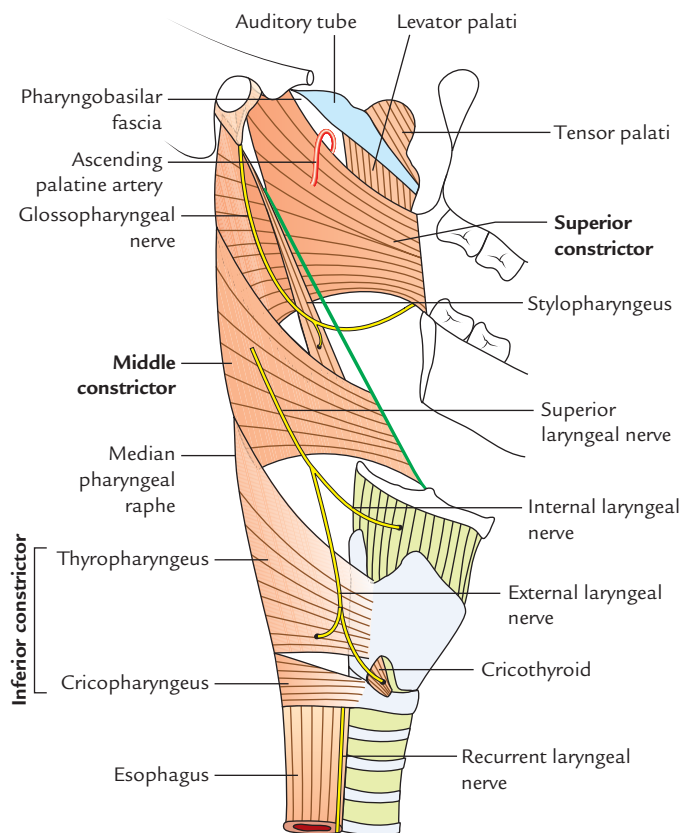


Fig. 14.10 Origin and insertion of the constrictors of the pharynx.

The origin, insertion, nerve supply, and actions of the constrictor muscles are presented in Table 14.1.

Clinical correlation

Pharyngeal Pouch (also called *Zenker's diverticulum*): Inferior constrictor muscle has two parts: *thyropharyngeus* made up of oblique fibres and *cricopharyngeus* made up of transverse fibres.

The potential gap posteriorly between the thyropharyngeus and cricopharyngeus is called *pharyngeal dimple* or *Killian's dehiscence* (Fig. 14.11). The mucosa and submucosa of the pharynx may bulge through this weak area to form a pharyngeal pouch or diverticulum (Fig. 14.12).

The formation of pharyngeal pouch in the region of Killian's dehiscence is attributed to the *neuromuscular incoordination* in this region, which may be because the two parts of the inferior constrictor have different nerve supply. The propulsive thyropharyngeus is supplied by the pharyngeal plexus and the sphincteric cricopharyngeus is supplied by the recurrent laryngeal nerve. If the cricopharyngeus fails to relax when the thyropharyngeus contracts, the bolus of food is pushed backwards and tends to produce a diverticulum.

Gaps in the Pharyngeal Wall

The four gaps exist on either side in the pharyngeal wall in relation to constrictor muscles. The gaps and structures

Table 14.1 Origin, insertion, nerve supply, and actions of the constrictor muscles of the pharynx

Muscle	Origin	Insertion	Nerve supply	Action
Superior constrictor (Quadrilateral in shape)	(a) Pterygoid hamulus (b) Pterygomandibular raphe (c) Medial surface of the mandible at the upper end of mylohyoid line (d) Side of the posterior part of the tongue	(a) Pharyngeal tubercle on the base of skull (b) Median fibrous raphe	Pharyngeal branch of the vagus nerve carrying fibres of cranial root of the accessory nerve	Helps in deglutition
Middle constrictor (Fan shaped)	(a) Lower part of the stylohyoid ligament (b) Lesser cornu of hyoid (c) Upper border of greater cornu of hyoid	Median fibrous raphe	Pharyngeal branch of the vagus nerve carrying fibres of cranial root of the accessory nerve	Helps in deglutition
Inferior constrictor (a) Thyropharyngeus	(a) Oblique line on lamina of the thyroid cartilage (b) Tendinous band between the thyroid (inferior) tubercle and cricoid cartilage	Median fibrous raphe	(a) Pharyngeal plexus and (b) External laryngeal nerve	Helps in deglutition
(b) Cricopharyngeus	Cricoid cartilage	Median fibrous raphe	Recurrent laryngeal nerve	

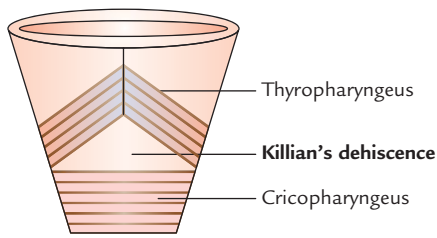


Fig. 14.11 Killian's dehiscence.

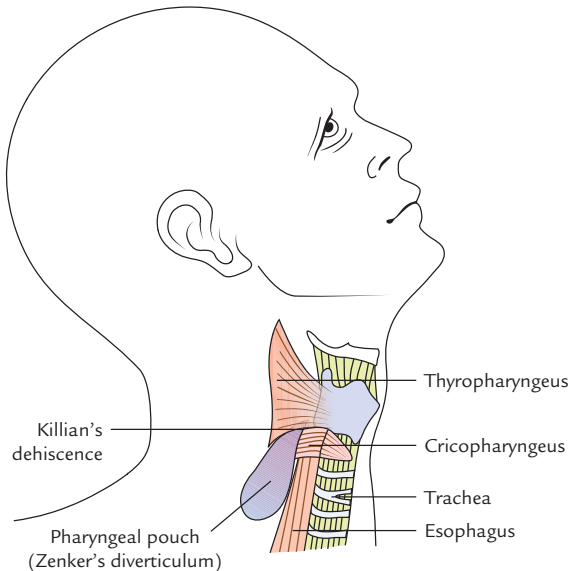


Fig. 14.12 Pharyngeal diverticulum.

Table 14.2 The gaps in the pharyngeal wall and structures passing through them

Gap	Structures passing through them
Between the base of skull and the upper concave border of superior constrictor (sinus of Morgagni)	<ul style="list-style-type: none"> • Auditory tube • Levator palati muscle • Ascending palatine artery • Palatine branch of the ascending pharyngeal artery
Between the superior and middle constrictors	<ul style="list-style-type: none"> • Stylopharyngeus muscle • Glossopharyngeal nerve
Between the middle and inferior constrictors	<ul style="list-style-type: none"> • Internal laryngeal nerve • Superior laryngeal vessels
Between the lower border of inferior constrictor and the esophagus (in the tracheo-esophageal groove)	<ul style="list-style-type: none"> • Recurrent laryngeal nerve • Inferior laryngeal vessels

passing through these gaps (Fig. 14.13) are presented in Table 14.2.

LONGITUDINAL MUSCLES (Fig. 14.14)

These muscles run longitudinally from above downwards to form the longitudinal muscle coat (Table 14.3). The origin,

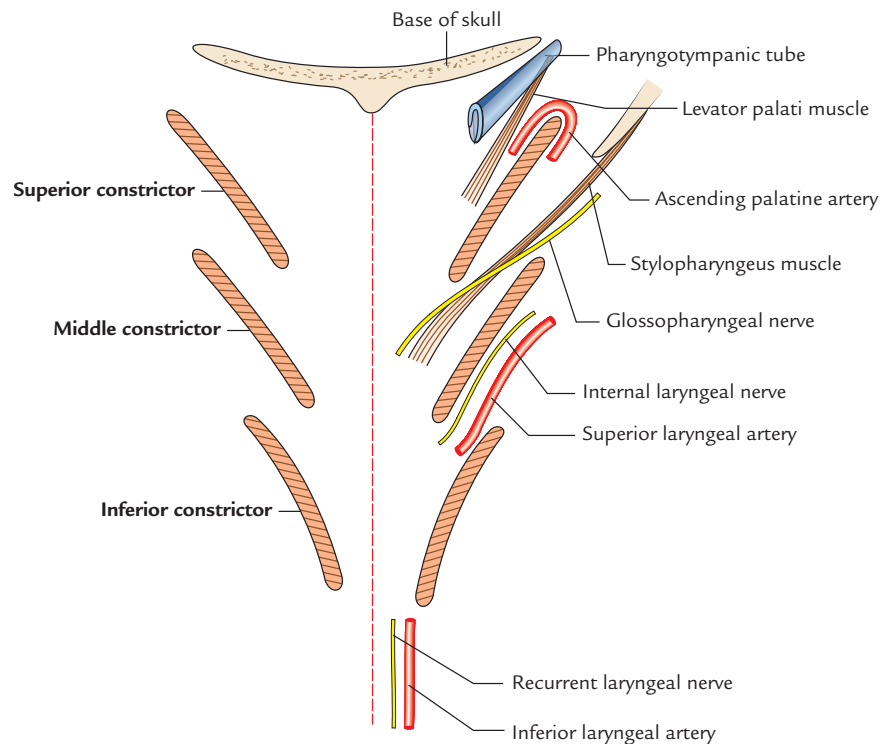


Fig. 14.13 Structures passing through the gaps in the pharyngeal wall.

Table 14.3 Origin, insertion, and nerve supply of the longitudinal muscles of the pharynx

Muscle	Origin	Insertion	Nerve supply
Stylopharyngeus	Medial surface of the base of styloid process	Posterior border of the lamina of thyroid cartilage	Glossopharyngeal (IX) nerve
Palatopharyngeus	By two fasciculi (anterior and posterior) from the upper surface of the palatine aponeurosis	Posterior border of the lamina of thyroid cartilage	Cranial root of 11th cranial nerve by pharyngeal plexus
Salpingopharyngeus	Lower part of the cartilage of the auditory tube	Posterior border of the lamina of thyroid cartilage	Cranial root of 11th cranial nerve by pharyngeal plexus

insertion, and nerve supply of the longitudinal muscles are presented in Table 14.3.

Actions of the Longitudinal Muscles

They elevate the larynx and shorten the pharynx during swallowing. At the same time palatopharyngeal sphincter formed by some fibres of the palatopharyngeus muscle closes the nasopharyngeal isthmus.

NERVE SUPPLY OF THE PHARYNX

Motor: All the pharyngeal muscles are supplied by the cranial root of accessory nerve (via pharyngeal branch of vagus and

pharyngeal plexus), except the stylopharyngeus which is supplied by the glossopharyngeal nerve.

Sensory:

1. *Nasopharynx*, by pharyngeal branch of the pterygo-palatine ganglion carrying fibres from maxillary division of the trigeminal nerve.
2. *Oropharynx*, by glossopharyngeal nerve.
3. *Laryngopharynx*, by the internal laryngeal nerve.

PHARYNGEAL PLEXUS OF THE NERVES

It lies on the posterolateral aspect of the pharynx over the middle constrictor underneath the buccopharyngeal fascia.

It is formed by:

1. Pharyngeal branch of the vagus nerve carrying fibres from cranial part of the accessory nerve.
2. Pharyngeal branch of the glossopharyngeal nerve.
3. Pharyngeal branch from superior cervical sympathetic ganglion.

ARTERIAL SUPPLY OF THE PHARYNX

The branches of the following arteries supply the pharynx:

1. Ascending pharyngeal artery (from external carotid artery).
2. Ascending palatine and tonsillar artery (from facial artery).
3. Greater palatine and pharyngeal artery (from maxillary artery).
4. Lingual artery (from external carotid artery).

VENOUS DRAINAGE OF THE PHARYNX

The venous blood from pharynx is largely drained into **pharyngeal venous plexus**, which, like the pharyngeal nerve plexus, is situated on the posterolateral aspect of the pharynx over the middle constrictor. It drains into the internal jugular vein.

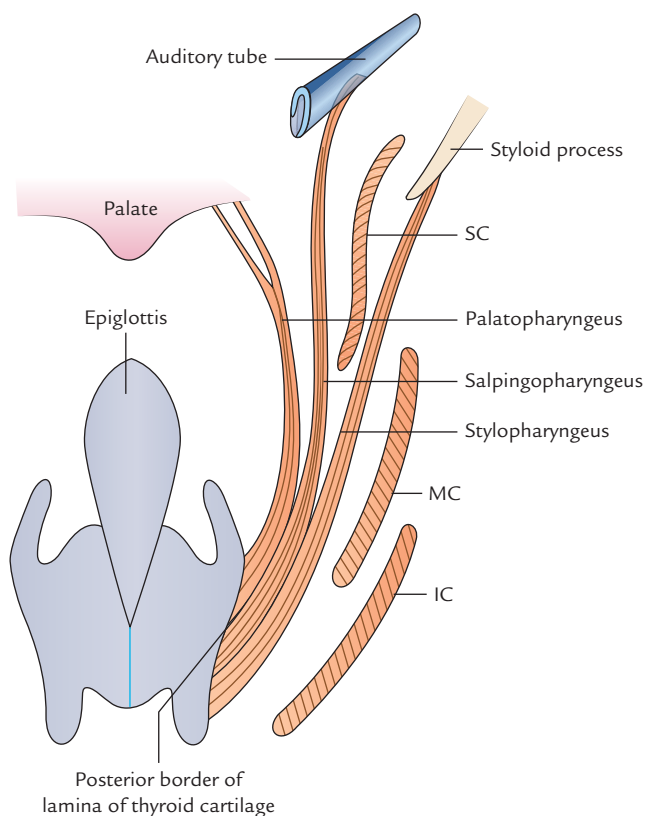


Fig. 14.14 Origin and insertion of the longitudinal muscles of the pharynx (SC = superior constrictor, MC = middle constrictor, IC = inferior constrictor).

LYMPHATIC DRAINAGE OF THE PHARYNX

The lymph from pharynx is drained into the upper and lower deep cervical lymph nodes directly and through retropharyngeal lymph nodes.

DEGLUTITION (SWALLOWING)

The deglutition is a process or act by which the food is transferred from the mouth to the stomach. It consists of the following three successive stages/phases:

1. First stage (in the mouth) – voluntary
2. Second stage (in the pharynx) – involuntary
3. Third stage (in the esophagus) – involuntary

First stage: In this stage the mouth is closed, the anterior part of tongue is raised against the hard palate anterior to the bolus of food to push the masticated food progressively in the posterior part of the oral cavity. The soft palate closes down onto the back of the tongue to help form bolus of food. Now the hyoid bone moves up and food is pushed from oral cavity to the oropharynx through oropharyngeal isthmus.

Second stage: This stage is very rapid. The nasopharyngeal isthmus is closed by the elevation of the soft palate and contraction of Passavant's ridge to prevent entry of food into the nasopharynx. The laryngeal inlet is closed by approximation of the aryepiglottic folds to prevent entry of food into the larynx. Now the pharynx and larynx are elevated behind the hyoid bone by the longitudinal muscles of the pharynx and the bolus of food is pushed down over the posterior surface of the epiglottis by gravity and

contraction of superior and middle constrictors. Thus food passes from the oropharynx to the laryngopharynx. This is followed by rapid downward displacement of the larynx and pharynx (by infrahyoid muscles), which reopens the laryngeal orifice.

Third stage: In this stage, propulsive action of thyropharyngeus followed by relaxation of cricopharyngeus pushes food, which passes from laryngopharynx to the esophagus. From here it enters into the stomach by peristaltic movements in the esophageal wall.

PHARYNGEAL SPACES

These are potential spaces in relation to pharynx, viz.

1. **Retropharyngeal space:** It is situated behind the pharynx and extends from the base of the skull above to the bifurcation of trachea below.
2. **Parapharyngeal space:** It is situated on the side of the pharynx. It contains carotid vessels, internal jugular vein, last four cranial nerves, and cervical sympathetic chain.

PALATINE TONSILS

There are two palatine tonsils (commonly called *tonsils*). Each tonsil is an almond-shaped mass of lymphoid tissue situated in the triangular fossa (tonsillar fossa) of the lateral wall of the oropharynx between the anterior and posterior pillars of fauces. The anterior pillar is formed by palatoglossal arch and posterior pillar is formed by palatopharyngeal arch (Fig. 14.15).

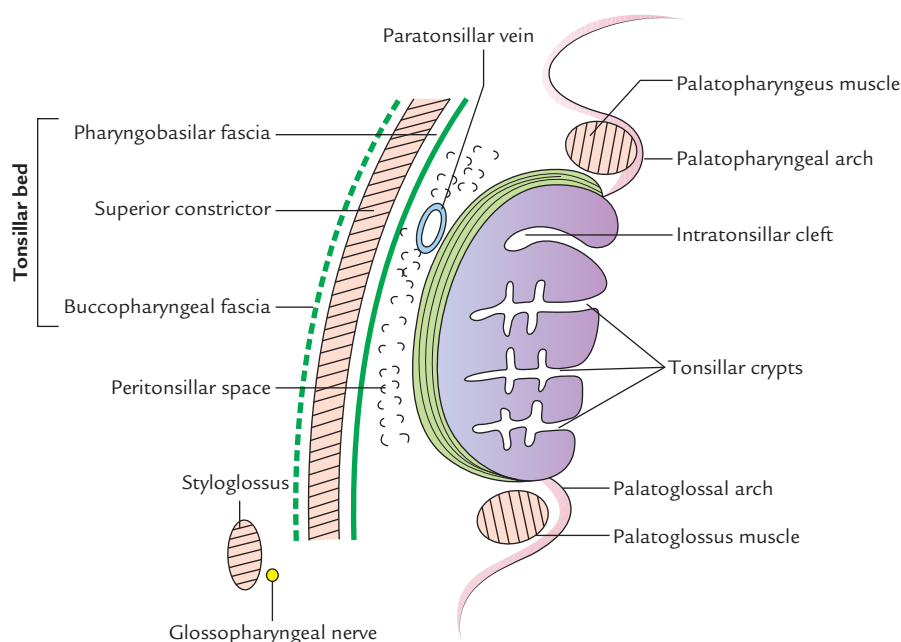


Fig. 14.15 Horizontal section through tonsillar fossa showing medial and lateral surfaces of the tonsil and tonsillar bed.

N.B. The actual size of tonsil is much bigger than it appears on oropharyngeal examination because parts of tonsil extend upwards into the soft palate, downwards into the base of the tongue and anteriorly underneath the palatoglossal arch.

Boundaries of the Tonsillar Fossa/Sinus

Anterior: Palatoglossal arch containing palatoglossus muscle.
Posterior: Palatopharyngeal arch containing palatopharyngeus muscle.
Apex: Soft palate, where both arches meet.
Base: Dorsal surface of the posterior one-third of the tongue.

Lateral wall

(or *tonsillar bed*): Superior constrictor muscle (mainly).

Tonsillar Bed (Fig. 14.15)

It is formed from within outwards by:

- pharyngobasilar fascia,
- superior constrictor muscle, and
- buccopharyngeal fascia.

External Features

The tonsil presents the following external features:

- Medial surface:** It is free and bulges into the oropharynx. It is lined by non-keratinized stratified squamous epithelium, which dips into the substance of tonsil forming crypts. The number of tonsillar crypts vary from 12 to 15 and their openings can be seen on the medial surface. One of the crypts situated near the upper

part of the tonsil is very large and deep. It is called **crypta magna** or **intratonsillar cleft** and represents the remnant of the second pharyngeal pouch. The crypts may be filled with cheesy material consisting of epithelial cells, bacteria, and food debris.

- Lateral surface (Figs 14.15 and 14.16):** It is covered by a well-defined fibrous tissue, which forms the tonsillar hemicapsule. Between the capsule and the bed of tonsil is the loose areolar tissue (*peritonsillar space*), which makes it easy to dissect the tonsil in this plane during **tonsillectomy**. It is also the site of collection of pus in **peritonsillar abscess**.

The superior constrictor separates this surface from the following structures (Fig. 14.16):

- Facial artery and two of its branches, the ascending palatine and tonsillar.
- Styloglossus muscle and glossopharyngeal nerve.
- Styloid process (when elongated).
- Angle of mandible and medial pterygoid muscle.
- Submandibular salivary gland.

The internal carotid artery is about 2.5 cm posterolateral to the tonsil.

- Anterior border:** It passes underneath the palatoglossal arch.
- Posterior border:** It passes underneath the palatopharyngeal arch.
- Upper pole:** It extends up into the soft palate. Its medial surface is covered by a semilunar fold extending between the anterior and posterior pillars enclosing a potential space called *supratonsillar fossa*.
- Lower pole:** It is attached to the tongue by a band of fibrous tissue called *suspensory ligament of the tonsil*.

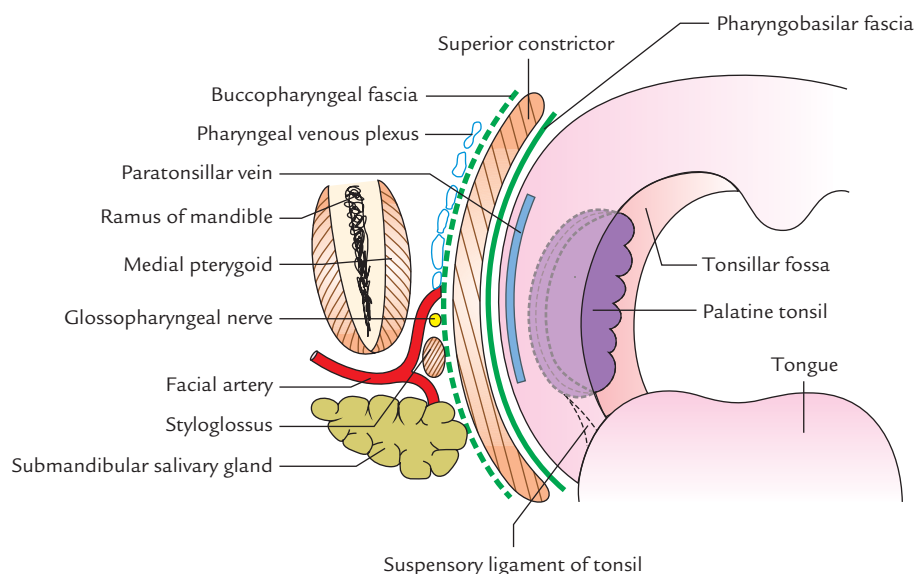


Fig. 14.16 Horizontal section through right palatine tonsil showing structures deep to its lateral surface.

N.B. A triangular fold of mucous membrane extends from anterior pillar to the anteroinferior part of the tonsil. It encloses a potential space called **anterior tonsillar space**.

The tonsil is separated from the tongue by a sulcus called **tonsillolingual sulcus**.

Surface anatomy: An oval area 1.25 cm above and in front of the angle of the mandible, marked in the parotid region of face indicates the location of tonsil on the surface.

Arterial Supply of the Tonsil (Fig. 14.17)

The following arteries supply the tonsil:

1. Tonsillar branch of facial artery (it is the principal artery and enters the lower pole of the tonsil by piercing the superior constrictor).
2. Dorsalis linguae branches of lingual artery.
3. Ascending palatine, a branch of facial artery.
4. Ascending pharyngeal, a branch of external carotid artery.
5. Greater palatine (descending palatine), a branch of maxillary artery.

Venous Drainage of the Tonsil

The veins from tonsil drain into paratonsillar vein. The paratonsillar vein descends from the soft palate across the lateral aspect of the tonsillar capsule and pierces the superior constrictor to drain into **pharyngeal venous plexus**.

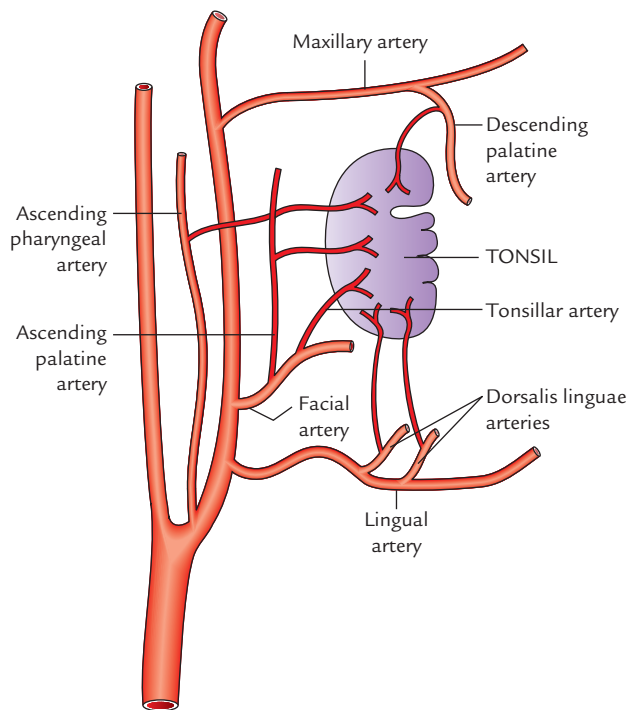


Fig. 14.17 Arteries supplying the tonsil.

Lymphatic Drainage of the Tonsil

The lymphatics of tonsil pierce the superior constrictor and drain into the upper deep cervical lymph nodes, particularly the jugulodigastric lymph node. It is often called **tonsillar lymph node** because it is primarily enlarged in infection of the tonsil (tonsillitis). The tonsillar lymph node is located below the angle of the mandible.

Nerve Supply of the Tonsil

Palatine tonsil is supplied by the glossopharyngeal nerve and lesser palatine branches of the sphenopalatine ganglion.

Clinical correlation

- **Acute tonsillitis:** The tonsils are the frequent sites of acute infection especially in school-going children. It may affect adults also. This condition is called *acute tonsillitis*. It is mostly seen in viral infection. It is rare in infants and persons above 50 years of age.
- **Acute follicular tonsillitis:** In this condition, the infection spreads into crypts, which become filled with purulent material presenting at the openings of crypts as *yellowish spots*.
- **Bleeding from tonsillar fossa after tonsillectomy:** It most commonly occurs due to damage of *paratonsillar vein*. The blood clots should be removed in order to check bleeding. If not removed, they interfere with the retraction of the vessel walls by preventing the contraction of the surrounding muscles. The postoperative edema of tonsillar bed after tonsillectomy can affect the glossopharyngeal nerve leading to loss of sensation in the posterior one-third of the tongue.

Histological Structure (Fig. 14.18)

Histologically, the tonsil presents the following features:

1. Its oral surface is lined by stratified squamous non-keratinized epithelium, which dips into underlying tissues to form crypts.
2. Presence of lymphatic nodules on the sides of the crypts.
3. Presence of mucous glands in the deeper plane.

Development of the Tonsil

The tonsil develops in the region of 2nd pharyngeal pouch. The cells of endodermal lining of pouch proliferate and grow out as solid columns/buds into the surrounding mesenchyme. The central portions of these cell columns are canalized and form tonsillar clefts. The lymphoid cells from the surrounding mesenchyme accumulate around the crypts and differentiate into lymphoid follicles. The remnant of 2nd pharyngeal pouch is seen as supratonsillar/intratonsillar cleft at the upper pole of the tonsil.

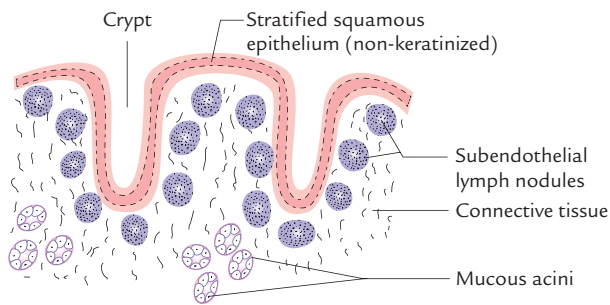


Fig. 14.18 Histological structure of the palatine tonsil. (Source: Fig. 14.6, Page 147, *Selective Anatomy Prep Manual for Undergraduates*, Vol. I, Vishram Singh, Copyright Elsevier 2014, All rights reserved.)

PHARYNGOTYMPANIC TUBE (SYN. EUSTACHIAN TUBE/AUDITORY TUBE)

It is a mucous-lined osseocartilaginous channel, which connects the nasopharynx with the tympanic cavity (Fig. 14.19). It maintains the equilibrium of air pressure on either side of the tympanic membrane for its proper vibration.

In an adult, it is about 36 mm long and runs downwards, forwards, and medially from its tympanic end.

Parts (Fig. 14.9)

The pharyngotympanic tube is divided into two parts, *viz.*

1. **Osseous or bony part:** It is posterolateral part and forms one-third (12 mm) of the total length of the tube. It lies between the tympanic and petrous parts of the temporal bone and opens into the middle ear cavity.
2. **Cartilaginous part:** It is anteromedial part and forms two-third (24 mm) of the tube.

The two parts meet at isthmus, which is the narrowest part of the tube. The cartilaginous part is made of a single piece of elastic fibrocartilage, which is folded upon itself in such a way that it forms the whole of the medial wall, roof, and a

part of the lateral wall. The rest of the lateral wall is filled by the fibrous membrane.

The cartilaginous part lies in the groove between the petrous part of the temporal bone and the posterior border of the greater wing of the sphenoid bone.

Ends of the Tube

The **tympanic end** of the tube is small and bony. It is situated in the anterior wall of the middle ear, a little above its floor.

The **pharyngeal end** is relatively large and slit-like (vertically). It is situated in the lateral wall of the pharynx, about 1.25 cm behind the posterior end of inferior nasal concha. The pharyngeal orifice is the widest part of the tube.

Lining of the Tube

The tube is lined by pseudostratified ciliated columnar epithelium with interspersed goblet cells. The cilia beat in the direction of nasopharynx and thus help to drain the secretions and fluid from the middle ear into the nasopharynx.

Pharyngotympanic Tubes of an Infant and an Adult

The features of the tube differ in infants and adults. These are enumerated in Table 14.4.

Table 14.4 Differences between the eustachian tube of an infant and an adult

	Infant	Adult
Length	18 mm	36 mm
Direction	More or less horizontal (makes an angle of 10° with the horizontal plane)	Oblique, directed downwards, forwards and medially (makes an angle of 45° with the horizontal plane)
Angulation of isthmus	No angulation	Angulation present

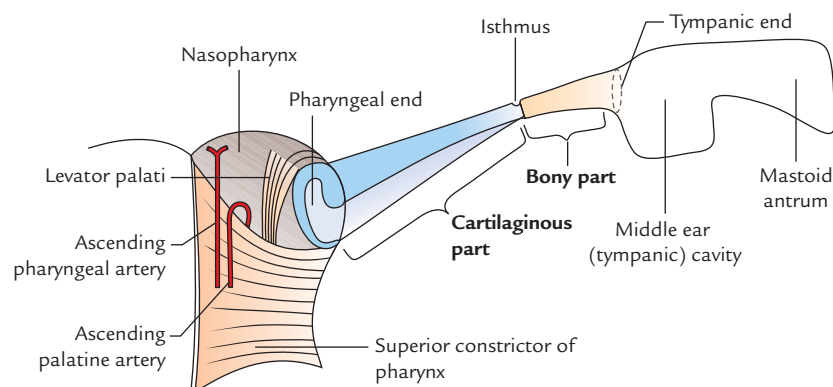


Fig. 14.19 Bony and cartilaginous parts, isthmus, tympanic, and pharyngeal ends of the pharyngotympanic tube.

Clinical correlation

Since the eustachian tube is shorter, wider, and more horizontal in infants, the infection from nasopharynx can easily reach the middle ear; for this reason, **middle ear infections are more common in infants and young children than in adults.**

Functions

The following are the functions of the pharyngotympanic tube:

1. Maintains equilibrium of air pressure on either side of tympanic membrane. At rest, the tube remains closed but during swallowing, yawning, and sneezing it reflexly opens.
2. Protection of middle ear by preventing the transmission of high sound pressure from nasopharynx to middle ear as normally the tube remains closed.
3. Clearance of middle ear secretions by active opening and closing of the tube. The cilia of mucous lining of the tube beat in the direction of nasopharynx and drain the secretion of the middle ear into the nasopharynx.

N.B. An individual swallows once every minute when awake and once every five minutes when asleep.

Clinical correlation

The pharyngotympanic tube equalizes the pressure in the middle ear with the atmospheric pressure to permit free movement of the tympanic membrane. If the tube is blocked due to inflammation of tubal tonsil, the residual air in the middle ear is absorbed into the blood vessels of its mucous membrane, causing a fall of pressure in it and consequent **retraction of tympanic membrane**. This causes disturbance of hearing and severe earache due to retraction of tympanic membrane (RTM). The persistently reduced air pressure within the middle ear is corrected by periodic introduction of air by eustachian catheter.

PALATE

The term *palate* refers to the roof of the mouth (L. *palate* = roof of the mouth). It forms a partition between the nasal and oral cavities.

The palate consists of two parts, *viz.*

1. **Hard palate**, which forms the anterior four-fifth of the palate, and
2. **Soft palate**, which forms the posterior one-fifth of the palate.

HARD PALATE

The hard palate is a partition between the nasal and oral cavities. Its anterior two-third is formed by the palatine

processes of the maxillae and posterior one-third by the horizontal plates of the palatine bones (Fig. 14.20).

The superior and inferior surfaces of the hard palate form the floor of the nasal cavity and the roof of the oral cavity, respectively.

- **Anterolaterally**, the hard palate becomes continuous with the alveolar arches and gums.
- The **posterior margin** of the hard palate is free and provides attachment to the soft palate.

The **inferior surface** of the hard palate presents the following features:

1. **Incisive fossa**, a small pit anteriorly in the midline behind the incisor teeth, into which open the incisive canals. Each incisive canal/foramen (right and left) pierces the corresponding side and ascend into the corresponding nasal cavity. The incisive foramen transmits terminal parts of the nasopalatine nerve and greater palatine vessels.
2. **Greater palatine foramen**, one on each side, lies in the posterolateral corner of the hard palate medial to the last molar tooth. It transmits the greater palatine nerve and vessels.
3. **Lesser palatine foramina** (1–3 in number) on each side are in the pyramidal process of palatine bone and are located just behind the greater palatine foramen. They provide passage to lesser palatine nerve and vessels.
4. **Posterior nasal spine** is a conical projection in the median plane on the sharp free posterior border of the hard palate.
5. **Palatine crest** is a curved ridge near the posterior border of the hard palate.
6. **Masticatory mucosa** is the mucous membrane lining the hard palate. In the anterior part, it is firmly united with the periosteum by multiple fibrous strands (Sharpey's fibres), hence moving bolus of food does not displace the mucous membrane. It presents:
 - (a) *transverse masticatory ridges* on either side of midline, and
 - (b) *palatine raphe*, a narrow ridge of mucous membrane extending anteroposteriorly in the midline from a little papilla overlying the incisive fossa.

The hard palate is lined by keratinized stratified squamous epithelium.

Arterial Supply

This is by greater palatine arteries from the third part of the maxillary artery. Each artery emerges from greater palatine foramen and passes forwards around the palate (lateral to the nerve) to enter the incisive canal and pass up into the nose.

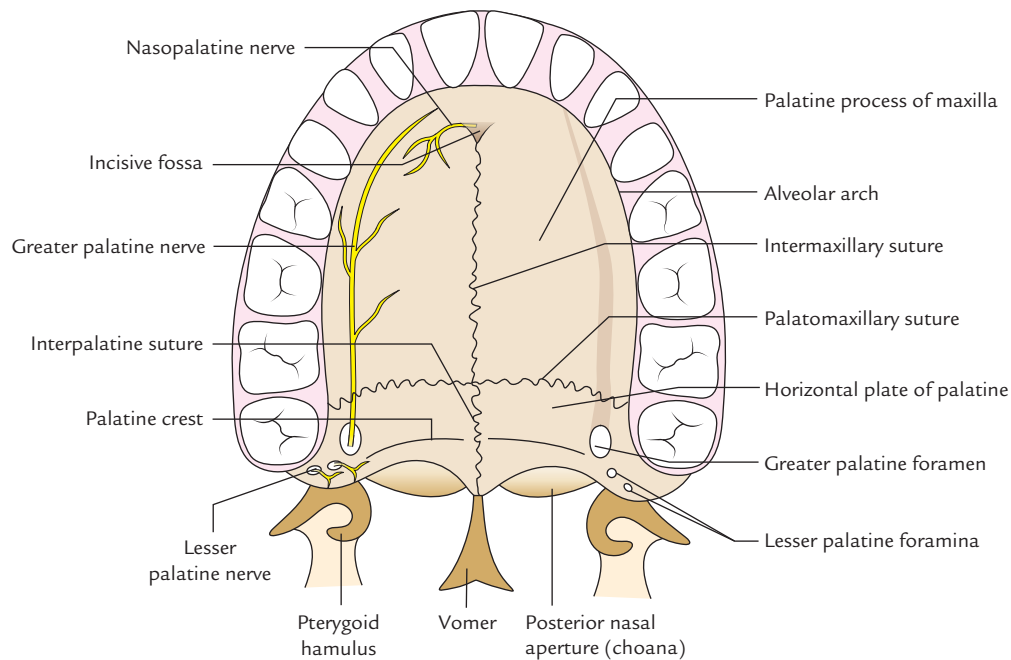


Fig. 14.20 Oral aspect of the hard palate.

Venous Drainage

The veins of hard palate drain into the pterygoid venous plexus (mainly) and pharyngeal venous plexus.

Nerve Supply

The hard palate is supplied by greater palatine and nasopalatine nerves derived from pterygopalatine ganglion. *The greater palatine nerve supplies whole of the palate except anterior part of palate behind incisor teeth (the area of premaxilla), which is supplied by nasopalatine nerves.*

Lymphatic Drainage

The lymphatics from palate drain mostly into the upper deep cervical lymph nodes and few into retropharyngeal lymph nodes.

SOFT PALATE

The soft palate is a mobile muscular flap, which hangs down from the posterior border of the hard palate into the pharyngeal cavity like a curtain or velum. It separates the nasopharynx from oropharynx.

External Features

The soft palate presents the following external features:

1. **Anterior (oral) surface** is concave and marked by a median raphe.
2. **Posterior surface** is convex and continuous with the floor of the nasal cavity.

3. **Superior border** is attached to the posterior border of the hard palate.
4. **Inferior border** is free and forms the anterior boundary of the pharyngeal isthmus. A conical, small, tongue-like projection hanging down from its middle is called **uvula**.

On each side from the base of uvula, two curved folds of mucous membrane extend laterally and downwards:

- (a) The anterior fold merges inferiorly with the side of the tongue (at the junction of oral and pharyngeal parts) and is known as **palatoglossal fold**. The palatoglossal fold contains the palatoglossus muscle and forms the lateral boundary of the oropharyngeal isthmus.
- (b) The posterior fold merges inferiorly with the lateral wall of the pharynx and is known as **palatopharyngeal fold**. The palatopharyngeal fold contains palatopharyngeus muscle and forms the posterior boundary of the tonsillar fossa.

Structure

The soft palate is made up of a fold of mucous membrane enclosing five pairs of muscles. The nasal surface of the soft palate is covered by pseudostratified ciliated columnar epithelium except posteriorly (the part that abuts on the Passavant's ridge of posterior pharyngeal wall), which is lined by non-keratinized stratified squamous epithelium. The oral surface of the soft palate is thicker and lined by non-keratinized stratified squamous epithelium.

In the submucosa on both the surfaces are mucous glands, which are in plenty around the uvula and on the oral aspect of the soft palate. The mucosa on the oral surface of the soft

palate also contains some taste buds (especially in children) and lymphoid follicles.

Muscles

The soft palate consists of the five pairs of muscles (Fig. 14.21), *viz.*

1. Tensor palati (tensor veli palatini).
2. Levator palati (levator veli palatini).
3. Palatoglossus.
4. Palatopharyngeus.
5. Musculus uvulae.

N.B. All the muscles of soft palate are extrinsic except musculus uvulae, which are intrinsic.

The origin, insertion, and actions of muscles of the soft palate are given in Table 14.5.

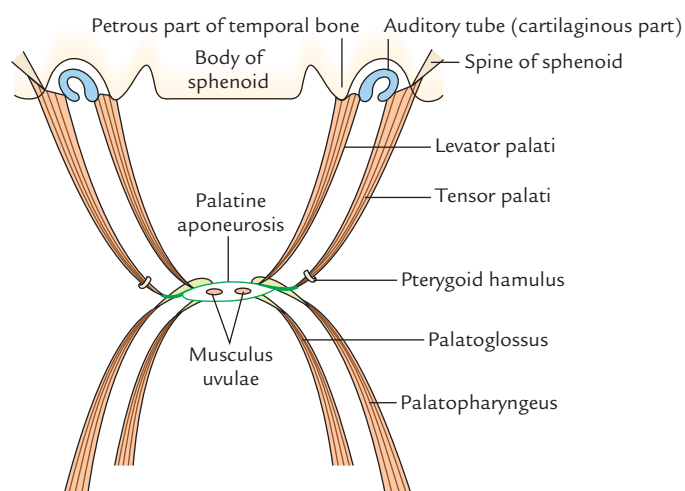


Fig. 14.21 Muscles of the soft palate.

Table 14.5 Origin, insertion, and actions of muscle of the soft palate

Muscle	Origin	Insertion	Actions
Tensor palati (thin triangular muscle; Fig. 14.22)	(a) Lateral aspect of the cartilaginous part of the auditory tube (b) Adjoining part of the greater wing of the sphenoid including its spine	Muscle descends, converges to form a tendon, which hooks around the pterygoid hamulus and then expands to form the palatine aponeurosis for attachment to: <ul style="list-style-type: none"> • Posterior border of the hard palate • Inferior surface of the hard palate behind the palatine crest 	(a) Tightens the soft palate (b) Helps in opening the auditory tube
Levator palati (a cylindrical muscle lying deep to tensor palati)	(a) Medial aspect of the cartilaginous part of the auditory tube (b) Adjoining part of the petrous temporal bone (inferior surface of its apex anterior to carotid canal)	Muscle runs downwards and medially and spreads out to be inserted on the upper surface of the palatine aponeurosis	(a) Elevates the soft palate to close the pharyngeal isthmus (b) Helps in opening the auditory tube
Musculus uvulae (a longitudinal muscle strip, one on either side of the median plane within the palatine aponeurosis)	(a) Posterior nasal spine (b) Palatine aponeurosis	Mucous membrane of the uvula	Pulls the uvula forward to its own side
Palatoglossus	Oral surface of the palatine aponeurosis	Descends into palatoglossal arch, to be inserted into the side of the tongue at the junction of its oral and pharyngeal parts	(a) Pulls up the root of the tongue (b) Approximates the palatoglossal arches to close the oropharyngeal isthmus
Palatopharyngeus (consist of two fasciculi, which are separated by the levator palati)	(a) Anterior fasciculus: from posterior border of the hard palate (b) Posterior fasciculus: from palatine aponeurosis	Descends in the palatopharyngeal arch and inserted into the <ul style="list-style-type: none"> • Median fibrous raphe of pharyngeal wall • Posterior border of the lamina of thyroid cartilage 	Raises the walls of pharynx and larynx during swallowing

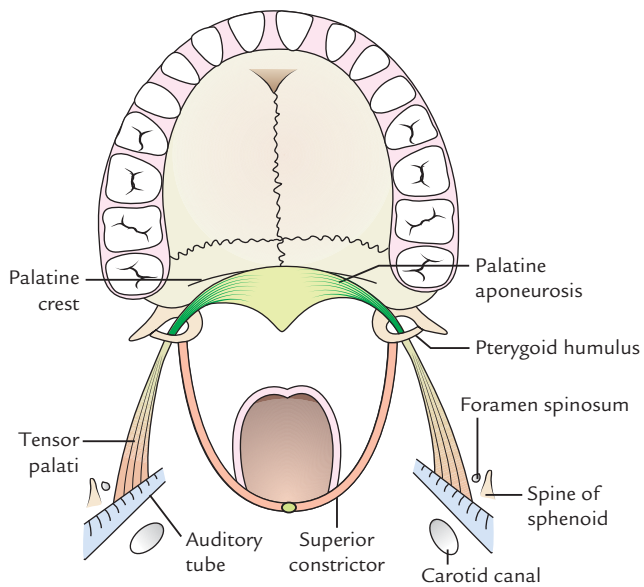


Fig. 14.22 Origin and course of the tensor palati muscles and formation of the palatine aponeurosis by the expansion of their tendons underneath the hard palate behind the palatine crest.

Functions

1. Separates the oropharynx from nasopharynx during swallowing so that food does not enter the nose.
2. Isolates the oral cavity from oropharynx during chewing so that breathing is not affected.
3. Helps to modify the quality of voice, by varying the degree of closure of the pharyngeal isthmus.
4. Protects the damage of nasal mucosa during sneezing, by appropriately dividing and directing the blast of air through both nasal and oral cavities.
5. Prevents the entry of sputum into nose during coughing by directing it into the oral cavity.

Clinical correlation

Paralysis of soft palate: The paralysis of the muscles of soft palate (due to lesion of vagus nerve) produces:

- (a) nasal regurgitation of liquids,
- (b) nasal twang in voice,
- (c) flattening of the palatal arch on the side of the lesion, and
- (d) deviation of uvula, opposite to the side of the lesion.

Arterial Supply

The soft palate is supplied by the following arteries:

1. Lesser palatine branches of the maxillary artery.
2. Ascending palatine branch of the facial artery.
3. Palatine branches of the ascending pharyngeal artery.

Venous Drainage

The venous blood from palate is drained into pharyngeal venous plexus and pterygoid venous plexus.

Lymphatic Drainage

The lymphatics from soft palate drain into retropharyngeal and upper deep cervical lymph nodes.

Nerve Supply

Motor supply: All the muscles of soft palate are supplied by the cranial root of accessory nerve via pharyngeal plexus except tensor palati, which is supplied by the nerve to medial pterygoid, a branch of the mandibular nerve.

Sensory supply: General sensations from palate are carried by:

- Lesser palatine nerves to the maxillary division of trigeminal nerve via pterygopalatine ganglion.
- Glossopharyngeal nerve.

Clinical correlation

Gag reflex: It is a protective reflex characterized by the elevation of the palate and contraction of the pharyngeal muscles with associated *retching and gagging* in response to stimulation of the mucous membrane of the oropharynx. It occurs when the palate, tonsil, posterior part of the tongue, or posterior pharyngeal wall are touched by unfamiliar objects such as swab, spatula, etc. The afferent limb of the reflex is provided by the glossopharyngeal nerve and efferent limb by the vagus nerve.

DEVELOPMENT OF THE PALATE

The face develops from five processes, which surround the primitive mouth or stomatodeum. The processes are as follows (Fig. 14.23):

1. Frontonasal process – a single process.
2. Maxillary processes (two) – one on each side.
3. Mandibular processes (two) – one on each side.

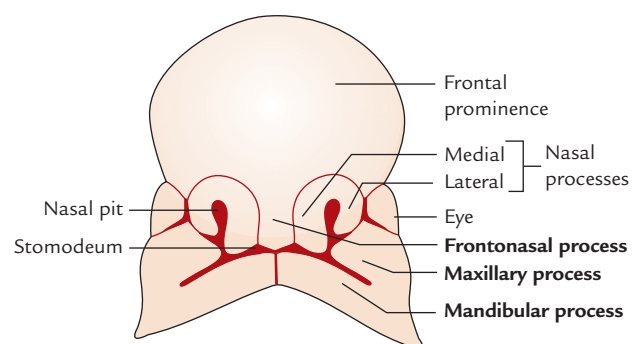


Fig. 14.23 Development of the face. Note the five processes around the primitive mouth (stomatodeum).

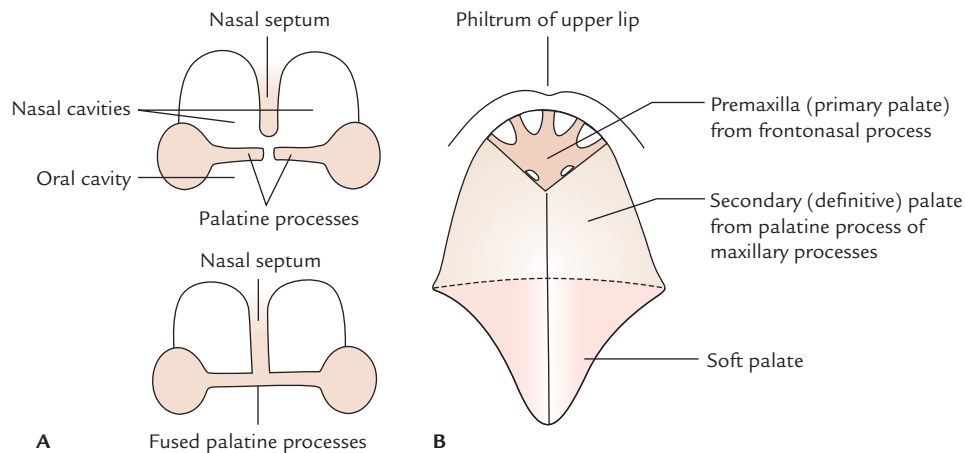


Fig. 14.24 Development of the palate: **A**, separation of the nasal cavities from each other and from oral cavity; **B**, embryological subdivisions of the palate and their source of development.

The primary palate (also called *premaxilla*) develops from the frontonasal process. The secondary palate develops from the palatine process of the maxillary processes.

Two palatine processes (one on each side) develop from the inner aspects of the maxillary processes and fuse in the midline to form the **secondary palate**, which is soon joined by nasal septum (Fig. 14.24).

The hard palate is formed by the fusion of the secondary palate with the primary palate. The incisive foramina mark the junction of the two components of the palate. The fusion takes place from anterior to posterior parts.

The soft palate develops from two folds that grow posteriorly from the posterior edge of the palatal processes. Thus uvula is the last structure to develop. The two folds unite to form the soft palate.

Clinical correlation

Cleft palate (Fig. 14.25): The defective fusion of various segments of the palate gives rise to clefts in the palate. These vary considerably in degree, leading to varieties of cleft palate, namely,

(a) Complete cleft

- *Unilateral complete cleft* occurs if maxillary process on one side does not fuse with the premaxilla. It is always associated with the cleft lip.
- *Bilateral complete cleft* occurs if both the maxillary processes fail to fuse with the premaxilla. In this type, secondary palate is divided into two equal halves by a median cleft with an anterior V-shaped cleft separating the premaxilla completely.

(b) Incomplete or partial cleft: The following stages may occur

- Bifid uvula—cleft involving only uvula. It is of no clinical importance.
- Cleft of soft palate—involving uvula and soft palate.
- Cleft of soft palate—extending into the hard palate.

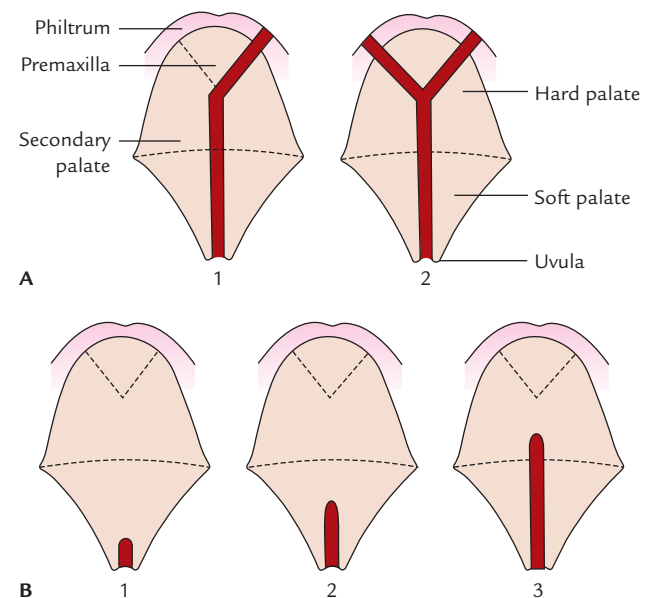


Fig. 14.25 Varieties of the cleft palate: **A**, complete cleft: 1 = unilateral, 2 = bilateral; **B**, partial cleft: 1 = bifid uvula, 2 = cleft soft palate, 3 = cleft of soft palate extending into the hard palate.

Golden Facts to Remember

▶ Killian's dehiscence	A weak area in the posterior wall of pharynx between the two parts of inferior constrictor muscle
▶ Principal artery of tonsil	Tonsillar branch of the facial artery
▶ Common source of bleeding after tonsillectomy	Paratonsillar vein
▶ Tonsillar lymph node	Jugulodigastric lymph node
▶ Most common variety of cleft palate	Unilateral cleft palate involving the hard palate
▶ Largest tonsils	Palatine tonsils
▶ Quinsy	Chronic infection of peritonsillar space
▶ Coffin corner	Lingual tonsillar sulcus

Clinical Case Study



Case 1

A 47-year-old man came in the emergency OPD and complained that while eating fish something got stuck in his throat. It was causing pain and lot of discomfort. The physical examination of throat revealed that discomfort increases on moving the thyroid cartilage from side to side. The physician concluded that the fish bone was stuck in the piriform fossa.

Questions

1. What is piriform fossa?
2. What are medial and lateral boundaries of the piriform fossa?
3. What nerve is likely to be injured during the removal of the fish bone?

Answers

1. Recess in the lateral wall of laryngopharynx, one on either side of laryngeal inlet.
2. Piriform fossa is bounded medially by aryepiglottic fold and quadrangular membrane of the larynx and laterally by inner surface of the thyrohyoid membrane and lamina of thyroid cartilage.
3. Internal laryngeal nerve.

Case 2

An 8-year-old boy was taken by his parents to the physician and complained that their son was suffering from recurrent attacks of sore throat and for the past few days he has difficulty in swallowing and feeling pain not only in his throat but also in his ears. On examination of oropharynx, the physician found that both the tonsils were enlarged and almost touching each other in the midline. The palpation of cervical lymph nodes revealed enlarged and tender tonsillar nodes. The boy was diagnosed as a case of *tonsillitis*.

Questions

1. What is meant by the term tonsil?
2. What are tonsillar lymph nodes?
3. What was the cause of ear ache?

Answers

1. Unless otherwise stated, reference to tonsil always refers to the palatine tonsil.
2. Jugulodigastric lymph nodes.
3. The tonsil is supplied by the glossopharyngeal nerve and tympanic branch of this nerve supplies mucous membrane of the middle ear (tympanic cavity). Therefore pain of tonsillitis is referred to the ear.

Larynx

The larynx is the upper expanded part of the lower respiratory tract, which is modified for producing voice, hence it is also called **voice box/organ of phonation**. It acts as a sphincter at the inlet of lower respiratory tract to protect the trachea and the bronchial tree from entry of any material other than the air. If this protective role is deranged, laryngeal incompetence results, and food and fluid may be aspirated into trachea. Further, the upward and downward movements of the larynx help in swallowing.

The **functions** of larynx include the following:

1. Phonation.
2. Respiration.
3. Protection.
4. Deglutition.

N.B. The primary (most important) function of the larynx is protection of the lower respiratory tract. The phonation has developed later with evolution and is related to the motor speech area of the brain.

Location and Extent

The larynx is situated in the anterior midline of the upper part of the neck in front of laryngopharynx. It extends from the root of the tongue to the trachea and lies in front of the 3rd, 4th, 5th, and 6th cervical vertebrae. However, in children and females it lies at a little higher level.

Size

The average measurements of larynx in males and females are as follows:

	Vertical	Transverse	Anteroposterior
Male	44 mm	43 mm	36 mm
Female	36 mm	41 mm	26 mm

Till puberty the size of larynx in both males and females is more or less same but at puberty male larynx grows rapidly and becomes larger than the female larynx. The pubertal

growth of the larynx in adult female does not differ much from a child, for this reason the pitch of voice is high in both females and children. In males, the characteristic pubertal growth of angle of the thyroid cartilage (*Adam's apple*) makes the voice louder and low pitched.

SKELETON (Fig. 15.3)

The skeletal framework of the larynx consists of a series of cartilages, which are connected to one another by ligaments, and fibrous membranes, and moved by a number of muscles.

N.B. The hyoid bone is closely associated to the larynx with distinctive functional roles. However, it is usually considered as a separate structure.

CARTILAGES

The larynx is composed of nine cartilages, of which three are unpaired and three are paired:

1. **Unpaired cartilages:** The unpaired cartilages are large and comprise:
 - (a) Thyroid
 - (b) Cricoid
 - (c) Epiglottis
2. **Paired cartilages:** The paired cartilages are small and comprise:
 - (a) Arytenoid
 - (b) Corniculate
 - (c) Cuneiform

The **principal cartilages of the larynx** are, cricoid, thyroid, and two arytenoids (Fig. 15.1).

Thyroid cartilage

It is most prominent and acts as a shield to protect the larynx from the front. It consists of two quadrilateral laminae, which meet in front at an angle called **thyroid angle**, which is acute in males and obtuse in females (like subpubic angle). The angle measures 90° in males and 120° in females.

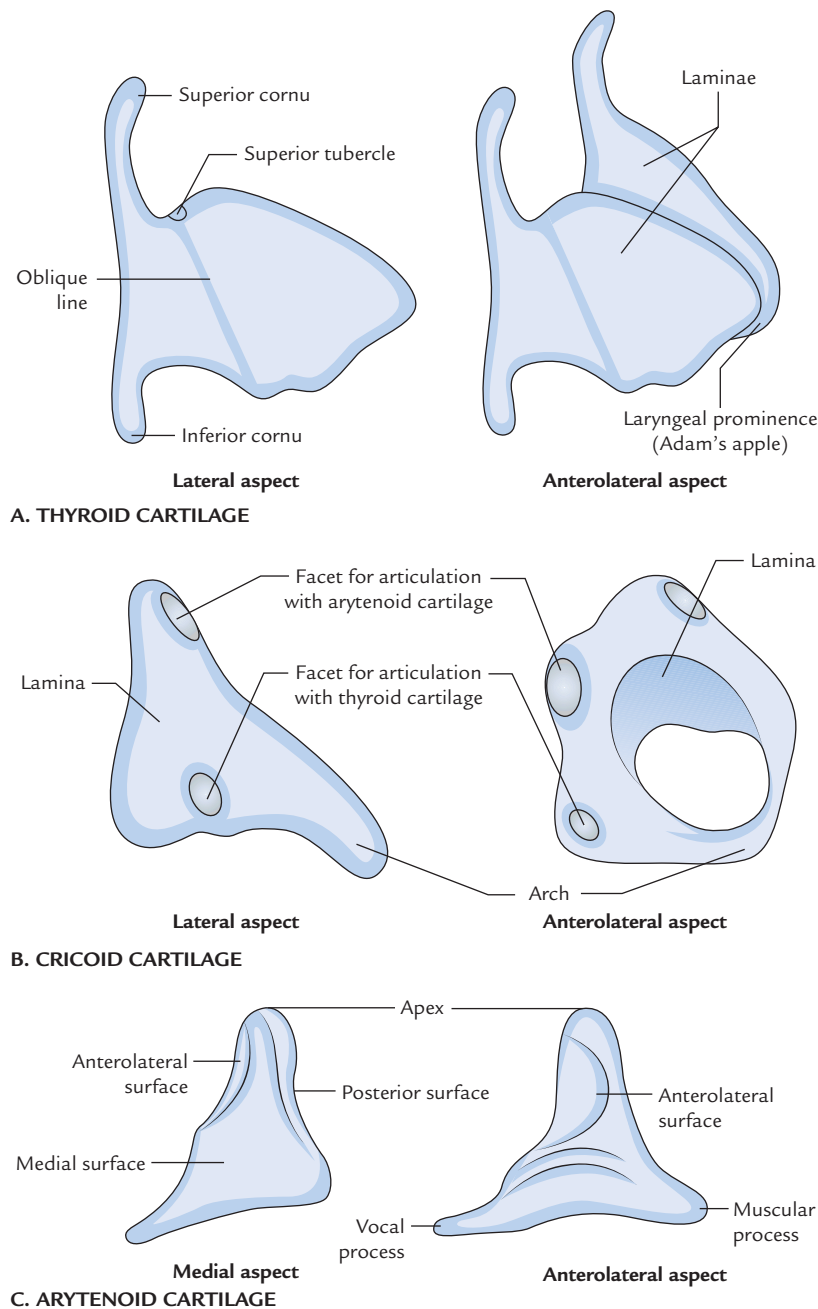


Fig. 15.1 Principal cartilages of the larynx.

The thyroid angle is prominent in males and it is responsible for prominence on the front of the neck called **Adam's apple**.

The posterior surface of the thyroid cartilage in the median plane provides attachment (from above downward) to following structures (Fig. 15.2A):

1. Thyroepiglottic ligament.
2. A pair of vestibular ligaments.
3. A pair of vocal ligaments.

The **posterior border of each lamina** is free and prolonged upwards and downwards as *superior and inferior horns/cornu*. It provides conjoined insertion to the following three muscles (Fig. 15.2B):

1. Palatopharyngeus.
2. Salpingopharyngeus.
3. Stylopharyngeus.

The **outer surface of each lamina** presents an oblique line and provides attachment to the following three muscles; from

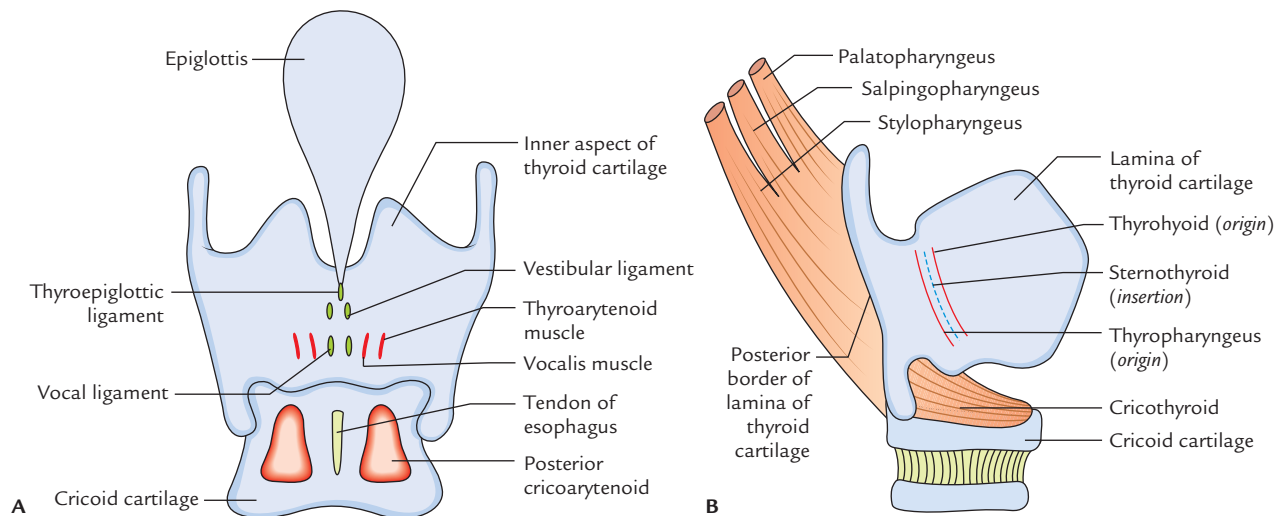


Fig. 15.2 Attachments of the muscles and ligaments on the thyroid cartilage: **A**, on the posterior surface; **B**, on the outer surface and posterior border of the lamina.

above downwards and from medial to lateral sides, these are (Fig. 15.2B) as follows:

1. Thyrohyoid.
2. Sternothyroid.
3. Inferior constrictor (thyropharyngeus part only).

Cricoid cartilage

This is a signet-shaped ring of cartilage with a narrow anterior arch and a broad posterior lamina. The cricoid cartilage is situated at the level of C6 vertebra and **completely encircles the lumen of the larynx**. It is considered as the **foundation stone of the larynx**. The posterior surface of lamina presents a median ridge and two depressed areas on each side of this ridge.

Epiglottis (Fig. 15.3)

It is leaf-like and extends up behind the hyoid bone and the base of the tongue. Its broad upper end is free and forms the upper boundary of the laryngeal inlet, while the lower end (stalk) is pointed and connected to the posterior surface of the angle of the thyroid by *thyroepiglottic ligament*.

The anterior surface of epiglottis is connected with the base of the tongue by median and lateral glossoepiglottic folds. The depression on each side of the median fold is called **vallecula**.

The posterior surface of epiglottis presents a tubercle in its lower part.

N.B. The epiglottis is rudimentary in human beings but in macrosomatic animals it is elongated and extends beyond the soft palate in the nasopharynx.

Arytenoid cartilages

The paired arytenoid cartilages articulate with the lateral parts of the upper border of cricoid lamina. Each arytenoid cartilage is pyramidal and presents an apex, base, three

surfaces (posterior, anterolateral, and medial), and two processes—muscular and vocal (Fig. 15.1).

The **muscular process** projects laterally and backwards whereas the **vocal process** is directed forwards.

The **base** of arytenoid cartilage is concave and articulates with the upper border of the lamina of cricoid cartilage. The base is prolonged anteriorly to form the *vocal process* and laterally to form the *muscular process*.

The **apex** is curved posteromedially and articulates with the corniculate cartilage.

Corniculate cartilages (of Santorini)

These are two small conical nodules, which articulate with the apices of the arytenoid cartilages. They are directed posteromedially and lie in the posterior parts of the aryepiglottic folds.

Cuneiform cartilages (of Wisberg)

They are tiny rod-shaped cartilages lying in the posterior parts of the aryepiglottic folds just above the corniculate cartilages.

TYPES OF LARYNGEAL CARTILAGES

The thyroid, cricoid, and basal parts of arytenoid cartilages are composed of **hyaline cartilage** and tend to ossify after 25 years of age and can be seen in radiographs.

The apices of arytenoid cartilages and other cartilages—epiglottis, corniculate, and cuneiform are made up of **elastic cartilage** and do not ossify.

JOINTS

The laryngeal joints include paired cricothyroid, cricoarytenoid, and arytenocorniculate joints (Fig. 15.4).

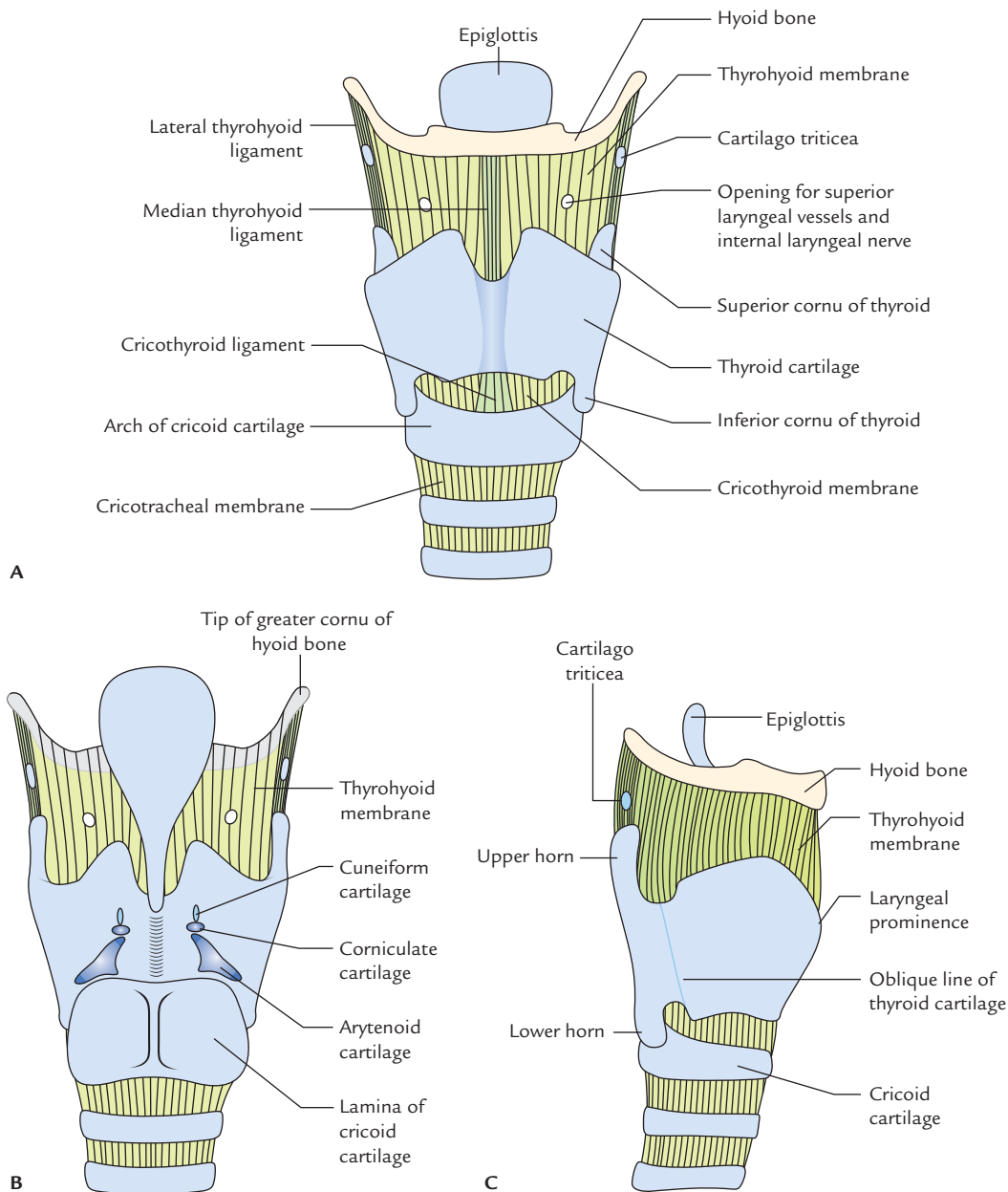


Fig. 15.3 Skeleton of the larynx: A, anterior view; B, posterior view; C, lateral view.

CRICOTHYROID JOINT

It is a plane synovial joint between the inferior cornu of the thyroid cartilage and side of cricoid cartilage. The recurrent laryngeal nerve enters the larynx very close to this joint. This joint permits two types of movements, *viz.*

1. **Rotatory movement**, in which cricoid rotates on the inferior cornua of the thyroid cartilage around a transverse axis, which passes transversely through both cricothyroid joints.
2. **Gliding movement**, in which cricoid glides, to a limited extent, in different directions of the thyroid cornua.

CRICOARYTENOID JOINT

It is a tiny plane synovial joint between the base of the arytenoid and lateral part of the upper border of the lamina of cricoid cartilage. This joint permits two types of movements, *viz.*

1. **Rotatory movement**, in which arytenoid cartilage moves around a vertical axis, thus abducting or adducting the vocal cords.
2. **Gliding movement**, in which one arytenoid glides towards the other or away from it, thus closing or opening the posterior part of glottis.

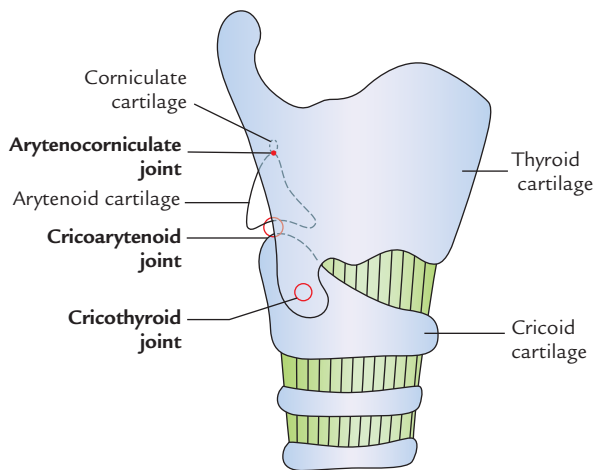


Fig. 15.4 Joints of the larynx.

ARYTENOCORNICULATE JOINT

It is a synovial joint between the arytenoid and corniculate cartilages. It is of no functional significance.

LIGAMENTS AND MEMBRANES

The skeletal framework of the larynx is interconnected by a number of ligaments and fibrous membranes. The most significant fibrous membranes connecting skeletal framework of the larynx are thyrohyoid, cricothyroid, quadrangular, and cricovocal membranes.

EXTRINSIC

The extrinsic ligaments and membranes are outside the inner tube of the fibroelastic tissue of laryngeal cavity (Fig. 15.3):

1. **Thyrohyoid membrane and ligaments:** The thyrohyoid membrane extends from the upper border of the thyroid cartilage to the upper border of the hyoid bone. It ascends behind the concave posterior surface of the hyoid bone. Between posterior aspect of hyoid and membrane lies the *subhyoid bursa*. In the median and lateral parts, the thyrohyoid membrane thickens to form *median and lateral thyrohyoid ligaments*. The lateral thyrohyoid ligament on each side contains a small nodule of elastic cartilage called *cartilago-triticea*. The thyrohyoid membrane is pierced on either side by internal laryngeal nerve and superior laryngeal vessels.
2. **Cricotracheal ligament:** It connects the cricoid cartilage with the first tracheal ring.
3. **Thyroepiglottic ligament:** It attaches the lower narrow end of epiglottis to the posterior surface of thyroid angle.
4. **Hyoepiglottic ligament:** It connects the posterior aspect of hyoid with the anterior surface of the upper end of epiglottis.

5. **Cricothyroid ligament:** It connects the lower border of the thyroid cartilage to the cricoid cartilage in the midline.

INTRINSIC

The intrinsic ligaments and membranes are the parts of a broad sheet of fibroelastic tissue, which forms the inner tube of the laryngeal cavity outside its mucous lining. This fibroelastic tube is, however, interrupted on each side by the sinus of the larynx. The part above the sinus is called **quadrangle** or **quadrangular membrane** and part below the sinus is called **cricovocal membrane** or **conus elasticus** (Fig. 15.5):

1. **Cricovocal membrane** extends upwards and medially from the upper border of the arch of the cricoid cartilage. Its upper edge is free and attached anteriorly to the posterior surface of the thyroid cartilage and posteriorly to the vocal process of the arytenoid cartilage. It is slightly thickened to form the **vocal ligament**. The fold of mucous membrane over this ligament forms the **vocal fold**.
2. **Vocal ligament** is made up of yellow elastic tissue and extends anteroposteriorly from posterior surface of the thyroid cartilage to the vocal process of arytenoids cartilage.
3. **Quadrangular membrane** extends from sides of epiglottis to the arytenoids. Its lower edge is free and attached anteriorly to the posterior surface of the thyroid cartilage (above the cricothyroid membrane) and posteriorly to

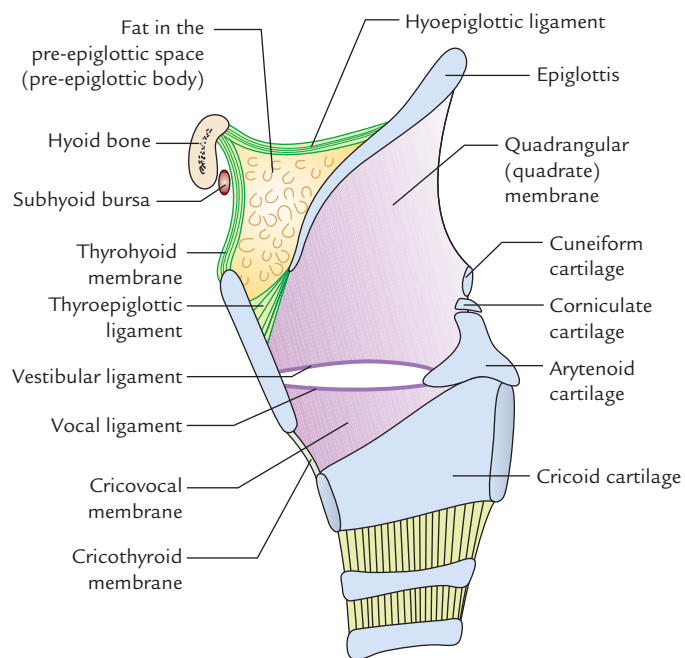


Fig. 15.5 Sagittal section of the larynx showing ligaments and membranes. Note the location of quadrangular and cricovocal membranes.

Table 15.1 Extrinsic and intrinsic membranes and ligaments of the larynx

	Extrinsic	Intrinsic
Membranes	<ul style="list-style-type: none"> • Thyrohyoid 	<ul style="list-style-type: none"> • Cricovocal (conus elasticus)
	<ul style="list-style-type: none"> • Cricotracheal 	<ul style="list-style-type: none"> • Quadrate/Quadrangular
Ligaments	<ul style="list-style-type: none"> • Median and lateral thyrohyoid 	<ul style="list-style-type: none"> • Vocal
	<ul style="list-style-type: none"> • Cricothyroid 	<ul style="list-style-type: none"> • Vestibular
	<ul style="list-style-type: none"> • Cricotracheal 	

the lateral surface of the arytenoid cartilage (in front of muscular process). Its lower edge is thickened to form the **vestibular ligament**.

4. **Vestibular ligament** is made up of fibrous tissue and extends anteroposteriorly from posterior surface of the thyroid cartilage to the lateral surface of the arytenoid cartilage.

Extrinsic and intrinsic membranes and ligaments are summarized in Table 15.1.

MUSCLES

They are of two types: extrinsic and intrinsic.

EXTRINSIC

They attach the larynx to the surrounding structures and are responsible for the movement of the larynx as a whole.

All the extrinsic muscles are paired and include:

1. Palatopharyngeus.
2. Salpingopharyngeus.
3. Stylopharyngeus.
4. Thyrohyoid.
5. Sternothyroid.

All these muscles elevate the larynx except sternothyroid, which depresses the larynx.

The first three muscles are discussed in detail in Chapter 14 and the last two in Chapter 6.

INTRINSIC (Fig. 15.6)

They attach the laryngeal cartilages to each other and are responsible for their movements. Their main functions are to:

- (a) open or close the laryngeal inlet,
- (b) adduct and abduct the vocal cords, and
- (c) increase or decrease the tension of the vocal cords.

Thus according to their actions, intrinsic muscles of the larynx are arranged into the following groups:

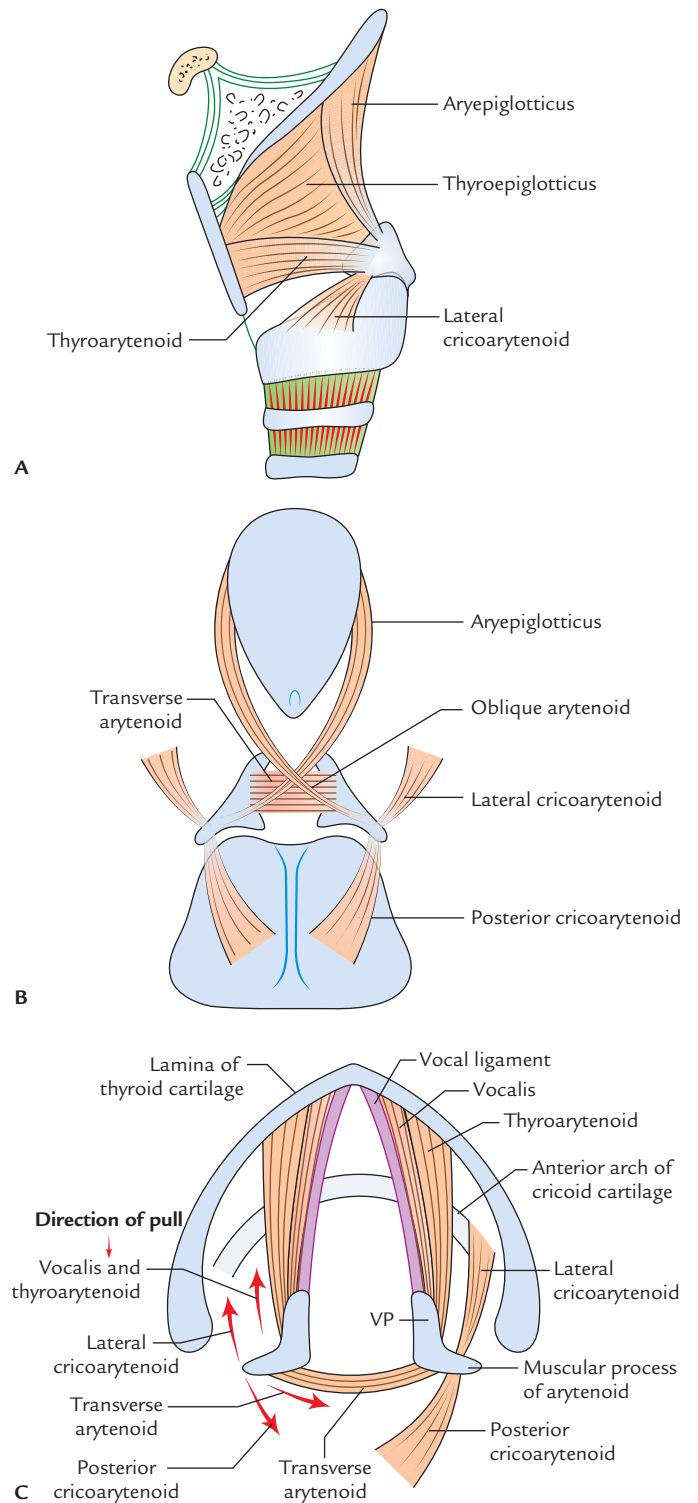


Fig. 15.6 Intrinsic muscles of the larynx: **A**, lateral view; **B**, posterior view; **C**, direction of pull of some intrinsic muscles (VP = vocal process of arytenoid).

Muscles that Open or Close the Laryngeal Inlet

1. Oblique arytenoids
 2. Aryepiglotticus
 3. Thyroepiglotticus: opens the inlet of larynx.
- } Closes the inlet of larynx.

Muscles that Abduct or Adduct the Vocal Cords

1. Posterior cricoarytenoids: abduct the vocal cords.
2. Lateral cricoarytenoids: adduct the vocal cords.
3. Transverse arytenoid: adduct the vocal cords.

Muscles that Increase or Decrease the Tension of Vocal Cords

1. Cricothyroid: tenses the vocal cords.
2. Vocalis: tenses the vocal cords.
3. Thyroarytenoid: relaxes the vocal cords.

N.B. All the intrinsic muscles of the larynx are paired except transverse arytenoid, which is unpaired.

The origin and insertion of the intrinsic muscles are presented in Table 15.2.

The student need not remember the origin and insertion of all the intrinsic muscles. However, they should know about a few muscles in detail. These are described in following text.

Cricothyroid Muscle

It is the only muscle of the larynx, which lies on the **external surface of the larynx**.

It is a small *fan-shaped* muscle, which arises from the *anterolateral aspect of the cricoid*. After origin, its fibres pass backwards and upwards, to be inserted into the inferior cornu and adjacent lower border of the lamina of the thyroid cartilage. It is supplied by **external laryngeal nerve**. Its contraction makes the thyroid cartilage to tilt slightly downwards and forwards at the cricothyroid joints, thereby *lengthening and tensing the vocal cord* (Fig. 15.7). It also helps in *adduction of vocal cord*.

The whole thyroid cartilage can move downwards and forwards over the cricoid like the Visor of a knight's helmet (Grant).

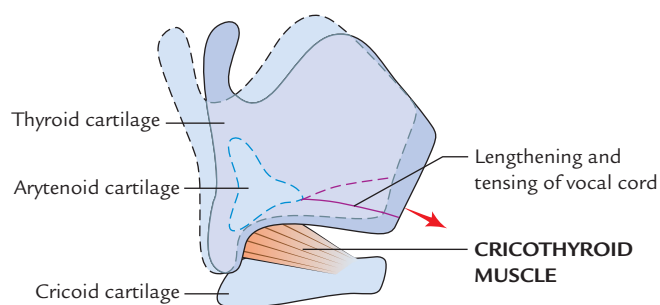


Fig. 15.7 Action of the cricothyroid muscle.

Table 15.2 Origin and insertion of muscles of the larynx

Muscle	Origin	Insertion
Cricothyroid (a triangular muscle)	Anterolateral part of the arch of the cricoid cartilage	Fibres pass backwards and upwards to be inserted into: (a) inferior cornu, and (b) adjacent part of the lower border of lamina of the thyroid cartilage
Oblique arytenoid	Muscular process of one arytenoid cartilage	Apex of opposite arytenoid cartilage
Aryepiglotticus (a slender elongated slip of the upper fibres of oblique arytenoid, which continue in aryepiglottic fold to reach the margin of epiglottis)	Muscular process of arytenoid cartilage	Margin of epiglottis
Transverse arytenoid (rectangular muscle) connects the posterior surfaces of two arytenoid cartilages	Posterior surface of one arytenoid	Posterior surface of another arytenoid
Lateral cricoarytenoid (a triangular muscle)	Lateral part of upper border of cricoid arch	Front of muscular process of the arytenoid cartilage
Posterior cricoarytenoid (a triangular muscle)	Posterior surface of cricoid lamina lateral to median ridge	Back of muscular process of the arytenoid cartilage
Thyroarytenoid	Posterior aspect of angle of the thyroid cartilage	Anterolateral surface of the arytenoid cartilage
Thyroepiglotticus (some upper fibres of thyroarytenoid curve upwards into aryepiglottic fold to reach the margin of epiglottis)	Posterior aspect of angle of the thyroid cartilage	Margin of epiglottis

Clinical correlation

The cricothyroid is an important muscle for the *tone and pitch of the voice*. When sound is about to be produced, it tenses the vocal cord and makes it ready to vibrate like a tuning fork. Hence it is also known as the **tuning fork of larynx**. Paralysis of this muscle following external laryngeal nerve lesion alters the voice quite significantly and is especially noticeable in singers.

Vocalis Muscle

1. It is the *detached medial part of the thyroarytenoid* and lies within the vocal fold just lateral and cranial to the vocal ligament. It arises from the *thyroid angle and anterior part of vocal ligament* and inserted into the lateral surface of the vocal process (Fig. 15.8). On its contraction the anterior part of vocal ligament tenses whereas its posterior part is relaxed.
2. It is supplied by the recurrent laryngeal nerve.
3. The segmental tension of vocal ligament helps in the **modulation of voice** like the fingers of a violinist.

Posterior Cricoarytenoid

1. It is a **triangular muscle**, which arises from the **posterior surface of the cricoid lamina** lateral to its median ridge. After origin, the fibres pass upwards and laterally to be inserted into the back of the muscular process of the arytenoid.
2. It is supplied by **recurrent laryngeal nerve**.
3. The posterior cricoarytenoid **abducts the vocal cords**.

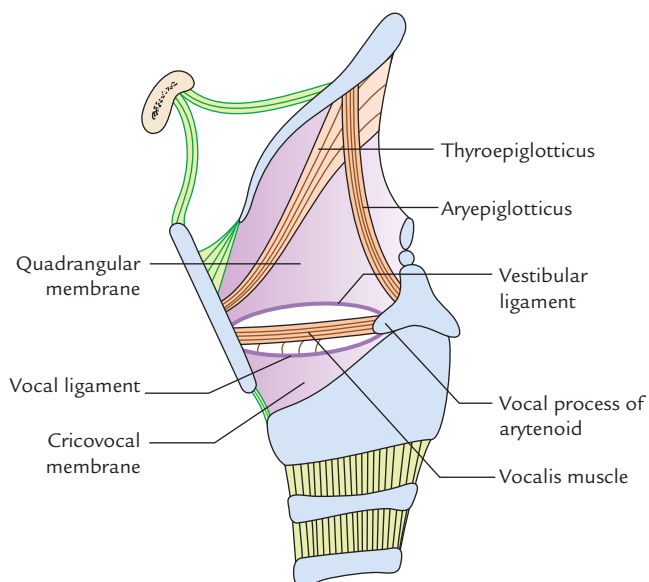


Fig. 15.8 Origin and insertion of the vocalis muscle.

Clinical correlation

Safety muscles of larynx: The posterior cricoarytenoid muscles are the only intrinsic muscles of the larynx, which abduct the vocal cords to allow entry of air through rima glottidis in the respiratory tract below it.

When posterior cricoarytenoids contract, muscular processes of both the arytenoid cartilages rotate medially. As a result, the vocal processes rotate laterally (abducting vocal cords) providing wide diamond-shaped opening of the glottis.

If posterior cricoarytenoids are paralyzed, the adductor muscles (of vocal cords) take the upper hand and the person might die due to lack of air. Hence the posterior cricoarytenoid muscles are called *safety muscles of the larynx*.

Nerve Supply

All the intrinsic muscles of the larynx are supplied by recurrent laryngeal nerve *except* cricothyroid, which is supplied by the external laryngeal nerve.

Clinical correlation

- **Damage of external laryngeal nerve:** *If it is damaged*, there is some weakness of phonation due to loss of tightening effect of cricothyroid muscle on the vocal cords.
- **Damage of recurrent laryngeal nerve:** *It is often damaged*, accidentally during partial thyroidectomy:
 - (a) *If damaged unilaterally*, the vocal cord on the affected side lies in paramedian position (between abduction and adduction) and does not vibrate. But, usually the other cord is able to compensate and the phonation is not much affected. The sound (normal) produced by vocal cords move freely and even cross the midline to meet the paralyzed vocal cord;
 - (b) *If damaged bilaterally*, both the vocal cords lie in the paramedian position with consequent loss of phonation and difficulty in breathing.
- **Damage of both recurrent and external laryngeal nerves:** If the recurrent and external laryngeal nerves are *involved on both sides*, the vocal cords are further abducted and fixed due to paralysis of all intrinsic muscles of the larynx. This is known as the *cadaveric position of vocal cords or rima glottidis*.

N.B.

Exceptions:

- The cricothyroid is the *only muscle* lying on the outer aspect of the larynx.
- All the intrinsic muscles of the larynx are paired *except* transverse arytenoid (interarytenoid), which is unpaired.
- All the intrinsic muscles of larynx adduct the vocal cords *except* posterior cricoarytenoids, which abduct the vocal cords.

CAVITY

It extends from inlet of larynx, where it communicates with the lumen of laryngopharynx to the lower border of the cricoid cartilage, where it is continuous with the lumen of the trachea. The anterior wall of laryngeal cavity is longer than the posterior wall.

Laryngeal inlet is obliquely placed, sloping downwards and backwards. It opens into the laryngopharynx.

Boundaries

<i>Anterior:</i>	Epiglottis.
<i>Posterior:</i>	Interarytenoid fold of the mucous membrane.
<i>Lateral (on each side):</i>	Aryepiglottic fold of the mucous membrane.

Within the laryngeal cavity, **two pairs of folds** of the mucous membrane extend (on each side) posteroanteriorly from arytenoid cartilage to the thyroid cartilage:

1. The upper folds are produced by vestibular ligament and called **vestibular folds** or **false vocal cords**. The space between vestibular folds is called **rima vestibuli**. When the vestibular folds come together, they prevent food and liquids from entering the larynx and air from leaving the lungs, as when a person holds his breath.
2. The lower folds are produced by the vocal ligaments and vocalis muscle, and called **vocal folds** or **true vocal cords**. They extend from the middle of the thyroid angle to the vocal processes of arytenoids. The space between the right and left vocal folds is called **rima glottidis**. The rima glottidis is the narrowest part of the laryngeal cavity.

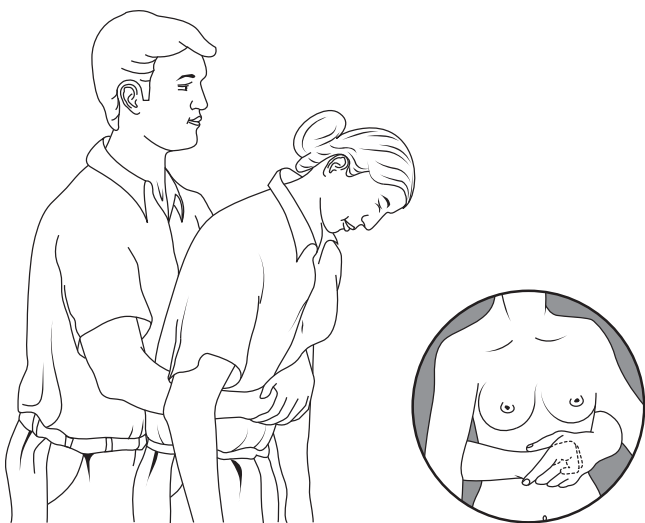


Fig. 15.9 Heimlich maneuver. Figure in the inset shows the position of hands in the epigastric region of the victim.

Clinical correlation

Laryngeal obstruction: The mucous membrane of the superior part of larynx is very sensitive. When foreign body (a piece of food or a drop of water etc.) enters into the laryngeal inlet it causes immediate explosive coughing and the foreign body is expelled out. If this reflex is slowed or absent as in neurological lesion or after consuming alcohol, a foreign body (e.g., piece of meat) may enter the laryngeal cavity and cause choking (i.e., laryngeal obstruction). Choking by food is a common cause of laryngeal obstruction and asphyxia. If foreign body is not dislodged and expelled out immediately by Heimlich maneuver, person will die within minutes, almost certainly before there is time to take him to the hospital. The **Heimlich maneuver** is performed as follows (Fig. 15.9):

Stand behind the victim, pass your arms under his arms, place hands in front of the victim's epigastrium with one hand formed into a fist and the other hand lying over it. Now give 3 or 4 abdominal thrusts directed upwards and backwards. By doing this, the residual air in the lungs is squeezed up in trachea and larynx with force, dislodging foreign body and thus relieving laryngeal obstruction (choking). The foreign body is either expelled itself or removed.

SUBDIVISIONS OF THE LARYNGEAL CAVITY

The laryngeal cavity is divided into three parts by two pairs of vestibular and vocal folds (Fig. 15.10), viz.

1. **Vestibule (supraglottic compartment):** It extends from laryngeal inlet to the vestibular folds.
 - Its **anterior wall** is formed by the mucous membrane covering the posterior surface of epiglottis, **posterior wall** by the mucous membrane covering the apices of arytenoids cartilages, and **corniculate cartilages**, and **sides** by aryepiglottic folds.

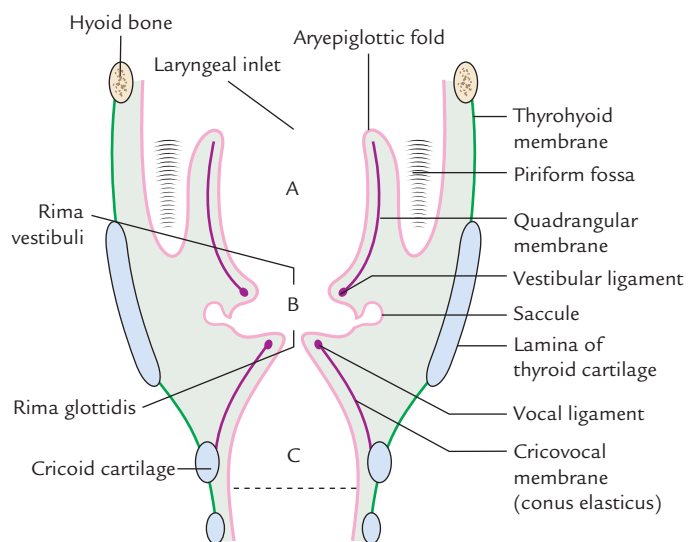


Fig. 15.10 Coronal section of the laryngeal cavity showing its subdivisions. A=vestibule, B=ventricle of the larynx, C=infraglottic compartment.

The aryepiglottic folds separate the vestibule from piriform recesses.

2. **Ventricle or sinus of the larynx (glottic compartment):** It is the deep elliptical space between vestibular and vocal folds. On each side, a narrow blind diverticulum of the mucous membrane extends posterosuperiorly between the vestibular fold and lamina of the thyroid cartilage, called **sacculae of the larynx**. It is provided with the mucous glands, whose secretions lubricate the vocal cords. Hence it is also termed *oil can of the larynx*.

Clinical correlation

Laryngocele: If air pressure in the laryngeal sinus is raised too much as in trumpet players, glass blowers or weight lifters, the sacculae dilates to produce an air-filled cystic swelling called *laryngocele* (Fig. 15.11). The laryngocele may be internal, when it is located within the larynx or external, when distended sacculae herniates through the thyrohyoid membrane and comes outside the larynx.

3. **Infraglottic compartment:** It extends from vocal folds to the lower border of the cricoid cartilage.

MUCOUS MEMBRANE

The mucous membrane of the larynx is loosely attached, *except* over the posterior surface of the epiglottis, true vocal cords, corniculate and cuneiform cartilages where it is firmly adherent.

The whole of the laryngeal cavity is lined by *ciliated columnar epithelium* except the anterior surface and upper half of the posterior surface of the epiglottis, upper parts of aryepiglottic folds and vocal folds, which are lined by *stratified squamous epithelium*.

The *mucous glands* are distributed all over the mucous lining. They are particularly numerous on the posterior surface of the epiglottis, posterior parts of aryepiglottic folds

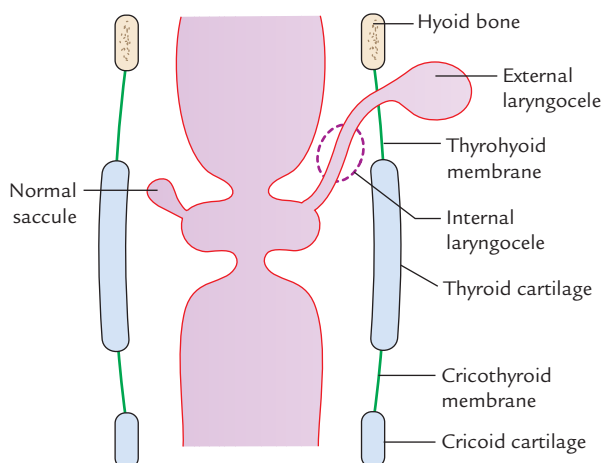


Fig. 15.11 Laryngocele.

and in the sacculae. There are no mucous glands in the vocal folds.

Clinical correlation

The mucosa (lined by stratified squamous epithelium) lining the vocal cords is firmly adhered to the vocal ligaments and there is no intervening submucosa. This accounts for the pearly white avascular appearance of vocal cords. The edema of larynx does not involve the true vocal cords since there is no submucous tissue.

NERVE SUPPLY OF THE LARYNX

Motor nerve supply: It is provided by internal and external laryngeal nerves.

Sensory nerve supply: The mucous membrane of larynx above the vocal folds is supplied by the *internal laryngeal nerve*, while below the vocal folds by the *recurrent laryngeal nerve*.

Clinical correlation

If *internal laryngeal nerve* is damaged, there is anesthesia of the mucous membrane in the supraglottic portion and loss of protective cough reflex. As a result, the foreign bodies can readily enter the larynx.

ARTERIAL SUPPLY OF THE LARYNX

The arterial supply of larynx is as follows:

1. **Above the vocal fold** by *superior laryngeal artery*, a branch of superior thyroid artery.
2. **Below the vocal fold** by *inferior laryngeal artery*, a branch of inferior thyroid artery.

N.B. Rima glottidis has dual blood supply (vide supra).

VENOUS DRAINAGE OF THE LARYNX

The veins draining the larynx accompany the arteries. These are:

1. **Superior laryngeal vein**, which drains into the superior thyroid vein.
2. **Inferior laryngeal vein**, which drains into the inferior thyroid vein.

LYMPHATIC DRAINAGE OF THE LARYNX

The lymphatics from:

- (a) **above the vocal cords** pierce the thyrohyoid membrane, run along superior thyroid vessels and drain into upper deep cervical lymph nodes (anterosuperior group).

- (b) below the vocal cords pierce the cricothyroid membrane and go to the prelaryngeal and pretracheal nodes, and then drain into lower deep cervical lymph nodes (posteroinferior group).

RIMA GLOTTIDIS AND PHONATION

It is the narrowest anteroposterior cleft of the laryngeal cavity. The anteroposterior diameter of glottis is 24 mm in adult males and 16 mm in adult females.

Boundaries

- In front:* Angle of thyroid cartilage.
Behind: Interarytenoid folds of the mucous membrane.
On each side: Vocal fold in anterior three-fifth and vocal process of arytenoid cartilage in the posterior two-fifth.

Subdivisions of Rima Glottidis

The rima glottidis is divided into the following two parts:

1. **Intermembranous part** in the anterior three-fifth, between the vocal cords.

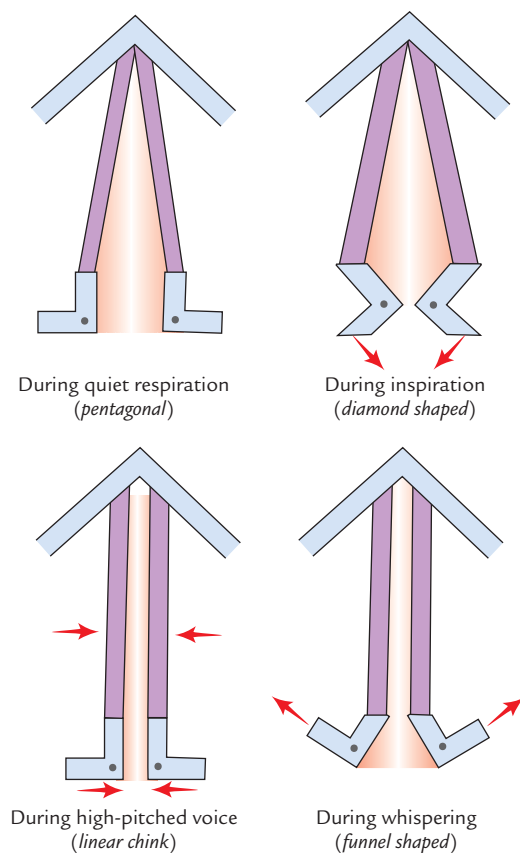


Fig. 15.12 Variations in the size and shape of rima glottidis during different movements of the vocal cords.

2. **Intercartilaginous part** in the posterior one-fifth, between the vocal processes of arytenoid cartilage.

Shape of Rima Glottidis (Fig. 15.12)

The size and shape of glottis varies with the movements of the vocal cords:

- In quiet breathing, the intermembranous part is triangular and intercartilaginous part is rectangular. As a whole the glottis is *pentagonal*.
- In full inspiration, the glottis widens and becomes *diamond shaped* due to abduction of vocal cords.
- During high-pitched voice, the rima glottidis is reduced to a *linear chink*, due to adduction of both intermembranous and intercartilaginous parts.
- During whispering, the intermembranous part is highly adducted and intercartilaginous part is separated by triangular gap, thus rendering an *inverted funnel* shape to the rima glottidis.

Clinical correlation

Laryngoscopy: The interior of the larynx can be inspected directly by laryngoscope (*direct laryngoscopy*), or indirectly through a laryngeal mirror (*indirect laryngoscopy*). The following structures are viewed (Fig. 15.13):

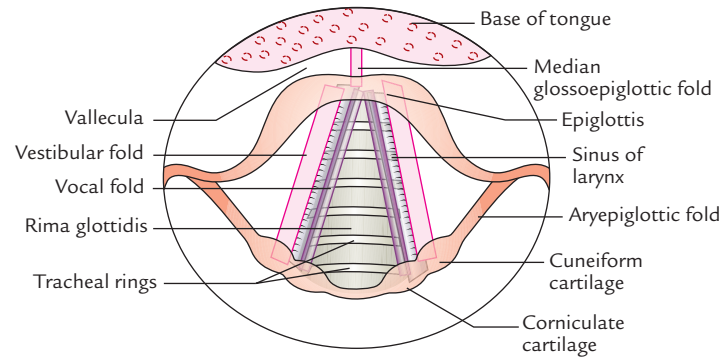
- Base of tongue.
- Valleculae.
- Epiglottis.
- Aryepiglottic folds.
- Piriform fossae.
- False vocal cords (red and widely apart).
- True vocal cords (pearly white), medial to false vocal cords.
- Sinus of the larynx between false and true vocal cords.

MECHANISM OF PHONATION

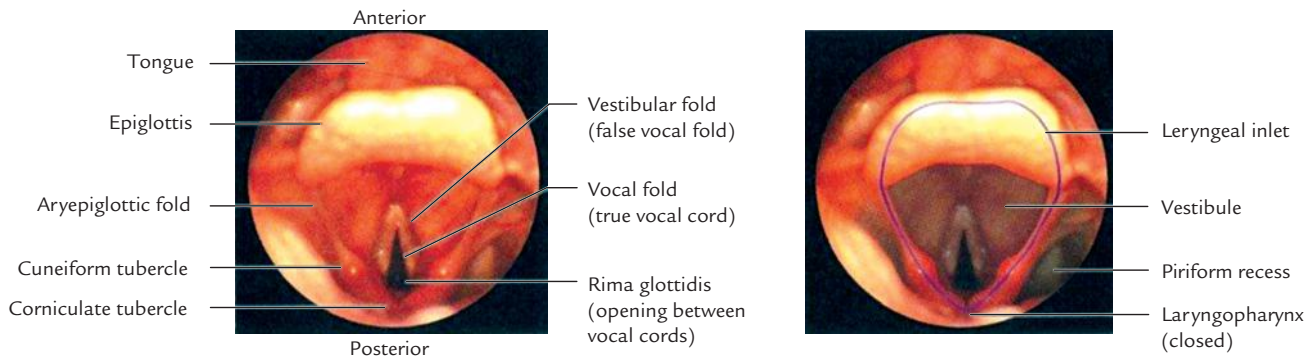
The phonation (speech) is produced by the vibrations of the vocal cords. The greater the amplitude of vibration, the louder is the sound.

The larynx is like a wind instrument. The voice is produced in following manner:

1. Vocal cords are kept adducted.
2. Infraglottic air pressure is generated by the exhaled air from lungs by the contraction of abdominal, intercostal, and other expiratory muscles.
3. Force of air opens the cords and is released as small puffs.
4. As the moving air passes through the vocal cords it makes them to vibrate producing sound.
5. Sound is amplified by mouth, pharynx, esophagus, and nose.
6. Sound is converted into speech by the modulatory actions of lips, tongue, palate, pharynx, and teeth.



A



B

Fig. 15.13 Laryngoscopic view of the laryngeal cavity during moderate respiration. Note that rima glottidis is widely open. A, schematic diagram; B, actual photographs. (Source: Fig. 8.208B, Page 956, *Gray's Anatomy for Students*, Richard L Drake, Wayne Vogl, Adam WM Mitchell, Copyright Elsevier Inc. 2005, All rights reserved.)

N.B.

- The *vowels* are voiced in the larynx due to vibration of vocal folds whereas *consonants* are produced by the intrinsic muscles of the tongue.
- The loudness of sound depends upon the amplitude of vibrating vocal folds, whereas pitch depends upon the frequency with which the vocal folds vibrate. Since the vocal cords are usually longer in males than females, they vibrate with greater amplitude but with lower frequency. Hence voice of male is louder but low pitched.

symmetrical, and vary in size from that of pin head to a split pea. In early stages, they are soft, reddish, and edematous but later become greyish or whitish in color (Fig. 15.14).

Clinical correlation

Vocal nodules (Singer's or Screamer's nodules): During vibration the area of maximum contact between the vocal cords is at the junction of their anterior one-third and posterior two-third and thus subject to maximum friction. Hence in individuals, who overuse their voice, such as teachers, pop singers, the inflammatory nodules develop at these sites called *vocal nodules*. They are bilateral and

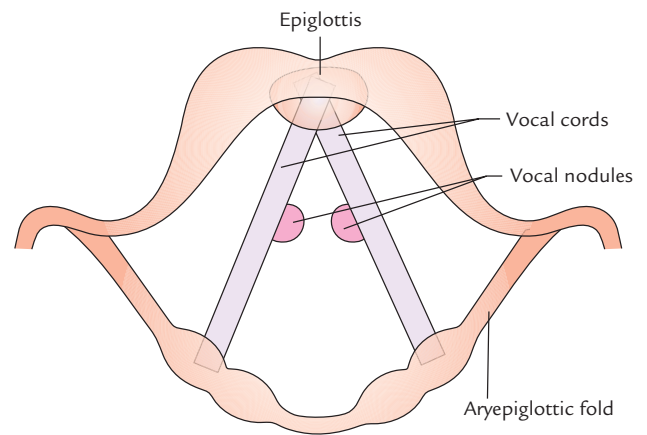


Fig. 15.14 Vocal nodules.

Golden Facts to Remember

- ▶ Largest and most prominent cartilage of the larynx Thyroid cartilage
- ▶ Cartilage, which completely encircles the lumen of larynx Cricoid cartilage
- ▶ Foundation stone of the larynx Cricoid cartilage
- ▶ All the intrinsic muscles of the larynx are paired *except* Transverse arytenoid (interarytenoid)
- ▶ All the intrinsic muscles of the larynx are adductors of the vocal cords *except* Posterior cricoarytenoids, which are abductors of the vocal cords
- ▶ Tuning fork of larynx (chief tensor of vocal cords) Cricothyroid
- ▶ Modulators of voice Vocalis muscles
- ▶ All the intrinsic muscles of the larynx are supplied by recurrent laryngeal nerve *except* Cricothyroid, which is supplied by the external laryngeal nerve
- ▶ Narrowest region of the laryngeal cavity Rima glottidis
- ▶ Safety muscles of the larynx Posterior cricoarytenoid
- ▶ Singer's nodules Inflammatory nodules on the vocal cords at the junction of anterior one-third and posterior two-third
- ▶ Commonest cancer of the larynx Squamous cell carcinoma (90–95%)
- ▶ Commonest site of the laryngeal cancer Glottic region
- ▶ Most common congenital abnormality of the larynx Laryngomalacia (excessive flaccidity of supraglottic larynx)
- ▶ Reinke's space Potential space under the epithelium of vocal cord

Clinical Case Study



A senior army officer along with his son, daughter, and wife went to a 5-star hotel to have dinner to celebrate the birthday of his wife. The officer consumed 3 or 4 pegs of alcohol before taking the meal. While having meals he began to suffocate and collapsed on the floor. The wife who was sitting by his side suspected that probably he has consumed too much alcohol. On close examination, his son who was a final year MBBS student, found that pulse was strong and face began to turn blue (cyanosis). He realized that his daddy was suffering from asphyxia. So he immediately opened his mouth and observed that a piece of meat was caught in the posterior part of the pharynx. He inserted his index finger and tried to take out the piece of meat. On being unsuccessful he rolled his daddy into a prone position and with his hands interlocked against the epigastrium exerted pressure on abdomen 2 or 3 times. He was happy that the piece of meat expelled out.

Questions

1. Where was the piece of meat most likely lodged?
2. Why is choking and asphyxia common in people who consume alcohol before meals?
3. What is Heimlich maneuver?
4. Which is narrowest part of the laryngeal cavity?

Answers

1. In the inlet of the larynx
2. Because of the following two reasons:
 - (a) People who are drunk are less able to chew their food properly and to detect a large bite.
 - (b) In a person who consumes alcohol, the protective explosive cough reflex when a foreign material enters the laryngeal cavity markedly reduces.
3. It is a *first-aid procedure* by which foreign bodies lodged in the respiratory tract are dislodged and expelled out (for details see page 226).
4. Glottis.

Blood Supply and Lymphatic Drainage of the Head and Neck

BLOOD SUPPLY OF HEAD AND NECK

The blood supply of head and neck consists of an arterial supply and venous drainage and carried out by the arteries and veins, respectively. The medical students must know the location of larger blood vessels of the head and neck because these vessels may become compromised due to disease process or during surgical procedures. The blood vessels also spread infection to head and neck. Further, they may also spread cancer cells from a malignant tumor to distant sites (*metastasis*) and at a faster rate than lymph vessels. The blood vessels are less numerous than lymph vessels yet the veins usually parallel the lymph vessels.

ARTERIAL SUPPLY

The arteries that supply the head and neck are subclavian and common carotid arteries (Fig. 16.1). The main arteries of the head and neck are right and left common carotid arteries, each of which divides into (a) an external carotid

artery and (b) an internal carotid artery. The external carotid artery supplies structures external to the head and greater part of the neck. The internal carotid artery supplies structures within the cranial cavity and the orbit. The common carotid, external carotid, and internal carotid together form the **carotid system of arteries**. The carotid system of arteries forms the major source of arterial blood supply to the head and neck.

SUBCLAVIAN ARTERIES

The subclavian artery is so called because it is located beneath the clavicle. It is the main source of blood supply to the upper limb and hence called **artery of the upper limb**. However, the subclavian artery also supplies considerable part of the thoracic wall, head, neck, and brain through its branches.

Origin (Fig. 16.2)

1. The *right subclavian artery* arises from the brachiocephalic trunk behind the right sternoclavicular joint at the root of neck.
2. The *left subclavian artery* arises from the arch of aorta in the thorax. It runs upwards on the left mediastinal pleura and makes groove on the left lung and enters the neck by passing behind the left sternoclavicular joint.

N.B. Based on their origin, the right subclavian artery has only cervical part whereas the left subclavian artery has thoracic as well as cervical parts. The *cervical part* extends from sternoclavicular joint to the outer border of the first rib.

Course (Fig. 16.3)

In the neck, both the arteries pursue a similar course.

On each side, the subclavian artery arches laterally across the anterior surface of the cervical pleura onto the first rib posterior to the scalenus anterior muscle. At the outer border of 1st rib, it ends by becoming axillary artery.

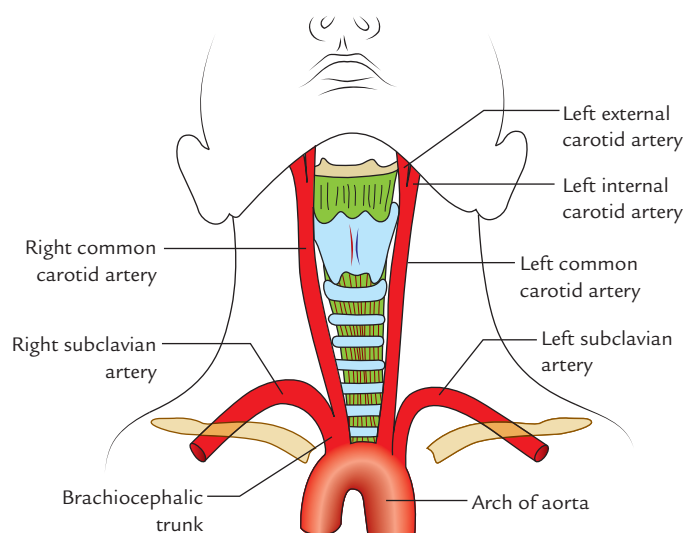


Fig. 16.1 Arteries supplying the head and neck.

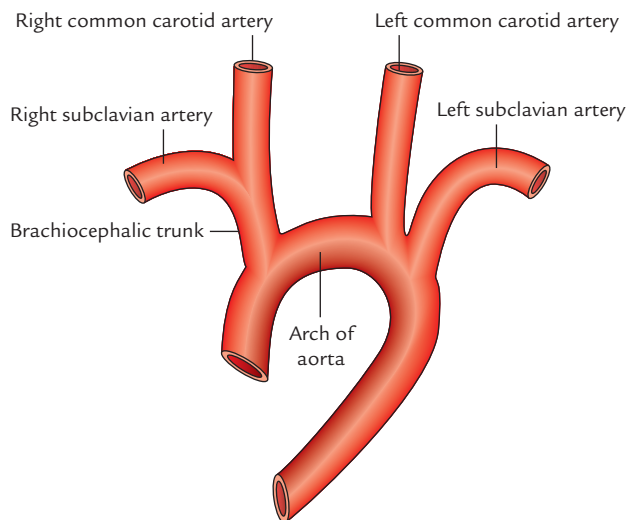


Fig. 16.2 Origin of the subclavian arteries. Note that the right subclavian artery arises from the brachiocephalic trunk whereas the left subclavian artery arises directly from the arch of aorta.

Termination

At the outer border of first rib where the subclavian artery continues as the axillary artery.

Parts

On each side, the subclavian artery is divided into three parts by the scalenus anterior muscle (Fig. 16.3). These are:

1. **First part**—extends from origin to medial border of scalenus anterior.
2. **Second part**—lies behind the scalenus anterior muscle.

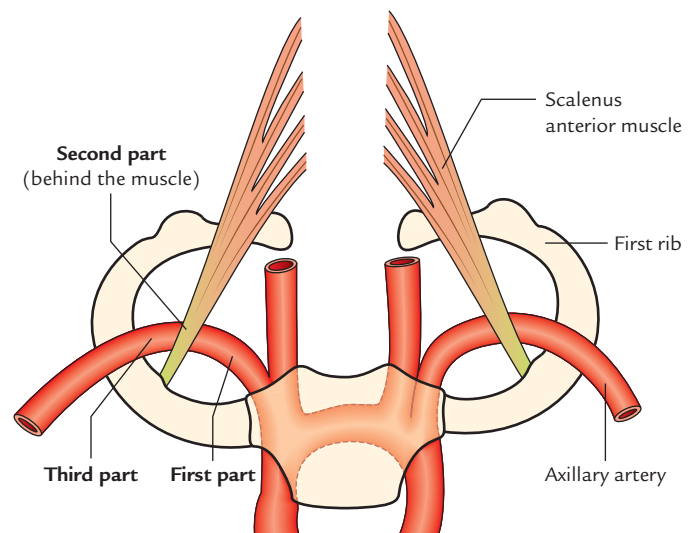


Fig. 16.3 Parts of the subclavian artery.

3. **Third part**—extends from the lateral border of scalenus anterior to the outer border of the first rib.

Relations (Fig. 16.4)

The relations of the three parts of subclavian artery are as follows:

First part

Anterior:

1. The common carotid artery, internal jugular vein, vagus nerve, vertebral vein, phrenic nerve, sternocleidomastoid, sternothyroid, and sternohyoid muscles.

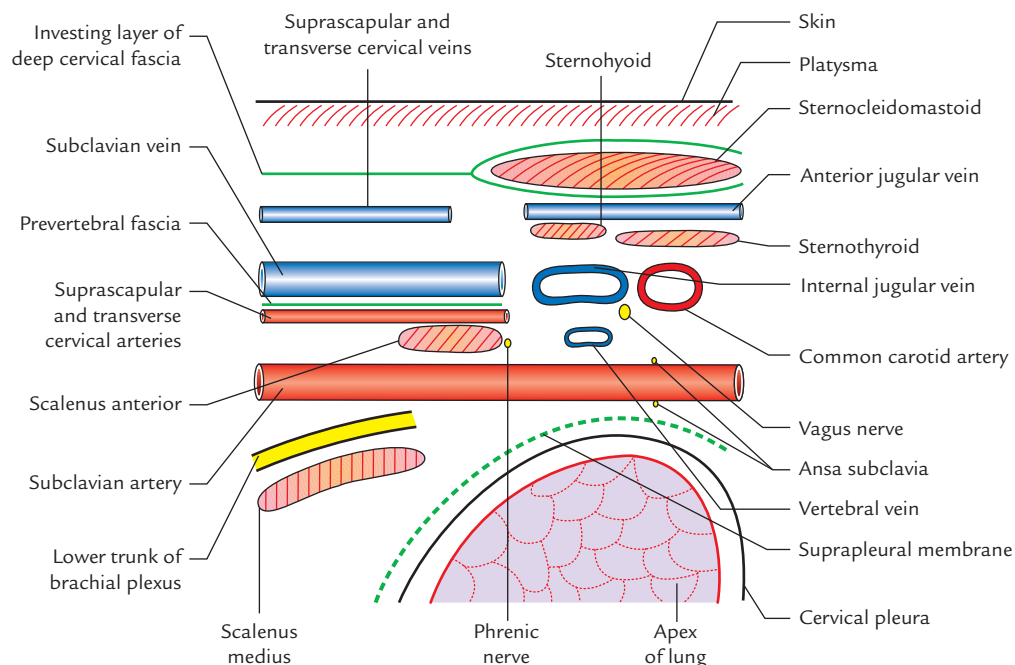


Fig. 16.4 Schematic diagram to show the relations of right subclavian artery.

- Thoracic duct (only on the left side), cardiac branches of the vagus and sympathetic trunk; and ansa cervicalis (encircling the subclavian artery), and phrenic nerve on the left side only.

Posterior:

- Apex of the lung covered by the cervical pleura and suprapleural membrane.
- Sympathetic trunk and right recurrent laryngeal nerve, which hooks the undersurface of the right subclavian artery.

Second part

Anterior:

- Scalenus anterior muscle.
- Phrenic nerve (on right side only).
- Sternocleidomastoid.

Behind:

- Apex of lung covered by the cervical pleura and suprapleural membrane.
- Lower trunk of the brachial plexus and scalenus medius muscle.

Third part

Anterior:

- Suprascapular and transverse cervical vessels.
- Subclavian and external jugular veins.
- Anterior jugular vein.

Behind:

- Apex of lung covered by the cervical pleura and suprapleural membrane.

- Lower trunk of the brachial plexus and scalenus medius muscle.

N.B. The second part forms the summit of the arch of the subclavian artery and rises 1.5–2.5 cm above the level of the clavicle. It emerges through the gap between scalenus anterior and scalenus medius muscle along with lower trunk of the brachial plexus.

Clinical correlation

Approach to subclavian artery: The third part of the subclavian artery is most superficial, and its pulsations can be felt on deep pressure. It is located mostly in the supraclavicular triangle, where it lies on the first rib. It can be compressed against the first rib by pressing downwards, backwards, and medially in the angle between the clavicle and posterior border of the sternocleidomastoid muscle. It can also be ligated conventionally at this site. The blood supply to the upper limb is not hampered due to adequate collateral circulation.

Branches of the Subclavian Artery (Fig. 16.5)

The subclavian artery usually gives off four branches. All of them arise from first part with the exception of costocervical trunk, which on the right side arises from the second part.

• *From the first part:*

- Vertebral artery
- Thyrocervical trunk – Inferior thyroid artery
– Transverse cervical artery
– Suprascapular artery
- Internal thoracic artery
- Costocervical trunk (on left side only)

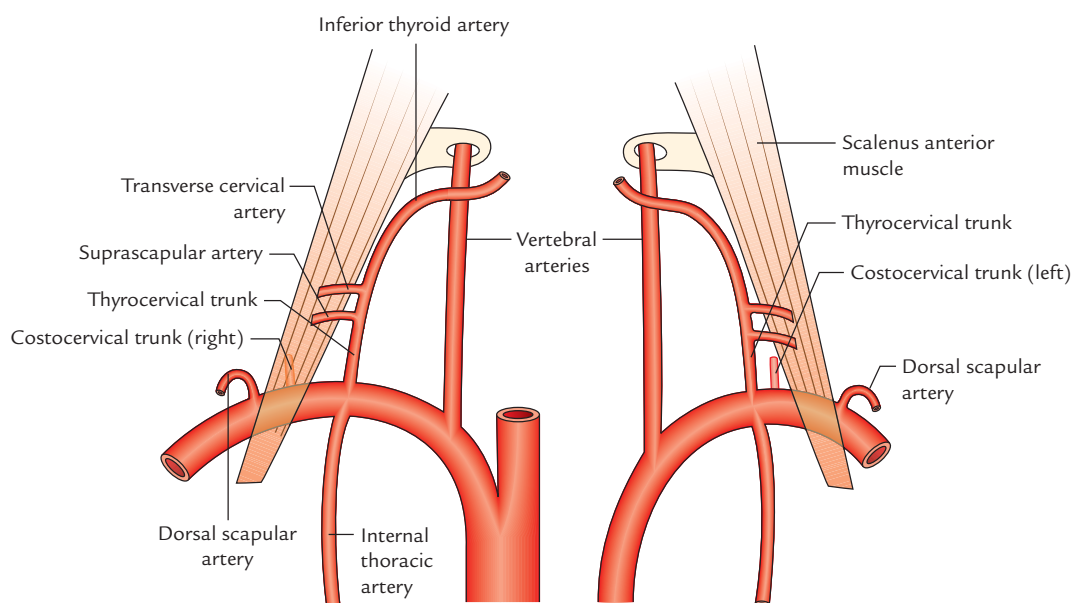


Fig. 16.5 Branches of the right and left subclavian arteries.

- *From the second part:*
Costocervical trunk (on right side only)
- *From the third part:*
Dorsal scapula artery: It is an occasional branch that may arise from the third part of the subclavian artery. When present, it replaces the deep branch of the transverse cervical artery.

Vertebral Artery

The vertebral artery is one of the principal arteries which supplies the brain.

It is the first and largest branch of the first part of the subclavian artery (Fig. 16.6).

Origin, Course, and Termination

The vertebral artery arises from the upper aspect of the first part of the subclavian artery, runs vertically upwards to enter the foramen transversarium of the transverse process of C6. Then it passes through the foramen transversaria of the upper six cervical vertebrae.

After emerging from the foramen transversarium of C1, it winds backwards around the lateral mass of the atlas and enters the cranial cavity through foramen magnum.

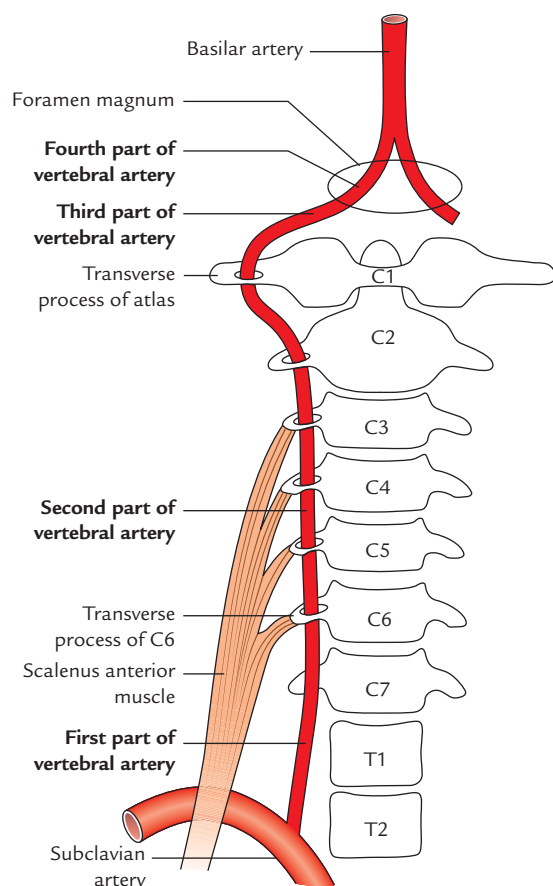


Fig. 16.6 Course and parts of the vertebral artery.

In the cranial cavity, it unites with the vertebral artery of the opposite side at the lower border of the pons to form the basilar artery.

Parts (Fig. 16.6)

The vertebral artery is divided into four parts, *viz.*

1. **First (cervical) part**—extends from origin to foramen transversarium of C6 vertebra. This part lies in the *scalenovertbral triangle*.
2. **Second (vertebral) part**—lies within the foramen transversaria of upper six cervical vertebrae.
3. **Third (suboccipital) part**—extends from foramen transversarium of C1 vertebra to the foramen magnum of skull. This part lies within the suboccipital triangle.
4. **Fourth (intracranial) part**—extends from foramen magnum to the lower border of the pons.

Branches

In the neck (cervical branches)

1. **Spinal branches:** They arise from the second (vertebral) part and enter the vertebral canal through intervertebral foramina to supply the upper five or six cervical segments of the spinal cord.
2. **Muscular branches:** They arise from the first and third parts of the vertebral artery. Those from the first part, supply deep muscles of the neck and those from the third part, supply the muscles of the suboccipital triangle.

In the cranial cavity (cranial branches)

They arise from the 4th part. These are:

1. Meningeal branches.
2. Posterior spinal artery.
3. Anterior spinal artery.
4. Posterior inferior cerebellar artery.
5. Medullary branches.

Clinical correlation

Subclavian steal syndrome (Fig. 16.7): If there is obstruction of the subclavian artery proximal to the origin of vertebral artery, some amount of blood from opposite vertebral artery will pass in a retrograde fashion to the subclavian artery of the affected side through the vertebral artery of that side to provide the collateral circulation to the upper limb on the side of lesion. Thus there occurs a sort of stealing of blood of brain by the subclavian artery of the affected side. Hence, the name *subclavian steal syndrome*.

Internal Thoracic Artery (Internal Mammary Artery)

The internal mammary artery arises from the inferior aspect of the first part of the subclavian artery opposite the origin of thyrocervical trunk. It passes downwards and medially in

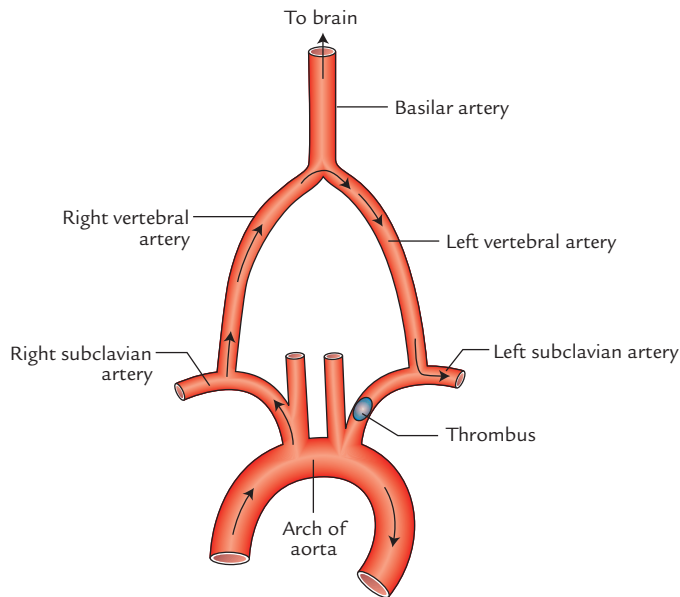


Fig. 16.7 Subclavian steal syndrome.

front of the cupola of the cervical pleura and enters the thorax behind the sternoclavicular joint.

In the thorax, it passes vertically downwards, about 1.25 cm away from the lateral border of the sternum, up to the level of the 6th intercostal space, where it divides into two terminal branches: **musculophrenic** and **superior epigastric arteries** (for details see *Textbook of Anatomy: Upper Limb and Thorax*, Vol. I by Vishram Singh).

Thyrocervical Trunk

It is the short, wide branch of the subclavian artery.

Origin, Course, and Termination

The thyrocervical trunk arises from the upper aspect of the first part of the subclavian artery at the medial margin of the scalenus anterior and lateral to the origin of vertebral artery. It immediately terminates into three branches.

Branches (Fig. 16.5)

These are:

1. Inferior thyroid artery.
2. Superficial cervical artery.
3. Suprascapular artery.

Inferior thyroid artery: It ascends along the medial border of scalenus anterior and just below transverse process of C7 vertebra, it turns medially in front of the vertebral artery and posterior to vagus nerve, sympathetic trunk, and common carotid artery to reach the posterior surface of the lateral lobe of the thyroid gland. Then it descends to the lower pole of the thyroid lobe and divides into **ascending** and **descending glandular branches**.

Other small branches:

In addition to glandular branches to thyroid gland it also gives the following branches:

1. **Ascending cervical artery** passes upwards in front of the transverse processes of cervical vertebrae along the medial side of the phrenic nerve and acts as a guide to this nerve. It supplies prevertebral muscles and sends spinal branches to the vertebral canal along the spinal nerves.
2. **Inferior laryngeal artery** accompanies the recurrent laryngeal nerve to the larynx and supplies the mucous membrane of the larynx below the vocal cord and muscles of the larynx.
3. **Tracheal, pharyngeal, and esophageal branches** to trachea, pharynx, and esophagus, respectively.

Transverse cervical artery: It passes laterally and upwards across the scalenus anterior to reach the posterior triangle, where it lies in front of the trunks of the brachial plexus. Here, it further divides into superficial and deep branches. The superficial branches ascend beneath the trapezius and anastomoses with the superficial division of the descending branch of the occipital artery.

The deep branch courses deep to the levator scapulae and takes part in the scapular anastomosis.

Suprascapular artery: It passes laterally across the scalenus anterior to lie in front of the third part of the subclavian artery and of brachial plexus. Now it passes behind the clavicle to reach the suprascapular notch of the scapula, where it passes above the suprascapular ligament to enter the suprascapular fossa and takes part in the formation of **arterial anastomosis around the scapula**.

Costocervical Trunk (Fig. 16.8)

Origin

It arises from posterior aspects of: (a) **first part of the subclavian artery on the left side**, and (b) **second part of the subclavian artery on the right side**.

Course and Termination

The artery arches backwards above the cupola of the pleura and on reaching the neck of the first rib it terminates by dividing into ascending deep cervical artery and ascending superior (highest) intercostal artery.

Deep cervical artery passes backwards between the transverse process of C7 vertebra and neck of the first rib. It then ascends between the semispinalis capitis and semispinalis cervicis and anastomoses with the deep division of the descending branch of the occipital artery.

Superior (highest) intercostal artery descends in front of the neck of the first two ribs and gives rise to posterior intercostal arteries to the first two intercostal spaces.

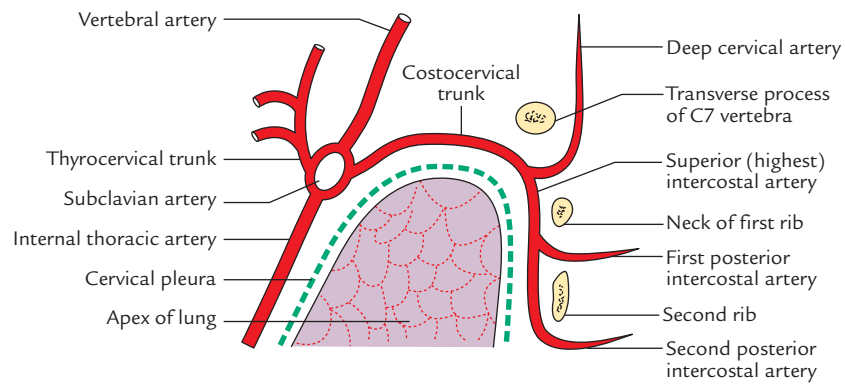


Fig. 16.8 Origin, course, and branches of the costocervical trunk.

Dorsal Scapular Artery

It arises from the third part of the subclavian artery (but may be the deep branch of the transverse cervical artery). As a direct branch of the subclavian artery, it passes laterally and backwards between the trunks of brachial plexus to reach underneath the levator scapulae. Now it descends along the medial border of the scapula in company with dorsal scapular nerve deep to rhomboids and takes part in the formation of arterial anastomosis around the scapula.

The branches of subclavian artery and their subsequent branches are summarized in Table 16.1.

Clinical correlation

- **Cervical rib** may compress the subclavian artery as it passes through the gap between the scalenus anterior and scalenus medius muscles. This can be tested clinically when the patient's chin is turned upwards and to the affected side after a deep breath the radial pulse is diminished or obliterated (*Adson's test*).
- **Aneurysm** may develop in the third part of subclavian artery. The pressure due to aneurysm on the brachial plexus causes numbness, weakness, and pain in the upper limb.
- **Dysphagia lusoria:** The right subclavian artery sometimes may arise from descending thoracic aorta and compress esophagus leading to difficulty in swallowing. This condition is called *dysphagia lusoria*.

Table 16.1 Summary of branches of the subclavian artery and their subsequent branches

Branches	Subsequent branches
Vertebral artery <ul style="list-style-type: none"> • First (cervical) part • Second (vertebral) part • Third (suboccipital) part • Fourth (intracranial) part 	Muscular branches Spinal branches Muscular branches Meningeal branches Posterior spinal artery Posterior inferior cerebellar artery Medullary branches
Internal thoracic artery	(See <i>Textbook of Anatomy: Upper Limb and Thorax</i> , Vol. I by Vishram Singh)
Thyrocervical trunk <ul style="list-style-type: none"> • Inferior thyroid artery 	Glandular branches Ascending cervical artery Inferior laryngeal artery Tracheal, pharyngeal, and esophageal branches
<ul style="list-style-type: none"> • Suprascapular artery 	(See <i>Textbook of Anatomy: Upper Limb and Thorax</i> , Vol. I by Vishram Singh)
<ul style="list-style-type: none"> • Transverse cervical artery 	Superficial branch Deep branch/dorsal scapular artery
Costocervical trunk	Deep cervical artery Highest intercostal artery

COMMON CAROTID ARTERIES

There are two common carotid arteries: right and left. They are the chief arteries of the head and neck.

Origin (Fig. 16.1)

The **right common carotid artery** arises in neck from *brachiocephalic trunk* (innominate artery) behind the sternoclavicular joint.

The **left common carotid artery** arises in thorax (superior mediastinum) directly from the *arch of aorta*. It ascends to the back of left sternoclavicular joint and enters the neck.

Course, Termination, and Relations

In the neck, both arteries (right and left) have similar course. Each artery runs upwards from sternoclavicular joint to the upper border of the lamina of thyroid cartilage (opposite the disc between the 3rd and 4th cervical vertebrae), where it terminates by dividing into internal and external carotid arteries. The internal carotid artery is considered as a continuation of common carotid artery. They are named as internal and external because the former supplies structures within the skull and latter supplies structures outside the skull.

Each common carotid artery lies in front of transverse processes of lower four cervical vertebrae under the cover of anterior border of the sternocleidomastoid muscle.

Branches

The common carotid artery gives only two terminal branches, i.e., external and internal carotid arteries.

Clinical correlation

Carotid pulse: The common carotid artery can be compressed against the prominent anterior tubercle of transverse process of the 6th cervical vertebrae called *carotid tubercle* (*Chassaignac's tubercle*) by pressing medially and posteriorly with the thumb. The carotid tubercle of the 6th cervical vertebra is located about 4 cm above the sternoclavicular joint at the level of cricoid cartilage.

Above this level, the common carotid artery is superficial and hence its pulsations can be easily felt. *The carotid pulse is the most constant pulse in the body.*

External Carotid Artery (Fig. 16.9)

It is one of the two terminal branches of the common carotid artery and supplies the structures external to the head and in front of the neck.

Course and Relations

The external carotid artery extends upwards from the level of upper border of the lamina of the thyroid cartilage to a point behind the neck of the mandible, where it terminates in the substance of the parotid gland by dividing into the superficial temporal and maxillary arteries.

The external carotid artery has a slightly curved course so that it is anteromedial to the internal carotid artery in its lower part and anterolateral to the internal carotid artery in its upper part (Fig. 16.9).

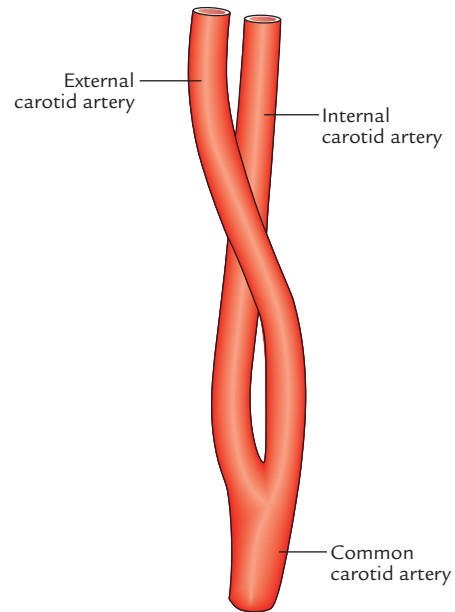


Fig. 16.9 Curved course of the external carotid artery. Note the relationship of the external carotid with the internal carotid arteries.

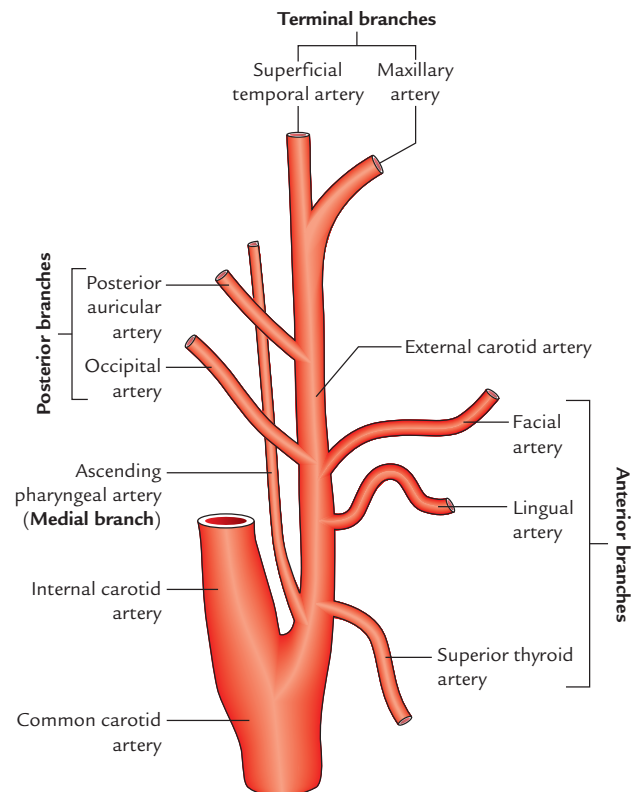


Fig. 16.10 Branches of the external carotid artery.

Branches (Fig. 16.10)

The external carotid artery gives rise to eight branches as follows:

1. Superior thyroid artery.
2. Lingual artery.
3. Facial artery.
4. Occipital artery.
5. Posterior auricular artery.
6. Ascending pharyngeal artery.
7. Maxillary artery.
8. Superficial temporal artery.

The first three arteries arise from anterior aspect, next two from posterior aspect, and next one from medial aspect. The last two are terminal branches.

The branches of the external carotid artery are eight in number (Mnemonic – the term EXTERNAL consists of 8 letters: 1, 2, 3, 4, 5, 6, 7, 8, which correspond to the number of branches of the external carotid artery).

1. **Superior thyroid artery:** It arises from the front of external carotid artery just below the tip of the greater cornu of the hyoid bone. It runs downwards and forwards, parallel and superficial to the external

laryngeal nerve to reach the upper pole of the thyroid gland, which it supplies.

Branches (Fig. 16.11)

- (a) *Infrahyoid branch*, which anastomoses with its fellow of opposite side.
 - (b) *Sternomastoid branch* to the sternomastoid muscle.
 - (c) *Superior laryngeal artery* accompanies the internal laryngeal nerve, passes deep to the thyrohyoid muscle and pierces the thyrohyoid membrane to supply the larynx.
 - (d) *Cricothyroid branch*, passes across the cricothyroid ligament and anastomoses with its counterpart of the opposite side.
 - (e) *Glandular branches* to the thyroid gland; one of which anastomoses with its fellow of the opposite side along the upper border of the isthmus of the thyroid gland.
2. **Lingual artery:** It arises from the front of the external carotid artery opposite the tip of the greater cornu of the hyoid bone. It is the main artery to supply blood to the tongue. It may arise in common with the facial artery (*linguofacial trunk*).

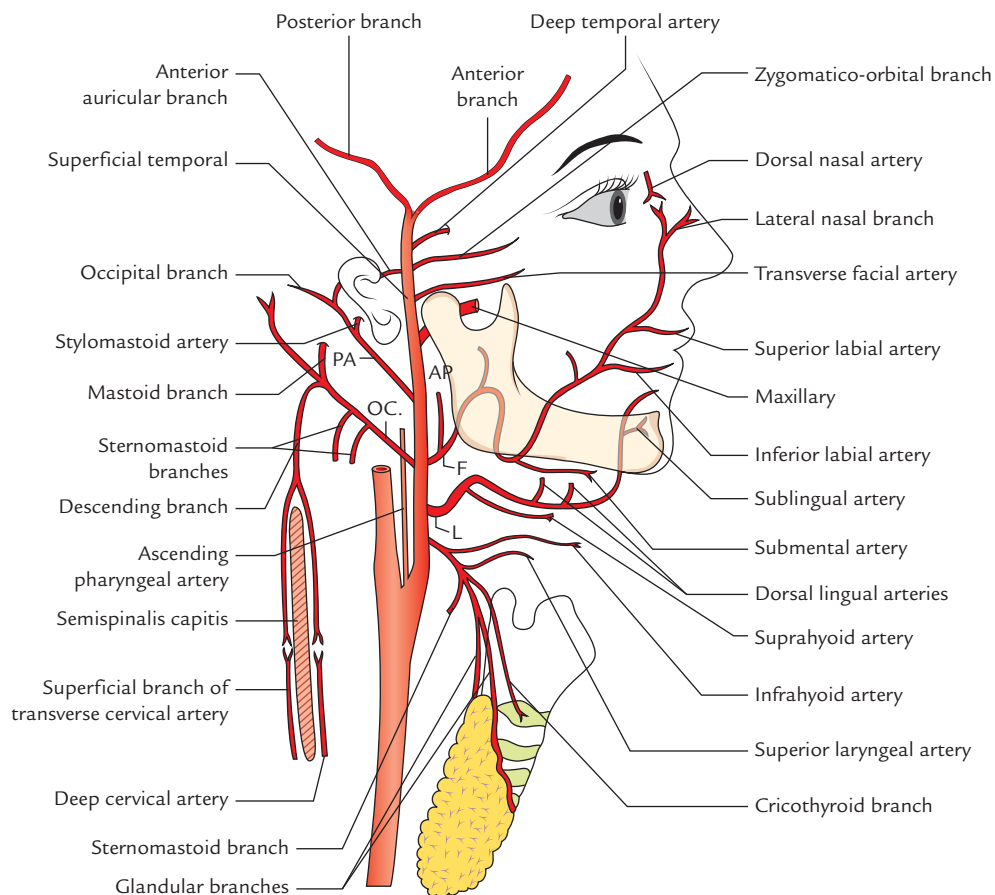


Fig. 16.11 Distribution of the branches of the external carotid artery (shown in dark red color) (F = facial artery, L = lingual artery, AP = ascending palatine artery, OC = occipital artery, PA = posterior auricular artery).

It is divided into three parts by the hyoglossus muscle, viz.

- First part* lies in the carotid triangle and forms a characteristic loop with convexity upwards above the greater cornu. The loop is crossed superficially by the hypoglossal nerve. The loop permits free movement of the hyoid bone.
- Second part* lies deep to the hyoglossus muscle along the upper border of the hyoid bone.
- Third part* (also called *arteria profunda linguae*) or *deep lingual artery* first runs upwards along the anterior border of the hyoglossus muscle and then forwards on the undersurface of the tongue, where it anastomoses with its fellow of opposite side.

Branches

- From first part—*suprahyoid branch*. It anastomoses with its fellow of opposite side.
 - From second part—*dorsal linguae* branches usually two in number, to the dorsum of tongue and tonsil.
 - From third part—*sublingual artery*, to the sublingual gland.
3. **Facial artery (formerly called external maxillary artery):** It arises from the front of the external carotid artery just above the tip of the greater cornu of the hyoid bone.

It is divided into two parts—cervical and facial:

- Cervical part* of the facial artery ascends deep to the digastric and stylohyoid muscles, passes deep to the ramus of mandible where it grooves the posterior border of the submandibular gland. Then it makes S-shaped bend, first bending down (with convexity upwards) over the submandibular gland, and then up (with convexity downwards) over the base of the mandible.
- Facial part* of the facial artery begins where the facial artery winds around the lower border of the body of the mandible at the anteroinferior angle of the masseter. (It has already been described on page 63).

Branches

From the cervical part (branches in the neck)

- Ascending palatine artery* arises near the origin of facial artery, ascends, and accompanies the levator palati, passes over the upper border of the superior constrictor and supplies mainly the palate.
- Tonsillar artery* (main artery of tonsil) pierces the superior constrictor and ends in the tonsil.
- Glandular branches* supply the submandibular gland.
- Submental artery*, a large artery which runs forwards on the mylohyoid muscle in company with mylohyoid nerve. It supplies the mylohyoid muscle and submandibular and sublingual salivary glands.

From the facial part (see Chapter 3, page 59)

- Occipital artery:** It arises from the posterior aspect of the external carotid artery at the same level as the facial artery. It runs backwards and upwards under cover of lower border of the posterior belly of digastric muscle superficial to internal carotid artery, internal jugular vein, and last four cranial nerves, crosses the apex of the posterior triangle. Then it runs deep to the mastoid process grooving the lower surface of the temporal bone medial to the mastoid notch. It crosses the superior oblique and semispinalis capitis and apex of suboccipital triangle to reach underneath the trapezius muscle, which it pierces 2.5 cm away from the midline and comes to lie just lateral to the **greater occipital nerve**. It supplies most of the back of the scalp.

Branches

- Sternomastoid branches* are usually two in number. They run downwards and backwards, and supply the sternocleidomastoid. The upper one accompanies the spinal accessory nerve and lower one is hooked by the hypoglossal nerve.
- Mastoid branch* enters the cranial cavity through mastoid foramen and supplies mastoid air cells.
- Meningeal branches* enter the cranial cavity through jugular foramen and hypoglossal canal to supply dura mater of posterior cranial fossa.
- Muscular branches* supply adjoining muscles.
- Auricular branch* (occasional) supplies the cranial surface of the auricle.
- Descending branch* divides into superficial and deep branches. The superficial branch anastomoses with the superficial branch of transverse cervical artery and deep branch anastomoses with the deep cervical artery—a branch of the costocervical trunk of subclavian artery on the superficial and deep surfaces of the semispinalis capitis, respectively.

Clinical correlation

The descending branch of the occipital artery provides the chief collateral circulation after ligation of the external carotid or the subclavian artery (vide supra).

N.B.

- The *hypoglossal nerve* hooks the occipital artery under its site of origin.
- The *upper sternomastoid branch* of occipital artery accompanies the spinal accessory nerve and the lower sternomastoid branch crosses the hypoglossal nerve.
- Occipital artery* crosses the apical part of the posterior triangle.

5. **Posterior auricular artery:** It arises from the posterior aspect of the external carotid artery a little above the occipital artery. It crosses superficial to the stylohyoid muscle. It runs upwards and backwards parallel to the occipital artery along the upper border of the posterior belly of digastric muscle and deep to the parotid gland. Then it becomes superficial and lies on the base of mastoid process behind the ear which it supplies.

Branches

- Stylomastoid artery* enters the stylomastoid foramen to supply middle ear, mastoid air cells, and facial nerve.
- Auricular branch* supplies both cranial and lateral surfaces of the auricle.
- Occipital branch*, supplies scalp above and behind the auricle.

Clinical correlation

The posterior auricular artery is cut in incisions for mastoid operations.

6. **Ascending pharyngeal artery:** It is a slender artery that arises from the medial aspect of the external carotid artery near its lower end. It runs vertically upwards between the side wall of the pharynx and internal carotid artery up to the base of the skull.

Branches

- Pharyngeal and prevertebral branches* to corresponding muscles.
 - Meningeal branches*, which traverse foramina in the base of the skull.
 - Inferior tympanic*, which supplies medial wall of tympanic cavity.
 - Palatine branches*, which accompany levator veli palatini to the palate.
7. **Superficial temporal artery:** It is the smaller but more direct terminal branch of the external carotid artery. It begins behind the neck of the mandible deep to the upper part of the parotid gland. It runs vertically upwards crossing the root of zygoma in front of the tragus where its pulsation can be felt.

About 5 cm above the zygoma, it divides into anterior and posterior branches, which supply the temple and scalp.

Branches

- Transverse facial artery* runs forwards across the masseter below the zygomatic arch.
- Anterior auricular branch*, supplies the lateral surface of auricle and external auditory meatus.
- Zygomatico-orbital artery* runs forwards along the upper border of zygomatic arch between two layers of temporal fascia and reaches the lateral angle of the eye.

- Middle (deep) temporal artery* runs on the temporal fossa deep to temporalis muscle and supplies temporalis muscle and fascia.
- Anterior (frontal) and posterior (parietal) terminal branches*.

The *anterior branch* supplies the muscles and skin of the frontal region. It is very tortuous and anastomoses with the branches of the ophthalmic artery. The *posterior branch* supplies skin and the auricular muscles.

Clinical correlation

- **Superficial temporal pulse:** The pulsations of superficial temporal artery can be readily felt in front of the tragus of the ear (*where it crosses the root of zygoma, the preauricular point*). It serves the useful purpose to anesthetists to whom the radial pulse is not available during surgery. For this reason, it is also called **anesthetist's artery**.
- The course of anterior terminal branch of the superficial temporal artery on the forehead can clearly be seen in a bald angry man. It becomes noticeably more tortuous with increasing age.

8. **Maxillary artery:** It is the larger terminal branch of the external carotid artery (see Chapter 10, page 136).

Internal Carotid Artery

The internal carotid artery is one of the two terminal branches of the common carotid artery but it is more direct. It is considered as an upward continuation of the common carotid artery. *It supplies structures inside the skull and in the orbit. It is the principal artery to supply the brain and eye.*

It begins as the upper border of the lamina of thyroid cartilage at the level of the disc between C3 and C4 vertebrae and runs upwards to reach the base of the skull, where it enters the carotid canal in the petrous temporal bone. It emerges in the cranial cavity by passing through the upper part of the foramen lacerum. In the cranial cavity, it enters the cavernous sinus and pursues a tortuous course before it ends below the anterior perforated substance of the brain by dividing into the *anterior and middle cerebral arteries*.

Parts

For the sake of convenience, the course of the internal carotid artery is divided into the following four parts:

1. **Cervical part:** It ascends vertically upwards from its origin to the base of the skull to reach the lower end of carotid canal and lies on the front of transverse process of upper cervical vertebrae. In the neck, the internal carotid artery is enclosed in the carotid sheath along with the internal jugular vein and vagus nerve.

The lower part of the artery is superficial and located in the carotid triangle. The upper part is deeply located

and lies deep to the posterior belly of digastric muscle, styloid process with structures attached to it, and parotid gland.

At the upper end, the internal jugular vein lies posterior to the internal carotid artery. Here the last four cranial nerves (glossopharyngeal, vagus, accessory, and hypoglossal) lie between the internal jugular vein and internal carotid artery.

Branches

In the neck, the internal carotid artery gives no branches.

2. **Petrous part:** The internal carotid artery enters the petrous part of the temporal bone in a carotid canal. It first runs upwards and then turns forwards and medially at the right angle. It emerges at the apex of petrous temporal bone in the posterior wall of foramen lacerum, and passes through its upper part to enter the cranial cavity.

Branches

- (a) *Caroticotympanic branches* to middle ear, which anastomose with the anterior and posterior tympanic arteries.
 - (b) *Pterygoid branch (small and inconstant)* enters the pterygoid canal and anastomoses with the greater palatine artery.
3. **Cavernous part:** This part lies within the cavernous sinus. From foramen lacerum, the internal carotid artery ascends and enters the cavernous sinus. In the sinus, it passes forwards along the side of sella turcica in the floor and medial wall of the sinus. Here it lies outside the endothelial lining of the sinus and related to the abducent nerve inferolaterally.

In the anterior part of the sinus, the artery ascends and pierces the dural roof of the sinus between the anterior and middle clinoid processes to reach underneath the cerebrum.

Branches

- (a) *Cavernous branches* to the trigeminal ganglion.
 - (b) *Superior and inferior hypophyseal arteries* to the hypophysis cerebri (pituitary gland).
4. **Cerebral part:** This part lies at the base of the brain. After emerging from the roof of the cavernous sinus, the artery turns backwards in the subarachnoid space along the roof of the cavernous sinus and lies below the optic nerve.

Finally it turns upwards by the side of the optic chiasma and reaches the anterior perforated substance of the brain located at the beginning of the stem of lateral sulcus of the cerebral hemisphere. Here it ends by dividing into anterior and middle cerebral arteries.

Branches

The branches of cerebral part of the internal carotid artery are described in detail in Chapter 29, page 407. The branches of internal carotid artery are summarized in Table 16.2.

Table 16.2 Summary of branches of the internal carotid artery

Part	Branches
Cervical part	No branches
Petrous part	1. Caroticotympanic branches 2. Pterygoid branch
Cavernous part	1. Cavernous branches 2. Superior and inferior hypophyseal arteries
Cerebral part	1. Ophthalmic artery 2. Anterior choroidal artery 3. Posterior communicating artery Terminal branches 4. Anterior cerebral artery 5. Middle cerebral artery

N.B.

Carotid siphon: The U-shaped bend formed by the internal carotid artery while passing through and above the cavernous sinus is called *carotid siphon*. It probably dampens down the pulsations of the artery. The carotid siphon is an important feature to be seen in cerebral angiography.

Clinical correlation

The carotid vessels are exposed during elective arterial surgery for aneurysms, arteriovenous fistulae, or arteriosclerotic occlusion. It is now established that partial or complete obstruction due to arteriosclerosis is a common cause of cerebral stroke. In fact, it may account for 20% of the cerebrovascular accidents, which at one time were believed to be either due to intracranial hemorrhage or thrombosis.

The structures passing between the external and internal carotid arteries are as follows (Fig. 16.12):

1. Deep part of the parotid gland.
2. Styloid process.
3. Styloglossus muscle.
4. Stylopharyngeus muscle.
5. Glossopharyngeal nerve.
6. Pharyngeal branch of the vagus nerve.

VEINS

The major veins draining the head and neck are subclavian, internal jugular, external jugular, and anterior jugular veins

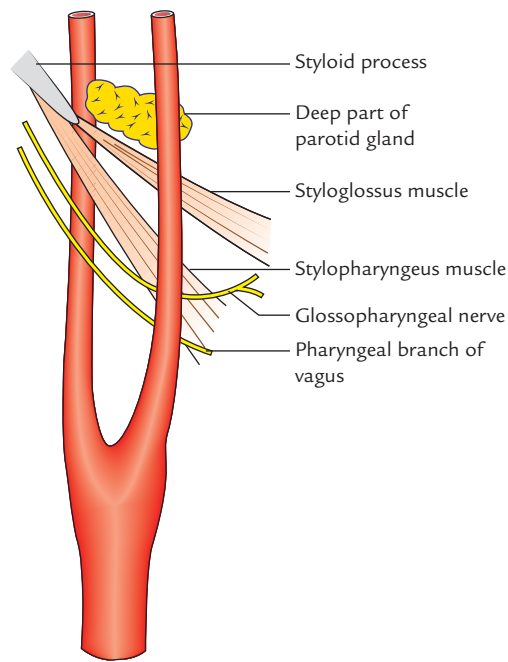


Fig. 16.12 Structures passing between the internal and external carotid arteries.

(Fig. 16.13). The *internal jugular vein is the principal vein of the head and neck region* for it drains the brain as well as most of the other tissues of the head and neck. The external jugular vein drains only a portion of extracranial tissues.

The valves in the lumen are mostly absent in the veins draining head and neck area, unlike in the rest of the body. This leads to two-way flow of blood dictated by local pressure changes. For this reason, infections in the head and neck area can lead to serious complications.

SUBCLAVIAN VEIN

It is the continuation of axillary vein and extends from the outer border of the first rib to the medial border of the scalenus anterior, where it joins the internal jugular vein to form brachiocephalic vein (Fig. 16.13). *The subclavian vein is principally the vein of the upper limb.*

The subclavian vein forms an arch across the pleura at a level below the arch of the subclavian artery. The two arches are separated from each other by the scalenus anterior.

It seldom rises above the level of the clavicle and possesses a pair of valves about 2 cm from its termination.

Relations (Fig. 16.14)

In front: Clavicle and subclavius muscle.

Behind: Subclavian artery with intervening scalenus anterior muscle and phrenic nerve.

Below: First rib and cupola of pleura.

Tributaries

The following are the tributaries of the subclavian vein:

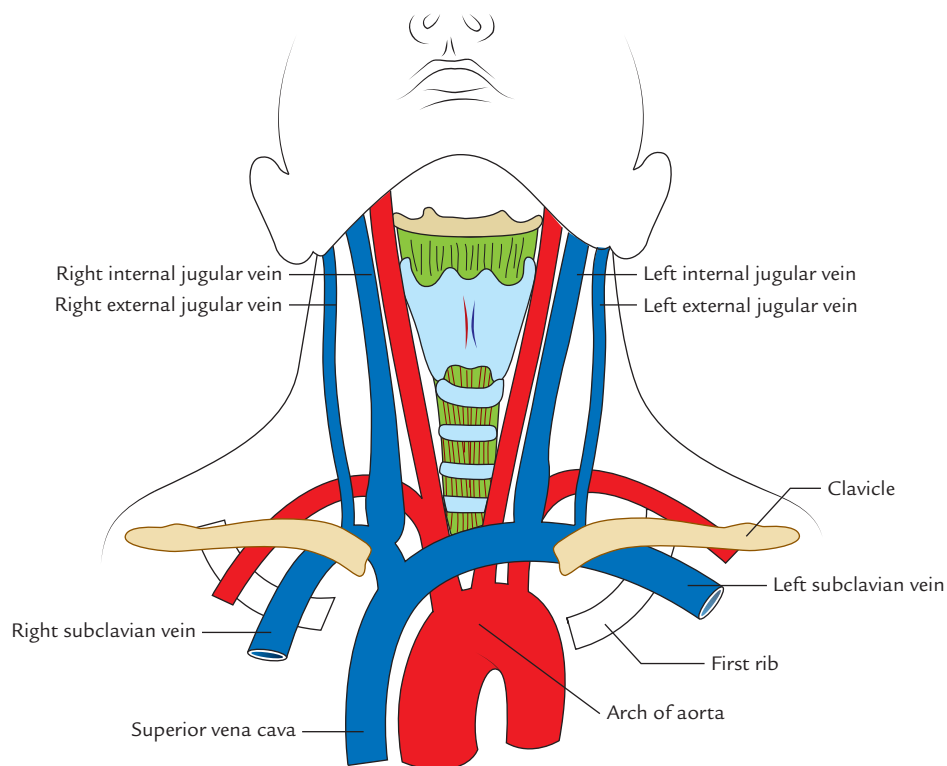


Fig. 16.13 Great blood vessels at the root of the neck.

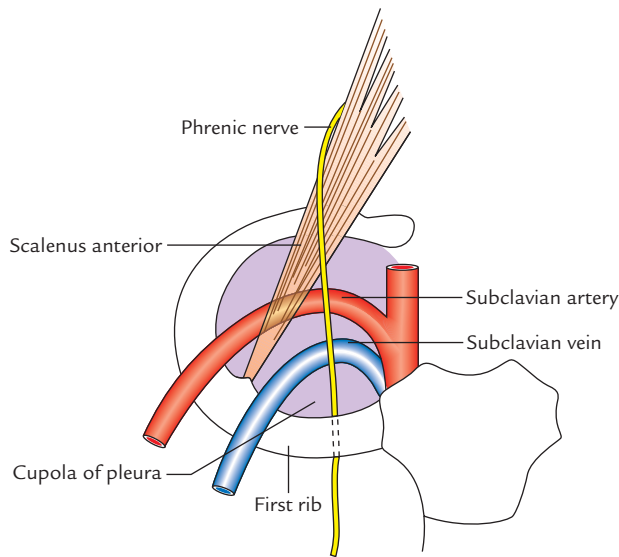


Fig. 16.14 Relations of the subclavian vein.

1. External jugular vein.
2. Dorsal scapular vein.
3. Thoracic duct on the left side and right lymphatic duct on the right side
4. Anterior jugular vein. } Only sometimes
5. Cephalic vein. }

Clinical correlation

- **Subclavian vein catheterization:** The subclavian vein is located immediately posterior to the medial third of the clavicle. It can be catheterized both from below (*infraclavicular approach*) and above (*supraclavicular approach*) the clavicle.

In *infraclavicular approach*, the needle is inserted just below the lower border of the clavicle at the junction of its medial one-third and lateral two-third. The needle is directed upwards and posteriorly towards the middle of the jugular notch.

In *supraclavicular approach*, the needle is inserted at the junction of lateral border of the clavicular head of sternocleidomastoid and upper border of the clavicle. The needle is directed downwards and medially towards the mediastinum.

- **Subclavian vein thrombosis:** It can be spontaneous (primary) or secondary. Clinically, it presents as edema of the upper limb especially after exercise. The *primary thrombosis* occasionally occurs due to excessive and unaccustomed use of arm at the shoulder joint. The *secondary thrombosis* occurs as a complication of an indwelling venous catheter.

INTERNAL JUGULAR VEIN

The internal jugular vein is usually the largest vein in the neck. It begins as the direct continuation of the sigmoid

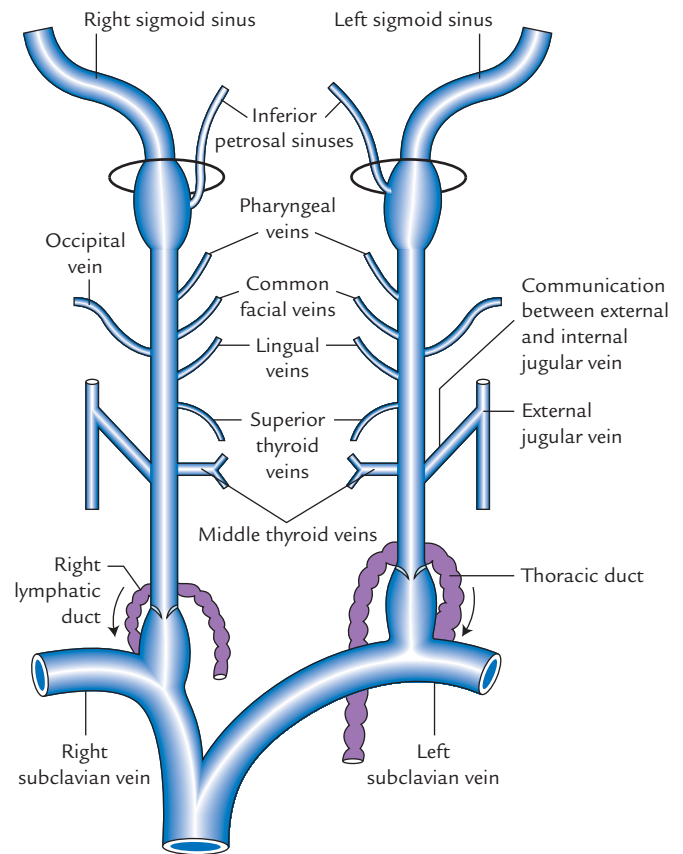


Fig. 16.15 Beginning and termination of the internal jugular veins along with their tributaries.

sinus at the base of the skull below the jugular foramen and descends vertically downwards to end behind the sternal end of the clavicle by joining the subclavian vein to form the brachiocephalic vein. The internal jugular vein drains brain and most of the tissues of the head and neck (Fig. 16.15).

N.B. The right internal jugular vein is usually larger than the left because it drains the blood from the larger superior sagittal sinus, c.f. the left internal jugular vein drains blood from the smaller inferior sagittal sinus.

Special Features

1. It presents two dilatations:
 - First, at its commencement, which lies in the jugular fossa of the temporal bone. It is known as **superior bulb** and is related to the floor of the middle ear.
 - Second, close to its termination, which lies in the lesser supraclavicular fossa between the sternal and clavicular heads of sternocleidomastoid. It is known as **inferior bulb** and is guarded by a pair of valves.
2. It is vertically applied to the lateral side of the internal and common carotid arteries, enclosed with them and the vagus nerve in the facial sheath called **carotid sheath**.
3. The deep cervical lymph nodes lie along its entire course.

- It is remarkably constant in position and can be marked on the surface by a vertical line extending from midpoint between the tip of the mastoid process and the angle of the mandible, to the sternoclavicular joint.

N.B. At the lower end, both the internal jugular veins (right and left) tend to shift to the right, so that the right comes to lie further lateral to the right common carotid artery while the left tends to overlap the left common carotid artery.

Relations

Deep (posterior):

From above downwards, these are (Fig. 16.16) as follows:

- Rectus capitis lateralis.
- Transverse process of atlas.
- Levator scapulae.
- Scalenus medius and cervical plexus.
- Scalenus anterior and phrenic nerve.
- Thyrocerical trunk and first part of vertebral artery.
- First part of the subclavian artery.
- Thoracic duct on the left side.
- The sternocleidomastoid overlaps the upper part and covers the lower part of the vein.

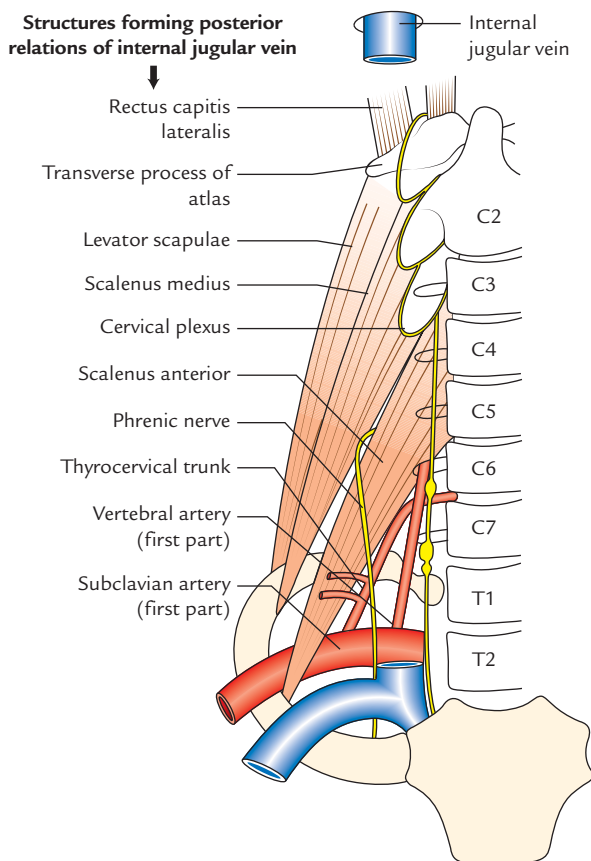


Fig. 16.16 Deep (posterior) relations of the internal jugular vein.

Superficial (anterolateral; Fig. 16.17):

These are as follows:

- Crossed by two muscles**
 - Posterior belly of digastric muscle in the upper part.
 - Inferior belly of omohyoid in the lower part.
- Crossed by two arteries**
 - Occipital artery.
 - Posterior auricular artery.
- Crossed by one vein: anterior jugular vein**
- Crossed by two nerves**
 - Spinal accessory nerve.
 - Inferior root of ansa cervicalis (descendens cervicalis).
- At the base of skull the internal carotid artery lies in front of the internal jugular vein and the last four cranial nerves intervene between the vein and the artery.

Medial:

Medially the vein is related to:

- Internal carotid artery and 9th, 10th, 11th, and 12th cranial nerves in the upper part.
- Common carotid artery and vagus nerve in the lower part.

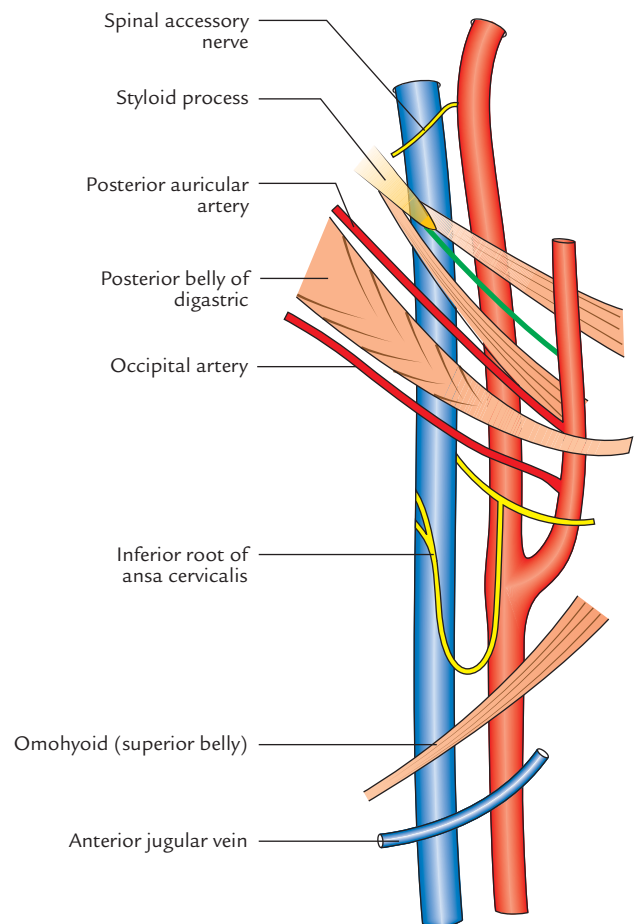


Fig. 16.17 Superficial (anterolateral) relations of the internal jugular vein.

Tributaries (Fig. 16.15)

1. Inferior petrosal vein—is usually the first tributary and joins the internal jugular vein immediately below the jugular foramen.
2. Pharyngeal veins—from pharyngeal plexus.
3. Common facial vein.
4. Lingual vein.
5. Superior thyroid vein.
6. Middle thyroid vein.
7. Occipital vein (only sometimes).

In addition to the above mentioned tributaries, the **right lymphatic duct** on the right side and **thoracic duct** on the left side, usually open into internal jugular vein or into the junction between the internal jugular vein and the subclavian vein.

N.B. In the upper part of the neck internal jugular vein may communicate with the external jugular vein by an *oblique jugular vein* across the anterior border of sternocleidomastoid muscle.

Clinical correlation

- The internal jugular vein acts as a guide for surgeons during removal of deep cervical lymph nodes. The facial (or common facial) vein is most important tributary of the internal jugular vein for it serves as a useful landmark in removal of the jugulodigastric (tonsillar) and upper anterior group of deep cervical lymph nodes.
- The malignant and tuberculous lymph nodes often get adhered to the internal jugular vein and not uncommonly the surgeon has to resect a portion of the vessel in order to facilitate their removal.
- Sometimes a thrill is felt at the root of the neck (in lesser supraclavicular fossa) during contraction of atria in systole, particularly in case of mitral stenosis.
- The vein is safely cannulated by inserting a needle at the apex of the lesser supraclavicular fossa. The needle is directed backwards and upwards to avoid the puncture of cervical pleura, which, if punctured, will lead to pneumothorax.

The **anterior jugular** and **external jugular veins** are described in detail in Chapter 4.

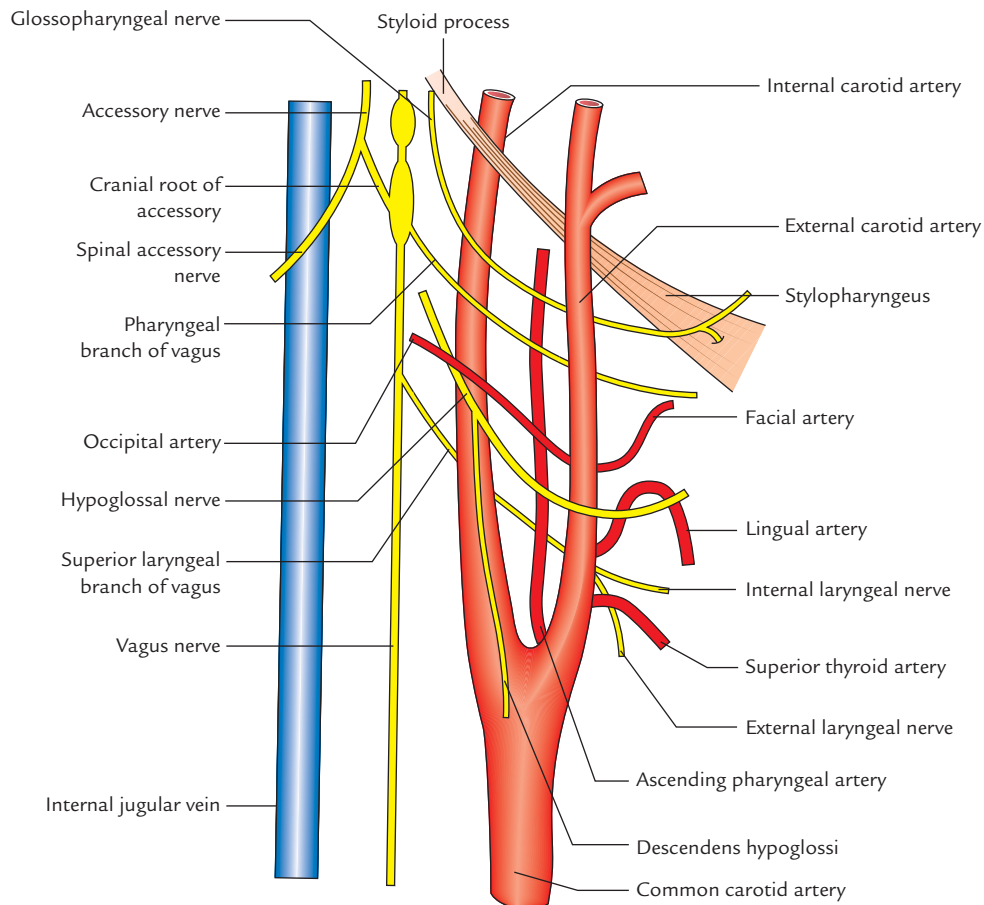


Fig. 16.18 Carotid arteries and nerves associated with them in the neck.

CAROTID SHEATH

The carotid sheath extends from the base of the skull above to the arch of the aorta below. At the upper end it is attached to the margins of carotid canal and the jugular fossa.

The upper part of the carotid sheath contains internal carotid artery, internal jugular vein, and last four cranial nerves (Fig. 16.18). Medial to it lies pharynx, lateral to it lies styloid apparatus, anterior to it lies infratemporal fossa, and posterior to it lies cervical sympathetic trunk on the prevertebral fascia.

The lower part of carotid sheath contains common carotid artery, internal jugular vein, and vagus nerve.

STYLOID APPARATUS

The styloid apparatus consists of styloid process and structures attached to it.

The structures attached to styloid process (Fig. 16.19) are:

1. **Three muscles:** stylohyoid, styloglossus, and stylopharyngeus.
2. **Two ligaments:** stylohyoid and stylomandibular.

The five elongated structures attached to styloid process resemble the **reins of a chariot**. Two of these reins (ligaments) are non-adjustable, whereas the remaining three reins (muscles) are adjustable, with each being controlled by separate cranial nerve, e.g., stylohyoid, stylopharyngeus, and styloglossus are supplied by 7th, 9th, and 12th cranial nerves, respectively.

STYLOID PROCESS

The styloid process is long, slender, pointed bony process projecting anteroinferiorly from the inferior aspect of the

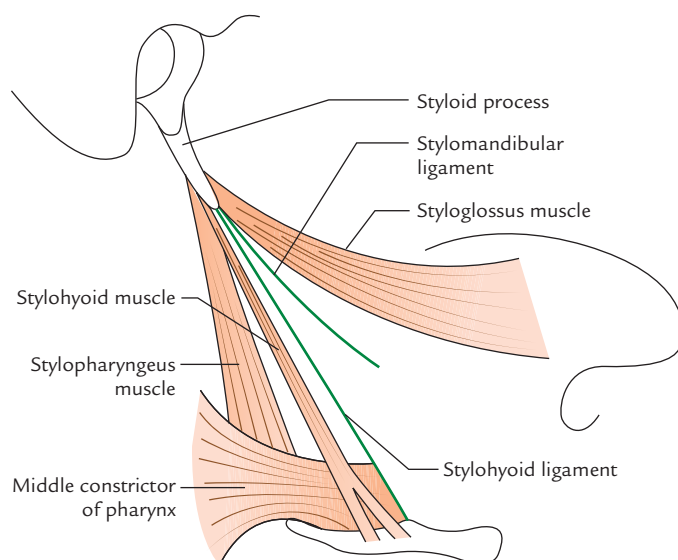


Fig. 16.19 Styloid apparatus.

temporal bone. Its length is variable, ranging from 2–3 mm to an average of 2.5 cm.

Its proximal part (*tympanohyal*) is ensheathed by the tympanic plate, while its muscles and ligaments are attached to its distal part (*stylohyal*). Its relation *in vivo* is important:

1. It projects between external and internal carotid arteries.
2. It is interposed between the parotid gland laterally and internal jugular vein medially.
3. Laterally, facial nerve crosses its base and external carotid artery crosses its apex.

MUSCLES

Stylohyoid Muscle

It is a slender muscle extending from posterior surface of the styloid process to the hyoid bone at the junction between its body and greater cornu (for details see Chapter 9). It helps in controlling movements of the hyoid bone.

Styloglossus Muscle

It extends from anterior surface of the tip of the styloid process and adjoining part of the stylohyoid ligament to the side of the tongue. It pulls the tongue upwards and backwards (for details see Chapter 9).

Stylopharyngeus Muscle

It extends from medial side of the base of the styloid process to the posterior border of the lamina of the thyroid cartilage. It helps to elevate the larynx during swallowing and phonation (for details see Chapter 14).

LIGAMENTS

Stylohyoid Ligament

It extends from tip of the styloid process to the lesser cornu of the hyoid bone.

Stylomandibular Ligament

It extends from the tip of the styloid process to the angle of ramus of the mandible. Sometimes it is pierced by the cervical part of the facial artery.

Clinical correlation

Eagle's syndrome: Normally, the tip of styloid process is located between the external and internal carotid arteries, just lateral to the tonsillar fossa. The elongated styloid process or calcification of stylohyoid ligament can cause recurrent throat pain in the region of tonsillar fossa and upper neck, which radiates to the ipsilateral ear. It aggravates during swallowing. This clinical condition is termed *styalgia* or *Eagle's syndrome*.

LYMPHATIC DRAINAGE OF THE HEAD AND NECK

The knowledge of lymphatic drainage of the head and neck is extremely important because the cancers arising in this region have predictable patterns of spread through the chains of lymph nodes in the neck, which help the surgeons to remove the desired lymph nodes. The lymph nodes and other lymphoid tissues in the head and neck are often inflamed and produce swellings, which are examined by physicians in day-to-day practice. All the lymph from the region of head and neck drains into *deep cervical lymph nodes* either (a) directly from the tissues or (b) indirectly after passing through the outlying groups of lymph nodes.

The efferents from deep cervical nodes form the **jugular trunk**, which on the right side drains into the **right lymphatic duct** and on the left side into the **thoracic duct**. The right lymphatic duct and thoracic duct generally empty into the junction of the subclavian and internal jugular veins on their respective sides.

LYMPH NODES

Out of total 800 lymph nodes in the body, about 300 lymph nodes are located in the region of the head and neck only. The lymph nodes in the region of the head and neck are broadly classified into two groups: peripheral and terminal (Fig. 16.20).

PERIPHERAL LYMPH NODES

Peripheral lymph nodes (also called *outlying lymph nodes*). They are usually found in groups, which are arranged in outer and inner circles (Fig. 16.21):

1. **Outer circle:** It is formed by lymph node groups, which form the **pericervical** or **cervical collar** at the junction of the head and neck (craniocervical junction) and extends from chin in front to the occiput behind. They include submental, submandibular, superficial parotid (preauricular), mastoid (postauricular), and occipital nodes.

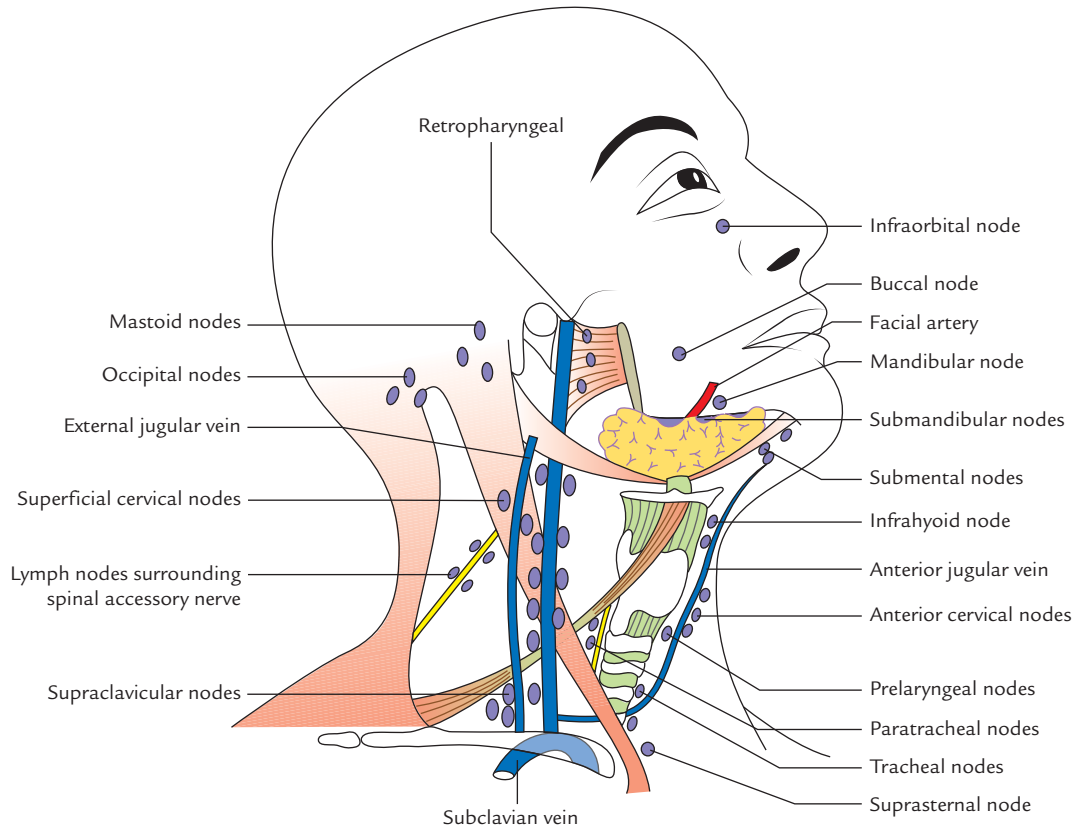


Fig. 16.20 Lymph nodes of the head and neck.

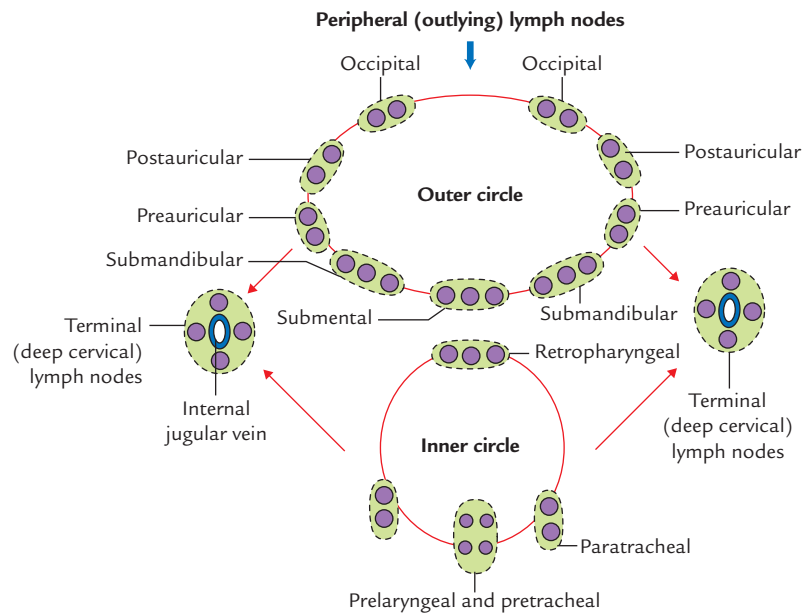


Fig. 16.21 General plan of location of the lymph node groups in the region of the head and neck.

Outlying extensions of lymph node groups of pericervical collar:

- (a) **Facial nodes:** These are extensions of submandibular nodes and include:
 - a small *buccal node* lying on the lateral surface of the buccinator along the facial vein.
 - a small *mandibular node* which is frequently present where facial vessels cross the lower border of the mandible.
 - a small *infraorbital node* lying just below the orbit.
 - (b) **Superficial cervical nodes:** They are situated superficial to sternomastoid (upper part) along the external jugular vein. These are the extensions of parotid nodes.
 - (c) **Anterior cervical nodes:** They are situated along the anterior jugular vein. One member of this group frequently lies in the suprasternal space (*suprasternal node*). They are extensions of submental lymph nodes.
2. **Inner circle:** The inner circle is formed by following lymph node groups, which lie deep to the investing layer of deep cervical fascia (Fig. 16.21):
- (a) **Infrahyoid nodes:** These lie in front of thyrohyoid membrane.
 - (b) **Prelaryngeal nodes:** These are situated in front of the conus elasticus or cricothyroid membrane.
 - (c) **Pretracheal lymph nodes:** These lie in front of trachea below the isthmus of thyroid gland.

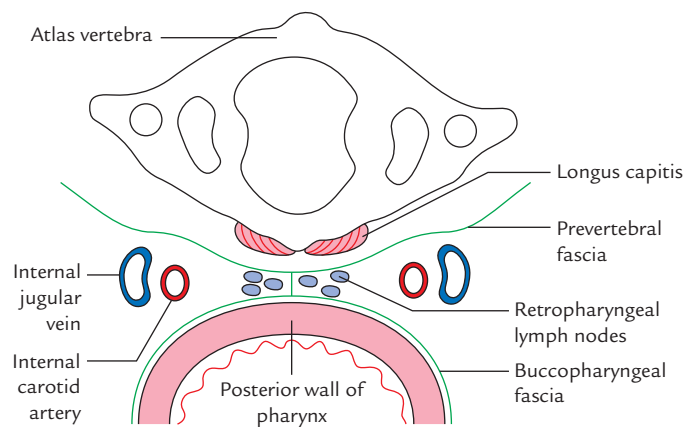


Fig. 16.22 Retropharyngeal lymph nodes.

3. **Paratracheal nodes:** These nodes flank the trachea and esophagus on either side along the recurrent laryngeal nerves.
4. **Retropharyngeal lymph node:** These lie posterior to pharynx and in front of prevertebral fascia in the retropharyngeal space (Fig. 16.22).

N.B.

Deep to inner circle, there is a submucosal ring of aggregated masses of lymphoid tissue called *tonsils*, which surround the commencement of air and food passages. These together constitute the *Waldeyer's lymphatic ring* (Fig. 16.23). The lymph from lymphoid tissue of this ring

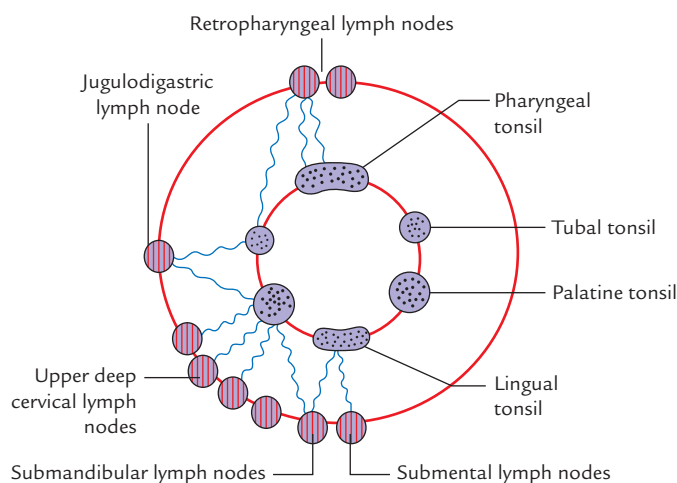


Fig. 16.23 Waldeyer's internal and external rings.

drains into pericervical chain and deep cervical chain, which constitutes the *external ring of Waldeyer*.

TERMINAL LYMPH NODES

These are **deep cervical lymph nodes** that lie along and around the internal jugular vein, some within the carotid sheath and some on the surface of the sheath, under cover of sternocleidomastoid.

For the convenience of description deep cervical lymph nodes are divided into upper and lower groups (superior and inferior deep cervical nodes), though there is no clear demarcation between them:

1. **Superior group of deep cervical lymph nodes:** They lie above the omohyoid. One lymph node of this group is situated below the posterior belly of digastric between the angle of the mandible and anterior border of the sternocleidomastoid in the triangle formed by posterior belly of digastric, facial vein, and internal jugular vein. It is called **jugulodigastric node**.

It drains the lymph primarily from the palatine tonsil. Therefore it is also termed **lymph node of the tonsil**. When enlarged due to pathology in the palatine tonsil, it is easily palpable behind and below the angle of the mandible.

2. **Lower group of deep cervical lymph nodes:** One of the lymph nodes of this group lies above the intermediate tendon of omohyoid posterior to the internal jugular vein. It is called **jugulo-omohyoid lymph node**. Since this lymph node drains lymph primarily from the tongue, it is termed **lymph node of the tongue**. This node lies deep to sternocleidomastoid, and therefore, can be palpated only if enlarged considerably.

Some nodes of this group extend into the supraclavicular fossa and are related to brachial plexus and subclavian vessels. These are termed **supraclavicular lymph nodes (Virchow's lymph nodes)**. The left supraclavicular lymph nodes are clinically important because they are common site of metastasis from malignant disease (cancer) of the stomach. The testicular and esophageal cancers can also metastasize in these nodes. The Virchow's lymph nodes are often palpable in cancer stomach. One or two lymph nodes of this group lie in contact with accessory nerve at a higher level in the posterior triangle.

Clinical correlation

Surgical neck dissection: The cancers arising in the head and neck region from structures such as nasopharynx, paranasal air sinuses, oral cavity, oropharynx, larynx, and thyroid gland have predictable patterns of spread through the chains of lymph nodes in the neck. When operating to remove malignant lesion in this region, it is vitally important to understand these patterns of spread. The surgeons classify lymph nodes in neck into the following levels:

- **Level I nodes** are in the submental and submandibular triangles.
- **Level II nodes** lie around the upper portion of internal jugular vein and upper part of spinal accessory nerve. They extend from the base of the skull to the bifurcation of the common carotid artery or the hyoid bone.
- **Level III nodes** lie around the middle third of the internal jugular vein and extend from inferior border of level II to the intermediate tendon of omohyoid (cricoid cartilage).
- **Level IV nodes** lie around the lower third of the internal jugular vein and extend from lower border of level III to the clavicle. It also includes supraclavicular lymph nodes.
- **Level V nodes** are in the posterior triangle of the neck, related to the spinal accessory nerve.
- **Level VI nodes** are nodes surrounding the midline visceral structures and include the pretracheal and paratracheal nodes.
- **Level VII nodes** are in the superior mediastinum. Knowing which levels of nodes are likely to be involved in the metastatic spread of a particular cancer, an appropriate nodal clearance is undertaken.

The classical radical neck dissection involves the removal of level I to V nodes and removal of the sternocleidomastoid muscle, internal jugular vein, and spinal accessory nerve.

The modified **radical neck dissection** (also called **functional neck dissection**) involves the removal of level I to V nodes but spares either or all of sternocleidomastoid muscle, internal jugular vein, and spinal accessory nerve.

The **selective neck dissection** involves some but not level I to V nodes.

Golden Facts to Remember

- | | |
|---|--|
| ▶ Chief arteries of the head and neck | Right and left common carotid arteries |
| ▶ Chief veins of the head and neck | Right and left internal jugular veins |
| ▶ All the branches of subclavian artery (generally) arise from its first part <i>except</i> | Costocervical trunk on the right side which arises from second part of that side |
| ▶ Largest branch of the first part of the subclavian artery | Vertebral artery |
| ▶ Shortest branch of the subclavian artery | Thyrocervical trunk |
| ▶ Most superficial part of the subclavian artery | Third part |
| ▶ Most constant pulse in the body | Carotid pulse |
| ▶ Anesthetist's artery | Superficial temporal artery |
| ▶ All the lymph node groups of pericervical collar are paired <i>except</i> | Submental group of lymph nodes which is unpaired |
| ▶ Lymph node of tonsil | Jugulodigastric lymph node |
| ▶ Lymph node of tongue | Jugulo-omohyoid lymph node |

Clinical Case Study



A 67-year-old man was keeping quite well until he suddenly developed weakness in his limbs on the right side. This lasted for about 12 hours and then improved spontaneously and he recovered completely after 24 hours. His family physician thought that he may have a *transient ischemic attack of brain (cerebral stroke)*. He was referred to a neurocentre by his family physician for thorough check-up by a neurosurgeon. On examination, the surgeon heard a bruit at the level of origin of common carotid artery on the left side. The color Doppler ultrasound scan revealed more than 75% narrowing of the internal carotid artery at its origin. A carotid angiogram confirmed this narrowing.

Questions

1. At what level does the common carotid terminate by dividing into internal and external carotid arteries?
2. What is bruit?

3. What are the main relations at the bifurcation of common carotid artery?
4. Why does a patient develop signs of a cerebral stroke if there is formation of atheroma in the internal carotid artery?

Answers

1. At the level of upper border of lamina of the thyroid cartilage.
2. It is a noise of blood flow produced when it passes through a narrowed vessel.
3. The common carotid artery is present in the carotid sheath containing internal jugular vein laterally and vagus nerve between and behind the artery and vein. The cervical sympathetic chain lies behind the carotid sheath on prevertebral fascia.
4. A portion of atheroma gets detached, and enters the middle cerebral artery and blocks it. This leads cerebral ischemia. Consequently, the patient develops the signs of cerebral stroke.

Nose and Paranasal Air Sinuses

NOSE

The nose is the uppermost part of the respiratory tract and contains the peripheral organ of smell.

It consists of the external nose and the nasal cavity. The Greek Word for nose is *rhinos*. Thus the study of the nose and its diseases is termed *rhinology*.

The functions of the nose are:

1. Respiration.
2. Olfaction.
3. Protection of the lower respiratory passages.
4. Air conditioning of the inspired air.
5. Vocal resonance.
6. Nasal reflex functions (e.g., sneezing).

A detailed knowledge of anatomy of the nose is essential to:

1. ENT and plastic surgeons to correct the various deformities of nose and enhance the looks of the face.

2. Physicians to treat diseases like rhinitis, sinusitis, and respiratory diseases including asthma due to environmental pollution.

EXTERNAL NOSE

FEATURES

The external nose is a pyramidal projection in the mid face. It presents the following features (Fig. 17.1):

1. **Tip** (or apex), the lower free end.
2. **Root or bridge**, the upper narrow part, which is continuous with the forehead.
3. **Dorsum**, a round border between tip and root where sides of the nose meet.
4. **Nostrils or nares**, the two piriform apertures at the broad lower end.
5. **Ala**, the lower flared part on the side of nose.

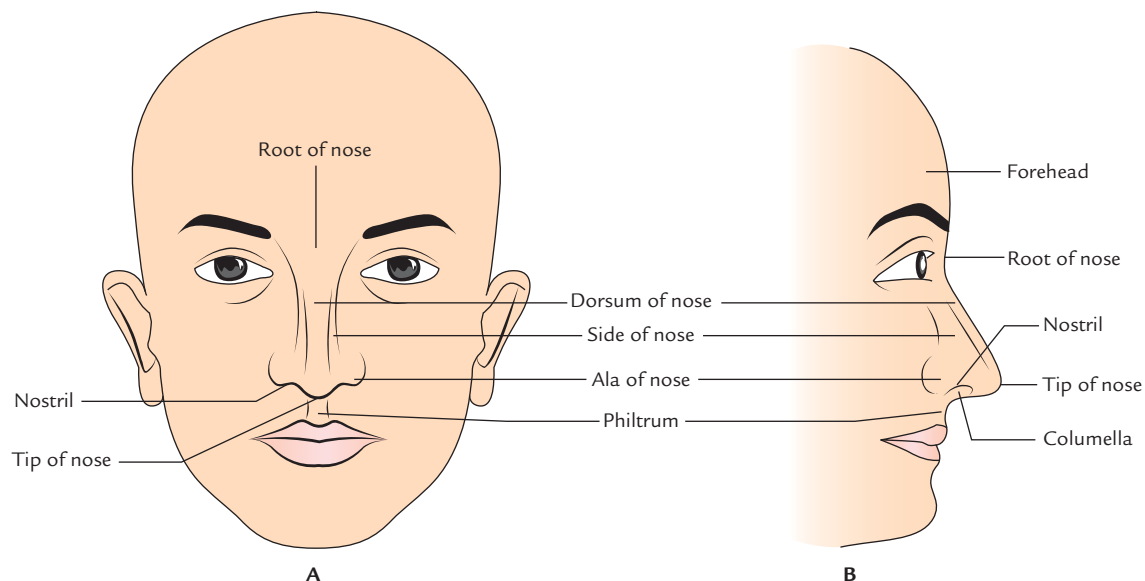


Fig. 17.1 Features of the external nose: A, front view; B, lateral view.

Skin

The skin covering the nose (nasal skin) is thin and loosely attached to the underlying structures, hence freely mobile. Over the apex and alae, it is thicker and more adherent and contains large sebaceous glands, whose orifices are usually very distinct. The hypertrophy of these sebaceous glands gives rise to a lobulated tumor—the **rhinophyma**.

Skeleton

The skeletal framework (Fig. 17.2) of the external nose is partly bony and partly cartilaginous.

The upper one-third of the external nose is bony and lower two-third is cartilaginous.

The **bony framework** is formed by:

- two nasal bones (forming the **bridge of the nose**), and
- frontal processes of the maxillae.

The two nasal bones meet in the midline and rest on the upper part of the nasal process of the frontal bone. They are held together between the frontal processes of the maxillae. The bony part of external nose terminates in front and below as the **piriform aperture**.

The **cartilaginous framework** of the nose is formed by five **main cartilages** and several additional tiny ones.

The five main cartilages of the nose are as follows:

- Two lateral cartilages.
- A single median septal cartilage.
- Two major alar cartilages.

The lateral and major alar cartilages are also termed **superior** and **inferior lateral cartilages**, respectively.

The cartilaginous framework is anchored to the piriform aperture by fibrous tissue.

The lateral cartilages, one on each side, articulate above with the margin of piriform aperture formed by the frontal process of maxilla and the nasal bone and below with the major alar cartilage. Medially, it is continuous by a narrow bridge with the septal cartilage.

The major alar cartilage is U-shaped and comprises of a medial and lateral crus. The medial crura of two sides meet in the midline below the lower margin of the septal cartilage to form the lower part of the nasal septum called **columella**.

The anterosuperior border of septal cartilage runs from under the nasal bones to the tip of the nose. It supports the dorsum of the cartilaginous part of the nose.

The lateral crus of major alar cartilage extends into the ala of the nose but does not reach the bony margin; the gap is filled by fibrofatty tissue and minor alar cartilages.

In addition to five main cartilages of the nose, there are two or more tiny cartilages, which lie above and lateral to major alar cartilage on either side and termed **minor alar** (or

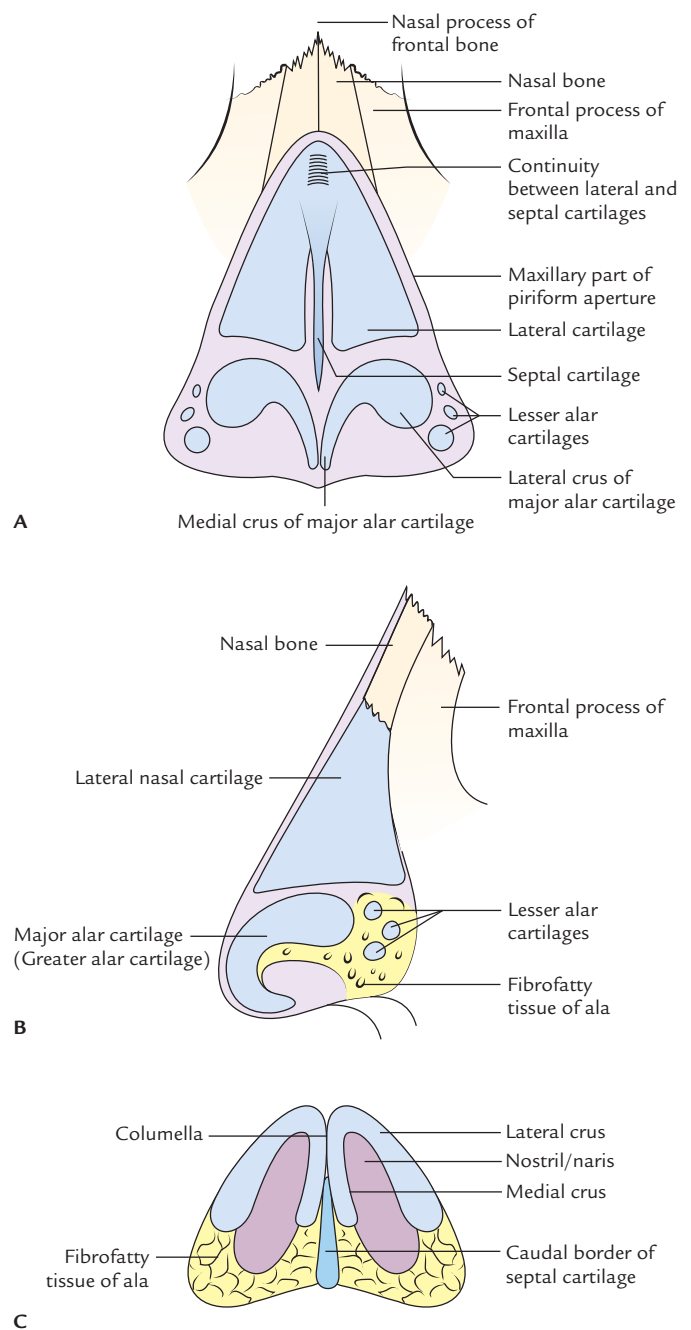


Fig. 17.2 Osseocartilaginous framework of the external nose: **A**, anterior view; **B**, lateral view; **C**, basal view.

sesamoid) cartilages. They are of no functional and clinical significance.

Clinical correlation

- **Nasal fractures:** Because the nose is the most projecting part of the face, the fractures of nasal bones are common facial fractures.

- The medial and lateral crura of major alar cartilage maintain the patency of the nostril (Fig. 17.2). The angle between the medial and lateral crura is variable, being acute in high narrow noses, and obtuse in low broad noses with flaring alae. This anatomical fact is of great significance in plastic surgery of the nose.

NASAL CAVITY

The interior of the nose (also called internal nose) is divided into right and left nasal cavities by a nasal septum (Fig. 17.3A).

Each nasal cavity communicates with the exterior through nostril (or naris) and with the nasopharynx through the posterior nasal aperture (or the choana; Fig. 17.3B). Each nasal cavity is divided into two portions: (a) a small anteroinferior part lined by skin—the **vestibule** and (b) a large posterosuperior part lined by mucosa—the **nasal cavity proper**.

VESTIBULE OF NOSE

It is the anteroinferior part of nasal cavity, lined by skin. The skin contains sebaceous glands, hair follicles, and the stiff interlacing hair called **vibrissae**. Its upper limit on the lateral wall of nasal cavity is marked by **limen nasi**. Its medial wall is formed by a mobile **columella**.

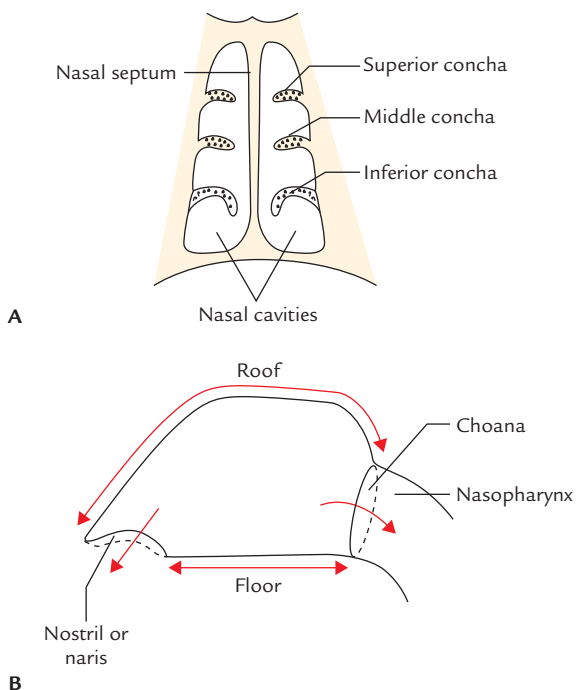


Fig. 17.3 Interior of the nose: **A**, division of the internal nose into right and left nasal cavities; **B**, communication of nasal cavity to exterior through nostril and to nasopharynx through choana.

NASAL CAVITY PROPER

Boundaries

The nasal cavity proper presents the following boundaries:

1. Roof.
2. Floor.
3. Medial wall (septum).
4. Lateral wall.

Roof: The roof is very narrow in front and widens to about 1 cm near the choanae. It is horizontal in the middle third, where it is formed by the cribriform plate of the ethmoid. Through this olfactory nerves enter the cranial cavity from the nasal cavity.

The anterior third of roof slopes downwards and forwards. It is formed by the nasal spine of the frontal, the nasal bone and the junction of the septal and lateral cartilages. The posterior third of the roof also slopes downwards and backwards (Fig. 17.3B). It is formed by the anterior surfaces of the body of the sphenoid.

Floor: The floor is almost horizontal. It is formed by the upper surface of the hard palate, i.e., anterior three-fourth is formed by palatine process of maxilla and posterior one-fourth is formed by the horizontal plate of the palatine bone.

Medial wall: It is formed by nasal septum. The nasal septum is a median osseocartilaginous partition between the two nasal cavities. It is seldom exactly in the median plane but bulges to one or the other side, more frequently to the right.

The **bony part** is formed by (Fig. 17.4):

- (a) perpendicular plate of ethmoid, which forms the posterosuperior part of the septum, and
- (b) vomer, which forms the posteroinferior part of the septum.

N.B. In addition, the nasal spine of frontal bone, crest formed by nasal bones, sphenoidal crest, and nasal crest formed by the fusion of palatine processes of maxillae and horizontal plates of palatine bones also contribute a bit in the formation of nasal septum.

The **cartilaginous part** is formed by (Fig. 17.4):

- (a) septal cartilage, which forms the major anterior part of the septum and fits in the angle between the vomer and perpendicular plate of ethmoid, and
- (b) septal processes of the two major alar cartilages.

N.B. The septal processes (medial crura) of two major alar cartilages are united together in the midline by a fibrous tissue to form *columella* (also called *columellar septum*).

Between the columella and caudal border of the septal cartilage, a small portion of septum is made up of double layer of the skin with no bony or cartilaginous support. This part is referred to as *membranous septum*.

Both columellar and membranous parts are freely movable from side-to-side.

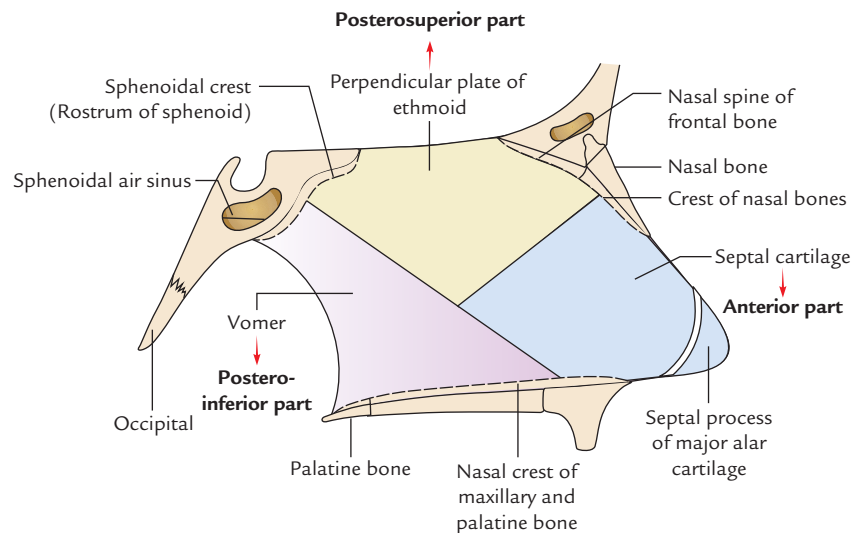


Fig. 17.4 Formation of the nasal septum.

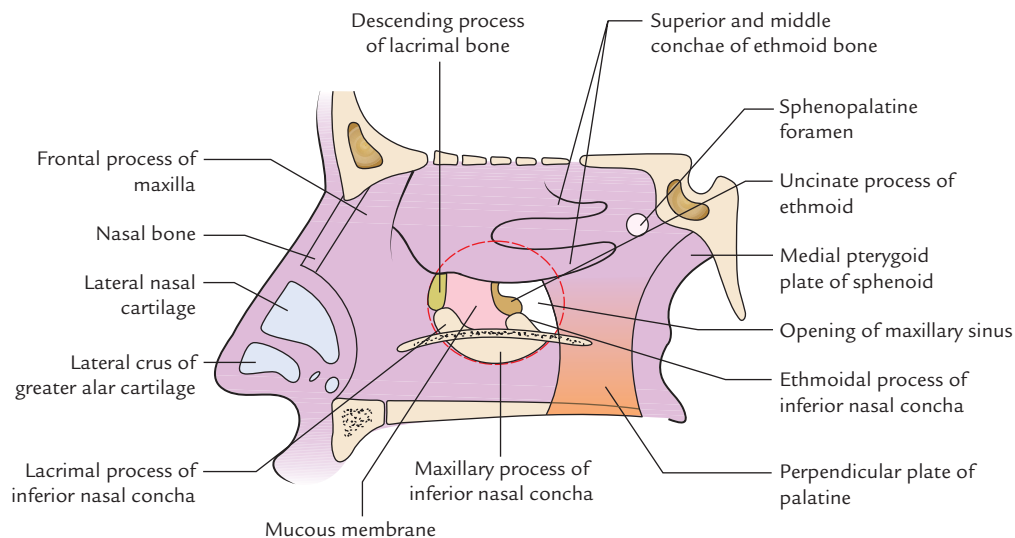


Fig. 17.5 Formation of the lateral wall of the nasal cavity. Red circle indicates the position of maxillary air sinus.

Clinical correlation

- **Deviated nasal septum (DNS):** The deviated nasal septum is not uncommon and is an important cause of nasal obstruction. The males are affected more than females. It occurs due to numerous factors such as trauma, developmental error, etc. If DNS is severe and causing mechanical obstruction, leading to difficulty in breathing sinusitis, headache, excessive snoring, etc., it is corrected by submucous resection (SMR) or septoplasty. (For details consult ENT textbooks.)
- The septal cartilage not only forms partition between the right and left nasal cavities but also provides support to

the dorsum of the anterior two-third of the nose. Therefore, its destruction due to disease or excessive removal in submucous resection leads to supratip depression of the external nose.

Lateral wall: The lateral wall of the nose (Fig. 17.5) is complicated. It is formed by a number of bones and cartilages (Fig. 17.5).

The **bones** forming the lateral wall are:

- nasal,
- frontal process of maxilla,
- lacrimal,

- (d) conchae and labyrinth of ethmoid,
- (e) inferior nasal concha,
- (f) perpendicular plate of palatine, and
- (g) medial pterygoid plate of sphenoid.

The **cartilages** forming the lateral wall are:

- (a) lateral nasal cartilage (upper nasal cartilage),
- (b) major alar cartilage (lower nasal cartilage), and
- (c) three to four tiny cartilages of the alae (minor alar cartilages).

Features (Fig. 17.6): The lateral wall is divided into the following three areas:

1. **Anterior part** presents a small depressed area, the **vestibule**. It is lined by the skin containing **vibrissae** (short, stiff curved hair).
2. **Middle part** is known as **atrium of the middle meatus**. It is limited above by a faint ridge of mucous membrane, the **agger nasi**. The curved mucocutaneous junction between the atrium and vestibule is known as **limen nasi**.
3. **Posterior part** presents three scroll-like projections, the **conchae or turbinates**. The spaces separating the conchae are called **meatuses**.

The **conchae and meatuses** form the main features of the lateral wall:

Conchae (also called **turbinates**) are the curved bony projections directed downwards and medially. Below and lateral to each concha is a corresponding **meatus**. From above downwards the conchae are superior, middle, and inferior nasal conchae. Sometimes a 4th concha, the concha suprema is also present.

Conchae:

1. Superior and middle nasal conchae are the projections from the medial surface of the ethmoidal labyrinth.

2. Inferior concha is an independent bone.
3. The superior concha is smallest and inferior concha is largest in size.

Meatuses:

Meatuses are the passages (recesses) beneath the overhanging conchae. They are visualized once conchae are removed.

1. **Inferior meatus** is the largest and lies underneath the inferior nasal concha.
2. **Middle meatus** lies underneath the middle concha. It presents following features:
 - (a) *Ethmoidal bulla* (bullae ethmoidalis), a round elevation produced by the underlying middle ethmoidal sinuses.
 - (b) *Hiatus semilunaris*, a deep semicircular sulcus below the bulla ethmoidalis.
 - (c) *Infundibulum*, a short passage at the anterior end of middle meatus.
3. **Superior meatus** is the smallest and lies below the superior concha.

A triangular depression, above and behind the superior concha is known as the **sphenoethmoidal recess**.

Openings (Fig. 17.7): The lateral wall of the nose has number of openings. These are listed in Table 17.1.

Lining of Nasal Cavity

The lining of the various regions of nasal cavity (Fig. 17.8) are as follows:

1. **Vestibule:** It is lined by the skin containing a large number of sebaceous glands and interlacing coarse hair—the **vibrissae**. As the air passes through the nostrils the large particles of dust in the air are trapped by the vibrissae.

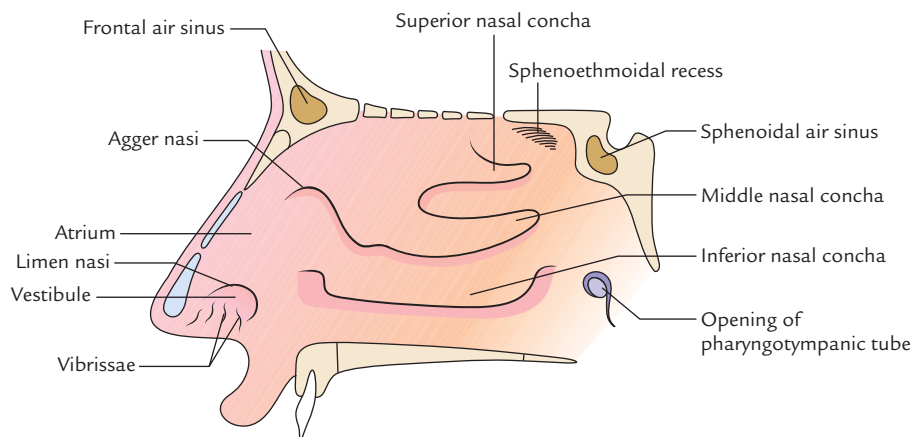


Fig. 17.6 Features of the lateral wall of the nasal cavity.

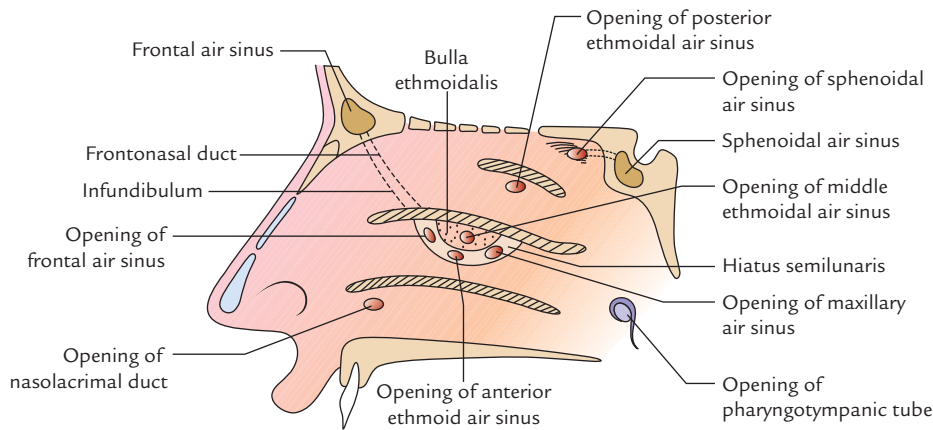


Fig. 17.7 Lateral wall of the nose with conchae removed showing openings of various sinuses and nasolacrimal duct.

Table 17.1 The openings in the lateral wall of the nose

Sites	Openings
Sphenoethmoidal recess	Opening of the sphenoidal air sinus
Superior meatus	Opening of the posterior ethmoidal air sinuses
Middle meatus	Opening of the middle ethmoidal air sinuses
• On bulla	
• In hiatus semilunaris	
– Anterior part	
– Middle part	Opening of the frontal air sinus
– Posterior part	Opening of the anterior ethmoidal air sinuses
	Opening of the maxillary air sinus
Inferior meatus	Opening of the nasolacrimal duct (in the anterior part of meatus)

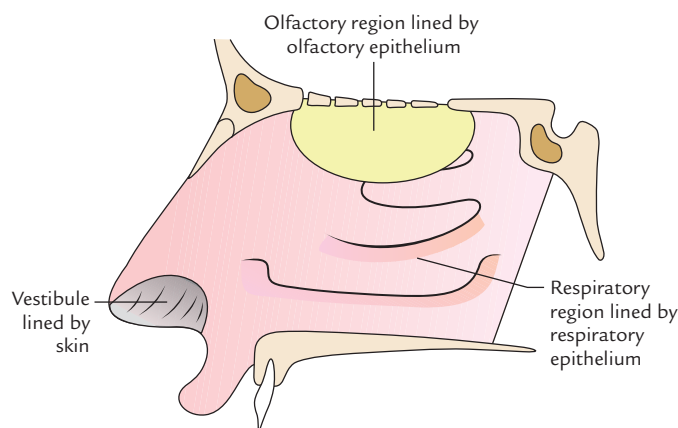


Fig. 17.8 Lining of the nasal cavity.

2. **Olfactory region:** The upper third of the nasal cavity bounded above by cribriform plate of ethmoid, laterally by superior nasal concha and medially by upper one-third of the nasal septum forms the olfactory region. It is lined by the olfactory epithelium, which contains receptor cells for smell. Here mucous membrane is paler in color.

3. **Respiratory region:** The rest of the nasal cavity (lower two-third) is lined by the respiratory epithelium, i.e., pseudostratified ciliated columnar epithelium with goblet cells. The respiratory mucosa is highly vascular and contains a large number of cavernous spaces and sinusoids to warm the air. In addition, it contains a large number of serous and mucous glands. The secretion of the serous glands makes the air moist while the secretion of the mucous glands traps the dust and other particles. Further, the cilia on the surface of the mucous membrane sweep the mucous posteriorly into the pharynx where it is swallowed and eliminated by the GIT.

N.B. Due to the presence of cilia in the epithelial lining and secretions of the serous and mucous glands in the nasal cavity, the air while passing through the nasal cavity is not only filtered but also moistened and humidified, a mechanism that protects the lower respiratory tract.

Arterial Supply of Nasal Cavity

The nasal cavity has rich arterial supply.

Arterial Supply of Nasal Septum

The nasal septum is supplied by the following arteries (Fig. 17.9):

1. Septal branch of the anterior ethmoidal artery (a branch of ophthalmic artery).
2. Septal branch of the posterior ethmoidal artery (a branch of ophthalmic artery).
3. Septal branch of the sphenopalatine artery (a branch of maxillary artery).
4. Septal branch of the greater palatine artery (a branch of maxillary artery).
5. Septal branch of the superior labial artery (a branch of facial artery).

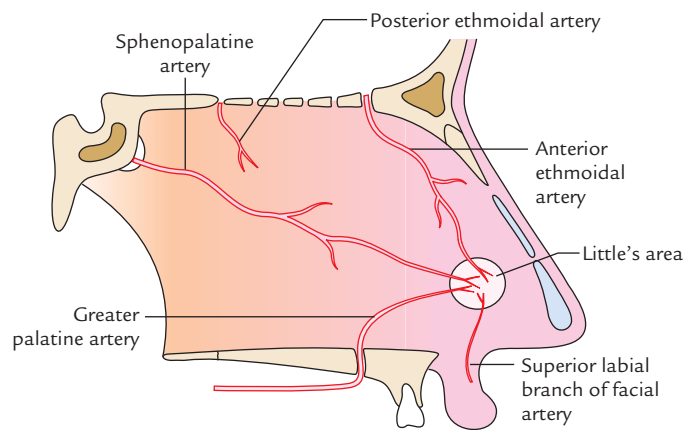


Fig. 17.9 Arterial supply of the nasal septum.

Clinical correlation

Little's area: It is an area in the anteroinferior part of the nasal septum just above the vestibule. It is highly vascular. Here the septal branches of the anterior ethmoidal, sphenopalatine, greater palatine, and superior labial arteries anastomose to form a vascular plexus called *Kiesselbach's plexus*. This area of nasal septum is the commonest site of **epistaxis (nose bleeding)** in children and young adults usually due to finger nail trauma following picking of the nose.

Arterial Supply of Lateral Wall

The arterial supply (Fig. 17.10) of the various parts of the lateral wall is as follows:

1. **Anterosuperior quadrant**, by the anterior ethmoidal artery, a branch of ophthalmic artery.
2. **Anteroinferior quadrant**, by branches of facial and greater palatine arteries.

3. **Posterosuperior quadrant**, by sphenopalatine artery, a branch of maxillary artery.
4. **Posteroinferior quadrant**, by branches of greater palatine artery, which pierces the perpendicular plate of palatine.

Venous Drainage of Nasal Cavity

The veins draining the nasal cavity form plexus beneath the mucosa and in general accompany the arteries. The veins of nasal cavity drain into facial vein, pterygoid venous plexus, and pharyngeal venous plexus.

N.B.

- The submucous venous plexus is more marked in the region of little's area.
- The *retrocolumellar* vein runs vertically downwards, crosses the floor of nasal cavity to join the venous plexus on the lateral wall. This is the common site of venous bleeding in young individuals.

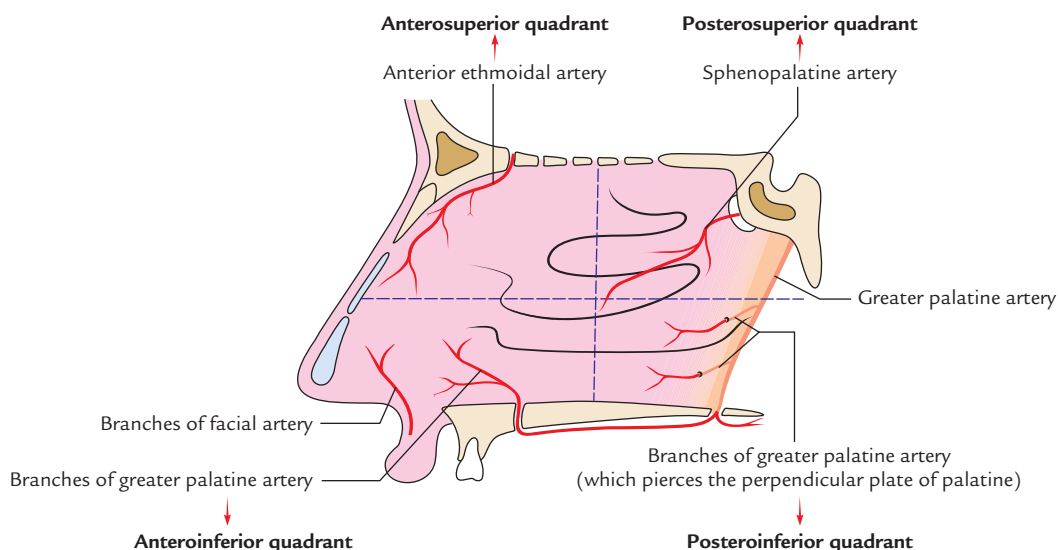


Fig. 17.10 Arterial supply of the lateral wall.

Lymphatic Drainage of Nasal Cavity

Lymph from anterior half of nasal cavity (both medial and lateral walls) is drained into *submandibular lymph nodes* and from posterior half into *retropharyngeal lymph nodes*.

Nerve Supply of Nasal Cavity

The nasal cavity is supplied by the following nerves:

1. **Olfactory nerves:** They carry sense of smell from olfactory region of nasal cavity (for details see Chapter 22).
2. **Nerves of general sensation:** These are:
 - (a) anterior ethmoidal nerve,
 - (b) branches of sphenopalatine ganglion, and
 - (c) branches of infraorbital nerve.

They carry sensations of pain, touch, and temperature from respiratory region and vestibule of nasal cavity.

3. **Autonomic nerves:** Both parasympathetic and sympathetic fibres supplying nasal cavity are derived from Vidian's nerve (nerve of pterygoid canal) through pterygopalatine ganglion.

The parasympathetic fibres supply nasal glands and control nasal secretion.

The sympathetic fibres, on stimulation, cause vasoconstriction.

Clinical correlation

Rhinitis: It is the inflammation of mucus membrane lining the nasal cavity. The hypertrophy of mucosa over inferior concha is a common feature of *allergic rhinitis*. Clinically it presents as: nasal blockage, sneezing, and water discharge from nose (*rhinorrhea*).

The *excessive rhinorrhea* due to *vasomotor and allergic rhinitis* can be controlled by sectioning the Vidian nerve.

Nerve Supply of Nasal Septum (Fig. 17.11)

The nasal septum receives supply from the following nerves:

1. **Olfactory nerves**—supply the upper part (one-third) just below the cribriform plate.
2. **Internal nasal branch** of the anterior ethmoidal nerve, a branch from nasociliary—supplies the anterosuperior part.
3. **Nasopalatine nerve**, a branch of pterygopalatine ganglion—supplies the posteroinferior part.
4. **Medial posterior superior nasal branches of pterygopalatine ganglion**—supply the posterosuperior part.
5. **Nasal branch of greater palatine nerve**—supplies the posterior part.
6. **Anterior superior alveolar nerve**, a branch of maxillary nerve—supplies the anteroinferior part.

Nerve Supply of Lateral Wall

The following nerves supply (Fig. 17.12) the different parts of the lateral wall:

1. **Olfactory nerves**—supply the upper part (one-third) just below the cribriform plate of ethmoid up to the superior concha.
2. **Anterior ethmoidal nerve** (from ophthalmic)—supplies the anterosuperior quadrant.
3. **Anterior superior alveolar nerve**, a branch of infraorbital nerve (from maxillary)—supplies the anteroinferior quadrant.
4. **Posterior superior lateral branches**, of pterygopalatine ganglion—supply posterosuperior quadrant.
5. **Nasal branches of greater palatine nerve**, (from pterygopalatine ganglion)—supply posteroinferior quadrant.

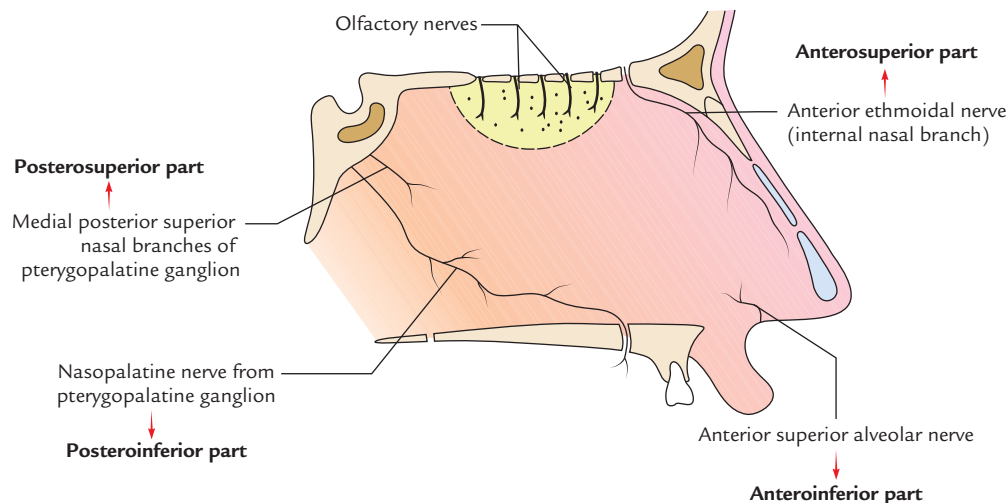


Fig. 17.11 Nerve supply of the nasal septum.

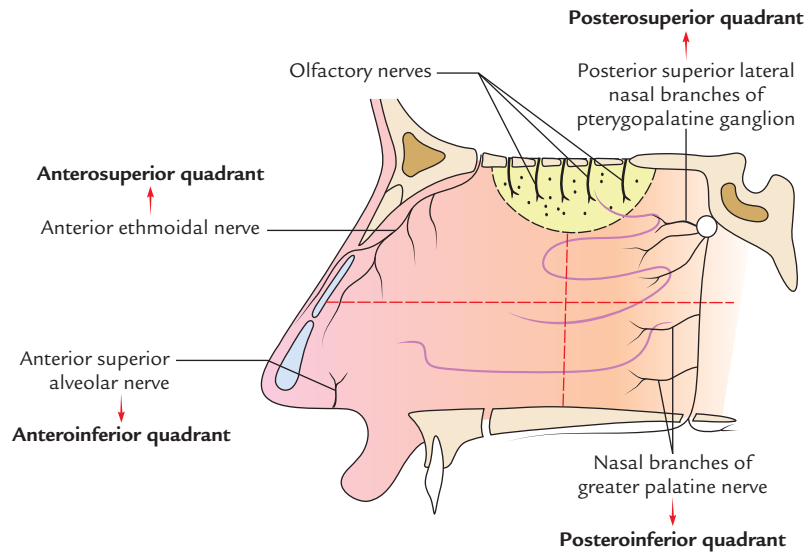


Fig. 17.12 Nerve supply of the lateral wall of the nose.

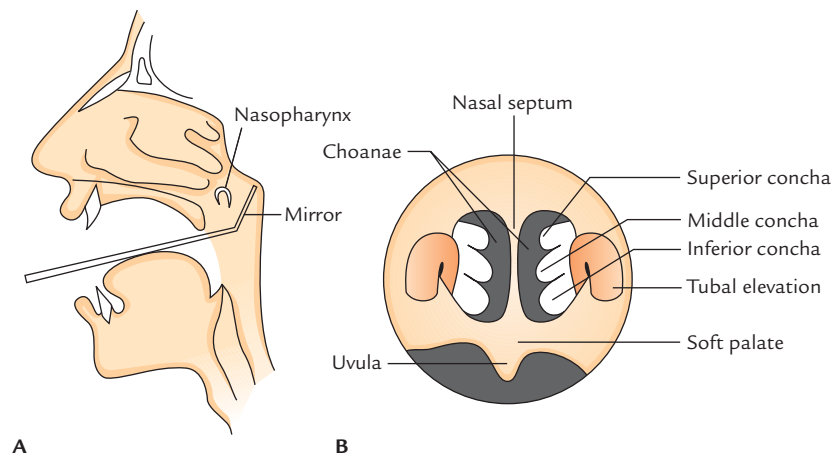


Fig. 17.13 Posterior rhinoscopy: A, showing placement of mirror in the nasopharynx; B, structures seen in the mirror.

Clinical correlation

Examination of the nasal cavity (Rhinoscopy): The nasal cavity can be examined in the living individual either through the nostril (**anterior rhinoscopy**) or through the pharynx (**posterior rhinoscopy**).

- Anterior rhinoscopy:** It is carried out by inserting a nasal speculum through a nostril. The following features are visualized by this method:
 - Middle and inferior conchae.
 - Superior middle and inferior meatuses.
 - Nasal septum.
 - Floor of the nasal cavity.
- Posterior rhinoscopy:** It is carried out by inserting a mirror into the pharynx (Fig. 17.13A). The following features can be visualized by this method (Fig. 17.13B):

- Choanae.
- Conchae.
- Posterior border of the nasal septum.

PARANASAL AIR SINUSES

The paranasal air sinuses are air-containing cavities in the bones around the nasal cavity. The paranasal air sinuses develop as mucosal diverticula of the main nasal cavity invading the adjacent bones. They are lined by a **pseudostratified ciliated columnar epithelium** as in the nasal cavity (Fig. 17.14).

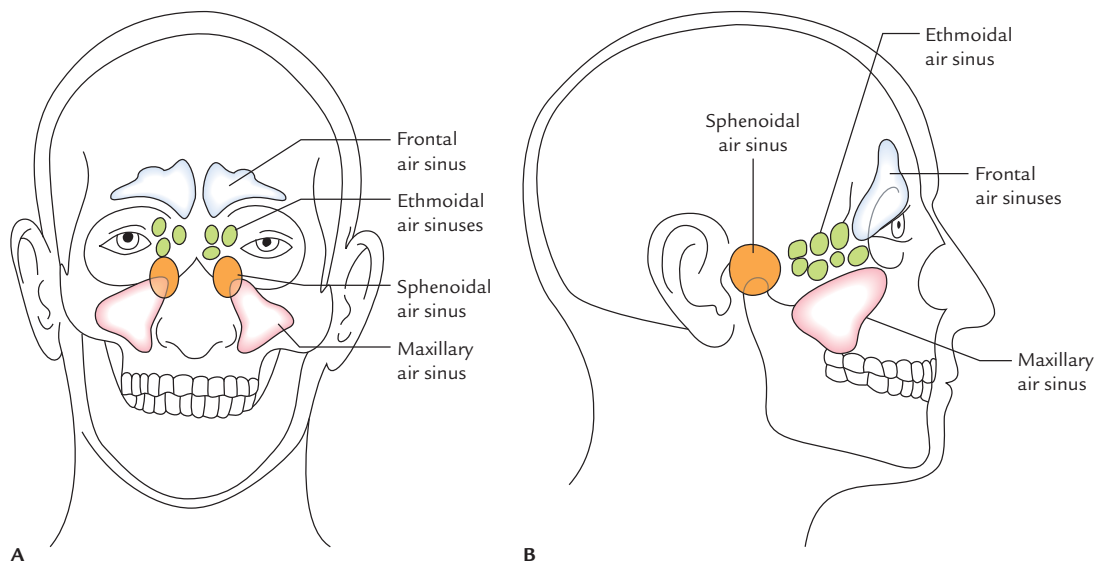


Fig. 17.14 Positions of paranasal air sinuses on the surface: A, front view; B, side view.

There are four paranasal air sinuses on each side and are named after the bones containing them, *viz.*

1. **Frontal air sinuses** present in the frontal bone.
2. **Ethmoidal air sinuses** present in the ethmoid bone.
3. **Maxillary air sinuses** present in the maxilla.
4. **Sphenoidal air sinuses** present in the sphenoid bone.

The paranasal air sinuses are arranged in pairs *except* the ethmoidal air sinuses, which are arranged in three groups, *viz.* anterior, middle, and posterior on each side.

The orbit of eye serves as a landmark to appreciate the location of various paranasal air sinuses.

The relationship of the paranasal sinuses to the orbit (Fig. 17.15) is as follows:

- the frontal air sinus *above*,
- the maxillary air sinus *below*,
- the ethmoidal air sinus *medial* to, and

- the sphenoidal air sinus *behind the orbit*.

The sinuses exhibit two spurts of growth, *viz.*

1. First around 7–8 years (during the eruption of the teeth).
2. Second at puberty.

N.B. All the paranasal air sinuses are present in rudimentary form at birth *except* the frontal air sinuses, which start developing 2 or 3 years after birth.

FUNCTIONS

Paranasal air sinuses perform the following functions:

1. Make the skull lighter.
2. Add resonance to the voice.
3. Act as air conditioning chambers by adding humidity and temperature to the inspired air.
4. Aid in the growth of facial skeleton after birth.

Clinical correlation

Sinusitis: The infection of a paranasal air sinus is called sinusitis. Clinically it presents as: headache and persistent thick purulent discharge from the nose.

In standard radiological images, the normal paranasal air sinuses are radiolucent, whereas diseased paranasal sinuses show varying degree of opacity. The newer imaging techniques, *viz.* CT scan provide very clear images of the sinuses, which significantly aid in diagnosis (Fig. 17.16).

CLASSIFICATION

Clinically the sinuses are divided into the following two main groups:

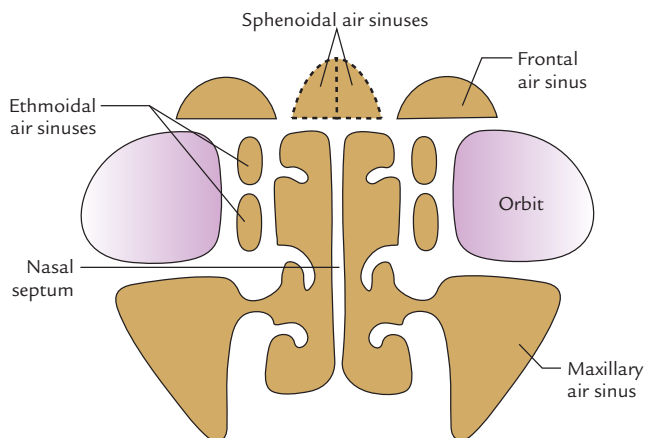


Fig. 17.15 Schematic diagram to show the location of various paranasal sinuses in relation to the orbit.

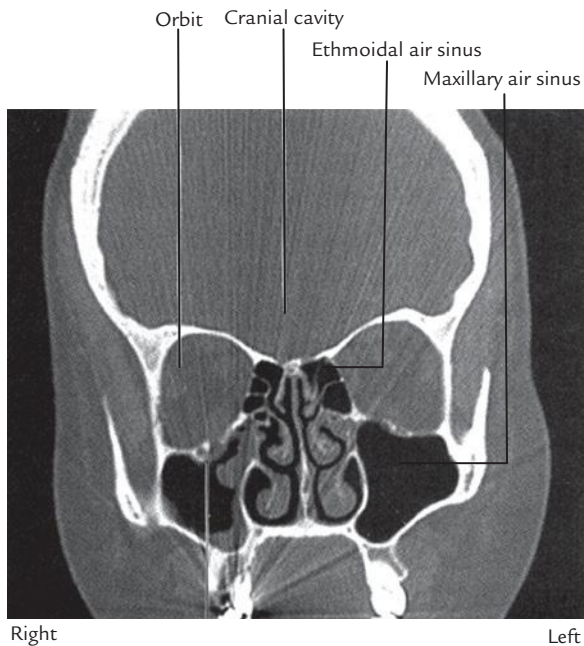


Fig. 17.16 Coronal CT scan showing ethmoidal and maxillary air sinuses. (Source: Fig. 8.281, Page 1029, *Gray's Anatomy for Students*, Richard L Drake, Wayne Vogl, Adam WM Mitchell. Copyright Elsevier Inc. 2005, All rights reserved.)

1. **Anterior group:** It includes those sinuses, which drain into the middle meatus, *viz.* frontal, anterior and middle ethmoidal, and maxillary sinuses.
2. **Posterior group:** It includes those sinuses, which do not drain into the middle meatus, *viz.* posterior ethmoidal and sphenoidal air sinuses.

FRONTAL AIR SINUSES

The frontal air sinus (two in number) lies between the inner and outer tables of the frontal bone deep to medial part of the superciliary arch. They are triangular in shape. The right and left sinuses are usually unequal in size and rarely symmetrical. The right is frequently larger than the left and separated from it by a septum.

Each sinus drains into the anterior part of the hiatus semilunaris of the middle meatus through frontonasal duct.

Measurements

Vertical: 3 cm.

Transverse: 2.5 mm.

Anteroposterior: 1.8 cm.

Relations

Anterior wall is related to: superciliary arch of forehead.

Posterior wall is related to: meninges and frontal lobe of the brain.

Inferior wall is related to: roof of nose, roof of orbit (medial part), and ethmoidal air cells.

Nerve Supply

It is by supraorbital nerve.

Clinical correlation

Frontal sinusitis: Infection of frontal air sinus may spread posteriorly into the anterior cranial fossa causing *frontal lobe abscess* or downwards into the orbit leading to *orbital cellulitis*.

The pain of frontal sinusitis is usually severe and localized over the affected sinus (*frontal headache*). It shows characteristic periodicity, *i.e.*, it starts on waking, gradually increases and reaches its peak by about midday and then starts subsiding. It is also referred to as '*office headache*' because of its presence during office hours.

MAXILLARY SINUS (ANTRUM OF HIGHMORE)

It is the largest of paranasal air sinuses and is present in the body of maxilla.

It drains into the hiatus semilunaris (posterior part) of the middle meatus.

Development

The maxillary sinus is first to develop. It appears about the 4th month of intrauterine life as an out-pouching from the mucous membrane lining the lateral wall of the nasal cavity. It is rudimentary at birth, enlarges rapidly during 6–7 years and becomes fully developed at puberty after the eruption of permanent teeth.

Measurements

Vertical: 3.5 cm.

Transverse: 2.5 cm.

Anteroposterior: 3.25 cm.

Shape

It is pyramidal in shape with the base directed medially towards the lateral wall of the nose and its apex laterally towards the zygomatic bone.

Relations (Fig. 17.17)

Roof is formed by the floor of the orbit. The infraorbital nerve and artery traverse the roof in a bony canal.

Floor (very small) is formed by the alveolar process of maxilla and lies about 1.25 cm below the floor of the nasal cavity. The level of the floor corresponds to the level of the ala of nose. Normally the roots of the first and second molar

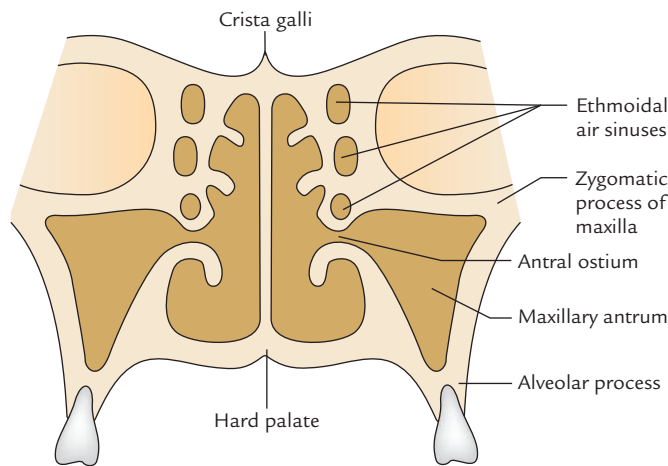


Fig. 17.17 Relations of maxillary sinus.

teeth project into the floor producing elevations but sometimes roots of the first and second premolars, third molar, and rarely even that of canine may project into the floor. Sometimes roots of teeth are separated from the sinus only by a thin layer of mucous lining.

Base is formed by the lateral wall of the nose. It possesses the *opening or ostium of the sinus* in its upper part, i.e., close to the roof, a disadvantageous position for natural drainage.

In the disarticulated skull, the base of maxillary sinus (medial surface of the body of maxilla) presents a large opening—the maxillary hiatus, which is reduced in size by the following bones (Fig. 17.5):

1. Uncinate process of ethmoid, from above.
2. Descending process of lacrimal, from in front.
3. Ethmoidal process of inferior nasal concha, from below.
4. Perpendicular plate of palatine from behind.

N.B. The *nasolacrimal duct* lies in the osseous canal formed by the maxilla, the lacrimal bone and inferior nasal concha. It opens into the inferior meatus beneath the inferior nasal concha.

Apex extends into the zygomatic process of maxilla.

Anterior wall is formed by the anterior surface of the body of maxilla and is related to infraorbital plexus of nerves. Within this wall runs the *anterior superior alveolar nerve* in a curved bony canal called **canalis sinuosus**.

Posterior wall is formed by the infratemporal surface of the maxilla, separating the sinus from the infratemporal and pterygopalatine fossae. It is pierced by the *posterior superior alveolar nerves and vessels*.

Opening

Maxillary sinuses open in the hiatus semilunaris of middle meatus near the roof of the sinus.

Arterial Supply

It is by the anterior, middle, and posterior superior alveolar arteries from maxillary and infraorbital arteries.

Lymphatic Drainage

The sinus drains into submandibular lymph nodes.

Nerve Supply

Maxillary sinuses are supplied by the anterior, middle, and posterior superior alveolar nerves from the maxillary and infraorbital nerves.

Clinical correlation

- **Maxillary sinusitis:** Maxillary sinus is most commonly infected of all the sinuses due to following reasons:
 - Infection can reach into this sinus from infected nose (viral rhinitis), carious upper premolar and molar teeth, especially molars, and infected frontal and anterior ethmoidal sinuses.
 - Being most dependent part, it acts as a **secondary reservoir** for pus from frontal air sinus through frontonasal duct and hiatus semilunaris.
 - Pain of maxillary sinusitis is referred to the upper teeth and infraorbital skin due to common innervation by the maxillary nerve.
- **Drainage of maxillary sinus:** The opening of this sinus is unfortunately located in the upper part of the lateral wall of nose, which is a disadvantageous site for adequate natural drainage. Surgically, maxillary sinus is drained in the following two ways:
 - **Antral puncture (antrostomy)** by using trocar and cannula, which are passed below the inferior nasal concha in an outward and backward direction (Fig. 17.18).
 - **Fenestrating the antrum through canine fossa in the gingivolabial sulcus (Caldwell–Luc operation).**
- **Carcinoma of maxillary sinus:** It arises from the mucous lining of the sinus. The signs and symptoms produced by the invasion of the carcinoma can be easily remembered anatomically:
 - The *upward invasion* into the orbit displaces the eyeball causing **proptosis** (protrusion of eyeball) and **diplopia** (double vision).
Involvement of infraorbital nerve produces pain and anesthesia in the skin over the face below the orbit.
 - The *downward invasion* into the floor produces *visible bulge* or even ulceration of palatal roof of the oral cavity.
 - The *medial invasion* encroaches the nasal cavity causing obstruction and **epistaxis**. The obstruction of nasolacrimal duct in this wall produces epiphora (overflow of tears).
 - The *lateral invasion* produces swelling on the face and palpable mass in the gingivolabial fold (groove).
 - *Backward (posterior) invasion* may involve the palatine nerves leading to severe referred pain to the upper teeth.

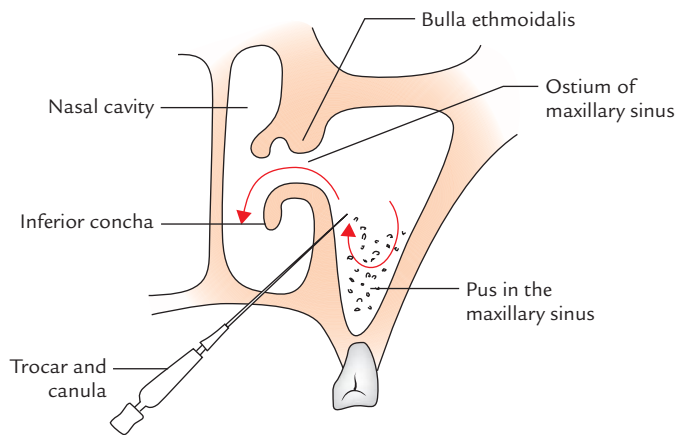


Fig. 17.18 Antral puncture (antrostomy).

ETHMOIDAL SINUSES

The ethmoidal air sinuses are made up of a number of air cells present within the labyrinth of ethmoidal bone, thus they are located between the upper part of the lateral nasal wall and the orbit.

They are divided into the following three groups:

1. **Anterior**, consisting of up to 11 cells.
2. **Middle**, consisting of 1–3, usually three cells.
3. **Posterior**, consisting of 1–7 cells.

The first two groups—*anterior and middle*—drain into the middle meatus (anterior opens in the hiatus semilunaris and middle on the surface of bull ethmoidalis) and the *posterior* into posterior part of superior meatus.

Clinical correlation

Ethmoidal sinusitis: It is often associated with infection of other sinuses. The pain is localized over the bridge of nose medial to the eye.

The ethmoidal sinuses are separated from the medial wall of the orbit only by a very thin plate of bone called *lamina papyracea*, therefore the infection from these sinuses can easily spread into the orbit producing *orbital cellulitis*.

SPHENOIDAL SINUSES

The right and left sphenoidal sinuses lie within the body of the sphenoid bone above and behind the nasal cavity. They are separated from each other by a bony septum. The two sinuses are usually asymmetrical. Each sinus drains into the sphenothmoidal recess of the nasal cavity.

Measurements

Vertical: 2 cm.

Transverse: 1.5 cm.

Anteroposterior: 2 cm.

Relations

Above: Pituitary gland and optic chiasma.

Below: Roof of the nasopharynx.

Lateral: Cavernous sinus and internal carotid artery (on each side).

Behind: Pons and medulla oblongata.

In front: Sphenothmoidal recess.

Clinical correlation

Sphenoidal sinusitis: Isolated *sphenoidal sinusitis* is rare. It is usually a part of pansinusitis or is associated with the infection of posterior ethmoidal sinuses.

The infection of sphenoidal air sinuses spreading upwards may affect the pituitary gland and optic chiasma.

Golden Facts to Remember

- ▶ Whole nasal cavity is respiratory in function except Upper one-fourth, which is olfactory in function
- ▶ All the conchae are parts of ethmoid bone except Inferior nasal concha, which is an independent bone
- ▶ Commonest site of nose bleeding Little's area
- ▶ Artery of nose bleeding Septal branch of the sphenopalatine artery
- ▶ Rhinologist's artery Septal branch of the sphenopalatine artery
- ▶ Woodruff's area Vascular area under the posterior end of inferior concha. It is the site of posterior epistaxis

- ▶ Largest paranasal air sinus Maxillary air sinus
- ▶ First sinus that can be visualized radiologically after birth Maxillary air sinus (4–5 months after birth)
- ▶ Most commonly infected paranasal air sinus Maxillary sinus
- ▶ All the paranasal air sinuses are present at birth except Frontal air sinuses, which start developing at the age of 2 years
- ▶ Most easily naturally drained paranasal air sinus Frontal air sinus
- ▶ Most deeply located paranasal air sinuses Sphenoidal air sinuses
- ▶ Only bone in the body, made up solely of spongy bone Inferior nasal concha

Clinical Case Study



A 12-year-old boy while playing in the school ground during the lunch break suddenly started bleeding from nose. His mates took him to the Principal's office where teachers tried to stop the bleeding by pinching the nose and pouring cold water on the nose. When bleeding did not stop, the student was taken to the nearby dispensary. The doctor packed his nose to stop bleeding and sent back the boy to the school.

Questions

1. What is the commonest cause of nose bleeding in children?
2. What is Little's area and which arteries anastomose in this area?
3. Which artery is called the artery of nose bleeding?

Answers

1. In vast majority of children, nose bleeding occurs because of digital trauma to the anastomosis of arterioles and veins (Kiesselbach's plexus) in Little's area.
2. Area on nasal septum just above the nasal vestibule. The arteries anastomosing in this area are septal branches of the sphenopalatine, greater palatine, anterior ethmoidal, and superior labial arteries.
3. Septal branch of the sphenopalatine artery.

The ear is the organ of hearing and plays an important role in maintaining the balance (equilibrium) of the body. The ear is divided into three parts (Fig. 18.1), *viz.*

1. External ear.
2. Middle ear.
3. Internal ear.

The external ear consists of the auricle or pinna and external auditory meatus at the medial end of which lies the tympanic membrane or ear drum, separating the external ear from the middle ear. The middle ear or tympanic cavity is a small

air-filled space within the petrous part of the temporal bone containing the auditory ossicles. It communicates with the nasopharynx through auditory tube. By its medial wall, the middle ear adjoins the internal ear. The internal ear consists of a bony labyrinth, a complicated space, also in the petrous part of the temporal bone containing fluid-filled membranous labyrinth. The membranous labyrinth contains sensory receptors for hearing and balancing.

The sensations of hearing and balancing from these receptors are carried by vestibulocochlear nerve to the cerebral cortex for interpretation.

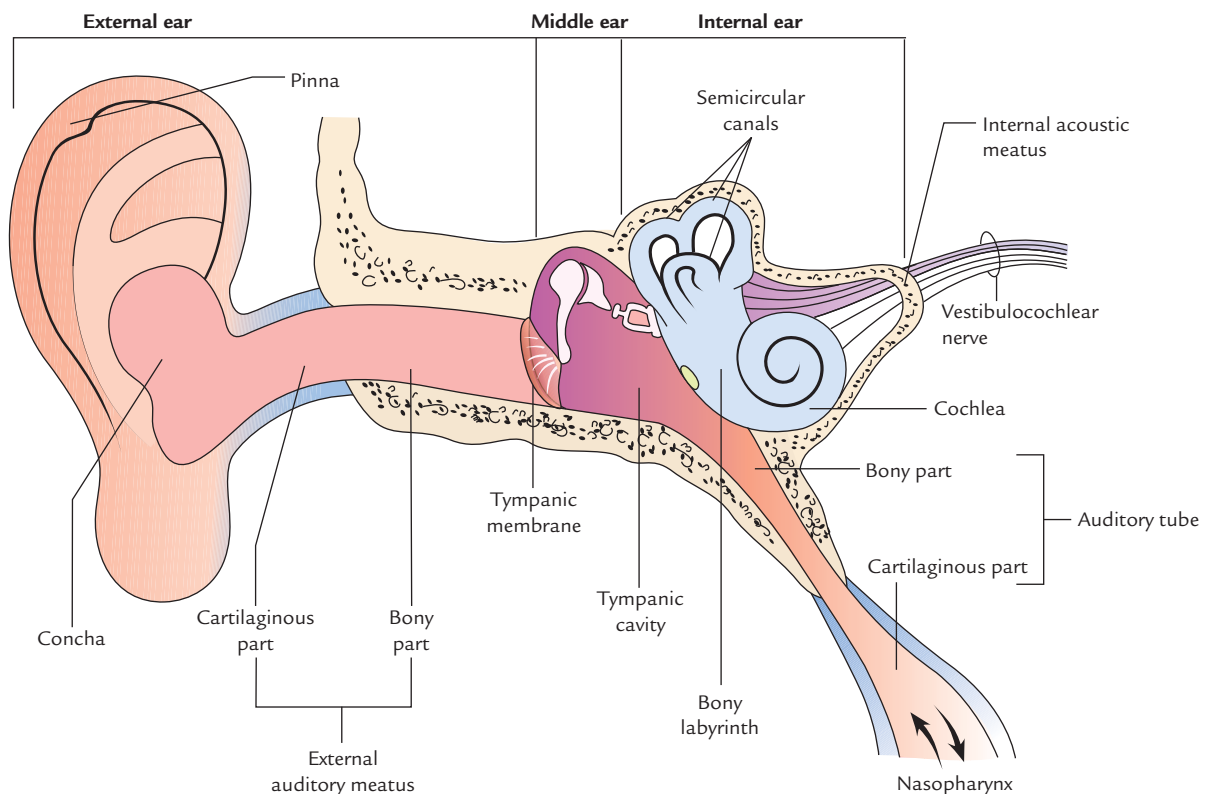


Fig. 18.1 The ear and its subdivisions (external, middle, and internal ear).

EXTERNAL EAR

The external ear consists of (a) pinna or auricle and (b) external auditory meatus, which are concerned with collection and transmission of sound waves to the tympanic membrane, respectively.

AURICLE/PINNA

The auricle is trumpet-like undulating projection on the side of the head (Fig. 18.2). The entire pinna except its lobule is made up of a single piece of crumpled yellow elastic cartilage covered with skin (Fig. 18.2B). The lobule of pinna is made of fibrofatty tissue covered with skin. The auricular cartilage is continuous with the cartilage of the external auditory meatus.

Features

The auricle presents two surfaces: lateral and medial.

The **lateral surface** of auricle (Fig. 18.2A) displays following elevations and depressions:

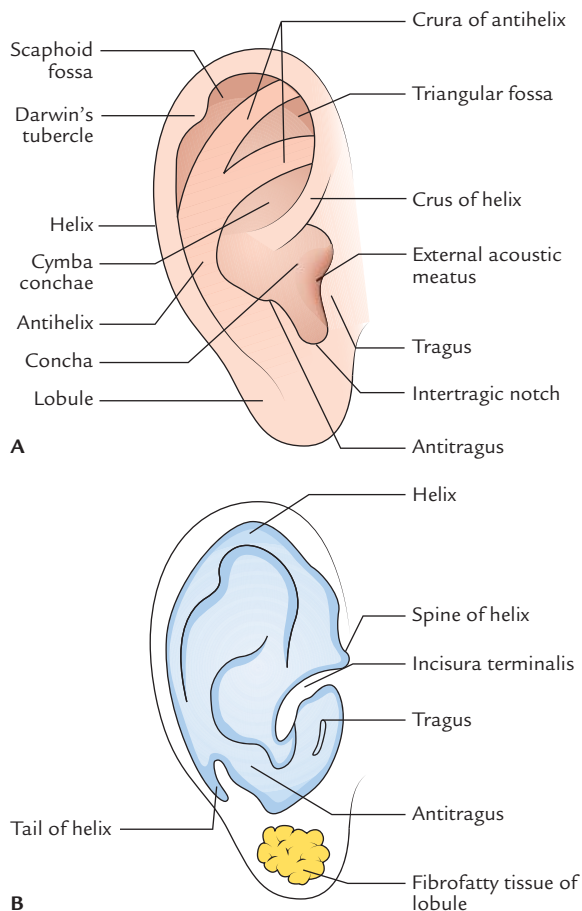


Fig. 18.2 Auricle: A, features on the lateral surface of the auricle; B, cartilage of the auricle.

1. **Concha**, a large depression that leads into the external auditory meatus. It is guarded in front by a triangular flap of cartilage, the **tragus**.
2. **Helix** forms a prominent peripheral rim of the pinna. It consists of two limbs—anterior and posterior. An anterior limb ends as **crus of helix**, which divides the concha into smaller upper and larger lower parts. The posterior limb ends below as flabby ear lobe and its upper end sometimes presents a small elevation called **Darwin's tubercle**. It is probably erroneously thought to represent the vestige of the pointed part of the quadruped ear.
3. **Antihelix** is another prominent ridge present in front and parallel to the posterior part of helix, partly encircling the concha. Its upper end divides into two crura enclosing a triangular depression called **triangular fossa**. The narrow gutter between the helix and antihelix is called **scaphoid fossa**.
4. **Tragus** is a small triangular flap in front of concha.
5. **Antitragus** is a small elevation opposite to tragus from which it is separated by an **intertragic notch**.
6. **Cymba conchae** is a small area of concha above the crus of helix. Clinically it is important as it corresponds to the suprameatal triangle (McEwen's triangle).
7. **Lobule** of the ear hangs below the antitragus as a large skin covered flap of fibrofatty tissue.

N.B.

- There is no cartilage between tragus and crus and the gap between the two is called **incisura terminalis**.
- The thick hair on pinna particularly on tragus in male represents Y-linked inheritance.
- The pinna collects and directs the sound waves to the external auditory meatus.

The **medial/cranial surface** of (pinna) presents the following features:

1. **Eminentia concha**, which corresponds to the depression of the concha.
2. **Eminentia triangularis**, which corresponds to the triangular fossa between the crura of the antihelix.

Clinical correlation

- Pinna is a source of several graft materials for the surgeons.
- The lobule of ear is commonly pierced for wearing earrings.
- For surgery of external auditory meatus, the incision is made in the region of incisura terminalis as it will not cut through the cartilage.

Muscles

The muscles of the auricle are divided into two groups: extrinsic and intrinsic. They are rudimentary in humans.

The **extrinsic muscles** pass from scalp or skull to the auricle. They are as follows:

1. Auricularis anterior.
2. Auricularis superior.
3. Auricularis posterior.

The anterior and superior muscles arise from epicranial aponeurosis and are inserted into the upper part of the helix and upper part of the cranial surface of the auricle, respectively. The auricularis posterior arises from the mastoid process and gets inserted into eminentia concha.

The **intrinsic muscles** are small muscular slips, which pass between the cartilaginous parts of the auricle.

Actions

The extrinsic muscles may play a role in positioning of the auricle to catch the sound, while intrinsic muscles may change the shape of the auricle. Such movements are rarely seen in human beings. However in animals they modify the shape of the pinna.

Skin

The skin covering the auricle is closely adherent to the underlying cartilage and fibrofatty tissue. Sometimes coarse hair projects out of the tragus, antitragus, intertragic notch, and helix in elderly males. The hairy pinna is an expression of Y-linked genes.

Arterial Supply

1. The cranial surface and posterior part of the lateral surface is supplied by the posterior auricular branch of the external carotid artery.
2. The anterior part of the lateral surface is supplied by the superficial temporal artery.

N.B. Few branches of occipital artery supply the upper part of the cranial surface.

Venous Drainage

The veins accompany the arteries and drain into superficial temporal and external jugular veins.

Lymphatic Drainage

The lymph from auricle drains into:

1. Preauricular (parotid) lymph nodes.
2. Mastoid lymph nodes.
3. Upper group of deep cervical lymph nodes.

Nerve Supply

Motor supply: All the extrinsic and intrinsic muscles of the auricle are supplied by the facial nerve. The auricularis anterior and auricularis superior are supplied by the temporal branch of the facial nerve, while auricularis

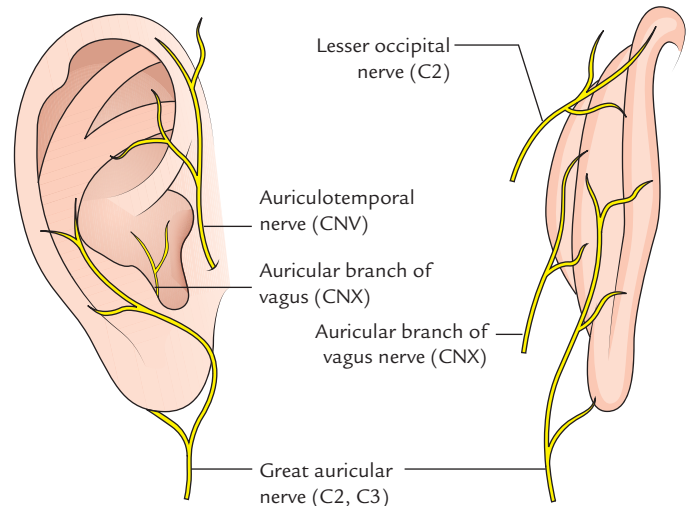


Fig. 18.3 Sensory supply of the auricle: A, lateral surface; B, medial surface.

posterior is supplied by the posterior auricular branch of the facial nerve.

Sensory supply (Fig. 18.3)

1. Lateral (facial) surface (Fig. 18.3A)
 - (a) Lower one-third, by great auricular nerve (C2, C3).
 - (b) Upper two-third, by auriculotemporal nerve [(a branch of mandibular division of the trigeminal nerve (CNV))].
 - (c) Concha, by auricular branch of the vagus (Alderman's nerve) nerve (CNX).
2. Medial (cranial) surface (Fig. 18.3B)
 - (a) Lower one-third, by great auricular nerve (C2, C3).
 - (b) Upper two-third, by lesser occipital nerve (C2).
 - (c) Eminentia conchae, by auricular branch of the vagus.

Clinical correlation

Involvement of pinna in herpes zoster of geniculate ganglion (Ramsay Hunt syndrome): Clinically, it is acknowledged that a few fibres of the facial nerve accompany the auricular branch of vagus and supply the skin in the region of concha and eminentia conchae, as vesicles are seen in these regions during involvement of the geniculate ganglion of the facial nerve by herpes zoster virus. The communication between the auricular branch of vagus and facial nerves takes place within the petrous temporal bone.

EXTERNAL AUDITORY MEATUS

The external auditory meatus (syn. external acoustic meatus) extends from the bottom of the concha to the tympanic membrane and measures about 24 mm along its posterior

wall. Note that it is not a straight tube but it has a typical S-shaped course. Its outer part is directed upwards, backwards, and medially (UBM), whereas its inner part is directed downwards, forwards, and medially (DFM). *Therefore, to examine the tympanic membrane the pinna has to be pulled upwards, backwards, and laterally, to bring the two parts in alignment.*

Parts

The external auditory meatus is divided into two parts: cartilaginous and bony.

The **cartilaginous part** forms the outer one-third (8 mm) of the meatus. The cartilage is the continuation of the cartilage of the auricle. The skin covering the cartilaginous part is thick, and contains hair and ceruminous (pilosebaceous) glands, which secrete ear wax.

Clinical correlation

- Since the hairs are confined to the outer part of the meatus, the *furuncles* (infection of hair follicles) develop only in this part.
- To examine external auditory meatus and tympanic membrane, the pinna is pulled upwards, backwards, and laterally (vide supra) in adults, while in infants it is pulled downwards and backwards. This is because in infants the bony part of external auditory meatus is not developed and tympanic membrane is directed mainly downwards.

The **bony part** forms the inner two-third (16 mm) of the external auditory meatus. The skin lining the bony part of meatus is thin and continuous with the cuticular layer of the tympanic membrane. It is devoid of hair and ceruminous glands. About 4 mm lateral to the tympanic membrane (about 20 mm deep to concha), the bony meatus presents a narrowing called **isthmus**. The foreign body lodged medial to isthmus gets impacted and are difficult to remove.

Sometimes the anterior wall of bony part presents a foramen (**foramen of Huschke**), permitting infection back and forth from parotid gland. This foramen is normally present in children up to the age of 4 years.

In the newborn, the bony canal is not developed and is represented by a tympanic ring of bone. Consequently the external auditory meatus is shorter in children, and therefore, deep insertion of ear speculum may damage the tympanic membrane.

Arterial Supply

The external auditory meatus is supplied by the following arteries:

1. Posterior auricular artery, a branch of the external carotid artery.

2. Deep auricular artery, a branch of first part of the maxillary artery.
3. Anterior tympanic artery, a branch of first part of the maxillary artery.

Nerve Supply

1. Roof and anterior wall are supplied by the auriculo-temporal nerve.
2. Floor and posterior wall are supplied by the auricular branch of vagus (note that it is the only cutaneous branch of the vagus nerve).

Clinical correlation

- The **infection and boils of the external auditory meatus** cause very little swelling but are very painful because the skin lining is firmly adhered to the underlying cartilage and bone.
- **Ear wax:** It prevents the injury of the lining epithelium of the external auditory meatus from water and the damage of tympanic membrane by trapping the insects. The excess of ear wax interfering with hearing is removed by syringing. The irritation of auricular branch of vagus during syringing may reflexly produce persistent cough called **ear cough**, vomiting, and even death due to sudden cardiac inhibition.
- The Aldermen were the individuals in ancient Rome, who were very fond of excessive eating and used to stimulate their jaded appetite by dropping cold water or spirit behind the ear as this could reflexly stimulate gastric peristalsis due to supply of this area by the vagus nerve which also supplies motor innervation to the GIT.

Development

The external auditory meatus develops as an ectodermal invagination of first pharyngeal cleft. It becomes filled with ectodermal cells forming a solid mass called *meatal plug*, which is canalized before birth. The auricle develops from six mesodermal tubercles around the external opening of the first pharyngeal cleft. The failure of canalization of meatal plug results in **atresia of the external auditory meatus**, while failure of fusion of tubercles will give rise to **accessory auricles**.

TYMPANIC MEMBRANE

The tympanic membrane (or ear drum) is a thin (0.1 mm thick) semitransparent membrane, which forms the partition between external acoustic meatus and middle ear. It is oval, measuring 9–10 mm in length, and 8–9 mm in width. It is placed obliquely making an angle of about 55° with the floor of the external acoustic meatus. The tympanic membrane faces downwards, forwards, and laterally as though to catch the sounds reflected from the ground. Consequently the anterior wall and the floor of external auditory meatus are longer than the posterior wall and the roof.

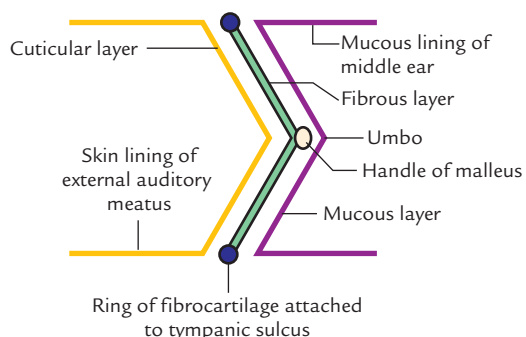


Fig. 18.4 Layers of the tympanic membrane.

Structure

The tympanic membrane is made of three layers (Fig. 18.4); from lateral to medial these are as follows:

1. **Outer cuticular layer** of stratified squamous epithelium, which is continuous with the skin lining the external auditory meatus.
2. **Middle fibrous layer**, which encloses the handle of the malleus. It contains outer radiating and inner circular fibres.
3. **Inner mucosal layer** is lined by low columnar epithelium, which is continuous with the mucous lining of the middle ear.

Parts

The tympanic membrane is divided into two parts: pars tensa and pars flaccida.

Pars tensa forms most of the tympanic membrane. Its periphery is thickened to form a fibrocartilaginous rim called **annulus tympanicus**, which fits into the tympanic sulcus. The fibrocartilaginous rim presents a notch above. From the margins of the notch the anterior and posterior malleolar folds in mucous membrane of tympanic cavity pass to gain attachment to the lateral process of the malleus. The handle of the malleus is firmly attached to the inner surface of the pars tensa. This part is rendered tough by the inward pull of the tensor tympani muscle, attached to the root of handle of the malleus and radial fibres.

Pars flaccida (Shrapnell's membrane) is a small triangular area above the lateral process of malleus between *anterior and posterior malleolar folds* (now called *malleal folds*). This part is thin and lax because intermediate fibrous layer here is replaced by loose areolar tissue. It appears slightly pinkish.

Surfaces

Lateral surface of the tympanic membrane is concave towards the meatus and directed downwards, forwards, and laterally.

Medial surface is convex and bulges towards the middle ear. The point of maximum convexity is called **umbo** (Fig. 18.5). When the tympanic membrane is illuminated for

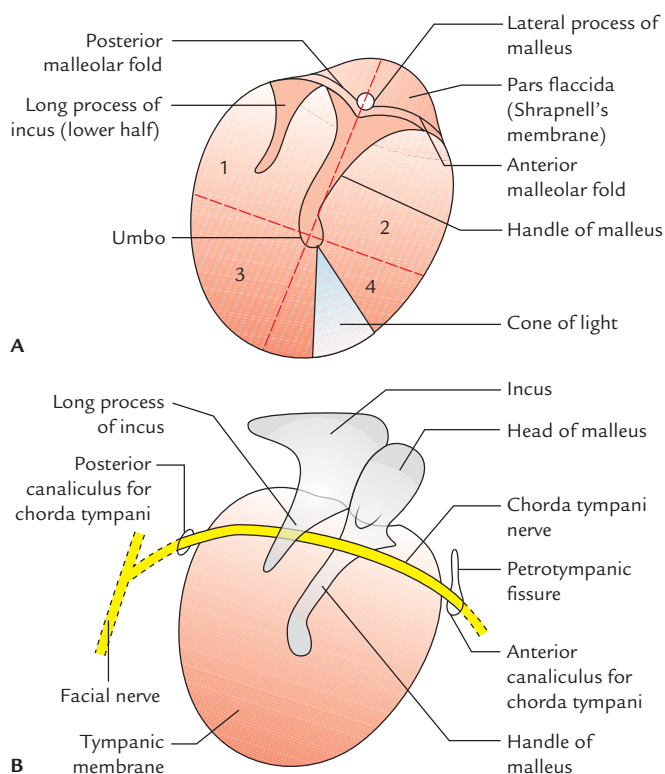


Fig. 18.5 Tympanic membrane (schematic diagram): **A**, external surface of tympanic membrane as seen through otoscope: 1 = posterosuperior quadrant, 2 = anterosuperior quadrant, 3 = posteroinferior quadrant, 4 = anteroinferior quadrant; **B**, medial surface of tympanic membrane showing the course of the chorda tympani nerve.

inspection, the concavity of the membrane produces a '*cone of light*' radiating from the umbo over the anteroinferior quadrant. This surface receives the attachment of malleus up to the center of the membrane. Here the handle of the malleus is crossed medially by chorda tympani nerve, which runs forwards between the fibrous and mucosal layer at the junction of pars flaccida and pars tensa.

Arterial Supply

1. The outer surface is supplied by deep auricular artery, a branch from first part of maxillary artery.
2. The inner surface is supplied by (a) anterior tympanic artery, a branch from first part of maxillary artery, and (b) posterior tympanic artery, a branch from stylomastoid artery arising from posterior auricular artery.

Venous Drainage

1. Veins from outer surface drain into external jugular vein.
2. Veins from inner surface drain into transverse sinus and pterygoid venous plexus.

Nerve Supply

1. Anterior half of the lateral surface is supplied by the auriculotemporal nerve (V3).
2. Posterior half of the lateral surface by the auricular branch of vagus (CNX).
3. Medial surface by tympanic branch of the glossopharyngeal (CNIX) through tympanic plexus.

Clinical correlation

- **Perforation of the tympanic membrane:** It may result from an external injury or middle ear infection (otitis media).
- **Examination of tympanic membrane:** Inspection of the tympanic membrane with an otoscope provides significant information about the condition of the middle ear. The color, curvature, presence of lesions, and position of malleus are features of special importance. When tympanic membrane is illuminated for examination, a cone of light is reflected in the anteroinferior quadrant of the membrane from umbo, the point of maximum concavity, which marks the attachment of the handle of the malleus. Since the membrane is semitranslucent, the following structures lying deep to it can be seen (Fig. 18.6):
 - *Handle of Malleus*, as a yellow streak extending from umbo upwards and forwards.
 - *Lateral process of malleus*, as a white prominence in the upper part of the streak of handle of malleus.
 - *Long processes of incus*, as white streaks behind and parallel to the upper part of the handle of malleus.
 - A cone of light at 5 o'clock position in anteroinferior quadrant.

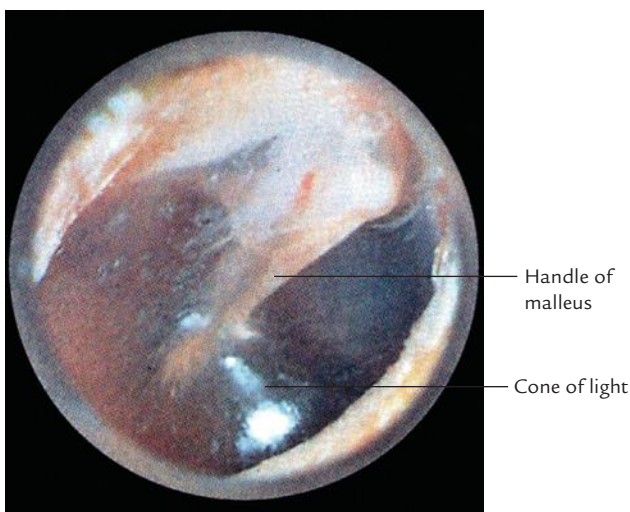


Fig. 18.6 Otoscopic view of the tympanic membrane. (Source: Fig. 8.109 B, Page 857, *Gray's Anatomy for Students*, Richard L Drake, Wayne Vogl, Adam WM Mitchell. Copyright Elsevier Inc., 2005, All rights reserved.)

Clinically, the tympanic membrane is divided into four quadrants by means of two imaginary lines passing through the umbo. One is drawn along the handle of the malleus and the other at right angle to it through the umbo.

N.B. On illumination the normal membrane looks pearly grey. Sometimes an incision is given in the tympanic membrane (*myringotomy*) to drain the pus from the middle ear. The incision is usually given in the posteroinferior quadrant to avoid injury to the chorda tympani nerve, which crosses the inner aspect of the membrane in the upper part.

Development

The tympanic membrane develops from first pharyngeal membrane consisting, from superficial to deep, of three layers: ectoderm, mesoderm, and endoderm.

Therefore, the tympanic membrane also consists of three layers from superficial to deep these are:

1. *Cuticular layer*, derived from ectoderm.
2. *Intermediate layer*, derived from mesoderm.
3. *Mucous layer*, derived from endoderm.

The three layers of tympanic membrane are likened to the three layers of *trilaminar embryonic disc*.

MIDDLE EAR

The middle ear (syn. tympanum, tympanic cavity) is a narrow slit-like air-filled cavity within the petrous part of the temporal bone. The middle ear is sandwiched between the external and internal ear. It contains three auditory ossicles, which transmit sound vibrations from tympanic membrane in its lateral wall to the internal ear via its medial wall. The tympanic cavity is really the intermediate portion of a blind diverticulum from the respiratory mucous membrane of the nasopharynx. From front to back, the diverticulum consists of pharyngotympanic tube, tympanic cavity, and mastoid antrum.

In a section through long axis of petromastoid bone, the outline of tympanic cavity together with mastoid antrum and pharyngotympanic tube resembles a pistol, the nozzle being represented by the tube, the body by tympanic cavity, and handle by mastoid antrum (Fig. 18.7).

Size and Shape

The middle ear is shaped like a cube, compressed from side to side. In coronal section, it resembles a biconcave disc, like a red blood cell (Fig. 18.8).

Measurements

- *Vertical diameter:* 15 mm.
- *Anteroposterior diameter:* 15 mm.

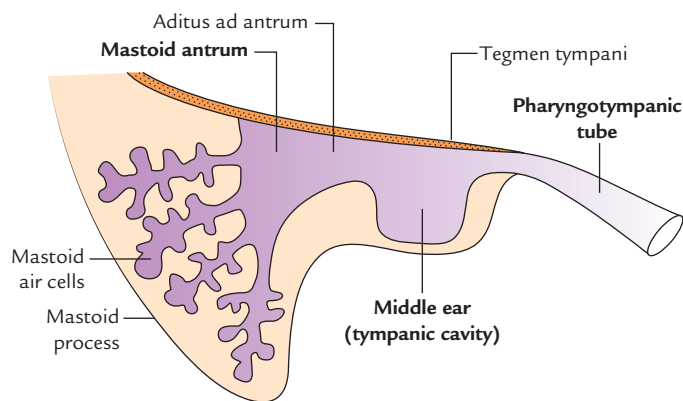


Fig. 18.7 Section through long axis of the petromastoid bone showing pharyngotympanic tube, middle ear (tympanic cavity), and mastoid antrum.

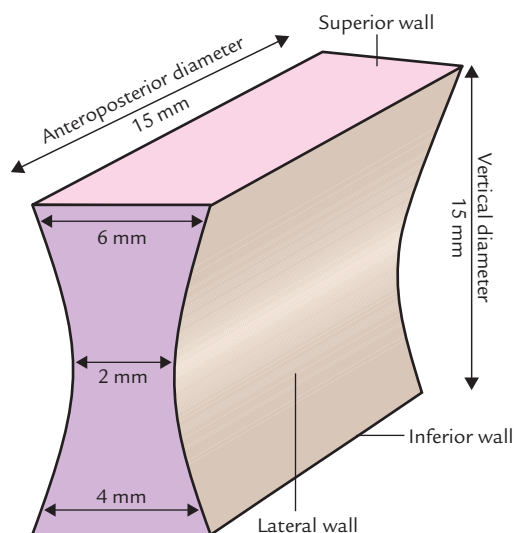


Fig. 18.8 The shape and dimensions of the middle ear cavity.

- **Transverse diameters**
 - (a) At roof: 6 mm.
 - (b) In the center: 2 mm.
 - (c) At the floor: 4 mm.

Communication

The middle ear communicates:

- Anteriorly* with nasopharynx through pharyngotympanic tube.
- Posteriorly* with mastoid antrum and mastoid air cells through aditus to antrum called **aditus ad antrum**.

Contents of the Middle Ear

Inside the mucous lining:

1. Air.

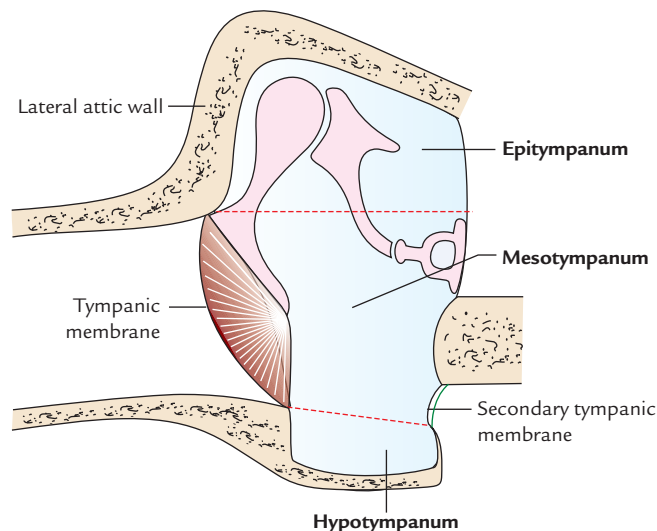


Fig. 18.9 Subdivisions of the middle ear.

Outside the mucous lining:

1. Three small bones called ear ossicles: malleus, incus, and stapes.
2. Two muscles: tensor tympani and stapedius.
3. Two nerves: chorda tympani and tympanic plexus.
4. Vessels supplying and draining the middle ear.
5. Ligaments of the ear ossicles.

N.B. The mucous membrane lining of the middle ear invests all the structures within it and forms several folds, which project into the cavity giving it a honey-comb appearance.

Thus strictly speaking, the middle ear contains only air.

Subdivisions of the Middle Ear (Fig. 18.9)

The tympanic cavity extends much beyond the limits of tympanic membrane, which forms its lateral boundary. It is divided into three parts, *viz.*

1. **Epitympanum (attic)**, a part above the tympanic membrane containing head of malleus, body, and short process of incus.
2. **Mesotympanum**, a part opposite to tympanic membrane containing handle of malleus, long process of incus, and stapes. It is the narrowest part of the middle ear.
3. **Hypotympanum**, a part below the tympanic membrane.

Boundaries (Fig. 18.10)

The middle ear is likened to a six-sided box and thus presents six walls, namely,

1. Roof.
2. Floor.
3. Anterior wall.
4. Posterior wall.
5. Medial wall.
6. Lateral wall.

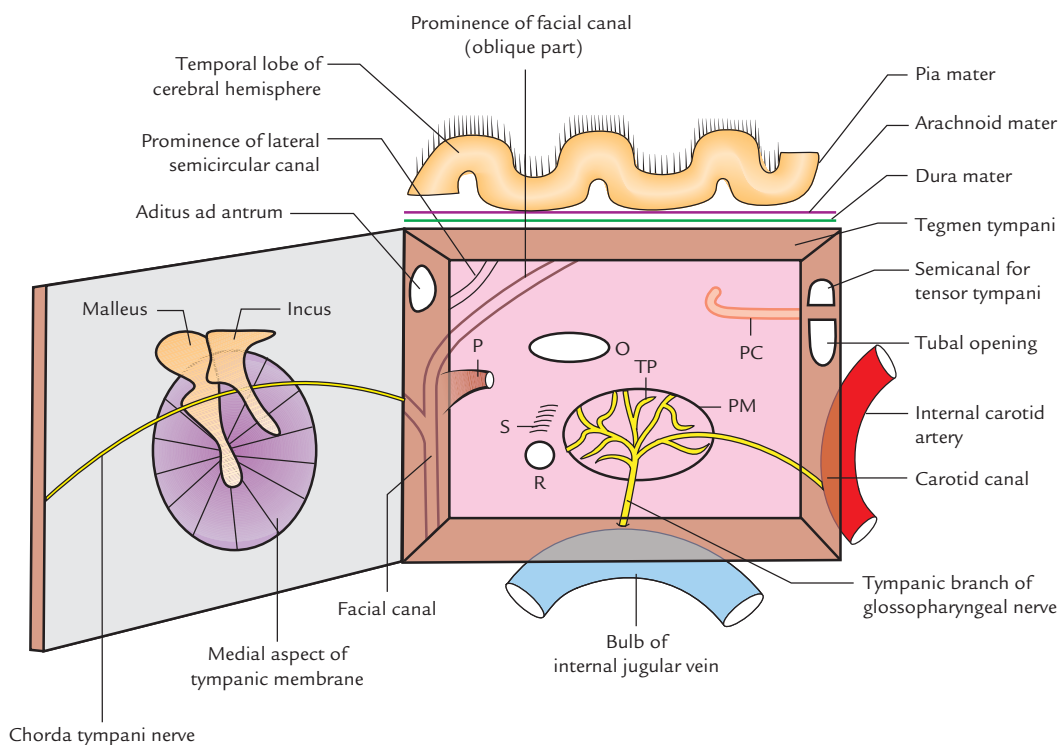


Fig. 18.10 Schematic diagram to show the boundaries (and their relations) of the middle ear. The middle ear is likened to a six-sided box and its lateral side is opened out (O = oval window, P = pyramid, PC = processus cochleariformis, PM = promontory, R = round window, S = sinus tympani, TP = tympanic plexus).

Roof: It is formed by a thin plate of bone called **tegmen tympani**. It separates the tympanic cavity from the middle cranial fossa. The tegmen tympani also extend posteriorly to form the roof of **aditus ad antrum**.

Floor: The floor is also formed by a thin plate of bone, which separates the tympanic cavity from the jugular bulb. Sometimes it is congenitally deficient and the jugular bulb then projects into the middle ear, being separated from cavity only by mucosa.

The **tympanic branch** of glossopharyngeal nerve pierces the floor between the jugular fossa and lower opening of the carotid canal and enters the tympanic cavity to take part in the formation of tympanic plexus.

Anterior wall: It is formed by a thin plate of bone. In the lower part it separates the cavity from internal carotid artery. The upper part of anterior wall presents two openings or canals, the upper one for the tensor tympani muscle and the lower one for the auditory tube.

The bony partition between the two canals extends backwards along the medial wall in the tympanic cavity as a curved lamina called **processus cochleariformis**.

Posterior wall: The posterior wall separates the tympanic cavity from mastoid antrum and mastoid air cells, and presents the following features:

1. **Aditus ad antrum**, an opening in the upper part through which tympanic cavity communicates with the mastoid antrum.
2. **Fossa incudis**, a small depression close to the aditus, lodging the short process of the incus.
3. **Pyramid**, a hollow conical bony projection below the aditus containing stapedius muscle whose tendon appears through its summit, passes forwards to be attached to the neck of the stapes.
4. **Vertical part of facial canal** runs in the posterior wall just behind the pyramid and descends up to the stylomastoid foramen.
5. **Posterior canaliculus for chorda tympani**, a small aperture for emergence of this nerve.

Medial wall: It separates the tympanic cavity from the internal ear; thus it is actually formed by the bony lateral wall of the internal ear. The medial wall presents the following features:

1. **Promontory**, a rounded prominence in the centre produced by first (basal) turn of the cochlea. The tympanic branch of the glossopharyngeal nerve ramifies on it to form **tympanic plexus**.
2. **Oval window (fenestra vestibuli)**, a reniform aperture located above and behind the promontory. It is closed by the base of stapes and annular ligament.

3. **Round window (fenestra cochleae)**, a small round opening below and behind the promontory which in life, is closed by fibrous secondary tympanic membrane. The secondary tympanic membrane separates the middle ear from the scala tympani.
4. **Sinus tympani**, a depression behind the promontory between fenestra vestibuli and fenestra cochleae, which indicates the position of ampulla of the posterior semicircular canal.
5. **Prominence of oblique part of the facial canal** that extends backwards and downwards above the oval window until it joins the vertical part of the facial canal in the posterior wall of the tympanic cavity. Sometimes the bony covering of the facial nerve may be absent, thus exposing the nerve for injuries and infection.
6. **Prominence of lateral semicircular canal of the internal ear**, which is seen as a small ridge high up in the angle between the medial and posterior walls.

Lateral wall: Most of the lateral wall is formed by **tympanic membrane**, which separates the tympanic cavity from the external auditory meatus (Fig. 18.10).

The **chorda tympani nerve**, a branch of facial nerve passes across the tympanic membrane lying lateral to the long process of the incus and medial to the handle of the malleus.

It enters the tympanic cavity through the posterior canaliculus in the posterior wall and leaves through the anterior canaliculus medial to the petrotympanic fissure.

Clinical correlation

Infection of the middle ear (otitis media): It is common especially in infants and children. Infective agents reach the middle ear from the upper respiratory tract through pharyngotympanic tube. The long-standing infection leads to chronic suppurative otitis media (CSOM), which clinically presents as ear discharge and perforation of tympanic membrane. The spread of infection from the middle ear may give rise to the following clinical conditions:

- *Acute mastoiditis and mastoid abscess*, when infection spreads into mastoid antrum and mastoid air cells through aditus ad antrum in the posterior wall.
- *Meningitis and temporal lobe abscess* may occur, if infection spreads upwards through the thin roof (tegmen tympani).
- *Lower motor neuron type of facial palsy*, when infection erodes the papery thin bony wall of facial canal.
- *Transverse and sigmoid sinus thrombosis*, when infection spreads through the floor.
- *Labyrinthitis*, when infection spreads deep into medial wall. The labyrinthitis causes *vomiting and vertigo*.
- *Cerebellar abscess*, when infection spreads too far posteromedially.

Ear Ossicles

The three ear ossicles (malleus, incus, and stapes) within the middle ear are connected to one another by synovial joints

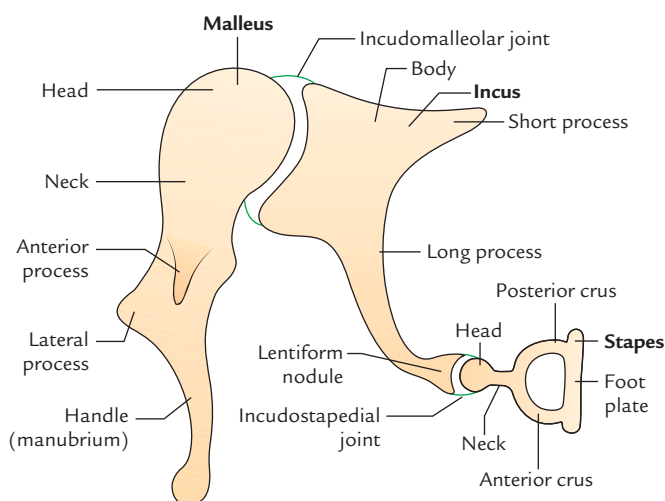


Fig. 18.11 Ear ossicles.

and form a bony chain that extend across the tympanic cavity from the tympanic membrane to the oval window (Fig. 18.11). They conduct sound vibrations from tympanic membrane to the oval window and subsequently to the inner ear fluid.

Malleus

It resembles a hammer and, therefore, known as *malleus*. It has head, neck, handle (manubrium), a lateral process, and an anterior process. The head and neck lie in the epitympanum, whereas the handle is embedded in the fibrous layer of tympanic membrane. The lateral process forms a knob-like projection on the outer surface of the tympanic membrane and provides attachment to the anterior and posterior malleolar folds. The head of malleus articulates with the body of the incus forming the incudomalleolar joint (saddle type of synovial joint).

Incus

It resembles an anvil or a premolar tooth in shape. It consists of a relatively large body and two slender processes: a short process and a long process. The body and short process lie in the attic, whereas its long process hangs vertically behind and parallel with the handle of the malleus. Its bulbous tip (lentiform nodule) is directed medially to articulate with the head of the stapes, forming the incudostapedial joint (ball and socket type of synovial joint).

Stapes

It resembles a stirrup. It consists of head, neck, anterior and posterior crura, and footplate. The footplate closes the oval window and is attached to its margin by annular ligament. The features of ear ossicles are summarized in Table 18.1.

Table 18.1 Features of the three ear ossicles

	Malleus	Incus	Stapes
Resemblance	Hammer	Anvil or premolar tooth	Stirrup
Development	First pharyngeal arch cartilage	First pharyngeal arch cartilage	Second pharyngeal arch cartilage
Muscle attached	Tensor tympani	None	Stapedius
Joint/Joints	Incudomalleolar (saddle type of synovial joint)	Incudomalleolar and incudo-stapedial	Incudostapedial (ball and socket type of synovial joint)

Table 18.2 Origin, insertion, nerve supply, and actions of the intratympanic muscles

Muscle	Origin	Insertion	Nerve supply	Actions
Tensor tympani	Cartilaginous part of the auditory tube and sulcus tubae	Medial aspect of the upper end of handle of malleus	Mandibular nerve (V3)	Tenses the tympanic membrane
Stapedius	Interior of hollow pyramidal eminence on the posterior wall of tympanic cavity	Posterior aspect of the neck of stapes	Facial nerve (CNVII)	Draws the stapes laterally thus tilting its footplate in the oval window

Intratympanic Muscles

There are two intratympanic muscles: **tensor tympani** and **stapedius**.

The features of these muscles are enumerated in Table 18.2.

Clinical correlation

Hyperacusis: Both, tensor tympani and stapedius contract reflexly and simultaneously to dampen very loud sounds, thus preventing noise trauma to the internal ear. The paralysis of stapedius results in *hyperacusis* (an abnormally increased power of hearing) where even whisper appears as noise.

Otosclerosis: Abnormal ossification of annular ligament, which anchors the footplate of stapes to the oval window is called *otosclerosis*. This impedes the movements of stapes and causes deafness. *The otosclerosis is the most common cause of conductive deafness in adults.*

Arterial Supply

The middle ear is supplied by six arteries, *viz.*

1. Anterior tympanic branch of the maxillary artery.
2. Stylomastoid branch of the posterior auricular artery.
3. Petrosal branch of the middle meningeal artery, running along the greater petrosal nerve.
4. Superior tympanic branch of the middle meningeal artery, running along the canal for tensor tympani.
5. Branch from the artery of pterygoid canal.
6. Tympanic branch of the internal carotid artery.

N.B. Out of the six arteries, first two—anterior tympanic branch of the maxillary and stylomastoid branch of the posterior auricular artery are the main source of the blood supply.

Venous Drainage

The veins from middle ear drain into:

1. Pterygoid venous plexus, via squamotympanic fissure.
2. Superior petrosal sinus, through subarcuate fossa.

Lymphatic Drainage

The lymphatics from middle ear drain into:

1. Retropharyngeal lymph nodes.
2. Parotid lymph nodes.
3. Upper deep cervical lymph nodes.

Nerve Supply

1. **Tympanic branch of glossopharyngeal nerve:** It enters the middle ear through a canaliculus in the floor of the tympanic cavity and takes part in the formation of tympanic plexus.

It provides **sensory supply** to the lining of middle ear, antrum, and auditory tube.

Its preganglionic parasympathetic fibres supply the secretomotor fibres to the parotid gland.

2. **Superior and inferior caroticotympanic nerves:** They are vasomotor and derived from sympathetic plexus around the internal carotid artery.
3. **Facial nerve:** It runs in the bony canal along the medial and posterior walls of tympanic cavity and gives rise to three branches, *viz.*
 - (a) *Chorda tympani nerve*, which (i) carries taste sensations from anterior two-third of the tongue except vallate papillae, and (ii) provides secretomotor fibres to submandibular and sublingual salivary glands.
 - (b) *Greater petrosal nerve*, which provides secretomotor fibres to lacrimal, nasal, and palatal mucous glands.
 - (c) *Nerve to stapedius muscle.*

4. **Mandibular nerve:** It provides motor fibres to tensor tympani muscle.

Tympanic Plexus

It is a plexus of nerves on the promontory in the medial wall of the middle ear. It is formed by:

- tympanic branch of the glossopharyngeal nerve* (Jacobson's nerve).
- superior and inferior caroticotympanic nerves* derived from sympathetic plexus around the internal carotid artery, and
- branch from facial ganglion* (geniculate ganglion).

The tympanic plexus supplies mucous membrane of the middle ear, mastoid air cells, and bony eustachian tube. The lesser petrosal nerve derived from it contains secretomotor fibres of glossopharyngeal nerve to supply the parotid gland via otic ganglion.

Clinical correlation

Referred pain of ear: Since the middle ear and external ear are supplied by the branches of trigeminal (CNV), glossopharyngeal (CNIX) and vagus (CNX) nerves, the pain in the ear (*otalgia*) is often referred to other areas supplied by these nerves, e.g., tongue, teeth, tonsil, and pharynx.

Mastoid Antrum

It is a large air-containing space in the upper part of the mastoid process. It communicates anteriorly with tympanic cavity through aditus ad antrum. Its roof is formed by **tegmen antri**, which is the backward continuation of **tegmen tympani**. It separates the antrum from middle cranial fossa. The lateral wall of the antrum is formed by a plate of bone, which is on an average 1.5 cm thick in the adult. (It is only 2 mm thick in a newborn.) It is marked on the surface of mastoid by suprameatal triangle (McEwen's triangle).

The floor of antrum receives the openings of mastoid air cells. Its posterior wall is related to sigmoid sinus whereas its medial wall presents bulging of the lateral semicircular canal.

Development

Mastoid antrum develops as a backward extension of tympanic cavity and assumes the full adult size at birth.

Clinical correlation

The **mastoid abscess** is a common condition. The antrum is approached surgically through its lateral wall. Thus it is important to assess the limits of suprimeatal triangle. This triangle is bounded *above* by supramastoid crest, *anteroinferiorly* by posterosuperior segment of bony external auditory meatus and *posteriorly* by a line drawn as a tangent to the posterior margin of the bony meatal opening.

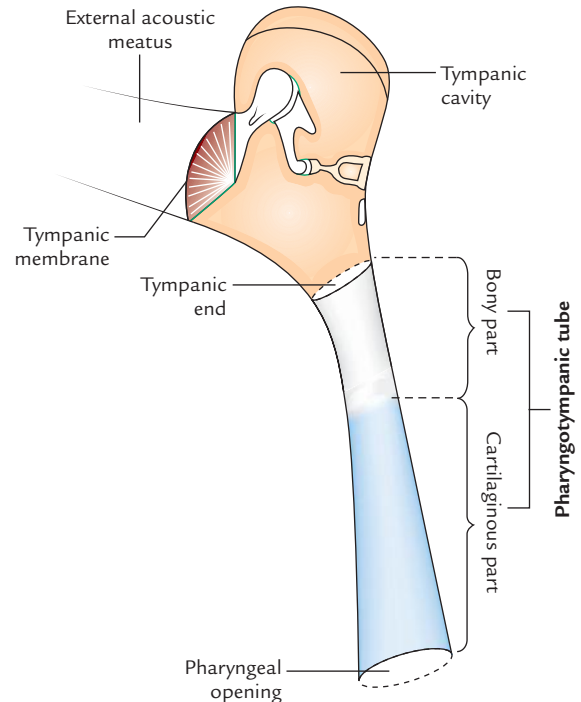


Fig. 18.12 Pharyngotympanic tube.

Pharyngotympanic Tube (Fig. 18.12)

The pharyngotympanic tube (auditory tube) is an osseocartilaginous tube, which connects the nasopharynx with tympanic cavity (middle ear). It is directed downwards, forwards, and medially from the tympanic cavity to the nasopharynx.

The auditory tube maintains equilibrium of air pressure on either side of the tympanic membrane for its proper vibration.

The pharyngotympanic tube is described in detail in Chapter 14.

Development of the Middle Ear

The auditory tube and middle ear develop from **endodermal tubotympanic recess**, which arises from the first pharyngeal pouch (and partly from second pharyngeal pouch). The mastoid antrum develops as an extension of the middle ear cavity into the mastoid process.

The **malleus and incus** develop from **mesoderm of the first arch**. The **stapes** develops from mesoderm of the second arch except its foot plate and annular ligament, which are derived from otic capsule.

INTERNAL EAR

The internal ear consists of a closed system of fluid filled intercommunicating membranous sacs and ducts called **membranous labyrinth**. The fluid filled in the membranous labyrinth is called **endolymph**. The membranous labyrinth

lies within the complex intercommunicating bony cavities and canals (**bony labyrinth**) in the petrous part of the temporal bone. The space between the membranous and bony labyrinth is filled with fluid called **perilymph**. The sensory receptors within the membranous labyrinth are responsible for hearing and balancing (equilibrium).

Components of the Internal Ear

The internal ear consists of two components, *viz.*

1. Membranous labyrinth.
2. Bony labyrinth.

MEMBRANOUS LABYRINTH (Fig. 18.13)

The membranous labyrinth consists of the following four parts (Fig. 18.12A):

1. Cochlear duct.
2. Sacculle.
3. Utricle.
4. Semicircular ducts (three).

The cochlear duct lies within the bony cochlea, the sacculle, and utricle lie within the bony vestibule, and three

semicircular ducts lie within the three bony semicircular canals.

These four parts are interconnected as follows:

1. The cochlear duct (basal turn) is connected to sacculle by *ductus reuniens*.
2. The sacculle and utricle are connected to each other by Y-shaped *utrículo-saccular duct*, which expands to form *ductus and sacculus endolymphaticus*.
3. The utricle is connected to three semicircular ducts through five openings.

N.B.

- The sensory receptor within cochlear duct is *spiral organ of Corti*. It is concerned with hearing.
- The sensory receptors within sacculle and utricle are *maculae*. They are concerned with static balance.
- The sensory receptors within the semicircular ducts are *cristae ampullaris*. They are concerned with kinetic balance.

The sensations from *cristae* (kinetic balance) and *maculae* (static balance) are carried by vestibular nerve, while sensations of hearing from spiral organ are carried by the cochlear nerve (Fig. 18.14).

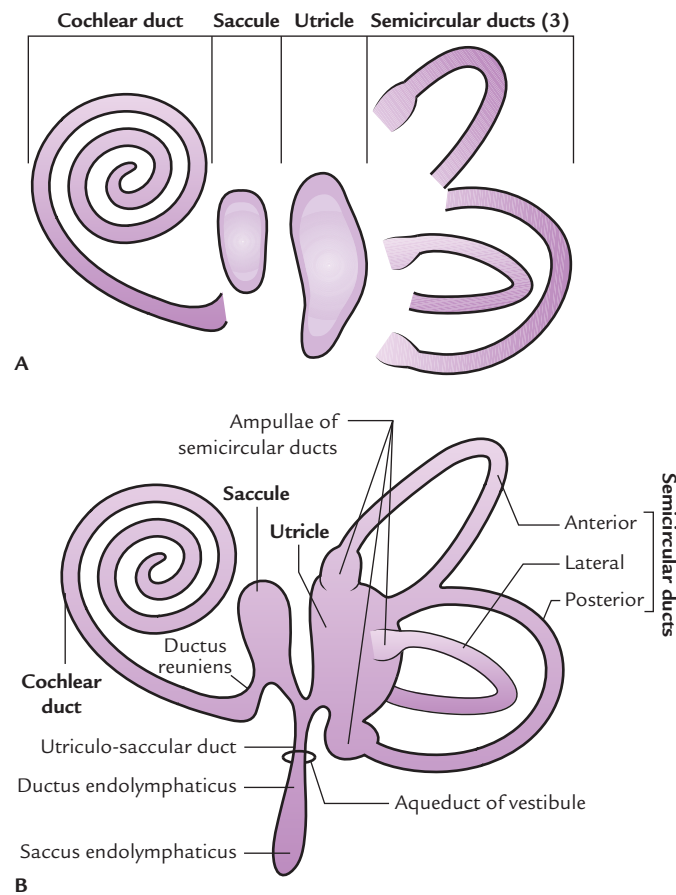


Fig. 18.13 Membranous labyrinth: A, four parts of labyrinth; B, complete labyrinth.

Cochlear Duct (Scala Media)

The cochlear duct is a spiral anterior part of the membranous labyrinth having two- and three-fourth turns. It lies in the middle part of the cochlear canal between *scala vestibuli* and *scala tympani*. The cochlear duct contains **spiral organ of Corti**, which is sensory receptor for hearing.

Structure

The structure of cochlear duct is best studied in cross section of the cochlear canal. In cross section, the cochlear duct is triangular in shape (Fig. 18.15).

Boundaries

- Base:** Formed by the osseous spiral lamina (medially) and basilar membrane (laterally).
- Roof:** Formed by the vestibular membrane (Reissner's membrane), which passes from upper surface of spiral lamina to the wall of cochlea.
- Laterally:** It is bounded by the outer wall of cochlear canal.

Spiral Organ of Corti

It is the peripheral organ of hearing in the cochlear duct and is situated on the basilar membrane. The important components of the organ of Corti are as follows:

1. **Tunnel of Corti:** It is formed by the inner and outer rod cells. It contains a fluid called *corticolymphe*. The exact function of *rods* and *corticolymphe* is not known.
2. **Hair cells:** These are receptor cells of hearing located on basilar membrane and their apices possess stereocilia

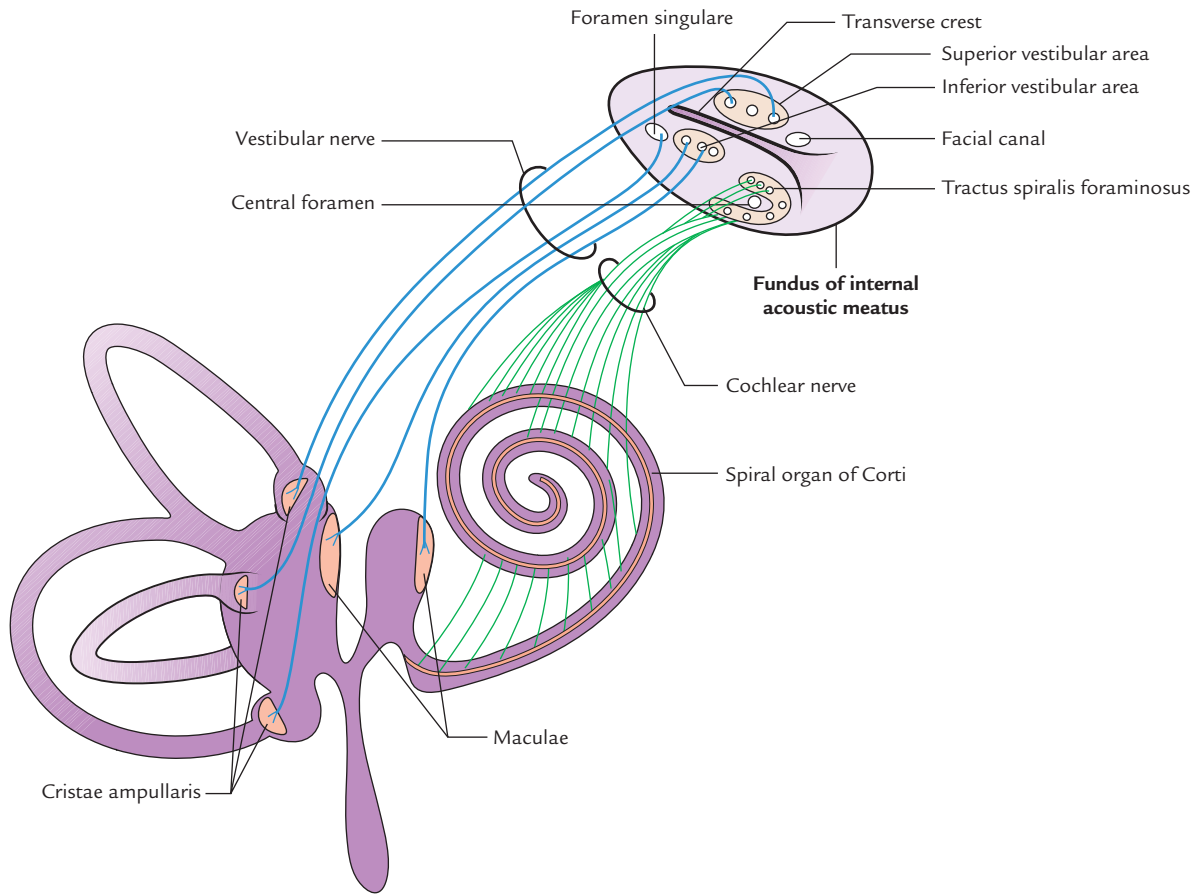


Fig. 18.14 Sensory receptors in different parts of the membranous labyrinth and nerves, which carry sensations from them.

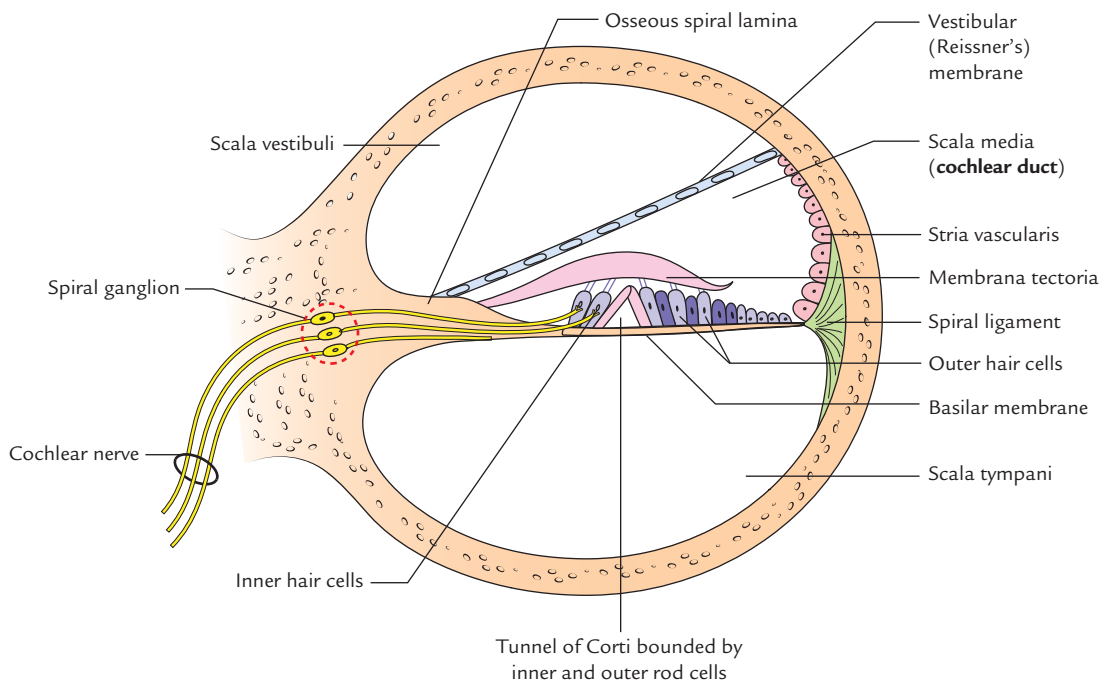


Fig. 18.15 Cross-section of the cochlear canal showing boundaries of the cochlear duct and organ of Corti within it.

(hair), which are overlaid by *tectorial membrane*. The inner cells are flask shaped and arranged in a single row while outer cells are cylindrical and arranged in 3 or 4 rows. When sound vibrations (in fact fluid waves) pass from perilymph of scala vestibuli to the perilymph of scala tympani, the basilar membrane bulge and the overlying hair cells are stimulated. The inner hair cells are richly supplied by the cochlear nerve fibres and are responsible for transmission of auditory impulses. The outer hair cells are innervated by efferent fibres from the olivary complex and are concerned with modulation function of inner hair cells.

3. **Supporting cells (Deiter's and Hansen's Cells):** The Deiter's cells are situated between the outer hair cells and provide support to the latter. The Hansen's cells lie outside the hair cells.
4. **Membrana tectoria:** It is made up of gelatinous substance and overlies the hair cells. Medially it is attached to osseous spiral lamina. The shearing force between the hair cells and tectorial membrane stimulate the hair cells.

N.B. The scala vestibuli and scala tympani containing perilymph lie above and below basilar membrane respectively. Therefore cochlea duct (containing endolymph) is bathed above and below by the perilymph within the two scalae. The two scala are continuous with each other through a narrow opening at the apex of cochlear duct called *helicotrema* (Fig. 18.17).

Innervation of Hair Cells of Organ of Corti

Ninety-five percent of afferent fibres (peripheral processes of bipolar neurons of spiral ganglion) supply the inner hair cells while only 5% supply the outer hair cells. The spiral ganglion is located in the spiral canal within the modiolus near the base of the spiral lamina. The central processes of ganglion cells form the cochlear nerve.

Efferent fibres to the outer hair cells come from olivocochlear bundle. Their cell bodies are located in the superior olivary complex.

Sacculae and Utricle

The *sacculae*, a small globular membranous sac, lies in the anteroinferior part of the vestibule. The utricle is an oblong membranous sac and is larger than the sacculae. It lies in the posterosuperior part of the vestibule.

The sacculae is connected in front to the basal turn of cochlear duct by the **ductus reuniens** and behind with the utricle by a Y-shaped **utrículo-saccular duct**. The vertical limb of 'Y' continues as endolymphatic duct (*ductus endolymphaticus*) and its dilated blind terminal end is called **sacculus endolymphaticus**. The endolymphatic duct passes through a bony canal (aqueduct of vestibule) in the posterior part of petrous temporal bone and its dilated terminal end projects on the posterior surface of petrous temporal bone

beneath the dura mater of the posterior cranial fossa. The endolymph is absorbed by the epithelial cells lining the saccus and drains into extradural vascular plexus.

The utricle receives the three semicircular ducts posteriorly through five openings.

Semicircular Ducts

The three semicircular ducts—anterior, posterior, and lateral lie within the corresponding semicircular canals. They open into the utricle by five openings.

Each duct has one dilated end called **ampulla**. It corresponds to the ampulla of the corresponding semicircular canal. The ampullary end of each duct bears a raised crest (*crista ampullaris*), which projects into its lumen.

Peripheral receptors in saccule, utricle, and semicircular ducts (vestibular system) are as follows:

1. **Maculae:** These are sensory receptors located in the medial walls of saccule and utricle. They sense position of head in response to gravity and linear acceleration, i.e., *static balance*.
2. **Cristae:** These are sensory receptors located in the ampullated ends of the three semicircular ducts. They respond to angular acceleration, i.e., *kinetic balance*.

Innervation of Peripheral Receptors of Vestibular System

The vestibular or Scarpa's ganglion is situated in the lateral part of the internal acoustic meatus. It consists of bipolar neurons. The peripheral processes of these cells innervate hair cells of cristae and maculae, while their central processes aggregate to form the vestibular nerve.

BONY LABYRINTH

The bony labyrinth consists of a series of intercommunicating bony cavities and canals within the petrous part of the temporal bone.

Parts

The bony labyrinth presents three parts (Fig. 18.16); from before backwards these are as follows:

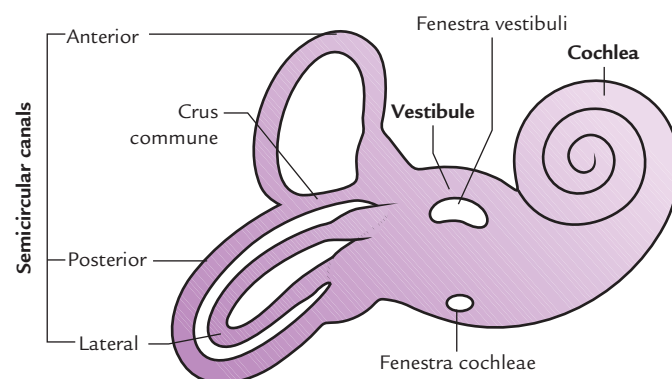


Fig. 18.16 Parts of the bony labyrinth.

1. Cochlea.
2. Vestibule.
3. Semicircular canals (three).

Cochlea

The cochlea resembles the shell of a common snail. Its apex (cupula) is directed towards the medial wall of the tympanic cavity, while its base is directed towards the bottom of the internal acoustic meatus.

The cochlea consists of a central pillar called modiolus, and a bony cochlear canal:

1. **Modiolus** is the axial bony stem around which the cochlear canal spirals. It is like an elongated cone. The base of modiolus lies at the fundus of the internal acoustic meatus and apex points towards the middle ear. The apex of the modiolus is overlaid by the apical turn of the cochlear canal. The modiolus is perforated spirally at its base in the internal acoustic meatus by the fibres of the cochlear nerve.
2. **Cochlear canal** is arranged spirally around the modiolus and makes two and three-fourth turns. Its basal turn bulges into tympanic cavity as the *promontory*.

A spiral ridge of bone called **spiral lamina** projects from the surface of the modiolus into the cochlear canal like a thread of a screw. The free edge of lamina splits into the upper and lower lips. The vestibular membrane extends from the upper lip of lamina to the outer wall of the cochlea, while basilar membrane extends from the lower lip of the lamina to the outer wall of the cochlea. The triangular area thus enclosed by the vestibular and basilar membranes, and the outer wall of the cochlear canal forms the **cochlear duct (scala media)**.

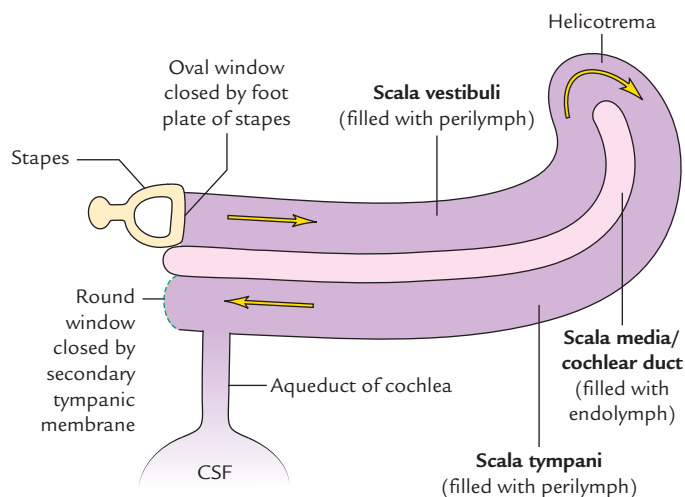


Fig. 18.17 Diagrammatic representation of the cochlear duct within cochlear canal. Note that cochlear duct is filled with endolymph and scala vestibuli and scala tympani are filled with perilymph (CSF = cerebrospinal fluid).

The spiral lamina partly divides the cochlear canal into scala vestibuli above and scala tympani below. The scala vestibuli and scala tympani communicate with each other at the apex of the cochlea by a small opening called **helicotrema** (Fig. 18.17).

At the basal turn of cochlea, the scala vestibuli communicates with the anterior wall of the vestibule. Close to the basal turn of cochlea the scala tympani presents two features—fenestra cochleae and beginning of the aqueduct of cochlea:

1. The **fenestra cochleae** open into the tympanic cavity below and behind the promontory. It is closed by secondary tympanic membrane in life.
2. The **aqueduct of cochlea** is a narrow tubular canal through which perilymph within the cochlea communicates with the cerebrospinal fluid (CSF) of the subarachnoid space through cochlear canaliculus.

Vestibule

The vestibule is a central ovoid cavity of bony labyrinth between cochlea in front and three semicircular canals behind. It lies medial to the middle ear cavity.

The **lateral wall** of the vestibule communicates with the middle ear cavity by **fenestra vestibuli**, which in life is closed by footplate of stapes and annular ligament.

The **medial wall** of the vestibule presents two recesses (Fig. 18.18): a **spherical recess** in front and an **elliptical recess** behind. The two recesses are separated by the vestibular crest, which splits inferiorly to enclose the cochlear recess. The spherical recess lodges saccule and is perforated by foramina

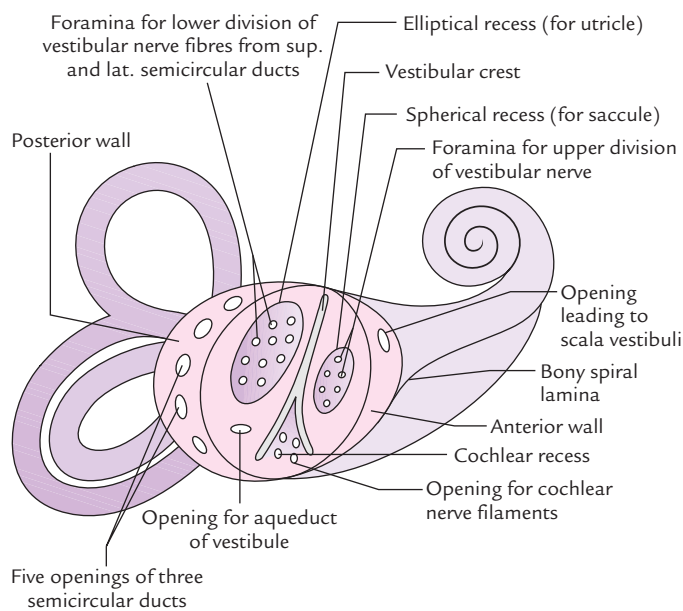


Fig. 18.18 Schematic interior of the bony labyrinth showing features in the medial, posterior, and anterior walls of the vestibule.

for the passage of lower division of the vestibular nerve. The elliptical recess lodges the utricle, and is perforated by foramina for the passage of the upper division of the vestibular nerve.

Just below the elliptical recess, there is an opening of a bony canal called **aqueduct of vestibule**, which reaches the epidural space on the posterior surface of the petrous temporal bone. The aqueduct of vestibule transmits the tubular prolongation of membranous labyrinth, the **sacculus** and **ductus endolymphaticus**. The **anterior** wall of the vestibule bears an opening, which communicates with **scala vestibuli** of the cochlear canal. The **posterior** wall of the vestibule bears five openings of three semicircular canals.

Semicircular canals

There are three bony semicircular canals: anterior (superior), posterior, and lateral. They lie in three planes at right angles to each other (Fig. 18.19). Each canal is about two-third of a circle and is dilated at one end to form the **ampulla**:

1. The **anterior semicircular canal** lies in a vertical plane at right angle to the long axis of the petrous temporal bone. It is convex upwards and its position is indicated on the anterior surface of the petrous temporal bone as **arcuate eminence**. Its anterior ampullated end communicates with vestibule anterolaterally. Its posterior non-ampullated end unites with the upper non-ampullated end of the posterior semicircular canal to form **crus commune**, which opens into vestibule.
2. The **posterior semicircular canal** also lies in a vertical plane parallel to the long axis of petrous temporal bone. Its convexity is directed backwards. Its lower ampullated end communicates with the vestibule and is innervated separately by a branch of vestibular nerve, which passes through *foramen singulare* in the fundus of internal acoustic meatus.

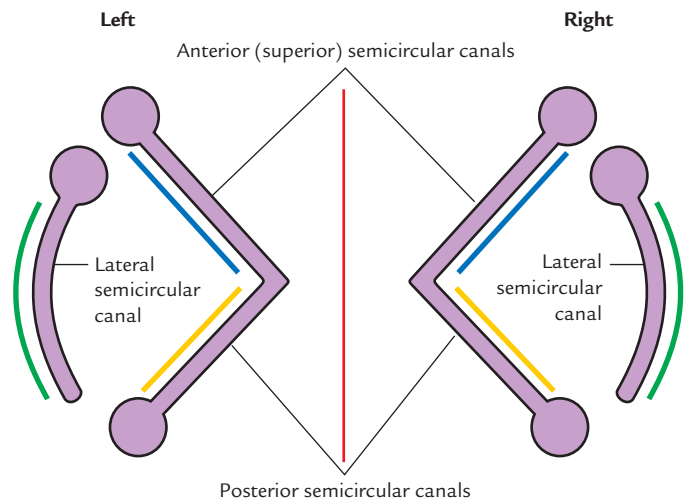


Fig. 18.19 Direction of semicircular canals.

3. The **lateral semicircular canal** lies in the horizontal plane. Its convexity is directed posterolaterally. Its anterolateral end is ampullated and lies close to the ampullated end of the anterior semicircular canal. Both the ends of this canal open directly into the vestibule.

Thus three semicircular canals open in the vestibule by five openings.

N.B.

- The *lateral semicircular canals* of two sides lie in the same plane.
- The *anterior semicircular canal* of one side lies parallel to the *posterior semicircular canal* of the other side.
- The *anterior and posterior semicircular canals*, lying across and along the long axis of the petrous temporal bone, are each at 45° with the sagittal plane.

Golden Facts to Remember

▶ Largest piece of yellow elastic cartilage in the body	Cartilage of the pinna of the external ear
▶ Narrowest part of external auditory meatus	Isthmus (44 mm lateral to tympanic membrane)
▶ All the parts of the ear acquire an almost adult size at birth <i>except</i>	External ear
▶ Safest quadrant of tympanic membrane for surgical incision (myringotomy)	Posterior inferior quadrant
▶ Smallest skeletal muscle in the body	Stapedius
▶ Point of maximum convexity on the medial surface of tympanic membrane	Umbo
▶ Smallest ball and socket joint in the body	Incudostapedial
▶ Smallest saddle joint in the body	Incudomalleolar
▶ All the contents within the middle ear are outside its mucous lining <i>except</i>	Air
▶ Smallest long bone in the body	Malleus
▶ Smallest bone in the body	Stapes
▶ Widest part of the pharyngotympanic tube	Pharyngeal end (1.25 cm behind the inferior nasal concha)
▶ Age at which the fetus can hear conversation between the mother and father	At 20th week of gestation of intrauterine life*
▶ Parts of the ear and related structures, which are of full adult size at birth	Tympanic cavity, ear ossicles, internal ear of mastoid antrum

*This fact probably explains how *Abhimanyu*, who still inside the womb of his mother, could hear conversation between his mother and father (Arjuna), in the legend narrated in the great Indian epic, the *Mahabharata*, written thousands of years ago.

Clinical Case Study



A 10-year-old boy was taken by his mother to an ENT surgeon and complained that her son was suffering from ear ache. On otoscopic examination, the surgeon found that right external acoustic meatus of the boy was full of wax. He told the mother that her son had wax in his right ear and it had to be removed by a minor procedure called syringing, for which she agreed. While syringing, the child started coughing, gagging, and subsequently vomited. The pulse rate of the child decreased.

Questions

1. Which glands in the external auditory meatus secrete wax?
2. Which nerves provide sensory innervation to the external auditory meatus?
3. Mention the anatomical basis of coughing, gagging, vomiting, and decreased pulse rate during syringing of the ear.

Answers

1. Ceruminous glands (modified sweat glands).
2. Auriculotemporal nerve, auricular branch of vagus.
3. Irritation of auricular branch of vagus during syringing may reflexly produce coughing (called ear cough), vomiting and decrease in pulse rate.

Orbit and Eyeball

ORBIT

The orbits are a pair of pyramidal-shaped bony cavities, located one on either side of the root of the nose and provides sockets for rotatory movements of the eyeballs. Each orbit is a four-sided pyramid with apex directed behind at the optic canal and base forward, represented by the orbital margin. The medial walls of two orbits are parallel to each other but the lateral walls are set at right angle to each other (Fig. 19.1).

The long axis of each orbit (**orbital axis**) passes backwards and medially.

BOUNDARIES

The boundaries of the orbit (Fig. 19.2) are as follows:

Medial wall (thinnest): Formed by four bones; from before backwards these are as follows:

1. Frontal process of maxilla.
2. Lacrimal process of maxilla.

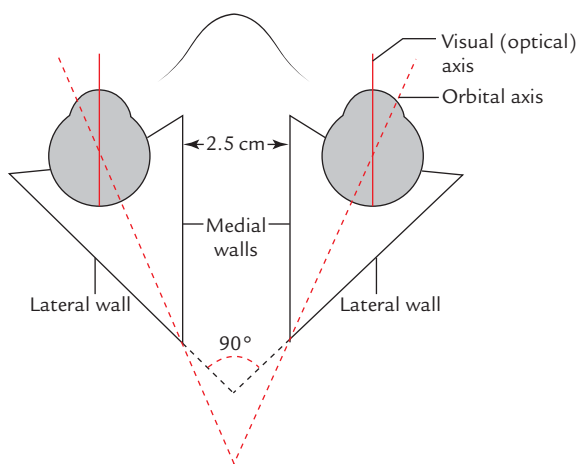


Fig. 19.1 Diagrammatic horizontal section through orbits showing: angle formed between lateral walls, distance between medial walls and their direction (parallel to each other), visual and orbital axes.

3. Orbital plate of ethmoid.
4. Body of sphenoid.

Lateral wall (strongest): Formed by two bones, *viz.*

1. Orbital surface of the zygomatic bone in front.
2. Orbital surface of greater wing of sphenoid behind.

Floor: Formed by three bones:

1. Orbital surface of the body of maxilla.
2. Orbital surface of the zygomatic bone, anterolaterally.
3. Orbital process of the palatine bone, posteromedially.

Roof: Formed by two bones, *viz.*

1. Orbital plate of the frontal bone in front.
2. Lesser wing of the sphenoid behind.

Presenting Features in Four Boundary Walls of Orbit (Fig. 19.3)

Medial wall: Presents two features, *viz.*

1. Lacrimal fossa is bounded in front by the anterior lacrimal crest of maxilla and behind by the posterior lacrimal crest of the lacrimal bone. The lacrimal fossa communicates with the nasal cavity through nasolacrimal canal. The lacrimal fossa and nasolacrimal canal lodge lacrimal sac and nasolacrimal duct, respectively.
2. Anterior and posterior ethmoidal foramina, lie at the junction between medial wall and the roof of the orbit.

Lateral wall: Presents two features, *viz.*

1. Zygomatic foramen. Sometimes there are two small foramina, for zygomaticofacial and zygomaticotemporal nerves.
2. Whitnall's tubercle, a small bony tubercle just behind the lateral orbital margin and slightly below the frontozygomatic suture.

Floor: Presents two features, *viz.*

1. Infraorbital groove and canal.
2. Small rough impression in anteromedial angle for origin of inferior oblique muscle.

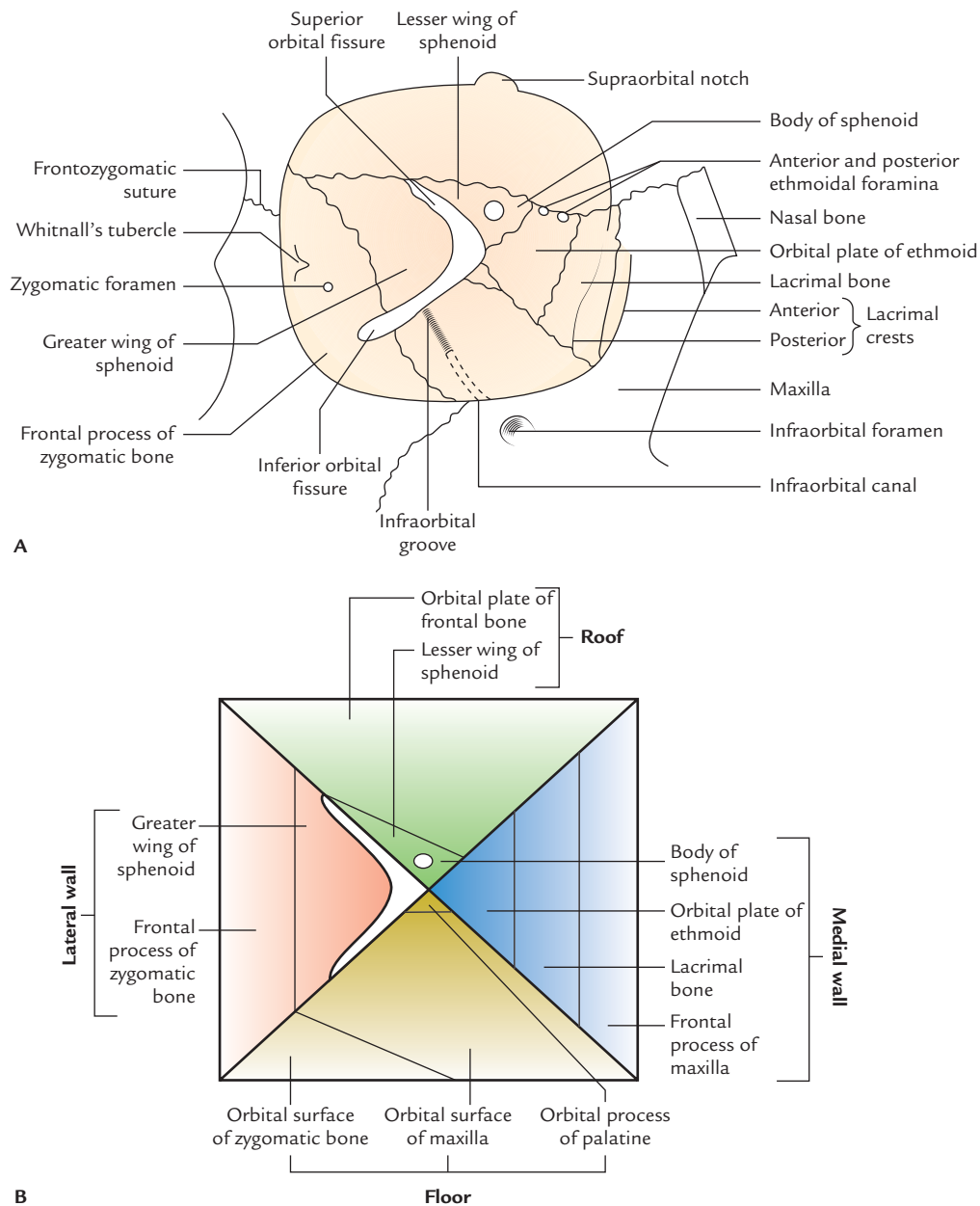


Fig. 19.2 Orbit: A, margins and walls; B, schematic diagram to show the bones forming the walls of the orbit.

Roof: Presents three features, viz.

1. Fossa for lacrimal gland in the anterolateral part.
2. Trochlear notch or spine at the anteromedial angle.
3. Optic canal at the extreme posterior part of the roof.

Apex: Lies at the posterior end of the orbit and is formed by sphenoid. More precisely it is formed by the centre of the bony bridge between optic canal and superior orbital fissure.

Base: Open and quadrangular, its boundaries form the orbital margins.

Orbital Margins

The orbital margins are formed as follows:

1. **Supraorbital margin** is formed by the frontal bone and presents a notch—supraorbital notch or foramen at the junction of its lateral two-third and medial one-third.
2. **Infraorbital margin** is formed by the zygomatic bone laterally and maxilla medially; it is continuous with *anterior lacrimal crest* medially.
3. **Medial orbital margin** is ill-defined. It is formed by the frontal bone above and lacrimal crest of the frontal process of maxilla below.

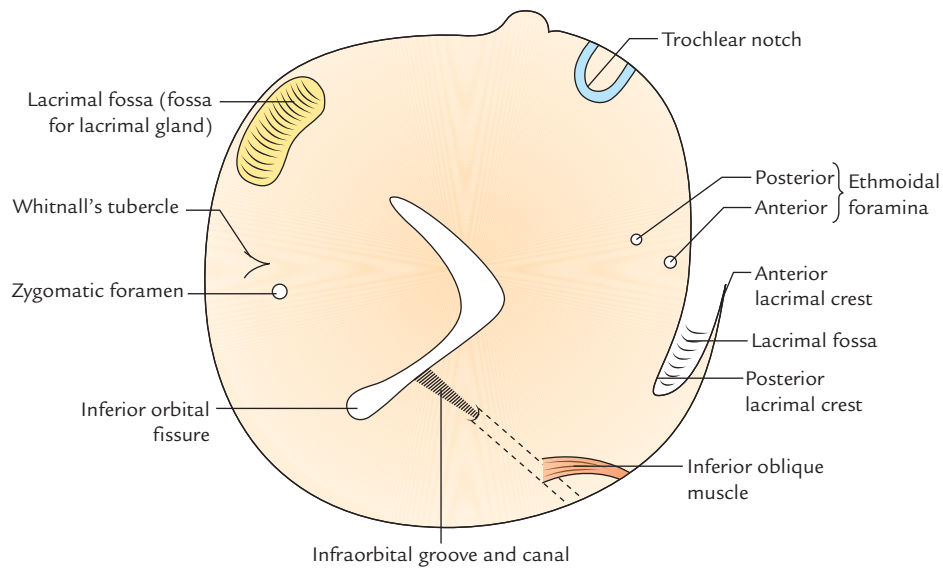


Fig. 19.3 Presenting features in the four boundary walls of the orbit.

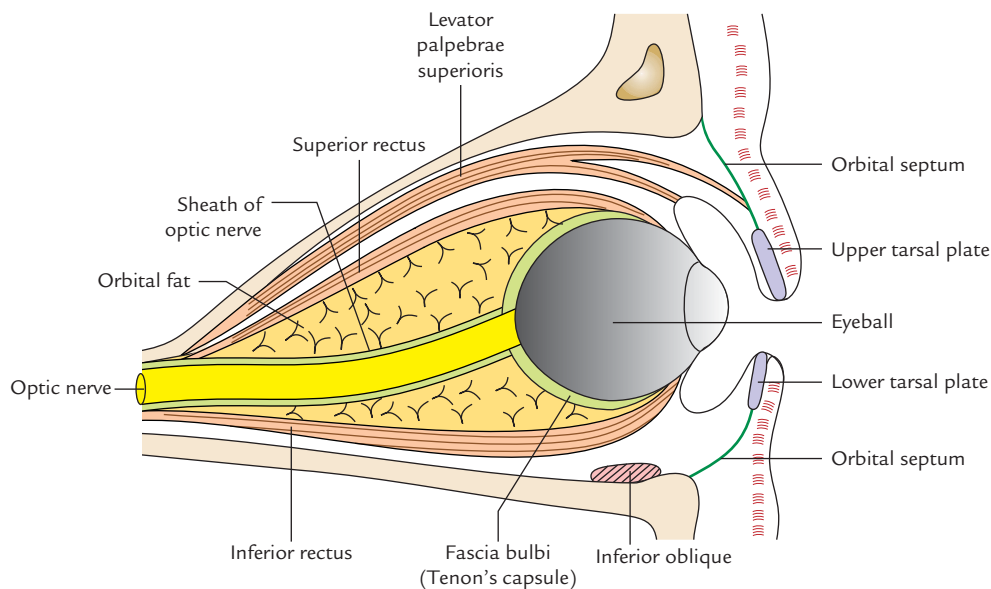


Fig. 19.4 Sagittal section of the orbital cavity showing some of its contents.

- Lateral orbital margin** is formed by zygomatic process of the frontal bone above and frontal process of the zygomatic bone below.

The margins of the orbit are readily palpable in vivo.

N.B. The orbital margins provide a fair bony protection to the eye except at the lateral margin. For this reason protective eye guards are designed to compensate for it, in squash and handball players and still permitting good peripheral vision.

RELATIONS

The relations of orbit are as follows:

Above: Anterior cranial fossa and frontal air sinus (usually).

Lateral: Temporal fossa in front and middle cranial fossa behind.

Below: Maxillary air sinus.

Medial: Ethmoidal air sinuses.

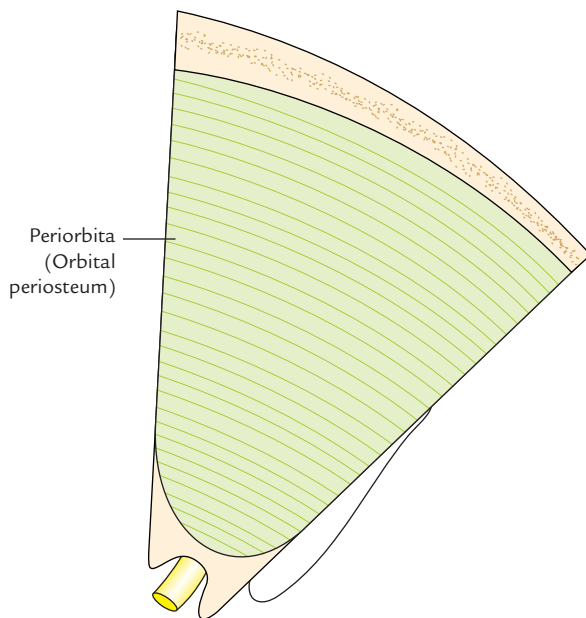


Fig. 19.5 Periorbita.

ORBITAL FASCIA OR PERIORBITA

It is the periosteum of the bony orbit, which lines the bony boundaries of the orbit and forms a funnel-shaped fascial sheath that encloses the orbital contents (Fig. 19.5). It is loosely attached to the bones, hence can be easily stripped off especially from roof and medial wall of the orbit.

At the optic canal and superior orbital fissure, it becomes continuous with the periosteum lining the interior of the skull (*endocranium*). At the infraorbital fissure and orbital margins, it becomes continuous with the periosteum covering the external surface of the skull (*periosteum*).

CONTENTS

Contents of the orbit includes the following structures (Fig. 19.4):

1. Eyeball (most important content).
2. Muscles.
3. Fascia bulbi.
4. Nerves
 - (a) Optic
 - (b) Oculomotor
 - (c) Trochlear
 - (d) Abducent
 - (e) Ophthalmic
 - (f) Ciliary ganglion.
5. Ophthalmic artery.
6. Ophthalmic veins.
7. Lacrimal gland.
8. Orbital fat.

All these structures lie within the orbital periosteum that lines the bony walls of the orbit.

N.B. Infraorbital nerve and vessels and zygomatic nerve lie outside the orbital periosteum, hence not included in the contents of the orbit.

EXTRAOCULAR MUSCLES

The extraocular muscles are classified into two groups: voluntary and involuntary.

VOLUNTARY MUSCLES

There are seven voluntary muscles in the orbit. Of these, six muscles move the eyeball and one muscle moves the upper eyelid.

The muscles moving the eyeball are four recti and two oblique muscles. The one which moves the upper eyelid is called *levator palpebrae superioris* (Fig. 19.6):

1. **Four recti muscles**
 - (a) Superior rectus,
 - (b) Inferior rectus,
 - (c) Medial rectus, and
 - (d) Lateral rectus.
2. **Two oblique muscles**
 - (a) Superior oblique,
 - (b) Inferior oblique.
3. **One levator palpebrae superioris.**

INVOLUNTARY MUSCLES

There are three involuntary/smooth muscles, viz. **superior tarsal or Muller's muscle, inferior tarsal and orbitalis.**

The voluntary muscles are described in detail because of their functional significance in the following text:

Recti muscles

Origin: All the recti arise from the corresponding margins of the common tendinous ring. The lateral rectus arises by two heads.

The common tendinous ring encloses the optic canal and middle part of the superior orbital fissure. It is attached medially to apex of the orbit and laterally to a small tubercle (tubercle of Zinn) on the lower border of superior orbital fissure.

Insertion: All the recti are inserted into sclera little posterior to the limbus (corneoscleral junction) in front of the equator of the eyeball. Average distance from limbus is:

Medial rectus, 5 mm

Inferior rectus, 6 mm

Lateral rectus, 7 mm

Superior rectus, 8 mm

The origin and insertion of recti muscles are shown in Figure 19.6.

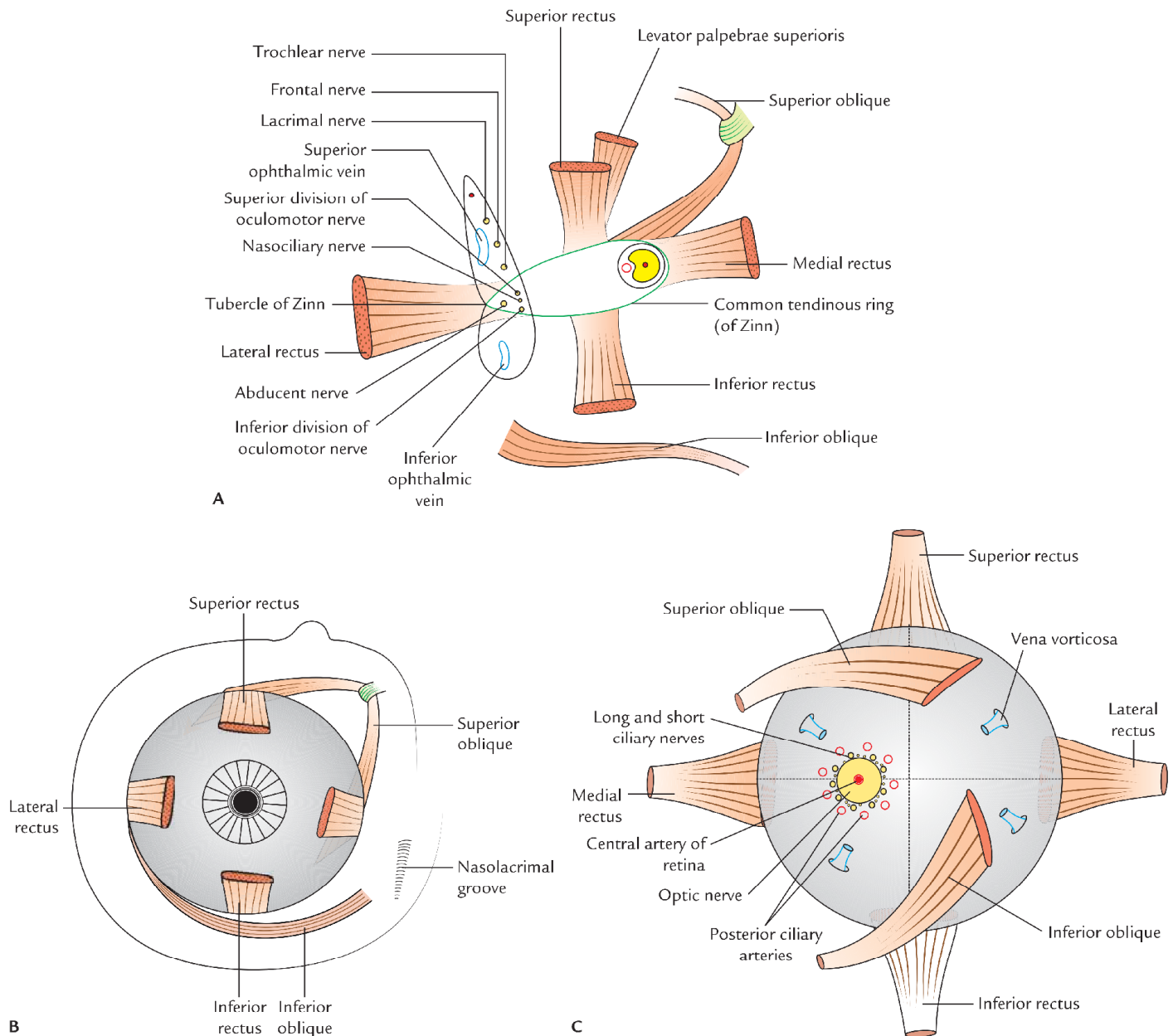


Fig. 19.6 Extraocular muscles: A, origin; B, insertion of the recti muscles; C, insertion of the oblique muscles.

Oblique muscles

The oblique muscles of the orbit are superior and inferior. Their origin and insertion (Fig. 19.6) are as follows:

1. Superior oblique

Origin: from body of sphenoid superomedial to the optic canal.

Insertion: into sclera behind the equator in posterior superior quadrant of the eyeball, between the superior rectus and lateral rectus. The tendon of superior oblique passes through a fibrocartilaginous pulley attached to the trochlear notch in the anterolateral part of the roof of the orbit.

2. Inferior oblique

Origin: from rough impression in the anteromedial angle of the floor of orbit, lateral to the lacrimal groove.

Insertion: into sclera behind the equator in the postero-superior quadrant of the eyeball a little below and posterior to the insertion of superior oblique.

Nerve supply (Fig. 19.7): all the extraocular muscles that move the eyeball are supplied by the oculomotor nerve (CN3) except lateral rectus and superior oblique, which are supplied by the abducent nerve (CN6) and trochlear nerve, respectively [*mnemonic: LR6, SO4, i.e., LR (lateral rectus) by 6 CN and SO (superior oblique) by 4 CN*].

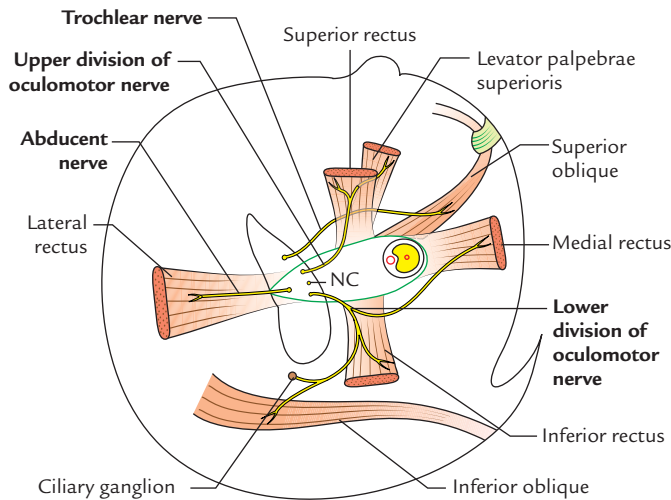


Fig. 19.7 Nerve supply of the extraocular muscles (NC = nasociliary nerve).

ACTIONS OF MUSCLES ON THE EYEBALL

The two eyes face forwards and their long axes (visual optic axes) lie in sagittal plane, parallel with each other and with medial walls of the orbits (Fig. 19.1). The lateral walls of orbits slope backwards and medially making a right (90°) angle with each other. The ocular muscles and optic nerve come from the apex of the orbit near the back of the medial wall and pass forwards and laterally to be attached to the eyeball. The actions of superior and inferior recti are, therefore, not straight, despite their name. The superior and inferior oblique muscles, therefore, have to act in concert with two recti in order to produce direct upward and downward movements of the eyeball.

Axis of Movements of the Eyeball

- **Elevation and depression:** around the transverse axis passing through the equator.
- **Adduction and abduction:** around the vertical axis passing through the equator.
- **Rotation (torsion):** around the anteroposterior axis extending from anterior pole to posterior pole of the eyeball.

When 12 o'clock position of the cornea rotates medially, it is called *intorsion* and when it rotates laterally, it called *extorsion*.

Actions of Individual Muscles

The actions of individual muscles are easily deduced from Starling's diagram (Fig. 19.8).

They are as follows:

Superior rectus (SR): elevation, adduction, and intorsion.

Medial rectus (MR): adduction.

Inferior rectus (IR): depression, adduction, and extorsion.

Lateral rectus (LR): abduction.

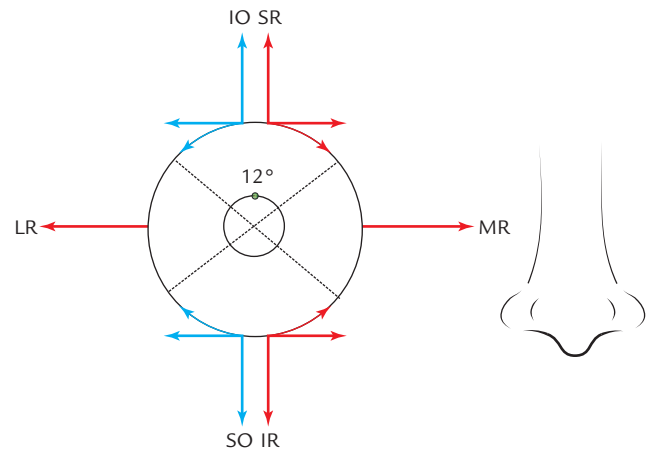


Fig. 19.8 Schematic diagram (modified after Starling) showing actions of various extraocular muscles (IO = inferior oblique, IR = inferior rectus, LR = lateral rectus, MR = medial rectus, SR = superior rectus, SO = superior oblique).

Superior oblique (SO): depression, abduction, and intorsion.
Inferior oblique (IO): elevation, abduction, and extorsion.

Associated Movements of the Eyeball

1. **Conjugate movements:** when both the eyes move in the same direction with visual axes being parallel.
2. **Disconjugate movements:** when the axes of both eyes converge or diverge.

Clinical correlation

Strabismus/squint: Unilateral paralysis of an individual muscle due to involvement of the nerves produces strabismus or squint (deviation of eye to the opposite side) and may result in diplopia (double vision). In diplopia, the light from an object is not focused on the identical areas of both retinæ. The real image falls on the macula of the unaffected eye and false image falls on the peripheral part of retina of the paralyzed eye. The examples are as under:

Muscle paralyzed	Nerve involved	Effects
Lateral rectus	Abducent	Medial squint
Medial rectus	Oculomotor	Lateral squint

Levator palpebrae superioris (LPS) muscle

Origin: from undersurface of the lesser wing of sphenoid at the apex of the orbit, above the common tendinous ring by a narrow tendon.

Insertion (Fig. 3.22): the muscle broadens as it passes forwards from its origin and divides into three lamellæ:

1. Upper lamella consisting of skeletal muscle penetrates the orbital septum passes through the fibres of orbicularis oculi to be inserted into the skin of upper eyelid.

- Intermediate lamella consisting of smooth muscle (superior tarsal muscle) is inserted on to the upper border of the superior tarsal plate.
- Lower lamella consisting of connective tissue is inserted on to the superior fornix of the conjunctiva.

Nerve supply

- Striped (skeletal muscle) part is supplied by the upper division of oculomotor nerve.
- Unstriped (smooth muscle) part is supplied by the post-ganglionic sympathetic fibres from the superior cervical ganglion.

Actions: Elevation of the upper eyelid to open the eye.

Clinical correlation

Paralysis of levator palpebrae superioris: Paralysis of levator palpebrae superioris due to involvement of the oculomotor nerve leads to *complete ptosis* (drooping of upper eyelid). The lesion of cervical sympathetic chain (as in Horner's syndrome) leads to *partial ptosis* (partial drooping of upper eyelid) as it affects only smooth muscle part of LPS.

FASCIA BULBI OR FASCIAL SHEATH OF THE EYEBALL

The fascia bulbi (**Tenon's capsule**) is a loose membranous sheath that envelops the eyeball and extends from optic nerve to the sclerocorneal junction. It is separated from the sclera by the episcleral space. The Tenon's capsule forms a socket for the eyeball to facilitate free ocular movements. It separates the eyeball from orbital fat (Fig. 19.9).

The fascia bulbi is pierced by:

- tendons of four recti and two oblique muscles of the eyeball, and

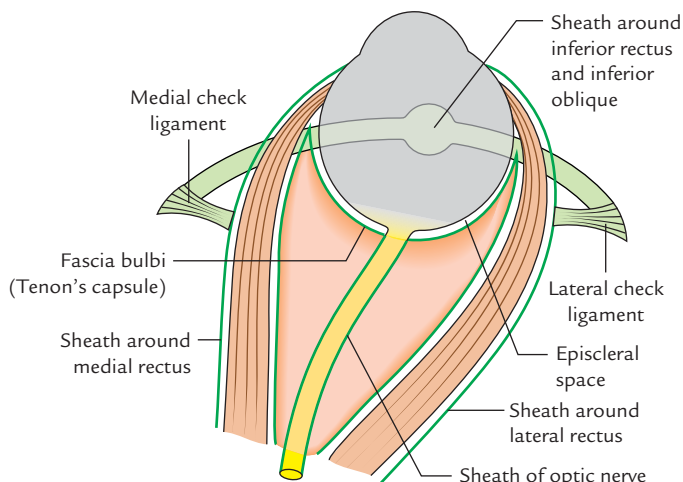


Fig. 19.9 Fascia bulbi (Tenon's capsule).

- ciliary nerves and vessels around the entrance of the optic nerve.

SUSPENSORY AND CHECK LIGAMENTS OF THE EYE

The fascia bulbi provides a tubular sleeve around each muscle that pierces it. From the fascial sleeve of lateral rectus, a triangular expansion (**lateral check ligament**) extends laterally for attachment to the lateral wall of the orbit on Whitnall's tubercle. Similarly, a triangular expansion from sleeve of medial rectus (**medial check ligament**) extends medially for attachment to the medial wall of the orbit on posterior lacrimal crest of the lacrimal bone.

The fascial sleeve of inferior rectus thickens on its underside and blends with the sleeve of inferior oblique as well as with the medial and lateral check ligaments forming a hammock-like support for the eyeball. It is called as **suspensory ligament of the eye (or suspensory ligament of Lockwood)**. It is expanded in the centre and narrows at its extremities. At the posterior pole of the eyeball the fascia bulbi becomes continuous with sheath of the optic nerve (Fig. 19.10).

Clinical correlation

- If suspensory ligament of the eye remains intact when the floor of the orbit is fractured or the maxilla is removed surgically, the eyeball does not sag.
- During enucleation of the eye, if Tenon's fascia is not damaged, and artificial eye is planted subsequently within the socket of Tenon's capsule it is able to move.

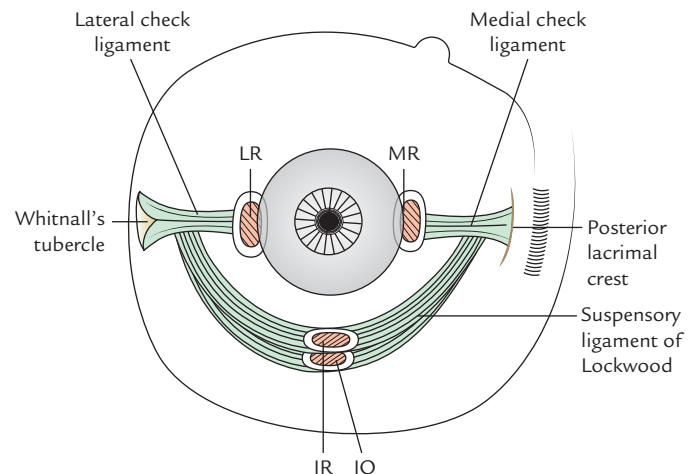


Fig. 19.10 Suspensory and check ligaments of the eye (IO = inferior oblique, IR = inferior rectus, LR = lateral rectus, MR = medial rectus).

NERVES OF THE ORBIT

Optic Nerve

It has been described in detail in Chapter 22. Therefore only brief account is presented here.

This nerve of sight is 4 cm long. It is made up of about 1 million myelinated nerve fibres. The optic nerve emerges from the eyeball, 3 or 4 mm nasal to the posterior pole of the eyeball. It runs backwards and medially, passes through the optic canal to enter the cranial cavity where it joins the optic chiasma. The entire nerve is enclosed in three meningeal sheaths derived from the meninges of the brain. The subarachnoid space around the brain, therefore, extends around the nerve up to the eyeball.

Relations

The central artery and vein of the retina pierce the optic nerve inferomedially about 1.25 cm behind the eyeball. The optic nerve is crossed superiorly from before backward by:

- superior ophthalmic vein,
- ophthalmic artery, and
- nasociliary nerve.

Mnemonic: VAN

Oculomotor Nerve (Fig. 19.11)

The two divisions of oculomotor nerve enter the orbit through superior orbital fissure within the common tendinous ring. Here the nasociliary nerve lies between the two divisions.

The **smaller superior division** runs forwards above the optic nerve and supplies the *superior rectus*, then pierces it to supply the *levator palpebrae superioris*.

The **larger inferior division** passes below the optic nerve and divides into three branches to supply *medial rectus*, *inferior rectus*, and *inferior oblique*.

The nerve to inferior oblique gives off the parasympathetic motor root to the ciliary ganglion.

Trochlear Nerve (Fig. 19.12)

The trochlear nerve enters the orbit through the superior orbital fissure superolateral to the common tendinous ring and curves medially above the levator palpebrae superioris to reach deep to the posterior part of superior oblique, which it supplies.

Abducent Nerve (Fig. 19.13)

The abducent nerve enters the orbit through superior orbital fissure within the common tendinous ring lateral to two divisions of the oculomotor nerve and nasociliary nerve, turns laterally away from optic nerve to enter the posterior part of lateral rectus.

Ophthalmic Nerve (Fig. 19.14)

The ophthalmic nerve is the first and the smallest of the three divisions of trigeminal nerve. It is purely sensory.

Course and relations

It arises from medial part of the convex anterior border of the trigeminal ganglion. It pierces the dura mater of the trigeminal cave and enters into the lateral wall of the cavernous sinus where it lies below the trochlear nerve. It enters the orbit through superior orbital fissure by dividing into three branches: lacrimal, frontal, and nasociliary.

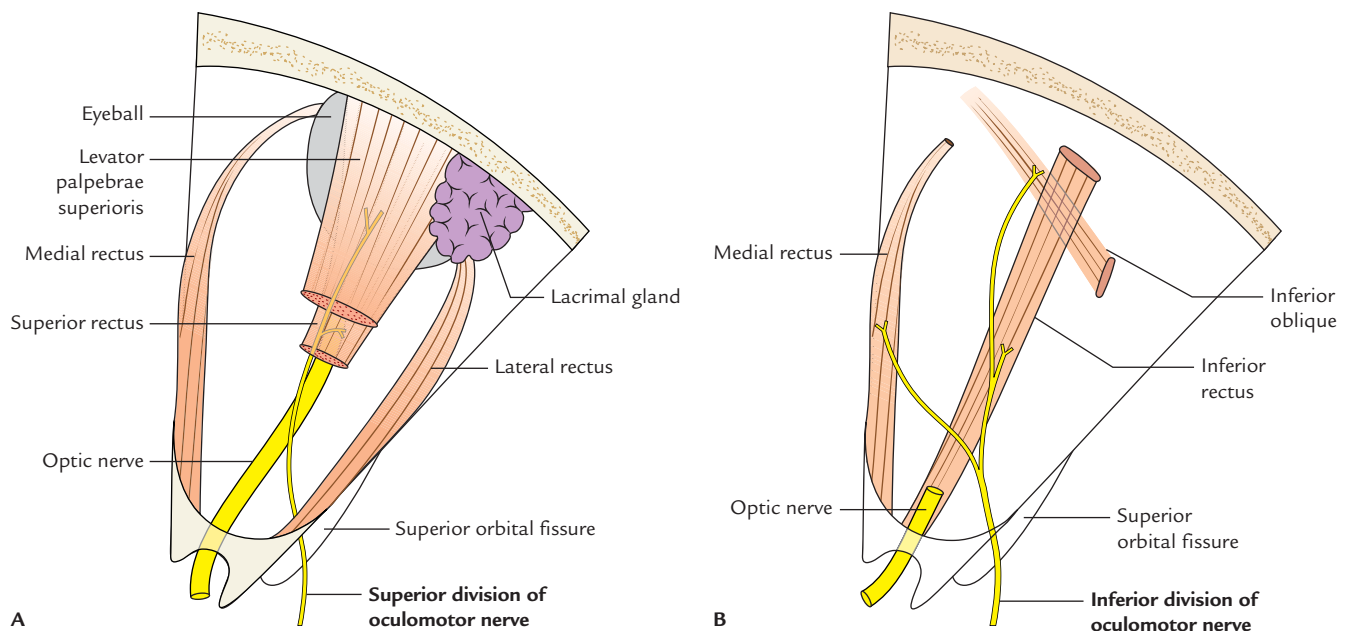


Fig. 19.11 Course and distribution of two divisions of the oculomotor nerves in the orbit: A, superior division; B, inferior division.

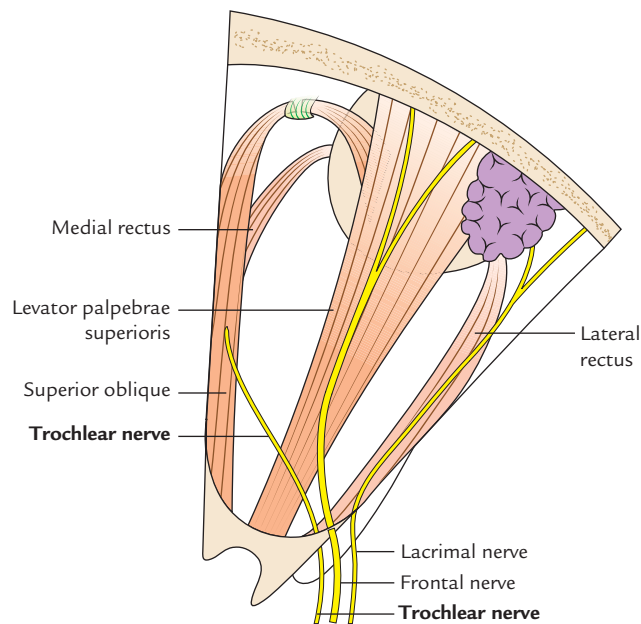


Fig. 19.12 Course and distribution of the trochlear nerve in the orbit. Also note the course of frontal and lacrimal nerves.

Branches and distribution

- Lacrimal nerve (smallest branch)** runs along the lateral wall of the orbit along with lacrimal artery and ends in the lacrimal gland (hence its name). It is joined by a communicating twig from the zygomaticotemporal branch of the maxillary nerve carrying postganglionic secretomotor fibres to the lacrimal gland. The lacrimal nerve supplies lacrimal gland and conjunctiva. Then it pierces orbital septum to supply the lateral part of the skin of upper eyelid.
- Frontal nerve (largest branch)** runs forwards between levator palpebrae superioris and periosteum lining the roof of the orbit. In the middle of orbit, it divides into large supraorbital and small supratrochlear nerves:
 - Supraorbital nerve** continues in the line of the frontal nerve to pass through supraorbital notch, where it turns upwards into the forehead and divides into medial and lateral branches, which supply the scalp as far back as the vertex.
 - Supratrochlear nerve** runs forwards medial to the supraorbital nerve. It passes above the trochlea for tendon of superior oblique muscle and then turns upwards along the superior orbital margin and supplies the skin of the lower part of the forehead.
- Nasociliary nerve** runs forwards and medially, crossing the optic nerve from above and from lateral to medial side behind the ophthalmic artery. On reaching the medial wall of the orbit, it ends by dividing into anterior ethmoidal and infratrochlear nerves.

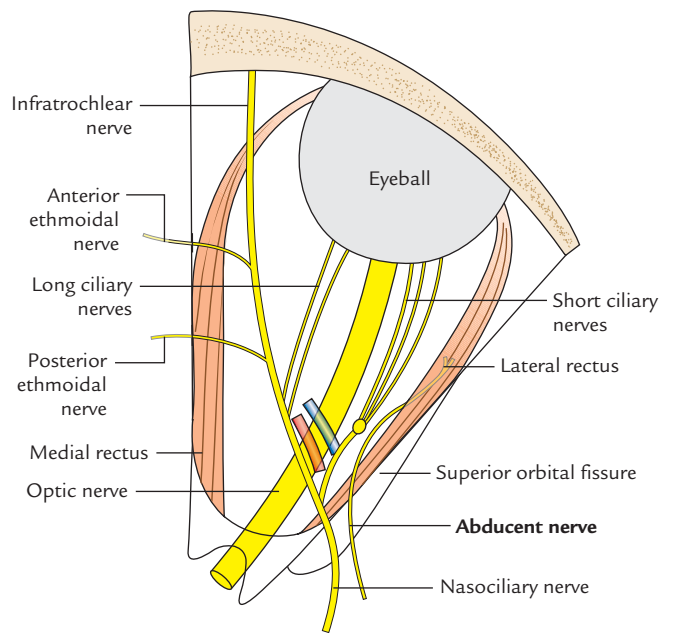


Fig. 19.13 Course and distribution of the abducent nerve in the orbit. Also note the course and branches of the nasociliary nerve.

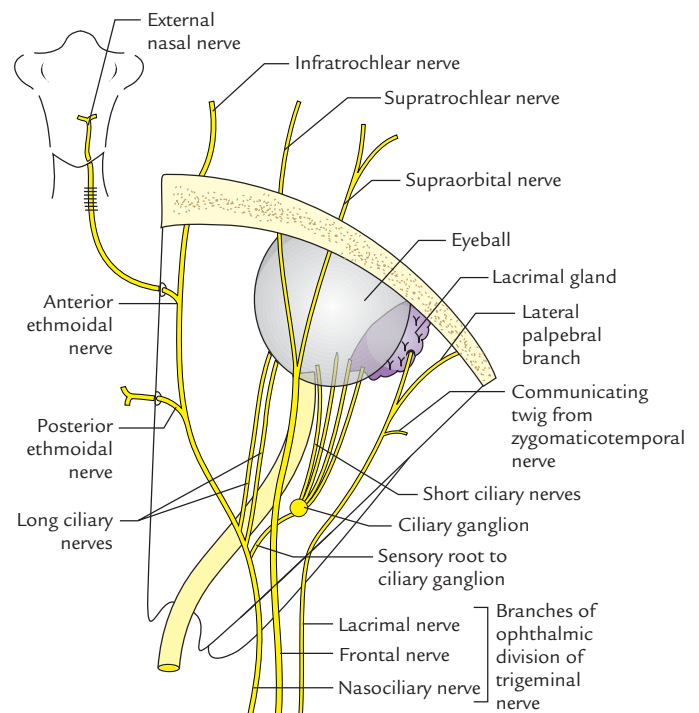


Fig. 19.14 Branches and distribution of the ophthalmic nerve.

It gives the following branches:

- Sensory root to the ciliary ganglion** is given just before crossing the optic nerve.
- Long ciliary nerves**, 2 or 3, arise from nasociliary nerve as it crosses the optic nerve. They pass forward, enter the

eyeball, and supply sensory fibres to the ciliary body, iris, and cornea.

The long ciliary nerves also carry some postganglionic sympathetic fibres to the dilator pupillae.

- (c) **Posterior ethmoidal nerve** enters the posterior ethmoidal foramen and supplies the ethmoidal and sphenoidal air sinuses.
- (d) **Anterior ethmoidal nerve** enters the anterior ethmoidal foramen and then passes through anterior ethmoidal canal to reach the anterior cranial fossa. Now it runs forwards over the cribriform plate of ethmoid and enters the nasal cavity by passing through a nasal slit at the side of crista galli. In the nasal cavity, the nerve lies in the groove on the posterior surface of the nasal bone and gives internal nasal branches to the nasal septum and lateral wall of the nose. At the lower border of the nasal bone, the nerve leaves the nasal cavity and appears on the dorsum of nose as *external nasal nerve*.
- (e) **Infratrochlear nerve** runs forwards on the medial wall of the orbit just below the trochlea and ends by supplying the skin of upper eyelid.

Ciliary Ganglion (Fig. 19.15)

It is a peripheral parasympathetic ganglion, connected with the nasociliary nerve. Although topographically it is connected to the nasociliary nerve from ophthalmic division of the trigeminal, but functionally it is connected to the oculomotor nerve.

Location

It is a minute body (2 mm in diameter) lying near the apex of orbit between the optic nerve and lateral rectus muscle.

Roots

Three roots enter its posterior end. These are as follows:

1. **Motor (parasympathetic) root:** It is derived from nerve to inferior oblique and consists of preganglionic parasympathetic fibres from Edinger–Westphal nucleus. These fibres relay in the ganglion. The postganglionic parasympathetic fibres arise from the cells of the ganglion and pass through short ciliary nerves to supply the ciliary muscle and sphincter pupillae.
2. **Sensory root:** It is derived from nasociliary nerve. It consists of sensory fibres (for pain, touch, and temperature) from eyeball, which pass through the ciliary ganglion without relay.
3. **Sympathetic root:** It is derived from sympathetic plexus around internal carotid artery. It consists of post-ganglionic sympathetic fibres from superior cervical sympathetic ganglion. The fibres pass through the ganglion without relay and further pass through short ciliary nerves to supply the dilator pupillae and blood vessels of the eyeball.

Branches

The branches of ciliary ganglion are **short ciliary nerves** (8–10). They contain fibres from all the three roots, run above and below the optic nerve towards the eyeball. On reaching the eyeball they pierce the sclera around the attachment of

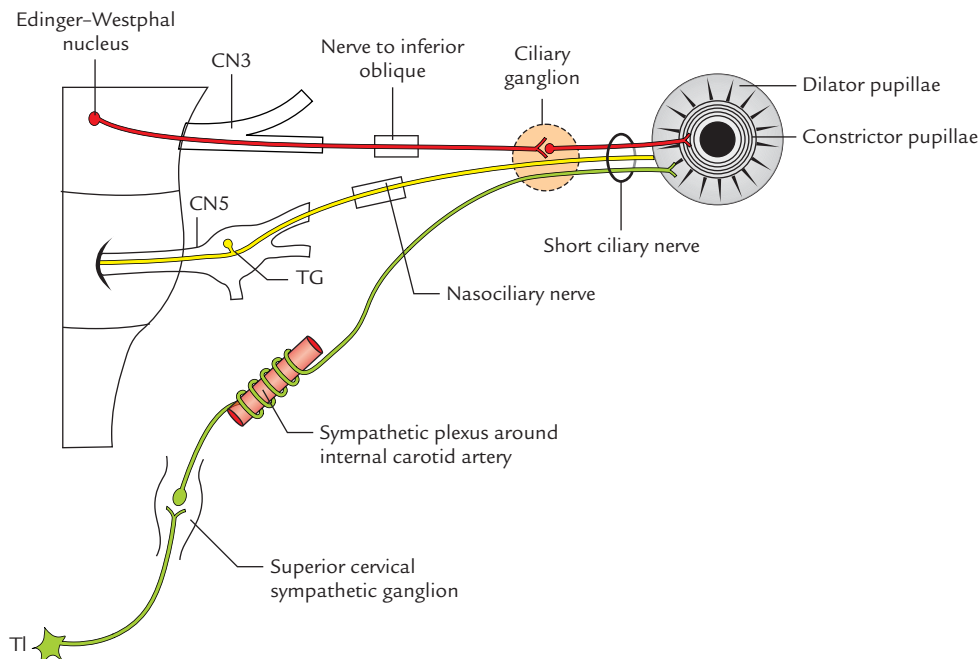


Fig. 19.15 Roots and distribution of the ciliary ganglion.

the optic nerve and pass forwards in the space between the sclera and choroid to reach the target organs.

Clinical correlation

The ciliary ganglion is blocked to produce dilatation of pupil before cataract extraction.

Infraorbital and Zygomatic Nerves (Fig. 19.16)

They lie outside the periosteum of the orbit. They are described in detail in Chapter 10.

OPHTHALMIC ARTERY

It is branch of the internal carotid artery. It arises from internal carotid artery as it emerges from the roof of the cavernous sinus medial to anterior clinoid process close to the optic canal. The artery enters the orbit through optic canal inferolateral to the optic nerve, both lying in a common dural sheath (Fig. 19.17).

The artery pierces the dura mater, ascends over the lateral side of the optic nerve to cross it superiorly from lateral to medial side along with the nasociliary nerve. It then runs forwards along the medial wall of the orbit tortuously to allow the movements of the eyeball. Near the medial angle of the eye it terminates by dividing into two branches: **supratrochlear** and **dorsal nasal**.

Branches

The branches of the ophthalmic artery are as follows:

1. **Central artery of the retina** (first and most important) arises from ophthalmic artery (still in dural sheath) below the optic nerve, runs forwards in the dural sheath

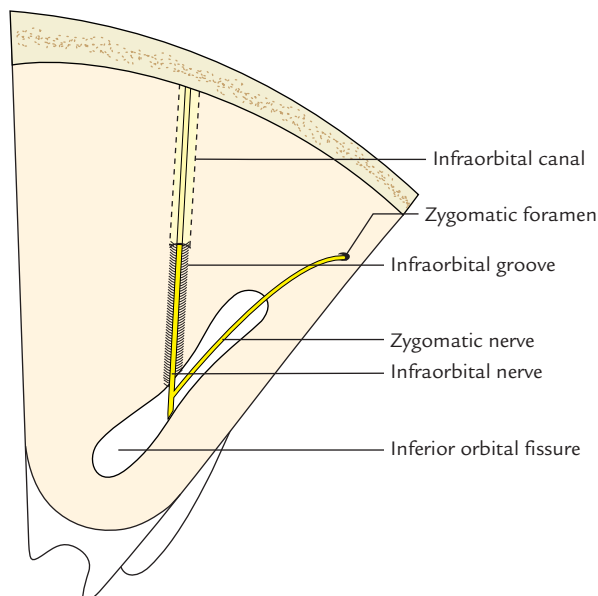


Fig. 19.16 Infraorbital and zygomatic nerves.

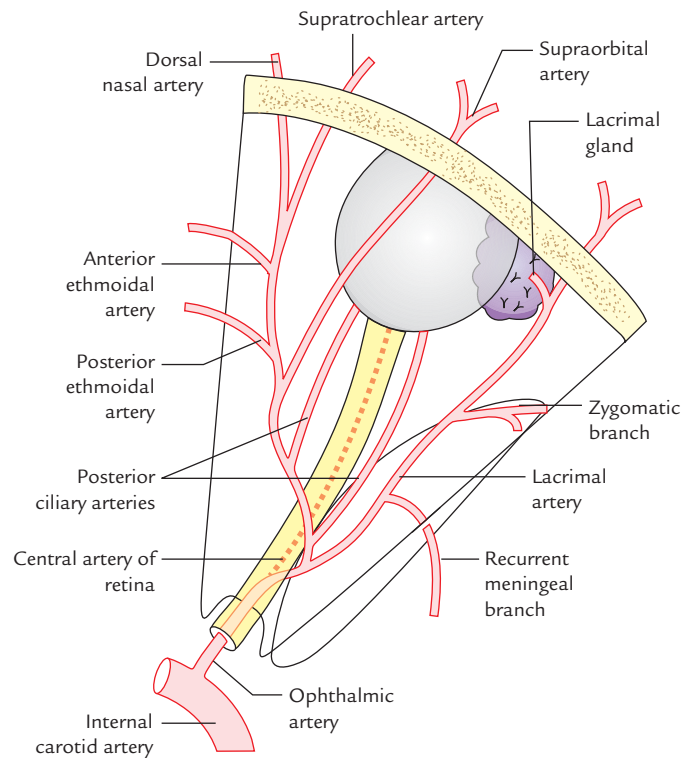


Fig. 19.17 Ophthalmic artery.

and pierces the optic nerve inferomedially about 1.25 cm behind the eyeball. The central artery reaches the optic disc through the central part of the nerve. It supplies the optic nerve and inner 6/7 layers of the retina.

Clinical correlation

The central artery of retina is an example of a typical end artery. Its damage produces sudden total blindness on the side of the lesion.

2. **Lacrimal artery** arises from ophthalmic artery just before it crosses the optic nerve. It passes forwards along the upper border of lateral rectus and supplies the lacrimal gland, eyelids, and conjunctiva. The lacrimal artery gives off the following branches:
 - (a) Glandular branches to lacrimal gland.
 - (b) Two lateral palpebral arteries—one to each eyelid.
 - (c) Two zygomatic branches: zygomaticofacial and zygomaticotemporal.
 - (d) Recurrent meningeal branch runs backwards to enter the middle cranial fossa through the superior orbital fissure.
 - (e) Muscular branches.
3. **Posterior ciliary arteries** consist of two sets: long and short, both of which pierce the sclera of the eyeball around the optic nerve and chiefly supply the choroid and sclera. Long ciliary arteries are usually two and short

ciliary arteries are usually seven in number. (Remember that *anterior ciliary arteries* arise from muscular arteries.)

4. **Supraorbital artery** accompanies the supraorbital nerve. It passes through supraorbital notch to enter the scalp and divides into medial and lateral branches.
5. **Posterior ethmoidal artery** enters the posterior ethmoidal foramen in the medial wall of the orbit and supplies the ethmoidal air sinuses, nasal cavity, and dura mater.
6. **Anterior ethmoidal artery** enters the anterior ethmoidal foramen in the medial wall of the orbit and supplies the ethmoidal air sinuses, medial and lateral wall of nasal cavity, and dura mater.
7. **Dorsal (external) nasal artery** supplies the lower part of the dorsum of nose.
8. **Supratrochlear artery** accompanies the supratrochlear nerve to supply the forehead.
9. **Medial palpebral branches**, one to each eyelid, anastomose with the corresponding lateral palpebral branches of the lacrimal artery.

N.B. Branches of ophthalmic artery accompany all the branches of nasociliary frontal and lacrimal nerves (derived from ophthalmic nerve), and within the orbit supply all the extraocular muscles, lacrimal gland, and the eyeball.

OPHTHALMIC VEINS

The ophthalmic veins drain the orbit and receive tributaries, which correspond to the branches of the ophthalmic artery (Fig. 19.18). The ophthalmic veins are as follows:

1. **Superior ophthalmic vein:** It is a large vein and accompanies the ophthalmic artery. It commences above the medial palpebral ligament and runs backwards above the optic nerve along with the ophthalmic artery, passes through the superior orbital fissure to drain into cavernous sinus.

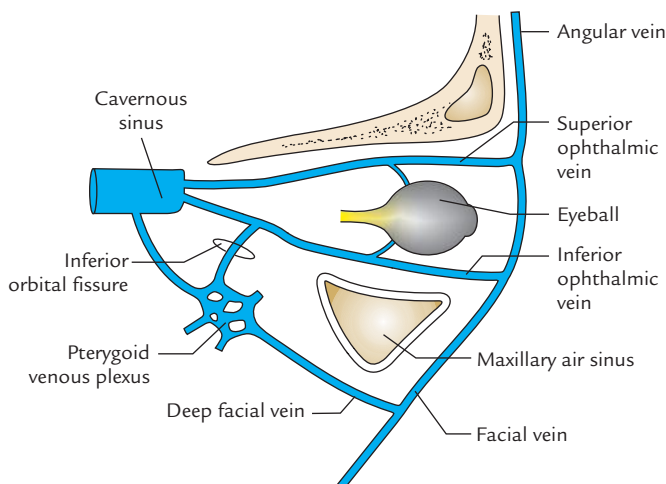


Fig. 19.18 Ophthalmic veins.

It communicates anteriorly at its commencement with the supraorbital and angular veins.

2. **Inferior ophthalmic vein:** It runs below the optic nerve and ends either by joining the superior ophthalmic vein or drain directly into the cavernous sinus.

It communicates with pterygoid venous plexus by small veins passing through the inferior orbital fissure.

N.B. There are no lymphatics in the eyeball.

Clinical correlation

Because the ophthalmic veins drain into cavernous sinus and communicate with the extracranial veins, they act as routes through which infection can spread from outside to inside the cranial cavity.

LACRIMAL GLAND

It is a tubulo-acinar type of exocrine gland, which secretes watery lacrimal fluid. It consists of two parts: orbital and palpebral. The orbital part is located in the lacrimal fossa on the anterolateral part of the roof of the orbit, while palpebral part is located in lateral part of the upper eyelid. Lacrimal gland has already been described in detail in Chapter 3.

ORBITAL FAT

It fills up the space between the eyeball, optic nerve, and cone of four rectus muscles. It serves as a cushion to stabilize the eyeball during its movements.

EYEBALL (BULBUS OCULI)

The eyeball (*L. oculus*; Gk. *ophthalmos*) or globe of the eye is an organ of sight and closely resembles a camera in its structure. It has light-sensitive retina and is provided with a lens system (cornea, lens, and refractive media) for focusing images and device for controlling the amount of light admitted (the iris diaphragm). Further, like a camera, its inside is black to prevent reflection of light (Fig. 19.19).

The eyeball is a highly durable structure for its wall enclosing the refractory media, is made up of three coats, and the fluid filled within it distributes hydraulic pressure uniformly to maintain its shape.

Location

The eyeball occupies the anterior one-third of the orbital cavity and is embedded in the fat. It is enclosed in the thin fibrous sheath (Tenon's fascia), which separates the eyeball from the fat. The optic nerve emerges from it, a little medial to its posterior pole.

Shape and Size

It is almost spherical in shape and has a diameter of about 24 mm.

TUNICS OF THE EYEBALL

The eyeball consists of three concentric coats (Fig. 19.19), *viz.*

1. An outer fibrous coat consisting of sclera and cornea.
2. A middle vascular coat consisting of choroid, ciliary body, and iris.
3. An inner nervous coat consisting of the retina.

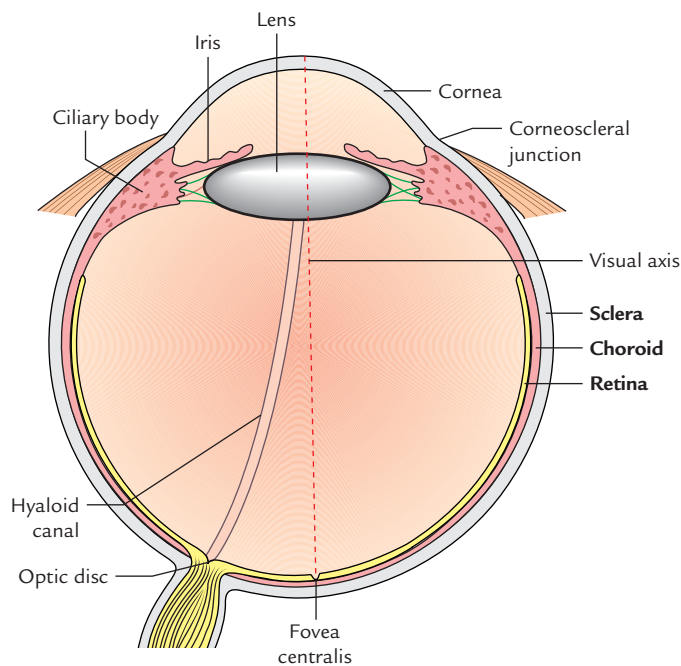


Fig. 19.19 Horizontal section of the eyeball showing its internal structure including three coats and visual axis.

OUTER FIBROUS COAT OF THE EYEBALL

Sclera

The sclera is the posterior five-sixth of the outer coat. It consists of dense fibrous tissue. It is opaque and a small portion of it is seen as the **white of the eye** in the palpebral fissure. The sclera is continuous anteriorly with the cornea. The junction between the sclera and cornea is termed **corneoscleral junction**. Just behind the corneoscleral junction, within the sclera is a circularly running canal called **sinus venosus sclerae (canal of Schlemm)**. Posterior to the canal is a triangular projection—the **scleral spur**—which points forwards and inwards and provides attachment to the ciliary muscle (Fig. 19.20). It is thinnest at the equator and thickest at the back but weakest at the site of emergence of optic nerve.

Functions

1. Helps to maintain the shape of the eyeball.
2. Protects internal structures.
3. Provides attachment to muscles that move the eyeball.

Structure Piercing the Sclera

1. **Optic nerve** pierces the sclera, a little inferomedial to the posterior pole of the eyeball. The perforating fibres of nerve make the area sieve-like (hence called *lamina cribrosa*).
2. **Posterior ciliary vessels and nerves** around the optic nerve.
3. **Anterior ciliary arteries** pierce the sclera close to corneoscleral junction.
4. **Four choroidal veins** (also called *venae vorticosae*) pierce the sclera, just behind the equator.

Cornea

The cornea is the anterior one-sixth of the outer coat. It bulges forwards from the sclera at the *corneoscleral junction* called

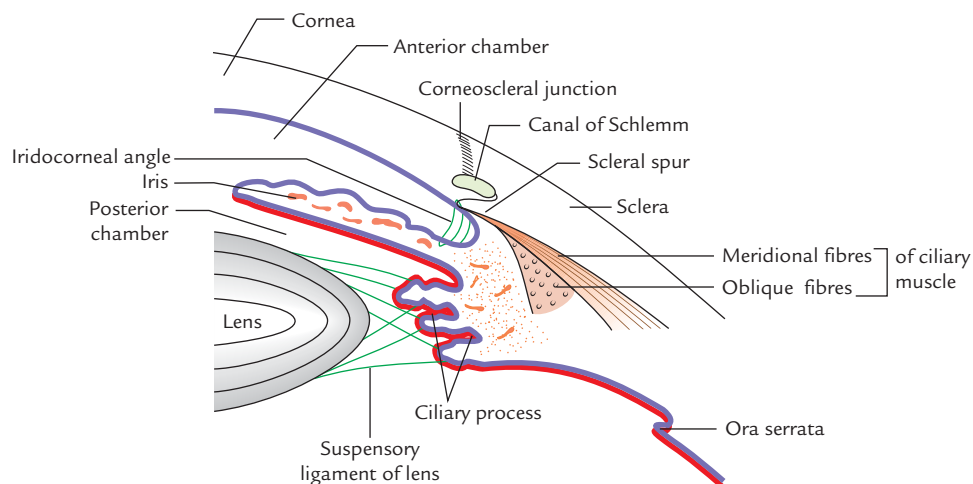


Fig. 19.20 Meridional section of the eyeball showing ciliary region and the iridocorneal angle.

limbus. It is transparent and more convex than sclera because it represents the segment of a smaller sphere. Its thickness is about 1 mm at the periphery and 0.5 mm at the centre.

Features

1. It is avascular and nourished by permeation of nutrients from loops of capillaries at the limbus, aqueous humour, and lacrimal fluid.
2. It not only permits the light to enter the eye but also reflects the entering light.
3. It is highly sensitive and supplied by the ophthalmic division of trigeminal nerve.
4. The nerves of cornea form the afferent limb of the corneal reflex (closure of the eyelids on stimulation of the cornea).

Structure

It consists of five layers, from outside inwards these are as follows (Fig. 19.21):

1. **Corneal epithelium:** It consists of non-keratinized stratified squamous epithelium.
2. **Anterior limiting membrane (or Bowman's membrane):** It is made up structureless homogeneous mass without any elastic fibres.
3. **Substantia propria (corneal stroma):** It is made up of about 200–250 lamellae of fine collagen fibres, which cross each other at right angles to form corneal spaces.
Flattened fibroblasts are located between the lamellae.
The transparency of cornea is due to precise lattice arrangement of its lamellae embedded in the ground substance.
4. **Posterior limiting membrane/Descemet's membrane:** It is made up of structureless homogeneous mass containing elastic fibres.
5. **Endothelium:** It consists of a single layer of low cuboidal cells.

Clinical correlation

- The periphery of the cornea frequently displays a whitish ring in older persons, owing to fatty degeneration. This whitish ring is termed *arcus senilis*.

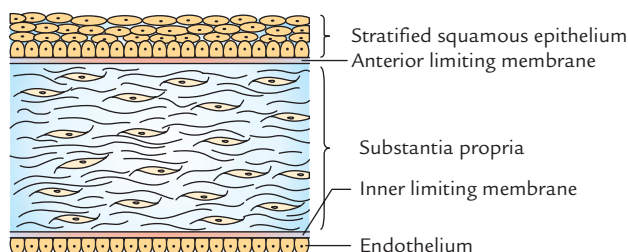


Fig. 19.21 Layers of the cornea.

- **Plastic lens:** The central part of the cornea receives oxygen from the outside air. Therefore, the soft plastic contact lenses worn for long periods must be permeable to the air so that oxygen can reach the cornea.
- **Corneal opacity:** The injury to cornea may cause opacity that may interfere with vision. The most common injuries of the eye are the cuts or tears of the cornea caused by foreign bodies.
- **Corneal graft:** The normal lack of vascularity and of lymph vessels accounts for the great success of *corneal grafts*. The cornea is successfully grafted from one person to the other.
- The **corneal reflex** is elicited clinically by gentle touching of the cornea with wisp of cotton wool. As the cornea is touched both the eyes are closed.

Pathway: Ophthalmic nerve (afferent limb) → Main sensory nucleus of trigeminal nerve → Reticular formation → Both the facial nerves (efferent limbs).

MIDDLE VASCULAR COAT OF THE EYEBALL

The middle coat is often called *vascular coat* because it contains most of the blood vessels of the eyeball. It is frequently known as **uveal tract** by the clinicians. This coat also contains a large number of melanin-containing cells. It consists of three parts; from behind forwards these are: choroid, ciliary body, and iris. These three parts together form **uvea** or **uveal tract**.

Choroid

The choroid is the posterior part of the vascular coat of the eyeball. It is brown, thin, and highly vascular membrane lining the inner surface of the sclera. *Anteriorly*, it is connected to the iris by the ciliary body and *posteriorly*, it is pierced by the optic nerve.

Arteries: They are derived from short ciliary arteries, which pierce the sclera around the optic nerve.

Veins: They are arranged in the form of whorls, which converge to form the 4 or 5 **venae vorticosae**, which pierce the sclera just behind the equator to open into the ophthalmic veins.

N.B. The inner surface of the choroid is firmly attached to the retina and nourishes the rods and cones of the retina by diffusion.

Structure

It consists of four layers (from outside inwards), *viz.*

1. **Suprachoroid lamina (lamina fusca):** It consists of loose network of elastic and collagen fibres and is traversed by long posterior ciliary vessels and nerves.
2. **Vascular lamina:** It consists of loose areolar tissue and pigment cells. It contains branches of short posterior ciliary arteries and veins, which converge in whorls to form 4 or 5 **venae vorticosae**, which pierce the sclera and drain into ophthalmic veins.

3. **Capillary lamina (capillary layer of choroid):** It consists of fine network of capillaries, which nourish photoreceptors of the retina (rods and cones) by diffusion.
4. **Basal lamina (membrane of Bruch):** It is a thin transparent membrane, which is firmly attached to the pigment cell layer of the retina.

The last three layers form the choroid proper, which is separated from sclera by **suprachoroid lamina**.

N.B. In some animals such as cat, tiger, lion, etc. the specialized cells of choroid form a reflecting media called *tapetum*, which produces greenish glare in the eyes of these animals in the night.

Ciliary Body

The ciliary body is the thickening in the vascular tunic. It is continuous with the choroid behind and the iris in front. It is situated posterior to the corneoscleral junction in front of the ora serrata of the retina.

The ciliary bodies suspend the lens via suspensory ligaments.

Parts of the Ciliary Body

The ciliary body is triangular in cross section, thick in front and thin behind. The ciliary body consists of (a) ciliary ring, (b) ciliary processes, and (c) ciliary muscle.

Ciliary ring is an outer fibrous ring, which is continuous with the choroid, *viz.*

Ciliary processes are a group of 60–90 folds on the inner aspect of the ciliary body. They are arranged radially between the ciliary ring and the iris. The grooves between the processes provide attachment to the fibres of suspensory ligament of the lens.

The ciliary processes are a complex of capillaries and cuboidal epithelium, which secretes aqueous humour. The ciliary processes may be compared with choroidal plexus of the brain ventricles involved in the secretion of CSF.

The **ciliary muscle** is a small unstriped (smooth) muscle mass consisting of mainly two types of fibres, *viz.*

1. Outer radial fibres.
2. Inner circular fibres.

Functions

Its main function is to focus the lens for near vision. The ciliary muscle as a whole acts as a sphincter, therefore, when its muscle fibres, both radial and circular contract, the choroid is pulled towards the lens reducing the tension on the suspensory ligaments. This allows the lens to assume a more spherical form because of its own elastic nature. Now lens can cause more refraction needed for accommodation.

Iris

The iris is a contractile diaphragm between the cornea and the lens. An opening in its centre is called the **pupil**. The iris is attached at its periphery to the middle of the anterior

surface of the ciliary body. Peripheral to this attachment the ciliary body and narrow rim of sclera form the **iridocorneal angle**.

Structure

The iris consists of four layers; from before backwards, these are as follows:

1. An anterior mesothelial lining.
2. A connective tissue stroma containing pigment cells and blood vessels.
3. A layer of smooth muscle, which consists of two parts.
 - (a) *Constrictor pupillae*—an inner (near the margin of the pupil) part made of circular fibres.
 - (b) *Dilator pupillae*—a peripheral part made up of radial fibres.

Nerve supply: Constrictor pupillae is supplied by the parasympathetic fibres and dilator pupillae by the sympathetic fibres.

Actions: The constrictor and dilator pupillae constricts and dilates the pupil, respectively.

4. A posterior layer of pigment cells, which is continuous with the ciliary part of the retina.

INNER NERVOUS COAT OF THE EYEBALL (RETINA)

The retina is the innermost coat of the eyeball (Fig. 19.22). It consists of two layers, *viz.*

1. An outer pigment layer.
2. An inner sensory layer.

The space between the two layers contains a gummy substance that glues the two layers.

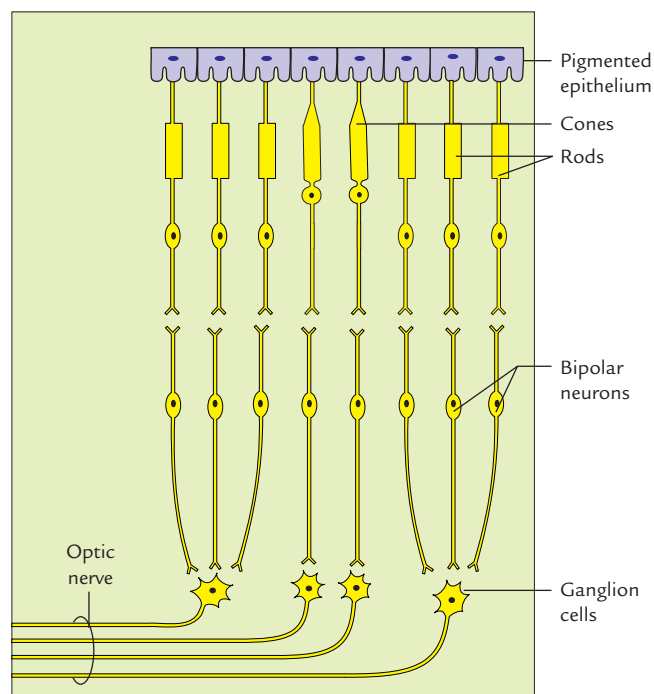


Fig. 19.22 Structure of the retina.

The retina is present between the choroid and the hyaloid membrane of the vitreous. The retina diminishes in thickness from behind forwards. Anteriorly, it presents an irregular edge called *ora serrata*.

Structure

1. The outer layer of the retina is insensitive to light and made up of pigmented cuboidal epithelium.
2. The inner sensory layer of the retina is sensitive to light and is made up of photoreceptors cells called rods and cones; as well as numerous relay neurons, *viz.* bipolar neurons and ganglion cells. The very thin non-cellular continuation of the retina in front of the *ora serrata* covers the ciliary body and iris. Thus the photosensitive part of the retina lines the inner surface of the eyeball posterior to the ciliary body. The nerve fibres arising from its ganglion cells covers inner surface and collect in the inferomedial region, where they pierce the outer two coats of eyeball and emerge as the optic nerve.

N.B. Histologically, the retina is composed of following 10 layers:

1. Outer pigmented layer
2. Layer of rods and cones (photoreceptor cells)
3. External limiting membrane
4. Outer nuclear layer (Cell bodies of rods and cones)
5. Outer plexiform layer
6. Inner nuclear layer (Cell bodies of bipolar neurons)
7. Inner plexiform layer
8. Ganglion cell layer
9. Nerve fibre layer
10. Internal limiting membrane

Blood Supply

The deeper part of the retina, i.e., up to the bipolar neurons is supplied by the central artery of the retina (a branch of the ophthalmic artery), while the superficial part of the retina up to the rods and cones is nourished by diffusion from the capillaries of the choroid.

Venous Drainage

It is by central vein of the retina, which drains into the cavernous sinus.

Development of the Retina (Fig. 19.23)

The retina develops from a hollow outgrowth the **optic vesicle** from diencephalon of primitive brain. The optic vesicle becomes invaginated to form the **optic cup**, consisting of two layers of cells. The outer layer differentiates to form the **pigment cell layer** and the inner layer differentiates to form the **neural layer**. The neural layer forms the remaining layers of the retina with photoreceptor cell (rods and cones) outermost, i.e., next to pigment cells. The ganglion cells are innermost. Therefore light has to pass through them to stimulate the rods and cones.

The two layers of optic cup remain separate during embryonic period but fuse later during early fetal period with potential space between the two. Therefore in retinal detachment, the plane of cleavage is between pigment cell layer and neural layer.

Clinical correlation

- **Retinal detachment:** In retinal detachment there is separation of two layers of the retina (i.e., pigment and neural layers).

- **Appearance of the retina as seen through an ophthalmoscope:** The posterior region of retina (fundus) can be examined by an ophthalmoscope, a procedure called *fundoscopy* (fundoscopic examination). The following features are observed (Fig. 19.24):

- *Macula lutea*, a pale yellowish area near the posterior pole.

It is approximately 4 mm in diameter. A small pit (1.5 mm in diameter) in its center is called *fovea centralis*, which is the point where light is normally focused.

The fovea is the portion of retina with maximum concentration of cone receptors, hence the site of greatest visual acuity, i.e., the ability to see the fine images (keenest vision).

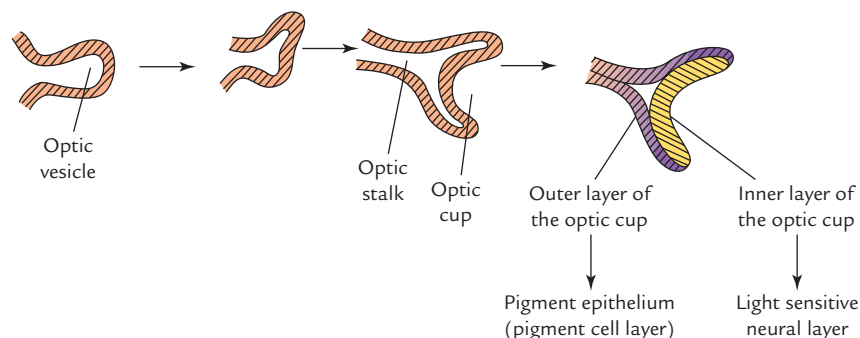


Fig. 19.23 Stages in the development of the retina.

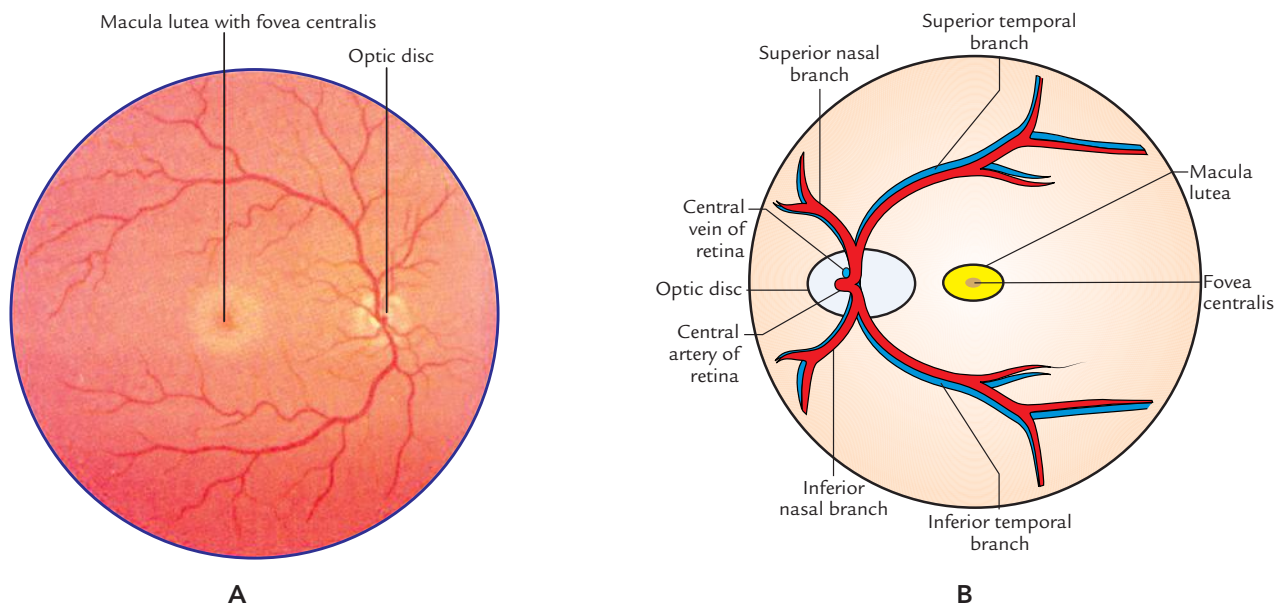


Fig. 19.24 Features in the fundus of eye as seen during ophthalmoscopy: **A**, actual photograph; **B**, schematic diagram of fundus. (Source: Fig. 8.102, Page 852, *Gray's Anatomy for Students*, Richard L Drabe, Wayne Vogl, Adam WM Mitchell. Copyright Elsevier Inc. 2005, All rights reserved.)

- **Optic disc** (1.5 mm in diameter), a white spot about 3 mm medial to the macula. The depressed area in the center is called *physiological cup*.

The nerve fibres from retina meet and pass through this region (optic disc) of the eyeball to form the optic nerve. The blood vessels of retina also pass through this spot.

Since there are no photoreceptor cells in the optic disc, it does not respond to the light. Therefore, the optic disc is also called *blind spot*.

- The **central artery of the retina** enters the eye through the center of the optic disc. It divides into superior and inferior branches. Each of them further divides into temporal and nasal branches. The **retinal veins** follow the arteries. The branches of the central artery of retina are seen radiating over the edges of the optic disc. They are smaller and paler than veins. At points where they cross veins, the vein wall can be seen through the artery.

The normal optic disc appears as a cup-shaped area paler than the surrounding area (fundus). The edges of the disc are sharp and well-defined.

The congestion of the optic disc from increased intracranial pressure is called *papilledema* in which the optic cup is obscured and the disc margin is blurred.

N.B. The fovea centralis is the thinnest part of retina and its size is comparable to optic disc.

ARTERIAL SUPPLY OF THE EYEBALL

The eyeball is supplied by the following arteries (Fig. 19.25):

1. Central artery of the retina.
2. Long and short posterior ciliary arteries.

3. Anterior ciliary arteries.

In the region of ciliary body, a **major arterial circle** is formed by the anastomosis between long posterior ciliary artery and anterior ciliary artery. From major arterial circle the vessel passes centripetally and anastomoses close to the pupillary margin to form the **minor arterial circle**.

COMPARTMENTS OF THE EYEBALL

The interior of the eyeball is divided into two compartments by the lens: a small anterior compartment in front of the lens and a large posterior compartment behind the lens (Fig. 19.26):

1. **Anterior compartment:** It is divided into two chambers: a smaller *anterior chamber* and a larger *posterior chamber*.

The anterior chamber lies between the iris and cornea and posterior chamber between iris and lens. The two compartments communicate with each other through pupil.

The two chambers are filled with an **aqueous humour**, which helps in maintaining the intraocular pressure. The aqueous humour is rich in ascorbic acid, glucose, and amino acids. It nourishes the cornea and the lens which are otherwise avascular.

Circulation of aqueous humour: The aqueous humour is secreted in the posterior chamber by the ciliary processes. From here it passes into the anterior chamber through the pupil. Here it passes through the spaces in the iridocorneal angle, located between the fibres of *ligamentum pectinatum* and then enter into the *canal of Schlemm*, from where it is drained by the *anterior ciliary veins*.

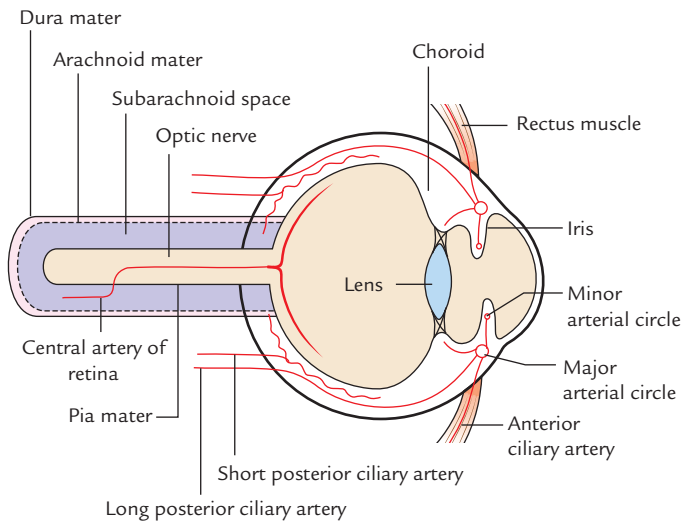


Fig. 19.25 Arterial supply of the eyeball.

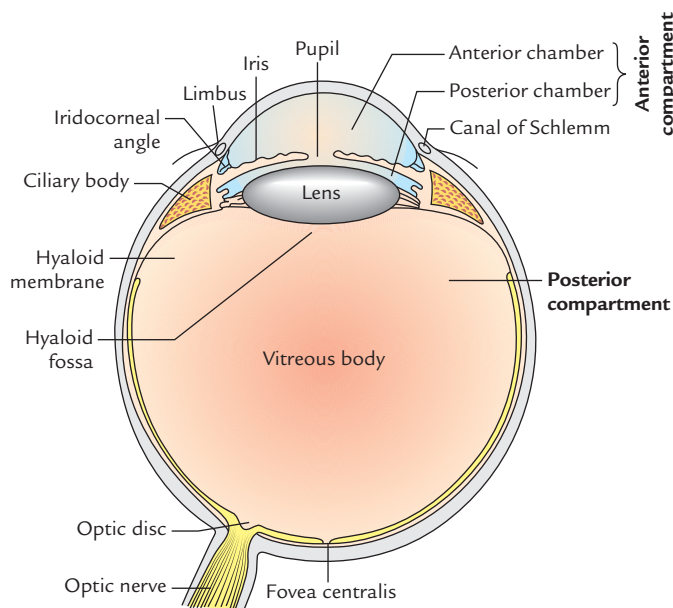


Fig. 19.26 Compartments of the eyeball.

Clinical correlation

Glaucoma: If the drainage of aqueous humour is blocked, there occurs an abnormal increase in the intraocular pressure—a condition called *glaucoma*. As a result, there is severe pain in the eye due to pressure on the highly sensitive cornea.

The glaucoma may cause variety of visual problems, viz. blindness due to compression of retina and its blood supply.

The intraocular pressure which normally is about 15 mmHg can be measured on anesthetized cornea (*tonometry*).

2. **Posterior compartment:** It is behind the lens and much larger than the anterior compartment (comprising four-fifth of the eyeball). It is surrounded almost completely by the retina and is filled with colorless, transparent jelly-like substance called **vitreous humour/vitreous body**. The vitreous humour is enclosed in a delicate *hyaloid membrane*. Anteriorly, the hyaloid membrane forms a depression the *hyaloid fossa* in which rests the lens. The vitreous humour helps in maintaining intraocular pressure and therefore the shape of the eyeball. Further, it holds the lens and the retina in place. The *hyaloid canal* extends from optic disc to the lens. The canal marks the site of the *hyaloid artery* in the fetus. The hyaloid artery is a continuation of central artery of the retina which disappears 6 weeks before birth.

LENS

The lens is an unusual biological structure. It is a transparent, biconvex body, 1 cm in diameter and 4 mm thick, placed between the anterior and posterior compartments of the eyeball.

External Features

The lens presents the following external features:

1. Anterior and posterior surfaces.
2. Anterior and posterior poles.
3. A circumference—the equator.

The line connecting the anterior and posterior poles is called the *axis of the lens*.

Structure

The lens is enclosed in a transparent elastic capsule. Anteriorly deep to capsule lies capsular epithelium. In the center, the epithelium is made up of a single layer of cuboidal cells. The cells at periphery prolongate to give rise to lens fibres. These fibres get arranged concentrically and form the lens substance. The center (nucleus) of the lens consists of oldest fibres. Here the lens fibres lose their nuclei and organelles. As a result, a special set of proteins called **crystallines** lie in the center. The center of the lens is, therefore, hard. The periphery of the lens (cortex) is soft because it is made up of more recently formed fibres.

Clinical correlation

- **Presbyopia (short vision):** The lens plays an important role in *accommodation*. The lens absorbs much of the ultraviolet light and becomes increasingly yellowish with age. It also becomes harder with age. As a result of which the power of accommodation is lessened in old age producing a clinical condition called *presbyopia*.

- **Cataract:** The opacity of the lens is termed *cataract*. With increasing age and in certain disease states, the lens becomes opaque. The increasing opacity leads to increasing visual impairment. This can be treated surgically by excision of opaque lens and replacement with an artificial lens.

Suspensory Ligaments of the Lens (Zonule of Zinn)

The lens is suspended between the anterior and posterior compartments of the eye by suspensory ligaments of the lens. These ligaments extend from ciliary body to the lens capsule mostly in front.

FUNCTIONS OF THE EYE

The main function of the eye is focusing of light waves and stimulation of photoreceptors of the retina. This requires five basic processes, *viz.*

1. Transmission of light waves through transparent media of the eyeball.
2. Refraction (bending) of light waves through different refractive media of different densities.

3. Accommodation of the lens to focus the light waves.
4. Regulation of amount of light entering the eye through pupil by iris diaphragm.
5. Convergence of eyeballs.

The stimulation of photoreceptors of retina generates action potentials that are relayed through the optic pathways to the visual cortex of the brain, where image is formed. The visual impairment may result if any one or more of these processes fail to function properly.

REFRACTIVE MEDIA OF THE EYE

These include:

1. Cornea (very refractive but not adjustable).
2. Aqueous humour.
3. Lens (refractive and adjustable).
4. Vitreous humour/vitreous body.

All these media together form the **refractive apparatus** of the eye.

N.B. Most of the refraction by eye takes place at the anterior surface of the cornea (not in the lens as generally thought).

Golden Facts to Remember

▶ Most important content of the orbit	Eyeball
▶ All structures within the orbit lie inside the orbital periosteum except	Infraorbital nerve and vessels and zygomatic nerve, which lie outside the orbital periosteum
▶ White of the eye	Sclera
▶ Uvea (or uveal tract)	Consists of choroid, ciliary body, and iris
▶ Weakest site of sclera	Lamina cribrosa
▶ Site of keenest vision in retina	Fovea centralis
▶ Blind spot of the retina	Optic disc
▶ Maximum refraction by the eye takes place at	Anterior surface of the cornea
▶ Most successful homotransplant (i.e., between the individuals of the same species)	Corneal transplant
▶ Most important branch of ophthalmic artery	Central artery of the retina
▶ All the extraocular muscles are supplied by the oculomotor nerve except	Lateral rectus (supplied by the abducent nerve) and superior oblique (supplied by the trochlear nerve)
▶ Canal of Schlemm	Circular vascular channel within sclera just behind the corneoscleral junction
▶ Refractive apparatus of the eye	Consists of cornea, aqueous humour, lens, and vitreous humour
▶ Tenon's capsule	Thin membranous sheath enclosing the eyeball
▶ Most common of all eye operations	Cataract extraction

Clinical Case Study



A 66-year-old person visited his family physician and complained of headache and blurring of vision. He referred him to an ophthalmologist, who on ophthalmoscopic examination found papilledema (edema of optic discs) and congestion of retinal veins. CT scan of his head revealed a large intracranial tumor in the region of the posterior cranial fossa.

Questions

1. What is an optic disc?
2. Describe the development of optic nerve and retina.
3. How does intracranial tumor cause papilledema.

Answers

1. The optic disc is a white spot (or plate area) about 3 mm medial to the posterior pole of eye—seen on ophthalmoscopic examination. The nerve fibres from retina leave the eyeball at this site to become the optic nerve. This area is devoid of photoreceptor cells. The central artery of retina enters and tributaries of central vein of retina leave the eyeball

through the centre of the optic disc. The region of optic disc does not respond to light due to absence of photoreceptor cells (rods and cones), hence it is also called the **blind spot**.

2. The optic nerve and retina develop from optic stalk and optic cup, respectively. The optic stalk and optic cup are derived from diencephalon as hollow outgrowth. The optic nerve being derived from brain is surrounded by three meninges.
3. The optic nerve is surrounded by three meninges of the brain, up to its entry in the eyeball, and the subarachnoid space filled with CSF is continuous with subarachnoid space around the brain. As a result, rise in intracranial pressure (and hence CSF pressure) due to intracranial tumor, the central vein of retina traversing the subarachnoid space around optic nerve is compressed. This leads to venous congestion and edema of the optic disc called papilledema.

Vertebral Canal and Its Contents

The vertebral canal is an elongated cavity inside the vertebral column. The vertebral column consists of 33 segments/vertebrae lying one above the other. They are grouped according to the body regions as follows: 7 cervical, 12 thoracic, 5 lumbar, 5 sacral, and 4 coccygeal vertebrae. In general, each vertebra consists of two parts: a ventral **body** and a dorsal **neural arch**, which enclose between them the vertebral foramen (for details see *General Anatomy*, Chapter 8: Vertebral Column by Vishram Singh).

The vertebral canal is a collective name given to the whole series of vertebral foramina lying one above the other when the vertebrae are held together in the vertebral column.

In human body both in vivo and in vitro, the vertebral canal is a smooth-walled space bounded anteriorly by the vertebral bodies, intervertebral discs, and the posterior longitudinal ligament; and posteriorly by the vertebral laminae and *ligamenta flava*. On each side, it is bounded by the pedicles of vertebrae with intervening large *intervertebral foramen*.

The **vertebral canal** is continuous above with the **cranial cavity** and below with the **sacral canal**. The latter is considered as the part of the vertebral canal.

CONTENTS OF THE VERTEBRAL CANAL

The vertebral canal contains spinal cord surrounded by its meninges. The bony wall of the canal is separated from the spinal meninges by the **epidural space**.

The contents of vertebral canal are summarized as follows:

1. Epidural space.
2. Spinal meninges.
3. Spinal cord with its nerve roots.

EPIDURAL SPACE

The epidural space lies between the spinal dura and the periosteum lining the vertebral canal. It is filled with loose areolar tissue and semiliquid fat and contains (a) **minute spinal arteries** and (b) a network of veins—the **internal vertebral venous plexus** (Fig. 20.1).

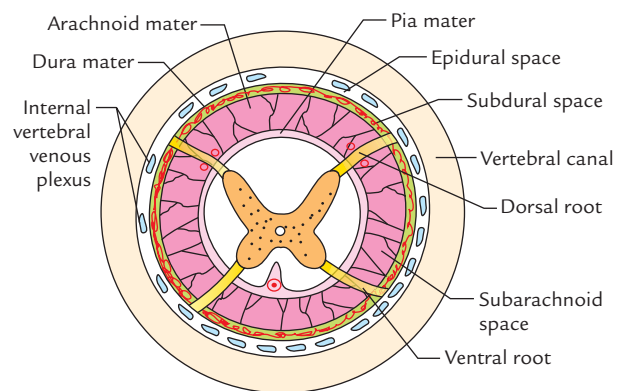


Fig. 20.1 Schematic transection of the vertebral canal showing its contents.

Spinal Arteries

These are segmental arteries, which arise from ascending cervical and deep cervical arteries in the cervical region, from posterior intercostal arteries in the thoracic region, from lumbar arteries in the lumbar region, and lateral sacral arteries in the sacral region. They enter the vertebral canal through intervertebral foramina along the spinal nerve roots. They supply spinal cord, its nerve roots and meninges, and the surrounding bones and ligaments.

Internal Vertebral Venous Plexus (Fig. 20.2)

The internal vertebral venous plexus is a network of veins in the epidural space of the vertebral canal and extends throughout the length of the vertebral canal. These veins correspond to the dural venous sinus within the cranial cavity and are continuous with them through the foramen magnum.

The plexus is drained by four subordinate longitudinal channels: two posterior and two anterior.

The anterior part of plexus receives large **basivertebral veins** (main tributaries) draining the active red marrow within the bodies of the vertebrae and sends efferent intervertebral veins through intervertebral foramina to drain into **external vertebral plexus**, which in turn drains into **segmental veins**.

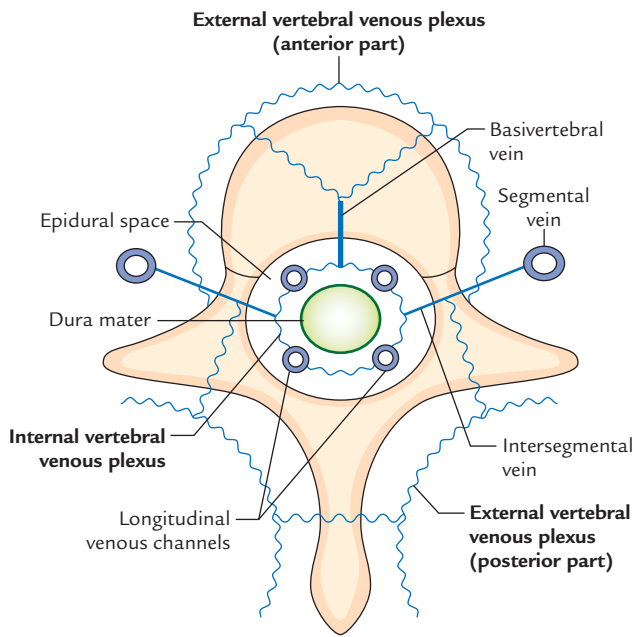


Fig. 20.2 Vertebral venous plexus.

The segmental veins are body wall veins, *viz.* vertebral, posterior intercostal, lumbar, and lateral sacral veins.

Apart from draining venous blood from the vertebrae, the internal vertebral venous plexus receives veins from spinal meninges and spinal cord.

External Vertebral Venous Plexus (Fig. 20.2)

The external vertebral venous plexus lies outside the vertebral column and consists of anterior vessels lying in front of vertebral bodies and posterior vessels lying on the back of the vertebral arches. The anterior and posterior vessels communicate with each other and with the internal vertebral venous plexus. All these veins are devoid of valves.

N.B. The veins of internal and external venous plexuses and their connecting veins do not have valves in their lumen. Consequently the blood flows within these veins in both directions.

Clinical correlation

The *internal venous plexus* provides a venous bypass when the inferior vena cava fails to cope with sudden flush of blood resulting from sudden increase of intra-abdominal pressure as during coughing and straining. It transmits venous blood from areas of high venous pressure, e.g., from the tributaries of inferior vena cava (lateral sacral and lumbar veins) to the tributaries of superior vena cava (posterior intercostal and vertebral veins). Thus pelvic tumors, especially cancer prostate, can spread to vertebral bodies and even to skull without having to pass through heart and lungs and produce secondaries at these sites.

SPINAL MENINGES

The spinal cord is surrounded by three coverings called *meninges* (Fig. 20.3). From superficial to deep, these are as follows:

1. Spinal dura mater.
2. Spinal arachnoid mater.
3. Spinal pia mater.

The potential space between the dura and arachnoid maters is termed as **subdural space**, while the large space between the arachnoid mater and pia mater is known as **subarachnoid space**.

Spinal dura mater

It is the prolongation of the inner meningeal layer of cranial dura mater and extends from foramen magnum to the lower border of S2 vertebra. It is attached firmly to the foramen magnum, the tectorial membrane and the posterior longitudinal ligament on the body of axis vertebra. Elsewhere it lies free in the vertebral canal. The lower blind end of dural tube is pierced by filum terminale in its center.

The spinal dura is pierced segmentally by dorsal and ventral roots of the spinal nerves and prolonged over these roots as sleeve-like projections, which enter the intervertebral foramina and ends by fusing with the epineurium of the spinal nerves. The recurrent meningeal branches of the spinal nerves supply the spinal dura.

Subdural space: It is a potential space between the spinal dura and arachnoid mater containing a thin film of serous fluid, which acts as a lubricant. As a result, the dura mater can freely move over the arachnoid. The subdural space is

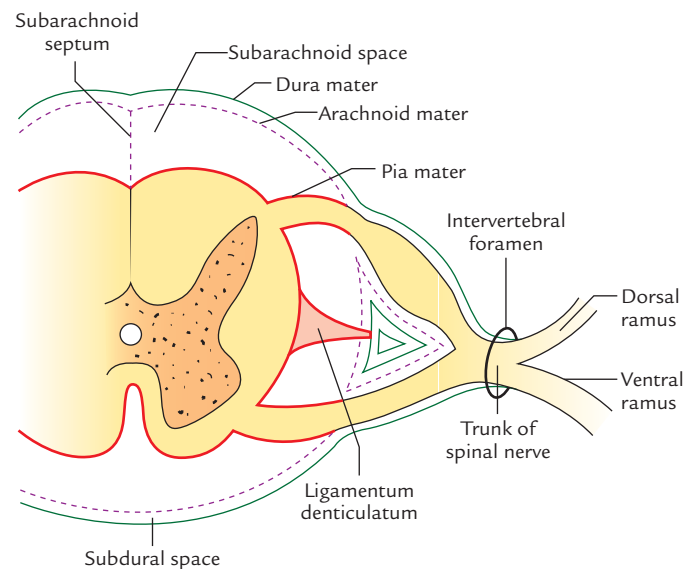


Fig. 20.3 Schematic transverse section of the spinal cord showing meninges and formation of meningeal sheaths onto the spinal nerve roots.

prolonged to a short distance around the roots of the spinal nerves.

Spinal arachnoid mater

It is a thin transparent vascular membrane that loosely invests the spinal cord. Above it is continuous with the arachnoid mater surrounding the brain and below it extends up to the lower border of second sacral vertebra. It is separated from pia mater by the subarachnoid space. The arachnoid mater sends many delicate thread like processes across the subarachnoid space to the pia mater forming a spider's web-like arrangement.

Subarachnoid space: The subarachnoid space is a relatively large space between arachnoid mater and pia mater. It is filled with cerebrospinal fluid (CSF), which forms about half of the total volume of CSF (i.e., 75 ml out of 150 ml). It communicates with the subarachnoid space around the brain at the foramen magnum. Below the level of conus medullaris (lower conical end of spinal cord) the space is quite roomy (called **lumbar cistern**) and contains only cauda equina and filum terminale in a pool of CSF. The *lumbar puncture* is usually done in this region between the L3 and L4 vertebra.

Spinal pia mater

It is a vascular membrane that closely invests the spinal cord. The pia mater is modified at some places. These modifications are called **processes of pia mater**.

Processes of pia mater

1. **Filum terminale:** It is a delicate thin thread-like prolongation of pia mater beyond the conus medullaris. It is about 20 cm long and extends from tip of conus medullaris to the base of the coccyx. It pierces the dural tube, passes through the sacral canal and sacral hiatus to gain attachment on the dorsum of the first piece of the coccyx. The filum terminale is divided into two parts: **filum terminale internum** and **filum terminale externum**.

The *filum terminale internum* is about 15 cm long and lies within the dural sac.

The *filum terminale externum* is 5 cm long and lies outside the dura mater.

2. **Ligamenta denticulata:** On each side between the dorsal and ventral nerve roots, the pia mater forms narrow ribbon-like transparent bands called **ligamenta denticulata**. The lateral margin of each ligamentum denticulatum sends 21 teeth-like projections, which pass through subarachnoid space and arachnoid mater to gain attachment on the inner surface of the dural tube between the points of emergence of two adjacent spinal nerves. Thus ligamenta denticulata helps to anchor the spinal cord in the middle of the subarachnoid space. The first tooth of ligamentum denticulatum is at the level of the foramen magnum, while the last tooth lies between T12 and L1 spinal nerves (Fig. 20.4).

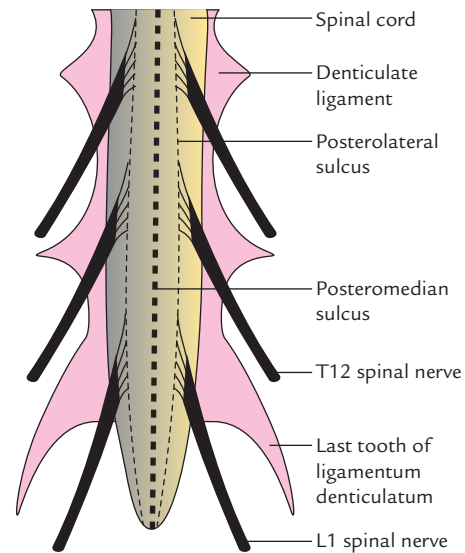


Fig. 20.4 Posterior view of part of the spinal cord showing ligamenta denticulata.

3. **Linea splendens:** It is a thickened band of pia mater along the anterior median fissure of the spinal cord.
4. **Subarachnoid septum:** It is a fenestrated pial septum in the midsagittal plane, which connects the pia mater with arachnoid mater posteriorly. Posteriorly, the pia mater is also attached to the posterior median septum of the spinal cord.

Clinical correlation

- **Lumbar puncture:** The lumbar puncture is done to draw CSF from subarachnoid space for diagnostic and therapeutic purposes. The needle is inserted between L3 and L4 or L4 and L5 vertebrae with patient's back flexed either in sitting position or lying on a bed in left lateral position, usually the later when patient is curled up lying on left side. The needle passes through the supraspinous and interspinous ligaments and between ligamenta flava before piercing the dura mater. As the dura mater is pierced, there is a distinct feel of *give way*. Since the spinal cord ends at the lower border of L1 vertebra, there is no danger of damage to the spinal cord (for details see *Clinical and Surgical Anatomy* by Vishram Singh).
- **Spinal anesthesia:** To give spinal anesthesia, the anesthetic solution is injected into the subarachnoid space. It mixes up with CSF surrounding the spinal nerve roots which get anesthetized. The procedure is same as that of lumbar puncture.
- **Epidural anesthesia:** To give epidural anesthesia, the anesthetic solution is injected into the epidural space at the desired site without piercing the dura mater. The solution infiltrates through the meningeal sheaths around the nerve roots, which consequently get anesthetized.

SPINAL CORD

The spinal cord is the long (average length 45 cm) lower cylindrical part of the central nervous system occupying the upper two-thirds of the vertebral canal. It begins at the foramen magnum as the continuation of medulla oblongata and usually terminates opposite the intervertebral disc between the L1 and L2 vertebrae. In the fetus, the spinal cord extends up to the level of the lower border of S2 vertebra.

The functions of the spinal cord are as follows:

1. Transmission of information to and fro between body and brain.
2. Execution of simple reflexes.

External Features

The spinal cord is cylindrical structure, somewhat flattened anteroposteriorly. Its lower end tapers into a cone forming the **conus medullaris**. The spinal cord gives origin to 31 pairs of spinal nerves. The girth of spinal cord increases considerably in the regions that give origin to large nerves of the limbs. These enlargements are known as *cervical and lumbar swellings/enlargements*. The spinal cord presents the following external features:

1. Fissures and sulci.
2. Attachments of spinal nerve roots.
3. Enlargements of the spinal cord.

Fissures and sulci

The anterior aspect of spinal cord possesses a deep midline groove called **anterior median fissure**. It extends along the entire length of the spinal cord. On either side of anterior median fissure it presents anterolateral sulci. The posterior aspect of the spinal cord presents a shallow posterior median sulcus, from which a posterior median septum of neuroglial tissue extends into the substance of the cord to a variable extent.

Attachments of spinal nerve roots

The anterior and posterior roots of the spinal nerve unite within the intervertebral foramina. The anterior root is formed by 3 or 4 rootlets, which emerge along the anterolateral sulcus of the spinal cord. The posterior root is formed by several rootlets, which are attached to the **posterolateral sulcus** of the spinal cord. A short distance from the cord the rootlets unite to form a single root. The anterior and posterior roots pass to their appropriate intervertebral foramina, where each evaginates dura mater separately before uniting to form the nerve trunk. The *ganglion* on the posterior root lies in the intervertebral foramen, within the tubular evagination of dura and arachnoid proximal to the point of union of anterior and posterior nerve roots.

At all levels from C1 to L1 vertebrae, the anterior and posterior nerve roots pass in front of and behind the ligamentum denticulatum, respectively.

Since the spinal cord is shorter than the vertebral canal, the course of spinal nerve roots in the vertebral canal to reach the appropriate intervertebral foramen varies.

The upper cervical nerve roots pass almost horizontally, the thoracic nerve roots pass obliquely, while lumbar and sacral nerve roots descend almost vertically downwards forming the *cauda equina*.

The cauda equina is a leash of lumbar (except L1), sacral, and coccygeal nerve roots around the filum terminale in the pool of CSF. It is so named because the lower end of the spinal cord along with the aforementioned structures resembles the tail of a horse (cauda = tail, equina = horse).

Exit of spinal nerves: All the spinal nerves exit out of vertebral canal through an intervertebral foramen except the following ones:

- C1 spinal nerve emerges above the posterior arch of atlas vertebra.
- C2 emerges between the posterior arch of atlas and axis vertebra.
- S5 and CX 1 emerge through lower end of the sacral canal. Other sacral nerves have separate sacral foramina for each ramus.

Spinal ganglia: These are collection of nerve cell bodies of pseudounipolar neurons. The nerve cell bodies give rise to sensory fibres (peripheral processes) in the peripheral nerve and nerve fibres (central processes) in the dorsal root on which the ganglion lies. There is no synapse in the spinal ganglia.

N.B. All the spinal ganglia lie in the intervertebral foramina except the sacral and coccygeal, which lie in the sacral canal and the first two cervical, which lie in the corresponding position above and below the first cervical vertebra, behind the articular facets.

Spinal segments: The portion of spinal cord which gives origin to a pair of spinal nerves is termed **spinal segment**. (The spinal segments are not visible on the surface.) Thus the spinal cord consists of 31 spinal segments. The size of segment depends upon the amount of tissue supplied by each segment.

Due to relative shortening of the spinal cord as compared to the vertebral canal, the spinal segments lie above their corresponding vertebral level, a fact of great clinical significance in determining the level of vertebral injury from signs and symptoms produced due to injury to a particular segment. Table 20.1 provides the approximate vertebral levels of the spinal segments.

Enlargements of spinal cord

The spinal cord is not uniform in diameter. It presents two enlargements in those regions, which supply the upper and lower limbs and associated girdles. The two enlargements are as follows:

Table 20.1 Approximate vertebral levels of the spinal segments

Spinal segments	Vertebral levels
Cervical 1–8	Foramen magnum to C6 vertebrae
Thoracic 1–6	C6 – T4 vertebrae
Thoracic 7–12	T4 – T9 vertebrae
Lumbar and sacral	T10 – L1 vertebrae

1. **Cervical enlargement:** In the region of C5–T1 spinal segments. The nerves arising from these segments form **brachial plexus**.
2. **Lumbar enlargement:** In the region of L2–S3 spinal segments. The nerves arising from these segments form the **lumbar plexus**.

The vertebral levels of these enlargements are quite different from that of spinal segments, *viz.* cervical enlargement lies opposite C3 to T1 vertebrae and lumbar enlargement lies opposite T9 to L1 vertebrae.

These enlargements in spinal cord are due to greatly increased mass of motor cells in the anterior horns of grey matter in these spinal segments.

Internal Structure

The spinal cord consists of a central mass of grey matter made up of nerve cells and peripheral mass of white matter made up of fibre tracts.

In a cross section of the cord, the grey matter is seen as an H-shaped (or butterfly shaped) fluted column, extending throughout the length of the spinal cord. It is divided into symmetrical right and left comma-shaped masses, which are connected across the midline by a **transverse grey commissure**. The central canal of the cord passes through the center of the grey commissure. The canal is surrounded by **substantia gelatinosa centralis**. The lateral comma-shaped mass of grey matter is divided by a transverse grey commissure into a narrow elongated **posterior horn** and **broad anterior horn**. The posterior horn extends almost up to the surface of the cord but anterior horn falls short of it (Fig. 20.5).

In the thoracic segments and upper two lumbar segments (T1 to L2), a triangular projection juts out from the side of the lateral grey mass between the anterior and posterior horns, nearly opposite to the grey commissure. It is called the **lateral horn**. The posterior horns are connected to the surface by a gelatinous substance called **substantia gelatinosa**. The amount of grey matter and shape of its horns, and amount of white matter varies at different levels (Fig. 20.5).

The anterior grey horns are largest in the cervical and lumbar enlargements as they are proportional to the volume of the tissue supplied by the spinal nerves at these levels. The posterior white columns are largest in the cervical region.

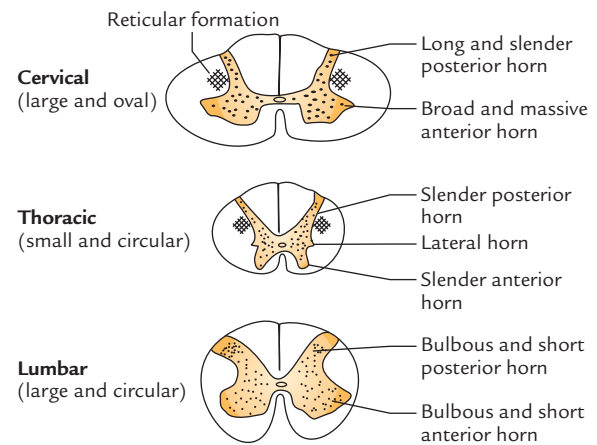


Fig. 20.5 Cross sections of the spinal cord in the cervical, thoracic, and lumbar regions. The shape of sections is given on the left side while the shape of anterior and posterior horns is given on the right side.

Table 20.2 enumerates the characteristic features of the spinal segments in different regions of the spinal cord.

Grey Matter

The grey matter of spinal cord consists of (a) nerve cells, (b) neuroglia, and (c) blood vessels.

Types of neurons in the grey matter

1. **Motor neurons:** These are present in the anterior and lateral horns.

Types of motor neurons in the anterior horn

(a) **Alpha (α) neurons:** They are large multipolar cells (25 μm or more in diameter) and supply the extrafusal skeletal muscle fibres.

(b) **Gamma (γ) neurons:** They are small multipolar cells (15–25 μm in diameter) and supply the intrafusal muscle fibres of the neuromuscular spindles in skeletal muscles.

Types of motor neurons in the lateral horn

They are preganglionic autonomic neurons.

N.B. The axons of motor neurons leave the spinal cord as the final common path (Sherrington) through the ventral roots of the spinal nerves and reach the skeletal muscles.

2. **Sensory neurons:** These are present in the posterior horn and involved in relay of sensory information to the different parts of the brain forming **ascending tracts**; or to the other segments of spinal cord forming **intersegmental tracts**.
3. **Interneurons:** These are small neurons present throughout the grey matter of the spinal cord. They connect different types of neurons, hence also called **association neurons**. These are either inhibitory or excitatory and concerned with integration of segmental activities.

Table 20.2 Characteristic features of the spinal segments as seen in transverse sections at cervical, thoracic, and lumbar regions of the spinal cord

Features	Levels		
	Cervical	Thoracic	Lumbar
Grey matter	Large	Small	Large
Posterior horn	Slender and extends far posteriorly	Slender	Bulbous
Anterior horn	Massive	Slender	Bulbous
Lateral horn	Absent	Present	Present only in L1 and L2 segments
Reticular formation	Well developed	Poorly developed	Absent
Amount of white matter	Massive ++++	Large (less than in the cervical region) ++	Less (but slightly less than in the thoracic region) ++

Nerve cell groups in the grey columns of spinal cord

Cell groups in the anterior grey column: Numerous groups of motor neurons are found in the cross section of anterior grey column, representing several longitudinally arranged columns of varying lengths. They are divided into three main groups or nuclei: (a) medial, (b) lateral, and (c) central.

Medial group extends along most of the length of the spinal cord and innervate the axial musculature of the neck and trunk. This is further subdivided into *ventromedial* and *dorsomedial* parts.

Lateral group is confined to the cervical and lumbosacral enlargements and supply the limb muscles.

Central group forms three definite nuclei, which are fairly localized. These are as follows:

1. **Phrenic nucleus** in the cervical region (extending from C3 to C5 segments) innervates the diaphragm.
2. **Lumbosacral nucleus** in the lumbosacral region (extending from L2 to S3 segments). Its function is unknown so far.
3. **Spinal nucleus of accessory (XI cranial) nerve** in the cervical region (extending from C1 to C5 segments) and giving origin to the spinal root of accessory nerve.

Cell groups in the posterior grey column: In the posterior grey column, the cell groups are arranged into four longitudinal columns; from the apex towards the base they are:

1. Substantia gelatinosa (of Rolando).
2. Nucleus proprius.
3. Nucleus dorsalis (or Clarke's column).
4. Visceral afferent nucleus.

Substantia gelatinosa is situated at the apex of the posterior grey column and extends throughout the length of the spinal cord. It is composed of small neurons (also called *interneurons*). It receives the afferent fibres of the lateral

division of the posterior nerve roots conveying primarily, the pain and temperature sensations. Some of these fibres synapse with the interneurons of substantia gelatinosa. The substantia gelatinosa is continuous above with the nucleus of spinal tract of the trigeminal nerve.

Nucleus proprius is a group of large nerve cells situated anterior to the substantia gelatinosa and constitutes the main bulk of cells present in the posterior grey column.

It extends along the whole length of the spinal cord and receives the fibres from posterior white column that are associated with the sense of position and movement (proprioception), two-point discrimination, and vibration.

Nucleus dorsalis (Clarke's column) occupies the medial part of the base of the posterior grey column, projecting somewhat into the posterior funiculus, and extends from C8 to L2/L3 segments of the cord and receives proprioceptive afferents (muscle and joint sense) and exteroceptive afferents (touch and pressure from the trunk and lower limb).

Visceral afferent nucleus is located lateral to the nucleus dorsalis and extends from T1 to L2 and from S2 to S4 segments of the cord and receives visceral afferents from the dorsal nerve roots.

Cell groups in the intermediate (lateral) grey column: The cells of the lateral grey column form two nuclei: (a) intermediolateral and (b) intermediomedial.

The **intermediolateral nucleus** extends from T1 to L2 segments of the cord and gives origin to preganglionic fibres of the sympathetic nervous system (*thoracolumbar outflow*) which leave the cord along with the anterior nerve roots.

The **intermediomedial nucleus** extends from S2 to S4 segments of the cord and gives origin to preganglionic fibres of parasympathetic nervous system (*sacral outflow*), which also pass out through the anterior nerve roots of the corresponding sacral nerves.

N.B. Apart from the central grey matter, there are strands of grey matter in the lateral white column adjacent to the base of the posterior horn, which are termed *reticular formation*.

White Matter

The white matter of the spinal cord surrounds the central H-shaped mass of grey matter and mainly consists of nerve fibres, the large proportion of them being myelinated, giving it a white appearance.

In each half of the spinal cord, the white matter is divided into three parts called columns:

1. **Posterior white column**, between the posterior median septum and the posterior horn.
2. **Lateral white column**, between the anterior and posterior horns.
3. **Anterior white column**, between the anterior median fissure and the anterior horn.

The anterior white columns are joined together by the **white commissure**.

Each white column is made up of tracts, which are either ascending (sensory) or descending (motor).

N.B. In general, the posterior white column is sensory, the anterior column is motor and lateral column is mixed

(i.e., motor as well as sensory). Further, the ascending tracts are located towards the periphery and the descending tracts towards the center.

TRACTS OF THE SPINAL CORD

The tracts are defined as collections of nerve fibres within the central nervous system, which have same origin, course, and termination. They are sometimes referred to as *fasciculi* (= bundles) or *lemnisci* (= ribbons).

The tracts are named after the names of masses of grey matter connected by them. Their names usually consist of two components (or terms), the first term denotes the origin and second the termination of the tract. For example, a tract arising in cerebral cortex and terminating in the spinal cord is called **corticospinal tract**. Similarly a tract arising in the spinal cord and terminating in the thalamus is called **spinothalamic tract** (Fig. 20.6).

Classification of the Tracts

The tracts of spinal cord are classified mainly into two types: descending and ascending (Fig. 20.6).

The distribution of different descending and ascending tracts in three white columns (anterior, lateral, and posterior) of the spinal cord are summarized in Table 20.3.

Table 20.3 The presence of different tracts in anterior, lateral, and posterior white columns of the spinal cord

Column	Descending tracts	Ascending tracts
Anterior white column	Anterior corticospinal, vestibulospinal, tectospinal, medial reticulospinal	Anterior spinothalamic
Lateral white column	Lateral corticospinal, rubrospinal, lateral reticulospinal, hypothalamospinal	Lateral spinothalamic, anterior spinocerebellar, posterior spinocerebellar, spinotectal
Posterior white column		<ul style="list-style-type: none"> • Fasciculus gracilis (tract of Goll) • Fasciculus cuneatus (tract of Burdach)

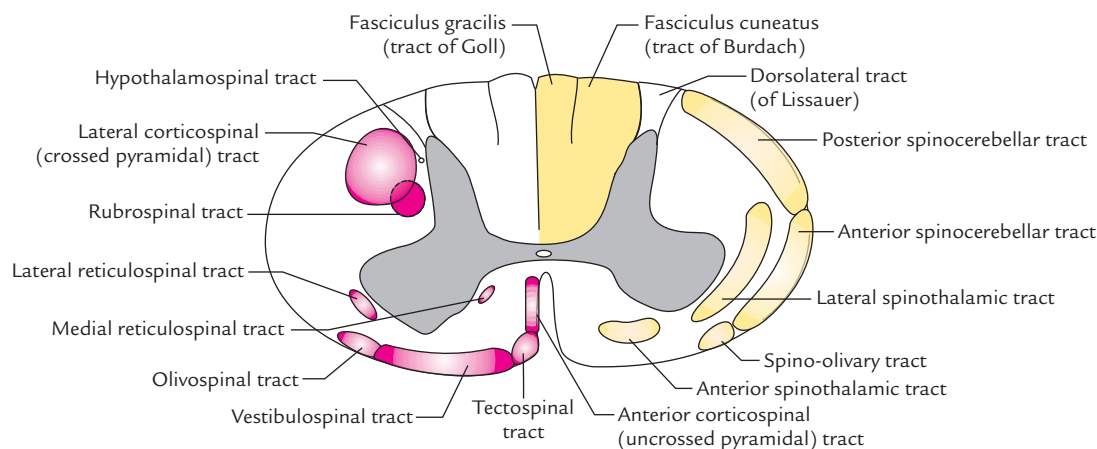


Fig. 20.6 Transverse section of the spinal cord at midcervical level showing main descending (on left side) and ascending (on right side) tracts.

DESCENDING TRACTS

The descending tracts conduct the impulses to the spinal cord from the brain.

Corticospinal Tracts (Pyramidal Tract; Fig. 20.7)

The lateral and anterior corticospinal tracts mediate voluntary motor activities.

The pyramidal tract consists of about one million fibres.

Origin: The most of the fibres of corticospinal tracts arise from pyramidal cells (of Betz) of the motor area of the cerebral cortex. Some fibres arise from other parts of the cortex.

Course: The fibres pass through corona radiata, internal capsule, crus cerebri of cerebral peduncles, ventral part of the pons, and pyramids of the medulla oblongata. In the lower part of the medulla majority of fibres (about 75%) cross to the opposite side at the pyramidal decussation of the medulla and descend in the lateral white column of the spinal cord as the *lateral corticospinal tract*. The uncrossed fibres descend in the anterior white column of the spinal cord as

the *anterior corticospinal tract*. The lateral corticospinal tract also contains some fibres, which arise from the ipsilateral cerebral cortex.

The lateral corticospinal tract lies in the lateral white column in front of the posterior horn and medial to the posterior spinocerebellar tract. The anterior corticospinal tract lies in the anterior white column close to the anterior median fissure. Lower down the fibres of anterior corticospinal tract also cross to the opposite side in the anterior white commissure of the spinal cord at the level of their termination.

Termination: The most of the fibres of both lateral and anterior corticospinal tracts terminate by synapsing with the interneurons, which in turn project to the motor neurons (α and γ) of the anterior horn. Only 2% of the fibres synapse directly with the motor neurons.

N.B.

- Because of decussation of corticospinal fibres in the medulla (*medullary decussation*), the cerebral cortex of one side controls the muscles of the opposite half of the body.
- As the pyramidal tract traverses the brainstem, the *corticobulbar fibres* supply the motor nuclei of the cranial nerves. Thus the pyramidal tract also includes corticobulbar fibres.

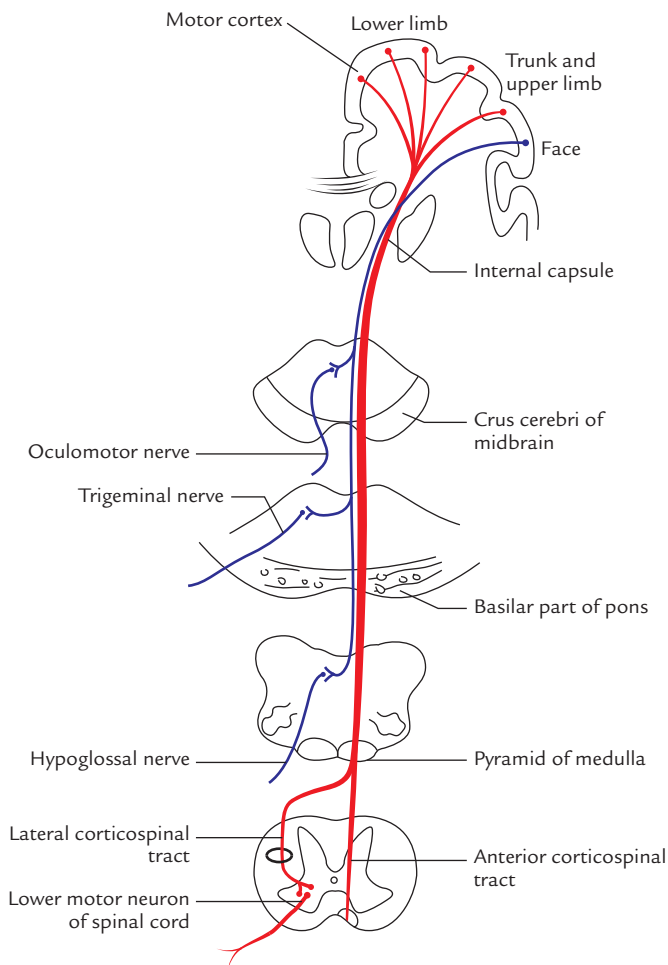


Fig. 20.7 Pyramidal tracts (corticospinal tract is shown in red and corticobulbar in blue color).

Clinical correlation

Effects of lesions of pyramidal tract: The lesions of pyramidal tract above the level of decussation, i.e., *upper motor neuron (UMN) lesions* result in the loss of voluntary movements in the opposite half of the body below the level of the lesion. The muscles are not actually paralyzed but the control on the motor neuron supplying them, i.e., *lower motor neurons (LMN)* is lost. As a result the tone of muscles is increased leading to *spastic paralysis*.

Rubrospinal Tract

The fibres of this tract arise from the cells of the red nucleus (nucleus ruber) located in the midbrain and immediately caudal to red nucleus they decussate with those of the opposite side and descend as a compact bundle in the lateral white column of the spinal cord, ventral to the lateral corticospinal tract. The fibres of this tract end just like those of corticospinal tract in the anterior horn cells of the spinal cord. This tract forms a part of extrapyramidal system.

Rubrospinal tract facilitates the activity of the flexor muscles and inhibits the activity of the extensor antigravity muscles.

Reticulospinal Tract

Lateral reticulospinal tract

This tract lies in the lateral white column. Its fibres arise from cells of the reticular formation in the brainstem (midbrain,

pons, and medulla) and relay in the anterior horn cells. This tract exerts facilitatory influence on the motor neurons, which supply the skeletal muscles.

Medial reticulospinal tract

It lies in the anterior white column. Its fibres arise from the cells of the reticular formation in the medulla and relay in the anterior horn cells of the spinal cord. This tract exerts inhibitory influence on the motor neurons supplying the skeletal muscles.

N.B. The reticulospinal fibres are now thought to be included in descending autonomic fibres. The reticulospinal tracts thus provide a pathway by which the hypothalamus can control the thoracolumbar sympathetic outflow and the sacral parasympathetic outflow.

Hypothalamospinal Tract

It projects from the hypothalamus and descends in the lateral white column of the spinal cord on the medial side of the lateral corticospinal tract and terminates by synapsing with lateral horn cells of T1 to L2 spinal segments responsible for sympathetic outflow, and lateral horn cells of S2, S3, and S4 spinal segments responsible for parasympathetic outflow.

ASCENDING TRACTS

The ascending tracts conduct the impulses from the periphery to the brain through the cord.

The important ascending tracts fall into the following three types:

1. Those concerned with **pain and temperature sensations and crude touch**, e.g., lateral and anterior spinothalamic tracts.
2. Those concerned with **fine touch and conscious proprioceptive sensations**, e.g., fasciculus gracilis and fasciculus cuneatus.
3. Those concerned with **unconscious proprioception and muscular coordination**, e.g., anterior and posterior spinocerebellar tracts.

Lateral Spinothalamic Tract (Fig. 20.8)

The cell bodies of first-order sensory neurons (pseudounipolar neurons) of this tract lie in the dorsal root ganglia of the spinal nerves. The central processes of these cells enter the cord through the lateral division of the dorsal root of the spinal nerves. In the cord, the fibres ascend one or two segments as the **dorsolateral tract of Lissauer** at the tip of posterior horns and then relay in the posterior horn by synapsing with the cells of substantia gelatinosa. The axons of second-order sensory neurons of substantia gelatinosa cross to the opposite side in the anterior white commissure and ascend up as **lateral spinothalamic tract** in the opposite lateral white column just lateral to the anterior horn. They terminate in the **ventral**

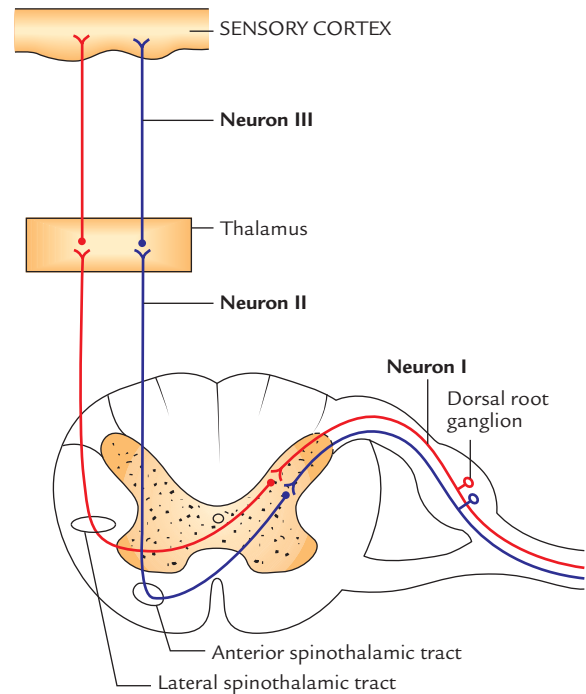


Fig. 20.8 Lateral and anterior spinothalamic tracts.

posterolateral nucleus (VPL) of the thalamus. The sacral, lumbar, thoracic, and cervical fibres are situated in layers in this tract from superficial to deep (somatotrophic organization). The axons of the third-order sensory neurons project to the primary sensory cortex of the cerebral hemisphere.

Clinical correlation

The fibres of this tract carry pain and temperature sensations—the pain fibres being lateral to the temperature. The pain fibres become very superficial in the lateral white column of the cord in the cervical region. Therefore *cordotomy* can be performed safely at this level to relieve pain in the opposite half of the body.

The involvement of decussating fibres of this tract in the anterior commissure in *syringomyelia* leads to bilateral loss of pain and temperature sensations below the level of the lesion.

Anterior Spinothalamic Tract

The cell bodies of the first-order sensory neurons of this tract lie in the dorsal root ganglia of the spinal nerves. The central processes of these cells (large and heavily myelinated) enter the cord through the medial division of the dorsal roots of the spinal nerves and ascend in the cord 1 or 2 segments as the **dorsolateral tract of Lissauer** and relay in the substantia gelatinosa of the posterior horn. The axons of second-order sensory neurons of substantia gelatinosa cross the midline in the anterior white commissure and then ascend as **ventral spinothalamic tract** in the opposite anterior white column

just in front of the anterior horn. These fibres terminate in the ventral posterolateral nucleus of the thalamus (Fig. 20.8).

N.B. The lateral spinothalamic tract carries pain and temperature sensations whereas anterior spinothalamic tract carries sensations of crude touch and pressure.

Clinical correlation

The damage of anterior spinothalamic tract leads to loss of light touch and pressure on the opposite side of the body below the level of the lesion.

Fasciculus Gracilis (Tract of Goll) and Fasciculus Cuneatus (Tract of Burdach)

These two tracts occupy the posterior white column of the cord, the tract of Goll being medial to the tract of Burdach. They carry sensations of **conscious proprioception**, two point tactile discrimination, and vibration. The cell bodies of the first-order sensory neurons lie in the dorsal root ganglia of the spinal nerves. The central processes of these cells (thickly myelinated) enter the cord through the medial division of the roots of spinal nerves and continue in the posterior white column as fasciculus gracilis and fasciculus cuneatus (Fig. 20.9).

Fibres from the coccygeal, sacral, lumbar, and lower thoracic segments ascend up in the tract of Goll, while the

fibres from the upper thoracic and cervical segments run in the tract of Burdach. The cervical, thoracic, lumbar, and sacral fibres are arranged in that order from lateral to medial in these tracts.

The fibres of fasciculus gracilis and fasciculus cuneatus terminate in nucleus gracilis and nucleus cuneatus, respectively. The axons of second-order sensory neurons from nucleus gracilis and nucleus cuneatus curve ventromedially around the central grey matter of the medulla as internal arcuate fibres to undergo decussation. The fibres after crossing the midline turn upwards as a flat tract called **medial lemniscus**, which courses upwards to terminate in the ventral posterolateral nucleus (VPL) of the thalamus. The third-order sensory neurons from thalamus project into the cerebral cortex of the cerebral hemisphere. This pathway carrying conscious proprioceptive sensations is termed '*dorsal column—medial lemniscus pathway*'.

Clinical correlation

The involvement of posterior white columns and posterior nerve roots in syphilitic degenerative disease called *tabes dorsalis* leads to loss of sense of position. The patient is not able to tell the position or movements of his lower limbs unless he sees them. Therefore, when he is asked to stand up with his feet together and eyes closed, he staggers and falls as he cannot maintain his correct position due to lack of proprioceptive information (*Romberg's sign*).

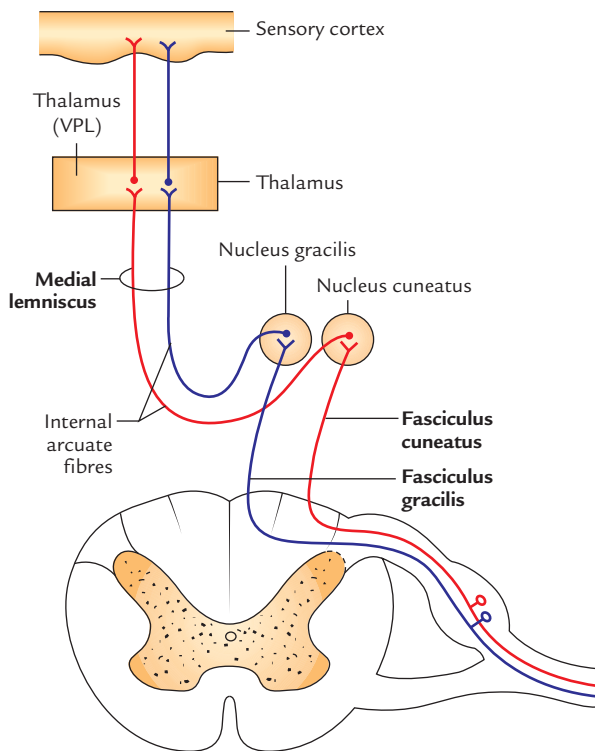


Fig. 20.9 Fasciculus gracilis and fasciculus cuneatus (posterior column—medial lemniscus pathway).

Spinocerebellar Tracts (Fig. 20.10)

The spinocerebellar fibres are located in the lateral white column of the cord and are divided into two tracts: **posterior spinocerebellar tract** and **anterior spinocerebellar tract** according to their location in the cord. They carry unconscious proprioceptive sensations from cord to the cerebellum and play an important role in muscular coordination.

Posterior (dorsal) spinocerebellar tract

The cell bodies of the first-order sensory neurons lie in the dorsal root ganglia of the spinal nerves. The central processes of these cells enter the posterior horn of the grey matter through posterior roots of spinal nerves and relay in the **nucleus dorsalis (Clarke's column)**. The axons from cells of nucleus dorsalis (second-order sensory neurons) pass to the dorsolateral part of the white column on the same side and ascend as *posterior spinocerebellar tract*. The fibres of the tract enter the cerebellum through the inferior cerebellar peduncle and terminate in the ipsilateral cerebellar cortex.

Anterior (ventral) spinocerebellar tract

The origin and course of the first-order sensory neurons is same as that of posterior spinocerebellar tract. The axons

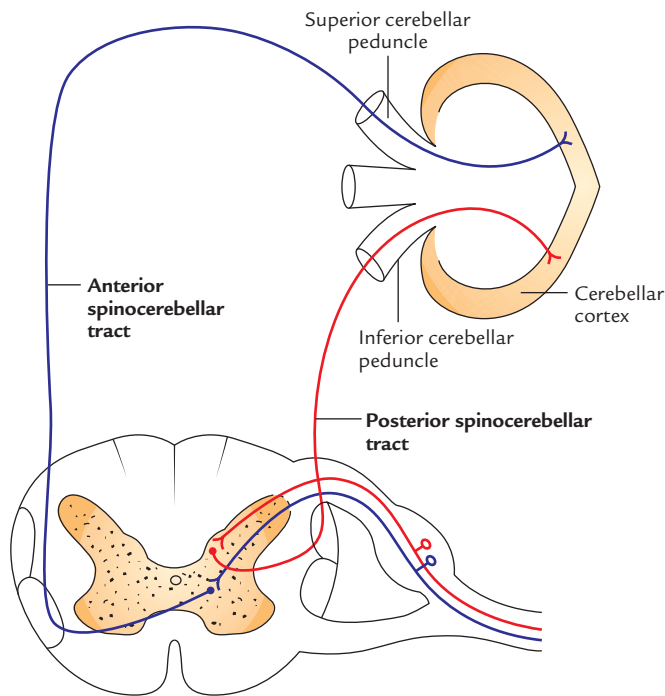


Fig. 20.10 Schematic diagram to show the posterior (red color) and anterior (blue color) spinocerebellar tracts.

of cells of nucleus dorsalis (second-order sensory neurons) cross to the opposite side and pass to the anterolateral part of the lateral white column of the spinal cord and then ascend to form the anterior spinocerebellar tract. The fibres of anterior spinocerebellar tract enter the cerebellum through superior cerebellar peduncle and terminate in the ipsilateral cerebellar cortex.

The input of both posterior and anterior spinocerebellar tracts is ipsilateral.

Functionally, both posterior and anterior spinocerebellar tracts carry impulses from the lower limb. The posterior tract is concerned with fine movements, whereas anterior tract is concerned with gross movements of the limb as a whole.

Clinical correlation

- **Subacute combined degeneration of the spinal cord:** It occurs due to deficiency of vitamin B₁₂. In this condition, the posterior white columns and lateral corticospinal tracts undergo degeneration on both sides. It usually affects the lumbosacral segments. Clinically, it presents with the following signs and symptoms:
 - Bilateral loss of position and vibratory sense.
 - Spastic paraplegia with exaggerated tendon reflexes and positive Babinski's sign.

- **Spinal cord injury:** In *complete transection of spinal cord*, there is loss of movements and all sensations below the level of the injured segment.

In *hemisection of spinal cord (Brown–Séquard syndrome)*, there is ipsilateral spastic paralysis due to lesion of corticospinal tract, contralateral loss of pain and temperature sensations and ipsilateral loss of conscious proprioception and sense of vibration due to lesions of lateral spinothalamic tract and dorsal column-medial lemniscus pathway respectively.

To summarize, the motor impulses travel from the brain to the anterior horn cells of spinal cord through the descending tracts and then out to the periphery via the spinal nerves. The sensory impulses from the periphery travel through spinal nerves into the spinal cord via posterior or dorsal horn and then up the spinal cord to the brain through ascending tracts.

BLOOD SUPPLY

Arterial Supply

The spinal cord is supplied by the following arteries:

1. Anterior spinal artery.
2. Posterior spinal arteries.
3. Segmental arteries.

Anterior spinal artery: The anterior spinal artery is formed by the union of two small spinal branches of the right and left vertebral arteries in the upper cervical canal. It runs caudally in the anterior median fissure of the spinal cord and terminates along the filum terminale.

Posterior spinal arteries: There are two posterior spinal arteries each arising as a small branch from either the vertebral or posterior inferior cerebellar artery. Each posterior spinal artery runs down on the posterolateral aspect of the cord in the posterolateral sulcus along the line of attachment of posterior nerve roots and usually divides into two collateral arteries along the medial and lateral side of the posterior nerve roots. Thus there are five longitudinal arteries around the spinal cord.

These arteries are reinforced by the segmental arteries (feeder arteries) to form five longitudinal arterial trunks. These arterial trunks communicate around the cord forming a pial plexus, the *vasocorona/arteriae coronae*. The *arteriae coronae* give peripheral branches, which supply the superficial regions of the cord.

The anterior spinal artery supplies the anterior two-third of the cord, while two posterior spinal arteries together supply the posterior one-third of the cord.

Clinical correlation

Anterior spinal artery syndrome: It occurs due to occlusion (thrombosis or compression of the anterior spinal artery).

Since the anterior spinal artery supplies anterior two-third of the cord, the occlusion of this artery will result in the following signs and symptoms:

- (a) *Motor symptoms* due to involvement of corticospinal tracts and anterior grey columns.
- (b) *Sensory symptoms (viz. bilateral loss of pain and temperature sensation)* due to ischemia of spinothalamic tracts.

The conscious proprioceptive sensations are preserved because the region of posterior white column is supplied by posterior spinal arteries.

Segmental arteries: The segmental arteries are spinal branches of *deep cervical, ascending cervical, posterior intercostal, lumbar, and lateral sacral arteries*. They reach the spinal cord as the anterior and posterior radicular arteries along the corresponding roots of the spinal nerves, respectively. They mainly nourish the nerve roots.

The largest segmental (radicular) arteries at the 1st (T1) and 11th thoracic (T11) segmental levels are often termed *arteria radicularis magna* (arteries of Adamkiewicz).

Venous Drainage

The veins draining the cord form six longitudinal venous channels around the cord, *viz:*

1. **Two median longitudinal**, one in the anterior median fissure and the other in the posteromedian sulcus.
2. **Two anterolateral**, one on either side, posterior to the anterior nerve roots.
3. **Two posterolateral**, one on either side, posterior to the posterior nerve roots.

These longitudinal venous channels communicate with the **internal vertebral venous plexus** and drained by veins, which leave through the intervertebral foramina to empty into the vertebral, posterior intercostal, lumbar, and lateral sacral veins.

The internal vertebral venous plexus communicates above with the basilar venous plexus.

Golden Facts to Remember

- | | |
|---|--|
| ▶ Most important descending tract of the spinal cord | Corticospinal tracts (pyramidal tract) |
| ▶ Most important ascending tracts of the spinal cord | Lateral and anterior spinothalamic tracts |
| ▶ Cauda equina | Leash of spinal nerve roots around filum terminale arising from conus medullaris, resembling the tail of a horse |
| ▶ Largest artery supplying the spinal cord | Anterior spinal artery |
| ▶ Artery supplying the most of the substance of spinal cord | Anterior spinal artery supplying anterior two-third of the cross sectional area of the spinal cord |
| ▶ Positional changes in the developing spinal cord | – In fetus: S2 vertebra (lower border)
– At birth: L3 vertebra (lower border)
– In adult: L1 vertebra (lower border) |
| ▶ All the sensory ganglia (spinal ganglia) of spinal nerves lie in the intervertebral foramina except | First two cervical, sacral, and coccygeal spinal nerves |
| ▶ Most susceptible spinal segments to ischemic necrosis if segmental arteries are occluded | T4 and L1 spinal segments |

Clinical Case Study



A 47-year-old patient went to a neurologist and complained to him of motor and sensory symptoms, which he had noticed in the last few months. After thorough neurological examination, he was diagnosed as a case of *subacute combined degeneration of the spinal cord*.

Questions

1. What is the cause of subacute combined degeneration of the spinal cord?
2. Name the main tracts, which undergo degeneration in this condition.
3. Mention the characteristic signs and symptoms of this condition.
4. Which spinal segments are usually affected in this condition?

Answers

1. Deficiency of vitamin B₁₂.
2. Fasciculus gracilis, fasciculus cuneatus, and lateral corticospinal tracts.
3. (a) Bilateral loss of position and vibratory sense below the level of lesion.
(b) Spastic paralysis with exaggerated tendon reflexes and positive Babinski sign.
4. Lumbosacral segments.

Cranial Cavity

The cranial cavity is the main cavity of the skull. It lodges the brain, meninges, portions of the cranial nerves, and blood vessels. It is roofed over by the skull cap and its floor is formed by the upper surface of the base of the skull (Fig. 21.1).

SKULL CAP (CALVARIA)

The skull cap or the vault of the skull forms the roof of the cranial cavity. It is made up of superior portions of frontal, parietal, and occipital bones.

External surface: The external surface of the skull cap or calvaria has been described in Chapter 2.

Internal surface (Fig. 21.2): The internal surface appears as an ovoid hollow plate of bone and presents the following features (Fig. 21.2):

1. **Coronal, sagittal, and lambdoid sutures.**
2. **Sagittal sulcus:** It is an anteroposterior groove in the median plane which lodges the superior sagittal sinus. When traced posteriorly, it becomes wider and at internal occipital protuberance, it becomes continuous with the right transverse sulcus.
3. **Granular pits:** These are numerous irregular depressions on each side of the sagittal sulcus which lodge **arachnoid granulations**. They are more prominent in skulls of elderly people.
4. **Vascular grooves:** These are produced by the terminal branches of middle meningeal vessels. Groove for the anterior branch is located behind the coronal suture, whereas that for the posterior (parietal) branch is more posteriorly placed.

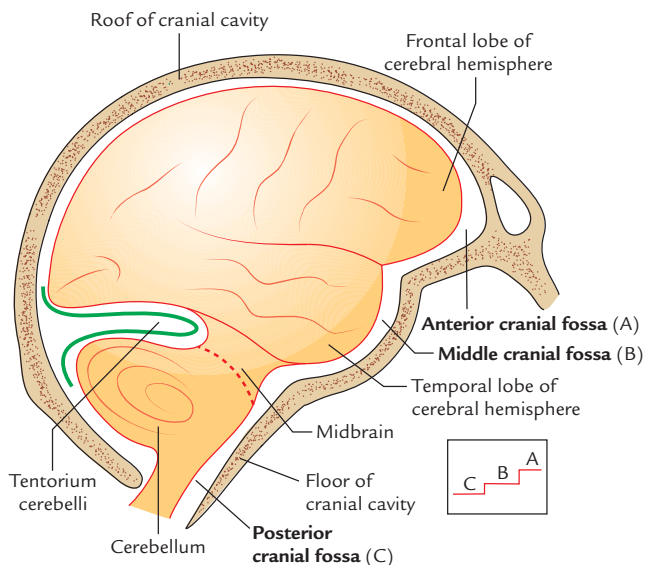


Fig. 21.1 Parasagittal section of skull showing anterior, middle, and posterior cranial fossae. The inset shows the levels of anterior, middle, and posterior cranial fossae akin to three terraces with descending levels.

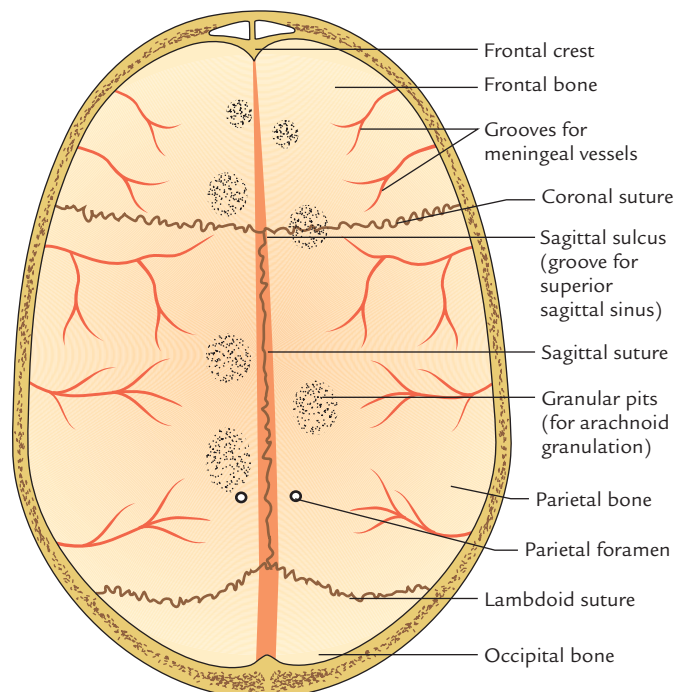


Fig. 21.2 Internal surface of the vault of the skull (calvaria).

The terminal branches of middle meningeal artery are separated from bone by their corresponding veins; hence, the vascular grooves are mostly produced by the veins rather than by the arteries.

5. **Parietal foramina:** It is one on each side close to the sagittal sulcus about 3.5 cm in front of the lambda.
6. **Impression for cerebral gyri:** They are rather less marked as compared to those on the internal surface of the base of the skull.

STRUCTURE

The bones of skull cap (cranial vault) consist of outer and inner layers/plates of compact bone (generally called outer and inner tables) with an intervening layer of the spongy bone called **diploë**.

N.B. In children, the bones of cranial vault are made of a single layer of the compact bone.

The outer table is thick, resilient, and tough, whereas the inner table is thin and brittle. The blows on head may cause fractures of either one or both the tables. When the inner table is fractured, it has tendency to shatter and can lacerate the underlying vessels within the dura mater. The diploë is filled with red bone marrow.

DIPLOIC VEINS

The blood from the diploë is drained by diploic veins (Fig. 21.3). These veins drain mostly into the intracranial dural venous sinuses. They lack valves and communicate with the veins draining the scalp that clothe the cranial vault. The recognizable diploic veins are usually four on each side and descend almost vertically to open into the nearest convenient venous sinus. These are as follows:

1. A **frontal diploic vein** that emerges from the bone in the supraorbital foramen to join the supraorbital vein.
2. An **anterior temporal (parietal) diploic vein** that pierces the greater wing of the sphenoid to join the sphenoparietal sinus or the anterior deep temporal vein.
3. A **posterior temporal (parietal) diploic vein** that pierces the inner table in the parietomastoid angle to join the transverse sinus.
4. An **occipital diploic vein** (the largest) that pierces the inner table near the internal occipital protuberance to join the transverse sinus near the confluence of sinuses or into an occipital emissary vein.

FLOOR OF THE CRANIAL CAVITY

The floor of the cranial cavity is divisible into three descending 'steps' by two sharp bony ridges on each side, viz. the posterior free border of the lesser wing of the

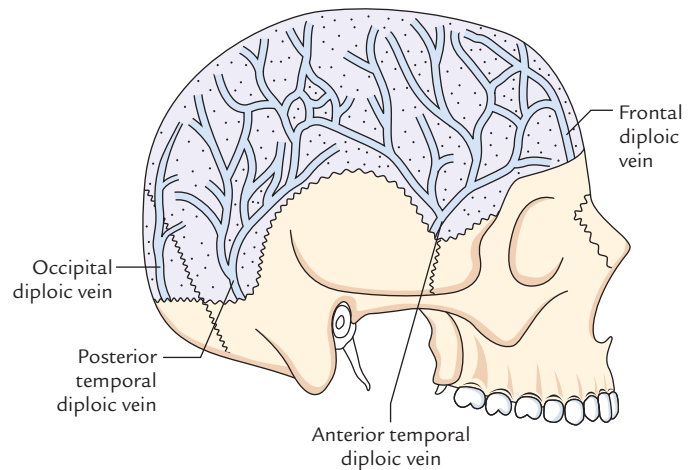


Fig. 21.3 Diploic veins displayed by the removal of the outer table of the vault of the skull.

sphenoid (**sphenoidal ridge**) in front, and the sharp superior border of the petrous temporal bone (**petrous ridge**) behind (Fig. 21.4).

The three steps are known as the **anterior, middle, and posterior cranial fossae**. Thus, the anterior cranial fossa is at the highest level, the posterior cranial fossa at the lowest level, and the middle cranial fossa at the middle level.

The internal surface of the base of the skull is divided into the anterior, middle, and posterior cranial fossae. They are arranged like three terraces with descending levels (Fig. 21.1 inset).

ANTERIOR CRANIAL FOSSA

The anterior cranial fossa lodges the frontal lobes of the cerebral hemispheres. Its floor is composed of the portions of the following three bones: ethmoid, frontal, and sphenoid (Fig. 21.4). It is demarcated from the middle cranial fossa by the:

- (a) posterior free border of the lesser wing of sphenoid on each side, and
- (b) anterior border of the sulcus chiasmaticus in the median region.

The junction between these two is marked by the anterior clinoid process.

Features

The anterior cranial fossa presents the following features:

1. In the **median region**, from before backward these are:
 - (a) *Frontal crest*, a vertical crest on the inner aspect of the frontal bone.
 - (b) *Foramen cecum* (in between the frontal crest and crista galli).

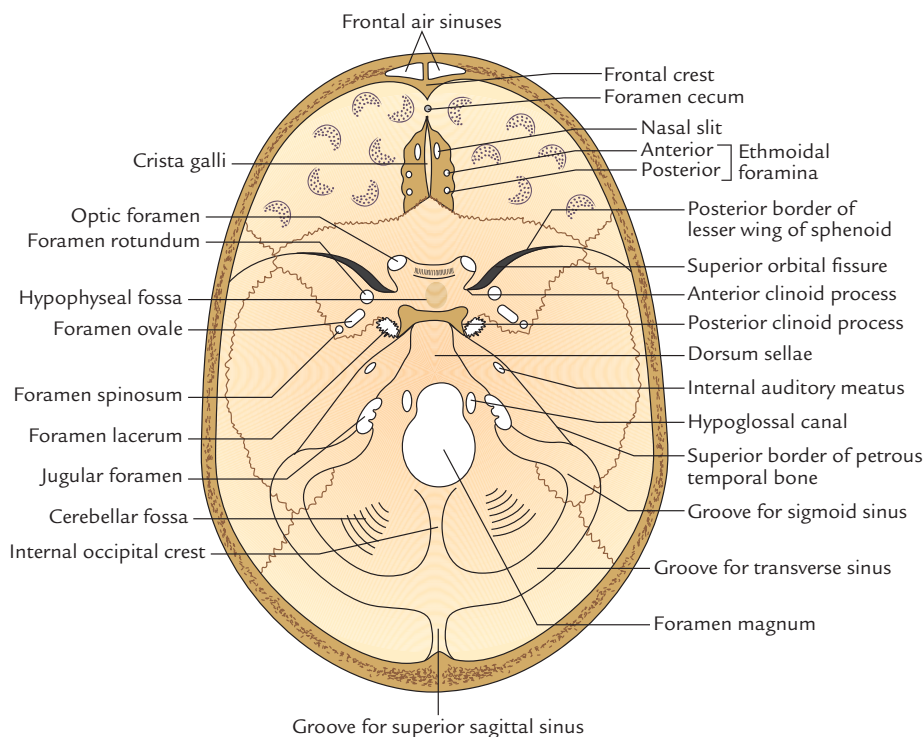


Fig. 21.4 Floor of the cranial cavity (the internal surface of the base of the skull).

- (c) *Crista galli*, a cock's comb-like bony crest, formed by the perpendicular plate of the ethmoid.
- (d) *Jugum sphenoidale* (the superior surface of the anterior part of the body of the sphenoid).
- (e) On each side of crista galli lies the sieve-like *cribriform plate of the ethmoid* which separates the anterior cranial fossa from the nasal cavity. It possesses:
- a number of small foramina, to provide passage for 15–20 filaments of the olfactory nerve,
 - nasal slits one on either side of crista galli to provide passage to the anterior ethmoidal nerve, and
 - an anterior ethmoid canal along the lateral border anteriorly and a posterior ethmoidal canal along the lateral border posteriorly to provide passage to the anterior and posterior ethmoidal nerve and vessels.
2. In the **lateral region** on either side, the orbital plate of the frontal bone separates the anterior cranial fossa from the orbit and supports the frontal lobe of the brain with consequent impressions of sulci and gyri.

Structures Passing Through Various Foramina in the Anterior Cranial Fossa

Foramen cecum

Emissary vein from the nasal mucosa to the anterior end of the superior sagittal sinus if foramen is patent.

Cribriform Foramina

Olfactory nerves surrounded by leptomeninges (pia and arachnoid maters): from the olfactory epithelium of the nasal cavity to the olfactory bulb in the anterior cranial fossa.

Anterior Ethmoidal Foramen

1. Anterior ethmoidal nerve: a branch of the nasociliary nerve.
2. Anterior ethmoidal artery: a branch of the ophthalmic artery.
3. Anterior ethmoidal vein: a tributary of the ophthalmic vein.

Posterior Ethmoidal Foramen

1. Posterior ethmoidal nerve: a branch of the nasociliary nerve.
2. Posterior ethmoidal artery: a branch of the ophthalmic artery.
3. Posterior ethmoidal vein: a tributary of the ophthalmic vein.

Clinical correlation

Foramen cecum may transmit an emissary vein from the nasal cavity to the superior sagittal sinus and then serve as a potential route for nasal infections to spread to the meninges of the cranial cavity.

MIDDLE CRANIAL FOSSA

Floor of the Middle Cranial Fossa (Fig. 21.4)

The floor of the middle cranial fossa resembles a butterfly—consisting of a small median part and an expanded lateral part on each side.

The middle cranial fossa is demarcated from the anterior cranial fossa by:

- the posterior free border of the lesser wing of the sphenoid on each side, and
- the limbus sphenoidalis in the median region. The limbus is an anterior edge of shallow transverse area called **sulcus chiasmaticus**.

The middle cranial fossa is demarcated from the posterior cranial fossa by:

- the superior border of the petrous temporal bone on each side, and
- the dorsum sellae (a rectangular plate of bone) in the median region.

Median Part of the Middle Cranial Fossa

The median part of the fossa is formed by the body of the sphenoid, which is more or less cuboidal.

The median region, from before backward, presents the following features:

- Sulcus chiasmaticus**, leading on each side into the optic canal which leads into the orbit.
- Sella turcica (Turkish saddle)**. It is the hollowed out upper surface of the body of the sphenoid (*hypophyseal fossa*) bounded in front by the tuberculum sellae—the posterior edge of sulcus chiasmaticus—and behind by the dorsum sellae. The lateral ends of the tuberculum sellae bear the middle clinoid processes and the lateral ends of the dorsum sellae bear the posterior clinoid processes.

The sella turcica consists of three parts: the tuberculum sellae, the hypophyseal fossa, and the dorsum sellae. The hypophyseal fossa is occupied by the pituitary gland in life.

The **carotid groove** is a shallow sulcus on either side of the body of the sphenoid lateral to the hypophyseal fossa. It begins at the foramen lacerum, runs upward, then forward, and finally upward again to end at the medial to the anterior clinoid process. The passage of internal carotid artery occupies this groove.

Sometimes the middle and anterior clinoid processes are united by a bony bar forming **caroticoclinoid foramen** for the passage of internal carotid artery.

N.B. The median part (region) of the middle cranial fossa is likened to a bed with four clinoid processes representing the four bed-posts (Gr. *Kline* = a bed).

Lateral Part of the Middle Cranial Fossa

The lateral part of the middle cranial fossa on each side is formed by the upper surface of the greater wing of the sphenoid together with the anterior surface of the petrous temporal bone and the squamous part of the temporal bone. It lodges the temporal lobe of the cerebral hemisphere.

It is limited in front by sharp posterior border of the lesser wing of the sphenoid, and behind by sharp upper border of the petrous temporal bone. These bony ridges are related to the sphenoparietal and superior petrosal sinuses respectively.

Greater Wing of the Sphenoid

The greater wing of the sphenoid presents:

- Four foramina** arranged roughly in a semicircular array (Fig. 21.5). From behind forward these are as follows:
 - Foramen spinosum* is posteriormost and located at the posterior tip of the greater wing. It is so called because on the undersurface of the greater wing at this point is the **spine of sphenoid**.
 - Foramen ovale* is located just in front and medial to the foramen spinosum. The reason for its name is obvious.
 - Foramen rotundum* is in front and medial to the foramen ovale. It leads downward and forward into the pterygopalatine fossa.
 - Superior orbital fissure* (an elongated triangular fissure) is in front and lateral to foramen rotundum under the overhanging shelf of the lesser wing of the sphenoid. *It is actually located between the body, lesser wing, and greater wing of the sphenoid.*

Of these four openings, however, only the first two can be seen on the inferior surface of the base of the skull.

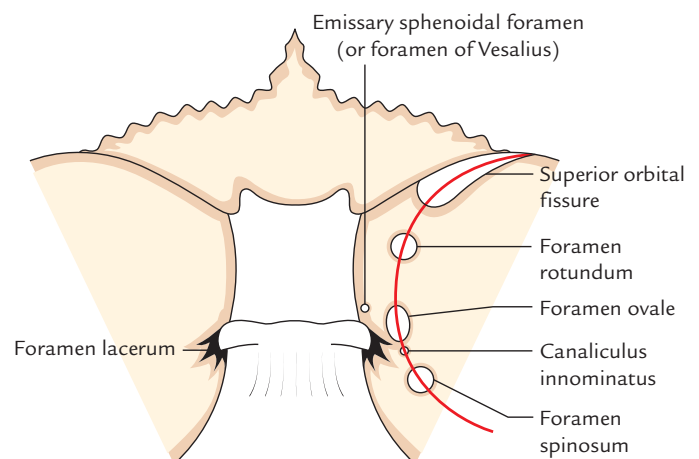


Fig. 21.5 The four foramina in the greater wing of the sphenoid are present along a **crescentic line**.

N.B. In addition to the four foramina, sometimes two more foramina are present in the greater wing of the sphenoid. These are:

- *Emissary sphenoidal foramen (of Vesalius)*: It lies medial to foramen ovale and conveys an emissary vein from the cavernous sinus.
- *Canaliculus innominatus*: It is located on a bar of bone between the foramen ovale and foramen spinosum. It transmits the lesser petrosal nerve when the latter does not pass through foramen ovale.

2. **Groove for middle meningeal vessels leads forward from the foramen spinosum**: After a short distance, the groove divides into the anterior and posterior grooves, which lodge the anterior and posterior branches of middle meningeal vessels. The anterior groove continues to the pterion and then arches upward and backward across the parietal bone. At the pterion, the groove may be converted into a *bony-tunnel*, thereby increasing the possibility of tearing the middle meningeal vessels in trauma on the side of the skull in the pterion region.

The posterior groove passes backward across the squamous part of the temporal bone.

3. **Foramen lacerum** lies at the posterior end of the carotid groove on the side of the body of the sphenoid, posteromedial to the foramen ovale. It is actually a gap between the petrous temporal and sphenoid bones.
4. **Anterior surface of the petrous temporal bone** presents the following five features:
 - (a) **Trigeminal impression**, a shallow depression medially near the apex of the bone. The trigeminal ganglion lies on this depression.
 - (b) **Hiatus and groove for the greater petrosal nerve**: In front of arcuate eminence, a slit or hiatus for the greater petrosal nerve is continued as a groove to the foramen lacerum.
 - (c) **Hiatus and groove for the lesser petrosal nerve** lie lateral to hiatus and groove for the greater petrosal nerve and lead to the foramen ovale or canaliculus innominatus, if present.
 - (d) **Arcuate eminence** (a rounded elevation) produced by the underlying superior semicircular canal is located at the middle of the anterior surface of the petrous temporal bone.
 - (e) **Tegmen tympani**, a thin plate of bone anterolateral to the arcuate eminence. It forms the roof of middle ear (tympanic cavity). Its anterior part turns downward into the squamotympanic fissure.

The inner surface of the squamous part of the temporal bone is grooved by the middle meningeal artery and its terminal anterior and posterior branches.

Structures Passing Through Various Canals and Foramina in the Middle Cranial Fossa

Optic Foramen

1. **Optic nerve**: along with its sheath of meninges, i.e., dura mater, arachnoid mater, and pia mater.
2. **Ophthalmic artery**: a branch of cerebral part of the internal carotid artery.
3. **Sympathetic plexus around the ophthalmic artery**.

Superior Orbital Fissure (Fig. 21.6)

This fissure is divided into three parts by means of the *common tendinous ring of Zinn*.

1. **Structures passing through the part present within the common tendinous ring**:
 - (a) Superior and inferior divisions of the oculomotor (3rd cranial) nerve.
 - (b) Nasociliary nerve: It lies between the two divisions of the oculomotor nerve.
 - (c) Abducent (6th cranial) nerve: It lies lateral to the nasociliary nerve.
 - (d) Sympathetic root of the ciliary ganglion: It lies between the nasociliary nerve and the lower divisions of the oculomotor nerve.
2. **Structures passing through the part present above and lateral to the common tendinous ring**:
 - (a) Trochlear (4th cranial) nerve
 - (b) Frontal nerve
 - (c) Lacrimal nerve
 - (d) Lacrimal artery
 - (e) Superior ophthalmic vein
 - (f) Recurrent meningeal branch of lacrimal artery.
3. **Structures passing through the part present below and medial to the common tendinous ring**:

Inferior ophthalmic vein

Foramen rotundum

- (i) Maxillary nerve.
- (ii) Emissary vein.

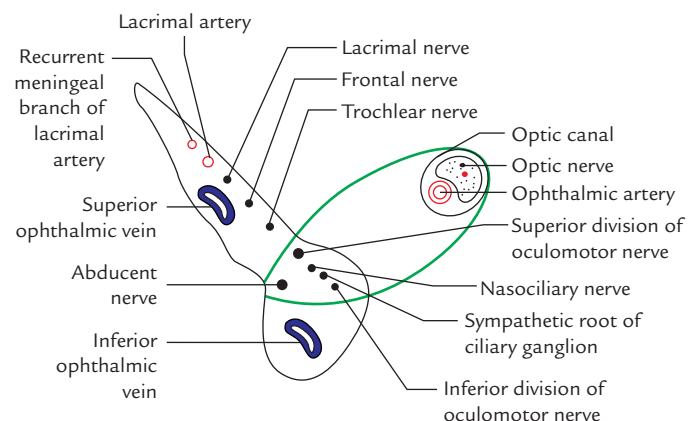


Fig. 21.6 Structures passing through the superior orbital fissure.

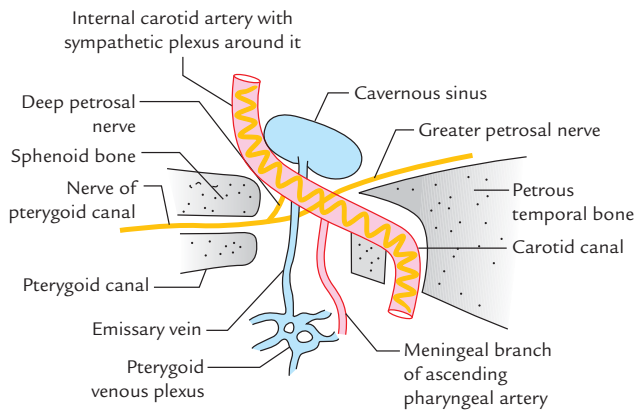


Fig. 21.7 Structures passing through the foramen lacerum.

Foramen ovale (Mnemonic: MALE)

- (i) Mandibular nerve.
- (ii) Accessory middle meningeal artery.
- (iii) Lesser petrosal nerve.
- (iv) Emissary vein: connecting the pterygoid venous plexus to the cavernous sinus.

Foramen spinosum

- (i) Middle meningeal artery.
- (ii) Nerves spinosus.

Foramen lacerum (Fig. 21.7)

- (i) Meningeal branch of the ascending pharyngeal artery.
- (ii) Emissary vein: from the cavernous sinus to the pharyngeal venous plexus.
- (iii) Internal carotid artery along with the sympathetic plexus around it enters it from behind and exists above.
- (iv) Greater petrosal nerve enters from posterolateral aspect and leaves anteriorly as a nerve of pterygoid canal.

N.B. Internal carotid artery and greater petrosal nerve do not pass through and through foramen lacerum.

The greater petrosal nerve joins the deep petrosal nerve derived from the sympathetic plexus around the internal carotid artery to form the nerve of the pterygoid canal (Vidian's nerve) which passes through the pterygoid canal. The posterior orifice of the pterygoid canal lies in the lower part of the anterior wall of the foramen lacerum.

Clinical correlation

Fracture of middle cranial fossa: The middle cranial fossa is the commonest site of fracture of the base of the skull. It is partly because of its position but also because it is weakened by numerous foramina and canals. In fracture of the middle cranial fossa, the tegmen tympani is usually fractured and the tympanic membrane is torn. As a result, there is *bleeding from the external acoustic meatus* and a leakage of cerebrospinal fluid (called *cerebrospinal otorrhea*).

The facial and vestibular cochlear nerves may be damaged. Bleeding may occur through nose and mouth if the body of the sphenoid is fractured. Vertigo may occur if semi-circular canals are involved.

POSTERIOR CRANIAL FOSSA (Fig. 21.4)

The posterior cranial fossa is the deepest of all cranial fossae and lies behind the superior border of the petrous temporal bone and the dorsum sellae of the sphenoid.

It is formed by portions of the sphenoid, temporal, parietal, and occipital bones. It lodges the hindbrain consisting of cerebellum, pons, and medulla oblongata. The posterior cranial fossa is limited above by the tentorium cerebelli (a wide tent-shaped fold of the dura mater) which intervenes between the occipital lobes of the cerebral hemispheres above and the cerebellum below.

Features

1. **The median area** presents the following features:
 - (a) *Clivus*, a sloping surface in front of foramen magnum, formed by the fusion of the posterior part of the body of sphenoid with the basilar part of the occipital bone. It is separated from the petrous temporal bone by petro-occipital fissure which ends posteriorly at *jugular foramen*.
 - (b) *Foramen magnum*, the largest foramen of the skull, is present in the lowest part of the posterior cranial fossa.

On each side of the foramen magnum a little above the lateral margin of its anterior part lies the *hypoglossal canal*.
2. **The squamous part of the occipital bone** shows the following features:
 - (a) *Internal occipital crest*: It is a vertical bony ridge, running downward from the internal occipital protuberance to the foramen magnum.
 - (b) *Internal occipital protuberance*: It is located opposite to the external occipital protuberance.
 - (c) *Grooves for the transverse and sigmoid sinuses*: The grooves for the transverse sinus, one on either side, run laterally from the internal occipital protuberance to the mastoid angle of the parietal bone where it becomes continuous with the groove for the sigmoid sinus which ends into the posterior part of the jugular foramen.
 - (d) *Cerebella fossa* on each side lies between the transverse and sigmoid grooves and the foramen magnum.
 - (e) *Fossae for occipital lobes* one on each side lie above the groove for the transverse sinus.

3. The **posterior surface of the petrous bone** presents the following features:
 - (a) *Internal acoustic (auditory) meatus*: It is a bony canal in the center of the posterior surface, lying almost directly medial to the external acoustic meatus. The meatus is about 1 cm in length.
 - (b) *Subarcuate fossa*, an indistinct depression lateral and superior to the internal acoustic meatus. It contains dural fold and some blood vessels.
 - (c) *Aqueduct of vestibule*, a slit behind the internal acoustic meatus. It transmits the endolymphatic duct of the internal ear.
 - (d) *Cochlear canaliculus*, a notch in the lower border of the posterior surface of the petrous bone, just above the anterior end of the jugular foramen. It lodges the cochlear canal.

N.B. The posterior surface of the petrous temporal bone is triangular and has three borders: superior, inferior, and posterior. Each border is related to a dural venous sinus: the superior border to the superior petrosal sinus, the inferior border to the inferior petrosal sinus, and the posterior border to the sigmoid sinus.

Structures Passing Through Various Foramina and Canals in the Posterior Cranial Fossa

Internal auditory meatus

1. Seventh cranial (facial) nerve.
2. Eighth cranial (vestibulo-cochlear) nerve.
3. Nervus intermedius.
4. Internal auditory (labyrinthine) vessels.

Jugular foramen (Fig. 21.8)

It may be divided into three parts: anterior, middle, and posterior.

1. **Anterior part**: Inferior petrosal sinus.
2. **Middle part**: In the anteroposterior direction.
 - (a) Ninth cranial (glossopharyngeal) nerve.
 - (b) Tenth cranial (vagus) nerve.
 - (c) Eleventh cranial (accessory) nerve.

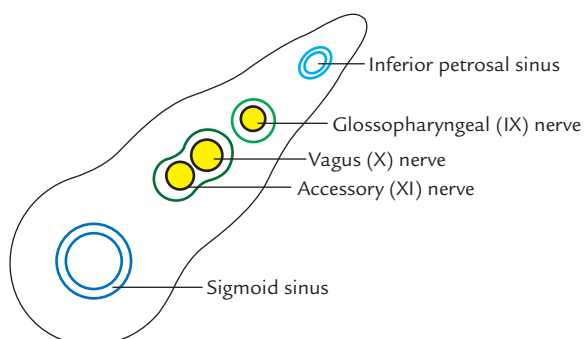


Fig. 21.8 Structures passing through the jugular foramen.

The tenth and eleventh cranial nerves are surrounded in a common sheath of the dura mater, whereas the 9th cranial nerve has an independent sheath of the dura mater.

3. **Posterior part**: Sigmoid sinus.

Hypoglossal (anterior condylar) canal

1. Twelfth cranial (hypoglossal) nerve.
2. Meningeal branch of the ascending pharyngeal artery.

Posterior condylar canal (only sometimes present in the lower part of the sigmoid groove)

1. Emissary vein: connecting the suboccipital venous plexus to the sigmoid sinus.
2. Meningeal branch of the occipital artery.

Foramen magnum (Fig. 21.9)

It is divided into small anterior and large posterior compartments by means of alar ligaments of axis vertebra:

1. **Anterior compartment**:
 - (a) Apical ligament of dens.
 - (b) Upper longitudinal band of the cruciform ligament of atlas.
 - (c) Membrana tectoria: a continuation of the posterior longitudinal ligament of the vertebral bodies.
2. **Posterior compartment**:
 - (a) Medulla oblongata: along with its meninges, i.e., dura mater, arachnoid mater, and pia mater.
 - (b) Two posterior spinal arteries (right and left).
 - (c) Anterior spinal artery.
 - (d) Communicating veins between the internal vertebral venous plexus and the basilar venous plexus.
 - (e) Two vertebral arteries (right and left).
 - (f) Sympathetic plexus around the vertebral arteries: this plexus consists of postganglionic sympathetic fibres derived from the inferior cervical sympathetic ganglion.
 - (g) Spinal roots of two accessory nerves (right and left).

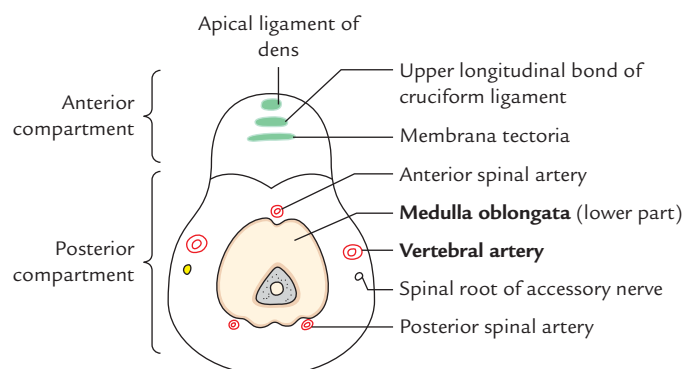


Fig. 21.9 Structures passing through the foramen magnum.

N.B. Tonsils of cerebellum project on each side of the medulla oblongata into the large posterior part of the foramen magnum.

Clinical correlation

The hemorrhage in the posterior cranial fossa does not become evident at once, unless the basilar part of the occipital bone is fractured and the mucous membrane of the pharyngeal roof is torn.

CRANIAL CAVITY AND MENINGES

The interior of the cranial cavity is lined by the dura mater and the surface of brain is covered by the pia mater. Between these two lies the arachnoid mater. These three membranes together constitute the **meninges** of the brain.

The arachnoid mater is connected to the pia mater by many fine filamentous processes. These two membranes are held together and closely associated with the brain, and therefore, discussed with the brain.

DURA MATER

The cerebral dura mater (also called **cranial dura**) is a strong fibrous membrane consisting of two layers: outer endosteal and inner meningeal layers. The two layers are fused with each other except where they enclose venous sinuses (Fig. 21.10).

Outer Layer (or Endosteal Layer)

The outer layer is really the periosteum lining the inner surfaces of the skull bones and is commonly referred to as **endocranium**. It presents the following features:

1. It is continuous with the periosteum (pericranium) on the outer surface of the skull through sutures and the foramina of the skull. It is also continuous with the periosteal lining (periorbita) of the orbit through superior orbital fissure.
2. It provides sheaths for cranial nerves, which fuse with epineurium. The dural sheath around the optic nerve fuses with the sclera of the eyeball.
3. It is loosely attached to the inner surface of the vault of the skull by numerous fibrous and vascular processes; however, it is firmly attached to the base of the skull along the sutures and around the margin of the foramen magnum. As a result, it is easily stripped from the vault of the skull but not from the base of the skull.
4. Meningeal vessels pass through this layer to supply the bone.

Inner Layer (or Meningeal Layer)

The inner layer is really the dura mater proper. It encloses the brain and at the foramen magnum becomes continuous with

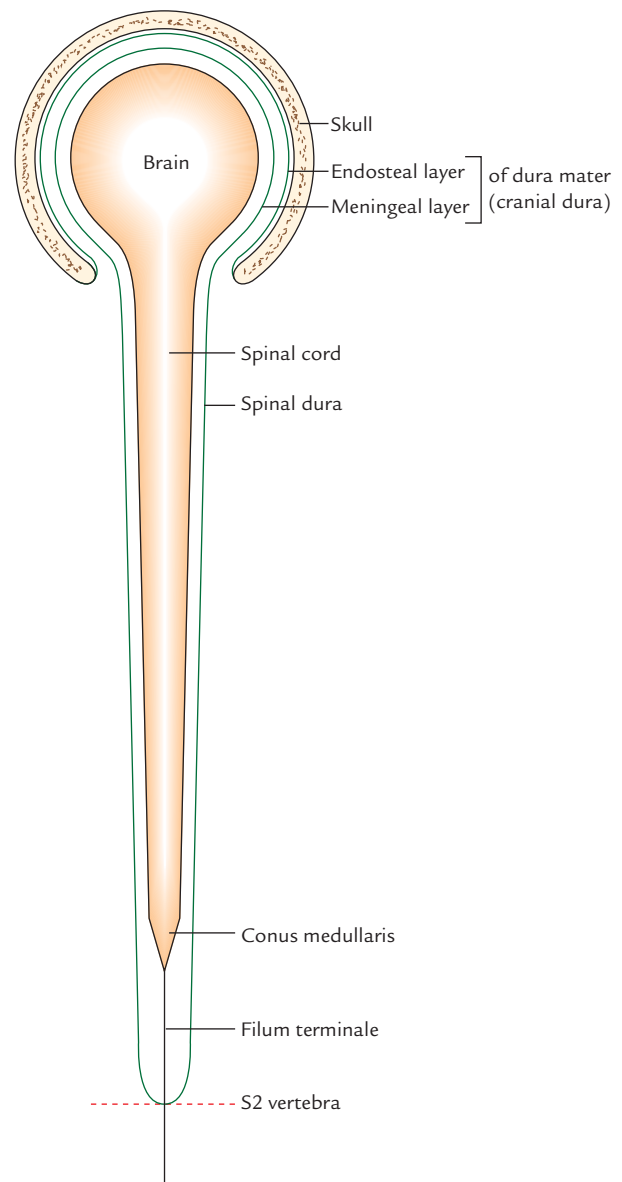


Fig. 21.10 Cranial and spinal dura.

the dura mater surrounding the spinal cord (i.e., spinal dura). It is separated from the arachnoid mater by a *subdural space*.

At places, the meningeal layer is folded on itself to form **dural folds** (also called dural septa). The dural folds project into the cranial cavity and divide it into compartments which lodge the different parts of the brain (Fig. 21.11).

Folds of the Dura Mater

The folds of the dura mater are as follows:

1. Falx cerebri.
2. Tentorium cerebelli.
3. Falx cerebelli.
4. Diaphragma sellae.

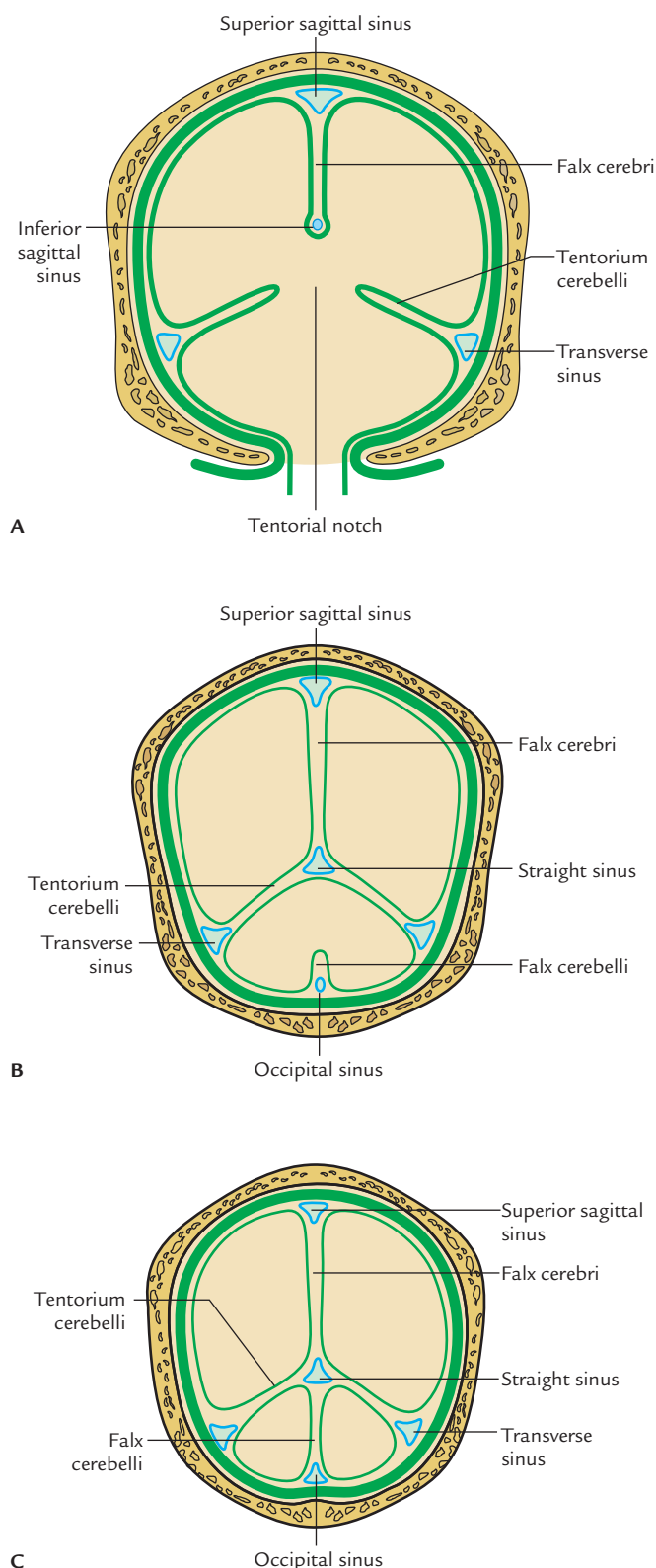


Fig. 21.11 Coronal section through the posterior cranial fossa showing dural folds and dural venous sinuses enclosed in them: **A**, section through the anterior part; **B**, section through the middle part; **C**, section through the posterior part.

Falx cerebri (Fig. 21.12)

1. It is a large sickle-shaped fold of the dura mater occupying the median longitudinal fissure between the two cerebral hemispheres.
2. Its narrow anterior end is attached to the crista galli and the broad posterior end on to the upper surface of the tentorium cerebelli along the median plane.
3. Its convex upper margin is attached to the lips of the sagittal sulcus of the skull vault and its lower concave margin is free and lies just above the corpus callosum.

Venous sinuses enclosed in the falx cerebri (Fig. 21.12)

1. Superior sagittal sinus is enclosed within the convex upper border.
2. Inferior sagittal sinus is enclosed within the lower concave margin.
3. Straight sinus lies along the line of attachment of the falx cerebri with the tentorium cerebelli.

Tentorium cerebelli (Fig. 21.13)

It is a tent-shaped fold of the dura mater forming the roof of the posterior cranial fossa. It separates the cerebellum from the occipital lobes of the cerebrum. It has two margins and two surfaces.

Margins

1. The *inner free margin* is U-shaped and encloses the tentorial notch (incisure) for the passage of the midbrain. The anterior ends of the concave free margin are attached to the anterior clinoid processes.
2. The outer attached margin is convex and attached on each side (from before backward) to the posterior clinoid process, the posteroinferior angle of the parietal bone, and the lips of transverse sulci on the occipital bone.

The free and attached margins cross each other near the apex of the petrous temporal bone to enclose a triangular area anteriorly which is pierced by the oculomotor nerve.

Surfaces

1. The convex upper surface slopes to either side from the median plane. In the median plane, it provides attachment to falx cerebri.
2. The concave inferior surface provides attachment to falx cerebelli in its posterior part.

N.B. *Trigeminal or Meckel's cave* (Fig. 21.14): It is a recess of the dura mater present in relation to the attached outer margin of the tentorium cerebelli.

It is formed by the evagination of the meningeal layer of the dura mater by two roots of the trigeminal nerve below the

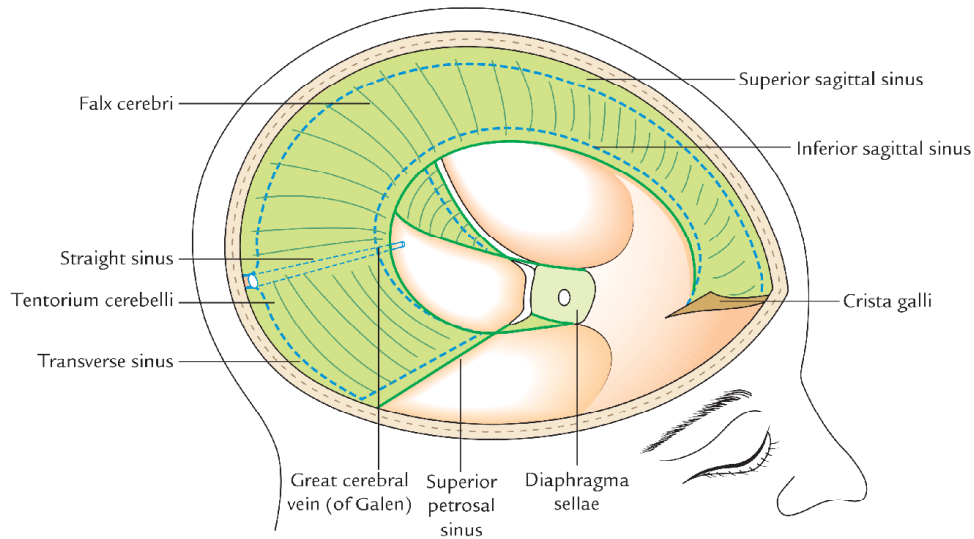


Fig. 21.12 Dural folds and dural venous sinuses enclosed within them, viewed from superolateral aspect.

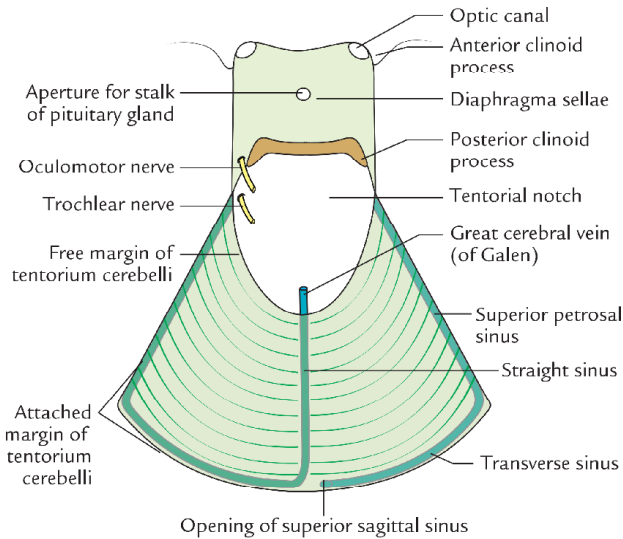


Fig. 21.13 Tentorium cerebelli as seen from above.

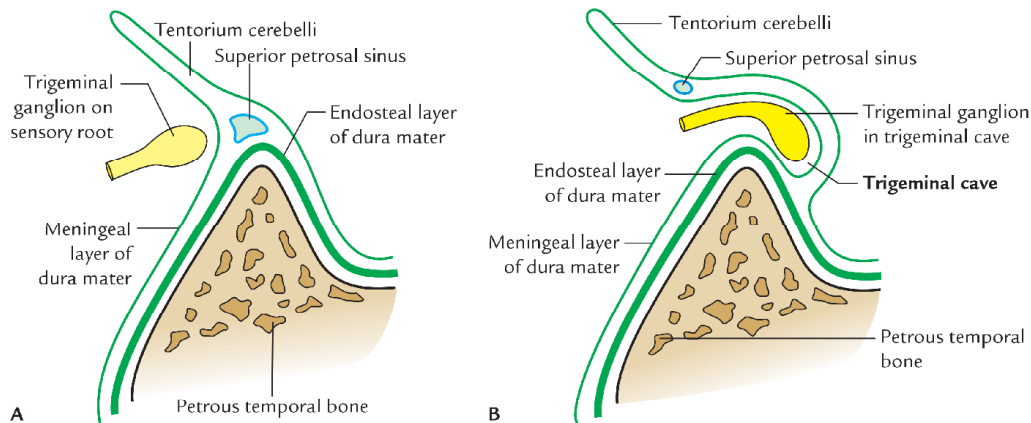


Fig. 21.14 Formation of trigeminal cave: A, before invagination of the meningeal layer of the dura mater; B, after invagination of the meningeal layer of the dura mater to form Meckel's cave (cavum trigeminale).

superior petrosal sinus over the trigeminal impression on the anterior surface of the petrous temporal bone near its apex.

Venous sinuses enclosed in the tentorium cerebelli

1. Transverse sinus, within the posterior part of the attached margin.
2. Superior petrosal sinus, within the anterolateral part of the attached margin.
3. Straight sinus, along the line of attachment between the falx cerebri and the tentorium cerebelli.

Falx cerebelli

It is a small sickle-shaped fold of the dura mater in the sagittal plane projecting forward into the posterior cerebellar notch. It extends from the internal occipital protuberance along the internal occipital crest to the posterior margin of the foramen magnum. It has a free concave anterior margin and a convex-attached posterior border.

Venous sinus enclosed in the falx cerebri: *Occipital sinus*, along with its posterior attached part.

Diaphragma sellae

It is a small circular horizontal fold of the inner layer of the dura mater forming the roof of the hypophyseal fossa.

It is attached *anteriorly* to the tuberculum sellae and *posteriorly* to the dorsum sellae and becomes *continuous* on each side with the dura mater of the middle cranial fossa.

It has a central aperture which provides passage to the stalk of the pituitary gland.

Blood Supply of the Dura Mater

Inner layer: The inner layer of the dura mater is more fibrous and requires very little blood to nourish it.

Outer layer: The outer layer of the dura mater is richly vascular and provides nourishment to the adjacent bone.

In the supratentorial compartment, it is supplied by the following arteries:

1. **In the anterior cranial fossa:** by the meningeal branches of the ophthalmic, anterior, and posterior ethmoidal arteries, and a branch of the middle meningeal artery.
2. **In the middle cranial fossa:** by the middle and accessory meningeal arteries and by the meningeal branches of the internal carotid and ascending pharyngeal arteries.
3. **In the posterior cranial fossa:** by the meningeal branches of the vertebral and occipital arteries.

Clinical correlation

The *meningeal arteries are the chief source of blood supply to the bones of the skull*. The bones receive very little blood from the vessels of the scalp. As a result, scalping does not produce necrosis of the underlying bone. The skull bones receive blood supply from exterior only where they provide attachment to muscles, viz. the temporal fossa and the suboccipital region.

Nerve Supply of the Dura Mater

Supratentorial dura is supplied by the ophthalmic nerve.

Infratentorial dura (dura of the floor) has rich sensory innervation (hence very sensitive to pain). It is supplied by the following nerves:

1. **In the anterior cranial fossa:** by the anterior and posterior ethmoidal nerves (and receives some twigs from the maxillary nerve).
2. **In the middle cranial fossa:** by the meningeal branch of the maxillary nerve (in the anterior part) and the meningeal branch of the mandibular nerve (nervus spinosus) in the posterior part.
3. **In the posterior cranial fossa:** by the meningeal branches of the vagus and hypoglossal nerves. These are the C1 and C2 fibres carried by the cranial nerves. The dura

mater around the foramen magnum is directly supplied by the C2 and C3 cervical nerves.

INTRACRANIAL DURAL VENOUS SINUSES

These are the various venous channels present in the cranial dura. They are formed in the following two ways:

1. By the separation of two layers of cranial dura.
2. By the reduplication of the meningeal layer.

All the venous sinuses, except the inferior sagittal and straight sinuses, lie between the meningeal and endosteal layers of the dura mater (Fig. 21.15). The sinuses have thin walls and are lined by endothelium which is continuous with that of veins. They drain blood from the brain and skull bones. The blood from dural venous sinuses is ultimately drained into internal jugular veins. Several of the sinuses communicate with the veins outside the skull, through emissary veins. The characteristic features of dural venous sinuses are as follows:

Features

1. Lie between the layers of the dura mater.
2. Have no muscle in their walls.
3. Lined by endothelium only (muscular coat is absent).
4. Are devoid of valves in their lumen.
5. Receive venous blood and CSF.
6. Receive valveless emissary veins which regulate the blood flow and maintain the equilibrium of venous pressure within and outside the skull.

Classification

There are about 21 sinuses. They are classified into two types: paired and unpaired (Table 21.1).

Table 21.1 Classification of the dural venous sinuses (seven paired and seven unpaired)

Unpaired sinuses	Paired sinuses
1. Superior sagittal	1. Cavernous
2. Inferior sagittal	2. Superior petrosal
3. Straight	3. Inferior petrosal
4. Occipital	4. Transverse
5. Anterior intercavernous	5. Sigmoid
6. Posterior intercavernous	6. Sphenoparietal
7. Basilar venous plexus	7. Petrosquamous

N.B.

- The middle meningeal veins are often termed *middle meningeal sinuses*.
- The sigmoid and transverse sinuses together are often termed *lateral sinus* by the clinicians.

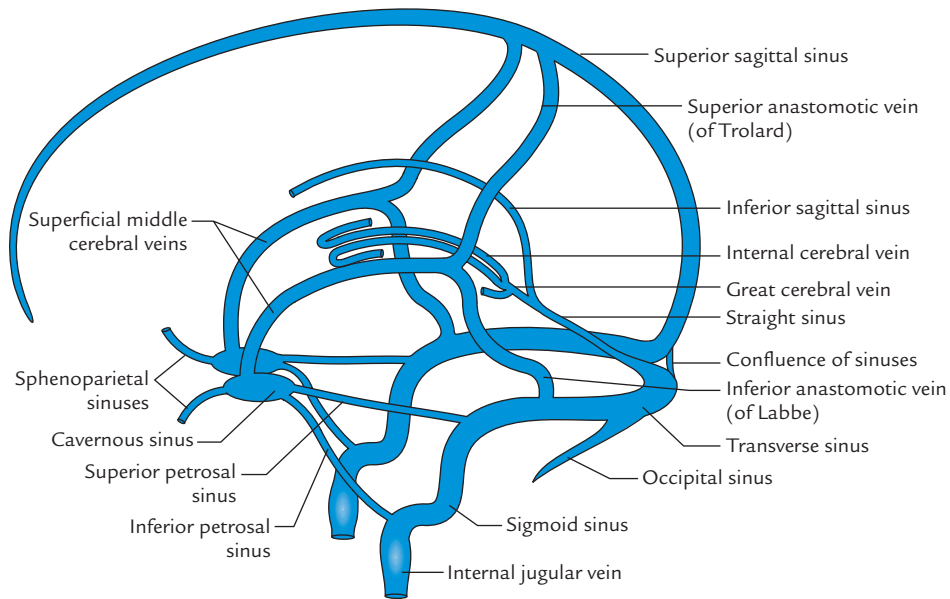


Fig. 21.15 Intracranial dural venous sinuses and their connections (lateral view).

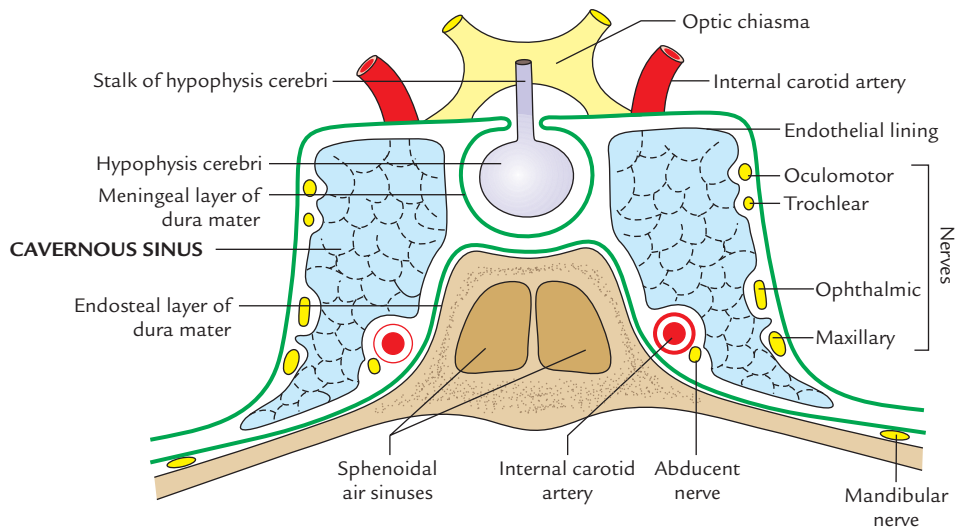


Fig. 21.16 Coronal section through the middle cranial fossa showing relations and contents of cavernous sinuses.

CAVERNOUS SINUS (Fig. 21.16)

Location

The cavernous sinus (2 cm long, 1 cm wide) is a large venous space situated on either side of the body of the sphenoid and sella turcica in the middle cranial fossa. Its interior is divided into a number of small spaces (caverns) by trabeculae, hence the name cavernous sinus. The floor of the sinus is formed by the endosteal layer, while the lateral wall, roof, and medial wall by the meningeal layer. Medially, the roof is continuous with the diaphragm sellae. Posteriorly, the roof has a

triangular depression between the attached margin (edge) of tentorium cerebelli to the posterior clinoid process and ridge raised by the free margin (edge) of tentorium cerebelli as it extends forward to gain attachment on the anterior clinoid process. The oculomotor and trochlear nerves pierce this triangle to enter the cavernous sinus.

Extent

Each sinus extends:

Anteriorly, up to the medial end of superior orbital fissure and posteriorly, up to apex to the petrous temporal bone.

Relations

Superior

1. Optic chiasma.
2. Optic tract.
3. Internal carotid artery.
4. Anterior perforated substance.

Inferior

1. Foramen lacerum.
2. Junction of the body and the greater wing of the sphenoid.

Medial

1. Pituitary gland (hypophysis cerebri).
2. Sphenoid air sinus.

Lateral

1. Temporal lobe (uncus) of the cerebral hemisphere.
2. Cavum trigeminale containing the trigeminal ganglion.

Anterior

1. Superior orbital fissure.
2. Apex of the orbit.

Posterior

1. Crus cerebri of midbrain.
2. Apex of the petrous temporal bone.

Structures Present in the Lateral Wall of the Sinus

From above downward these are as follows:

1. Oculomotor nerve.
2. Trochlear nerve.
3. Ophthalmic nerve.
4. Maxillary nerve.

Structures Passing Through Cavernous Sinus

1. Internal carotid artery surrounded by the sympathetic plexus of nerves.
2. Abducent nerve (it enters the sinus by passing below the petrosphenoid ligament and accompanies the artery on its inferolateral aspect).

It is believed that the pulsations of the internal carotid artery help in expelling blood from the sinus.

Tributaries of the Cavernous Sinus (Fig. 21.17)

The cavernous sinus receives blood from three sources: orbit, meninges, and brain. Hence, its tributaries come from these sources as follows:

From orbit

1. Superior ophthalmic vein.
2. Inferior ophthalmic vein.
3. Central vein of retina (sometimes).

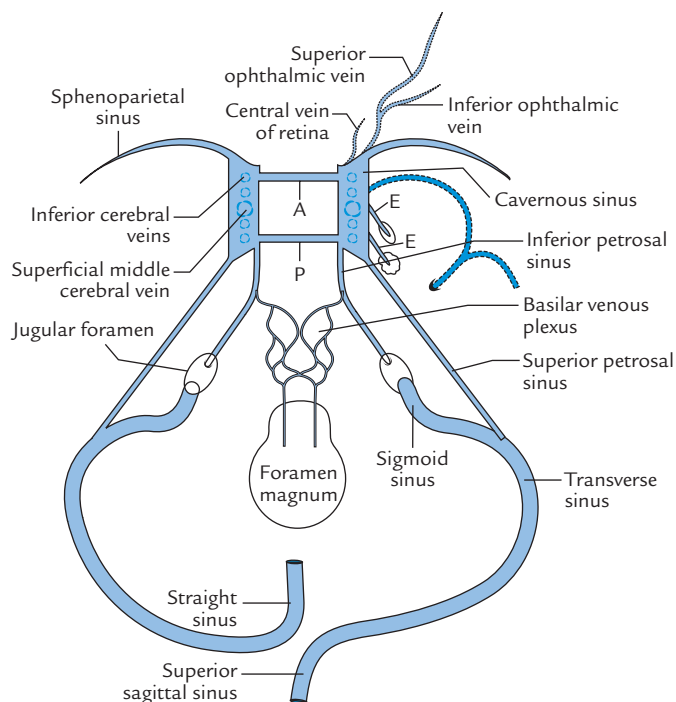


Fig. 21.17 Tributaries and communications of cavernous sinus (superior view) (A = anterior intercavernous sinus, P = posterior intercavernous sinus, E = emissary vein).

From meninges

1. Sphenoparietal sinus.
2. Anterior (frontal) trunk of the middle meningeal vein.

From brain

1. Superficial middle cerebral vein.
2. Inferior cerebral veins (only few).

Communications of Cavernous Sinus (Fig. 21.17)

The cavernous sinus communicates with the:

1. Transverse sinus via superior petrosal sinus.
2. Internal jugular vein via inferior petrosal sinus.
3. Pterygoid venous plexus via emissary veins which pass through foramen ovale, foramen lacerum, and emissary sphenoidal foramen.
4. Facial vein via two routes:
 - (a) Superior ophthalmic vein → angular vein → facial vein
 - (b) Emissary veins → pterygoid venous plexus → deep facial vein → facial vein.
5. Opposite cavernous sinuses via anterior and posterior intercavernous sinuses.
6. Superior sagittal sinus via superficial middle cerebral vein and superior anastomotic vein.
7. Internal vertebral venous plexus, via basilar venous plexus.

Clinical correlation

- **Cavernous sinus thrombosis:** The septic thrombosis of cavernous sinus may be caused by its numerous communications. The commonest cause of thrombosis is the passage of septic emboli from the dangerous area of the face through facial vein—deep facial vein—pterygoid venous plexus—emissary vein.

Cavernous sinus thrombosis gives rise to the following signs and symptoms:

- Severe pain in the eye and forehead, due to involvement of the ophthalmic nerve.
- Ophthalmoplegia (paralysis of ocular muscles) due to involvement of the 3rd, 4th, and 6th cranial nerves.
- Marked edema of eyelids with exophthalmos, due to congestion of orbital veins following obstruction of ophthalmic veins.

- **Arteriovenous communication:** If the internal carotid artery is ruptured in the fracture base of the skull, an arteriovenous communication/fistula is established between the artery and cavernous sinus. Consequently, arterial blood rushes into the cavernous sinus, enlarging it and forcing blood into the connecting veins.

Arteriovenous communication gives rise to the following signs and symptoms:

1. Pulsating exophthalmos; the eyeball protrudes and pulsates with each heartbeat.
2. A loud bruit (loud systolic murmur) is easily heard over the eye.
3. Ophthalmoplegia due to involvement of the 3rd, 4th, and 6th cranial nerves.
4. Marked orbital and conjunctival edema due to raised venous pressure in the cavernous sinus.

SUPERIOR SAGITTAL SINUS

It lies between the two layers of the falx cerebri along the convexity of its attached border (Fig. 21.18).

It begins at the crista galli behind the foramen cecum, passes backward (lodges itself in a sagittal groove on the vault of the skull) and on reaching the internal occipital protuberance, it deviates usually to the right to become continuous with the right transverse sinus which in turn becomes continuous with the right sigmoid sinus. The right sigmoid sinus leaves the skull through the jugular foramen to continue as the right internal jugular vein. The size of sinus becomes progressively larger as it passes backward from the crista galli to the internal occipital protuberance.

Features

1. Is triangular in cross section.
2. Communicates with venous lacunae on each side; the sites of drainage of diploic and meningeal veins.
3. Arachnoid granulations project into its lumen (and those of venous lacunae).

Tributaries

1. Superior cerebral veins.
2. Parietal emissary veins.
3. Small vein from the nasal cavity (if foramen cecum is patent).
4. Veins of the frontal air sinus.

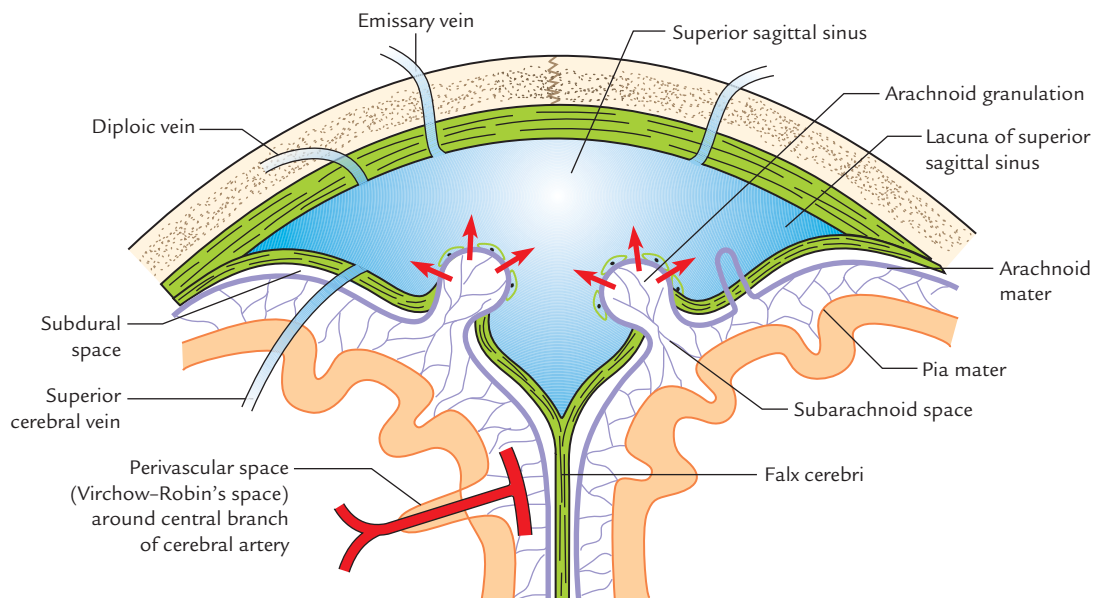


Fig. 21.18 Schematic coronal section through the superior sagittal sinus showing arachnoid granulations and absorption of the cerebrospinal fluid.

Clinical correlation

Thrombosis of superior sagittal sinus: The spread of infection from dangerous area of the face, scalp, and diploë to the superior sagittal sinus may cause its thrombosis.

The presenting clinical features of thrombosis are:

- (a) *marked increase in intracranial pressure*, due to defective adsorption of CSF, and
- (b) *delirium*, due to congestion of superior cerebral veins.

INFERIOR SAGITTAL SINUS

It is a small venous channel present between the two layers of the lower free margin of the falx cerebri. It ends by joining the great cerebral vein to form straight sinus. It drains the lower part of the medial surface of each cerebral hemisphere.

STRAIGHT SINUS

It lies in the median plane within the junction of falx cerebri and tentorium cerebelli.

It begins as a continuation of the inferior sagittal sinus and terminates usually into the left transverse sinus which at the mastoid angle of the parietal bone becomes continuous with the left sigmoid sinus.

TRANSVERSE SINUS

It begins at the internal occipital protuberance and runs laterally between the two layers of the attached margin of the tentorium cerebelli. It courses horizontally grooving the occipital bone and mastoid angle of the parietal bone and becomes continuous as the sigmoid sinus. The right transverse sinus is larger than the left transverse sinus because the right sinus is the continuation of the larger superior sagittal sinus and the left sinus is the continuation of the smaller straight sinus.

SIGMOID SINUS

Each sigmoid sinus is a direct continuation of the transverse sinus. It is sigmoid or S-shaped, hence its name. In its course, it deeply grooves the inner surface of the mastoid part of the petrous bone. Its terminal part curves downward and then forward to the posterior margin of the jugular foramen through which it passes to continue as the internal jugular vein.

Its tributaries are:

1. Mastoid and condylar emissary veins.
2. Cerebellar veins.
3. Internal auditory vein.

Clinical correlation

Thrombosis of sigmoid sinus: The sigmoid sinus is separated from the mastoid antrum and mastoid air cells only by a thin plate of the bone. The thrombosis of the sigmoid sinus is, therefore, secondary to infection of the middle ear or mastoid process. Further, utmost care should be taken not to expose sigmoid sinus during operations on the mastoid process.

OCCIPITAL SINUS

It lies between the two layers of the attached margin of falx cerebelli. The occipital sinus runs downward from the internal occipital protuberance to the posterior margin of the foramen magnum where it skirts the margin of the foramen and drains into the sigmoid sinuses.

BASILAR VENOUS PLEXUS

It consists of network of veins lying between the two layers of dura on the clivus. It connects the two inferior petrosal sinuses and communicates with the internal vertebral venous plexus. It receives blood from the pons and medulla. Thrombosis of the basilar venous plexus is, therefore, usually fatal.

N.B.

Confluence of sinuses (torcular herophili): It is the region where the superior sagittal and straight sinuses end and the right and left transverse sinuses begin. The occipital sinus also drains into the confluence. The confluence of sinuses is situated near the internal occipital protuberance.

SPHENOPARIETAL SINUS

The sphenoparietal sinus lies along the posterior free margin of the lesser wing of the sphenoid and drains into the anterior part of the cavernous sinus.

SUPERIOR PETROSAL SINUS

This sinus lies in the anterior part of the attached margin of tentorium cerebelli and crosses above the trigeminal nerve.

INFERIOR PETROSAL SINUS

This sinus lies in the petro-occipital suture.

Middle meningeal veins, one on each side, form two trunks: frontal and parietal. The two trunks follow the corresponding divisions of the middle meningeal artery nearer to the bone, hence more liable to injury in skull fracture. The frontal trunk usually drains into the cavernous sinus and the parietal trunk into the pterygoid venous plexus by passing through the foramen spinosum.

PETROQUAMOUS SINUS

This sinus lies in the petrosquamous suture if present and drains into the transverse sinus.

ANTERIOR AND POSTERIOR INTERCAVERNOUS SINUSES

The anterior and posterior intercavernous sinuses connect the cavernous sinuses. They pass through diaphragma sellae in front and behind the opening for infundibulum of the pituitary gland, respectively. Intercavernous sinuses and cavernous sinuses together form the **circular sinus**.

PITUITARY GLAND

The pituitary gland (hypophysis cerebri) has been described in detail in *General Anatomy* (pages 198–201), by Vishram Singh. The following text deals with the surgical anatomy of the gland.

Location (Fig. 21.19)

The pituitary gland is a small endocrine gland situated in the hypophyseal fossa on the superior surface of the body of the sphenoid (*sella turcica*). It is suspended from the floor of the 3rd ventricle of the brain by a narrow stalk called **infundibulum**. The gland is enclosed in the dural sheath, whose tense upper wall—the **diaphragma sellae**—is perforated by the infundibulum or stalk. On each side, the pituitary gland is related to the cavernous sinus and in front and behind to the anterior and posterior intercavernous sinuses.

Shape and Measurements

The gland is oval in shape and measures 8 mm anteroposteriorly, 12 mm transversely, and weighs about 500 mg.

Relations

Superior: Optic chiasma with diaphragma sella intervening

Inferior: Sphenoidal air sinuses with thin bony plate of the hypophyseal fossa intervening.

Lateral: Cavernous sinus on each side.

Subdivisions (Fig. 21.20)

The gland has two main subdivisions: adenohypophysis and neurohypophysis, which differ from each other embryologically, morphologically, and functionally (Table 21.2). The **adenohypophysis** develops as a diverticulum (Rathke's pouch) from the ectodermal roof of the stomodeum. Normally the communication with the roof of the pharynx disappears completely owing to the rapid growth of the sphenoid. Occasionally, however, it may persist as a *craniopharyngeal canal*. The uppermost part of the original diverticulum remains as a cleft which separates the

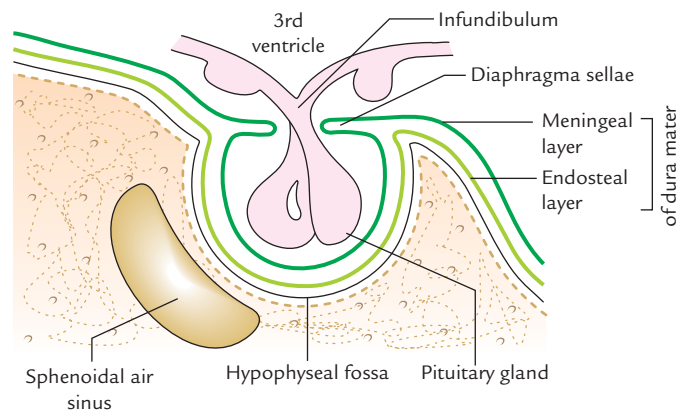


Fig. 21.19 Location of hypophysis cerebri (pituitary gland).

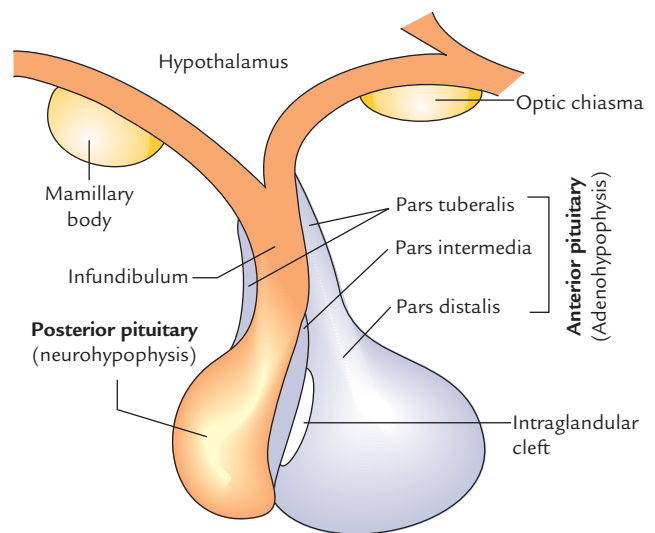


Fig. 21.20 Parts of hypophysis cerebri as seen in sagittal section.

Table 21.2 Hormones secreted by different parts of adeno hypophysis

Part	Cell types/nuclei	Hormones secreted
Pars anterior	Acidophil cells	I. Growth hormone II. Prolactin
	Basophil cells	I. Adrenocorticotrophic hormone II. Thyrotrophic hormone III. Gonadotrophic hormone
Pars intermedia		Melanocyte stimulating hormone
Pars posterior	Supraoptic nucleus of hypothalamus Paraventricular nucleus of hypothalamus	Vasopressin or antidiuretic hormone Oxytocin

pars anterior and pars intermedia. The **neurohypophysis** develops as a downgrowth from the floor of the diencephalon.

Adenohypophysis consists of:

- pars anterior,
- pars intermedia, and
- pars tuberalis.

Neurohypophysis consists of:

- pars posterior, and
- infundibulum.

Functional Connections with Hypothalamus

Hypothalamohypophysial Tract

It consists of nerve fibres arising from the supraoptic and paraventricular nuclei of the hypothalamus and projecting into the posterior lobe of the pituitary gland. The vasopressin and ADH produced in supraoptic and paraventricular nuclei are transported by the nerve fibres of the tract, and stored in the nerve terminals (**Herring bodies**) of these fibres in the posterior lobe (neurohypophysis). Then hormones are released in the venous sinusoids as and when necessary.

Hypothalamohypophysial Portal System

It consists of two sets of capillaries—one in the hypothalamus (**median eminence**) and the other in the hypophysis cerebri (sinusoids of pars anterior). The neurons of the hypothalamus produce hormones-releasing factors in the capillaries of the median eminence and upper part of the infundibulum. These are carried by the portal system to pars anterior where they stimulate it to release appropriate hormones.

Arterial Supply

The following branches of internal carotid artery supply the pituitary gland:

- Superior hypophyseal artery, one on each side.
- Inferior hypophyseal artery, one on each side.

Venous Drainage

Short veins from the pituitary gland drain into neighboring dural venous sinuses (e.g., cavernous and intercavernous sinuses). The hormones pass out of the gland through venous blood to the target sites.

Clinical correlation

- **Craniopharyngioma:** The remnants of Rathke's pouch may give rise to a tumor inside the sphenoid bone called *craniopharyngioma*.

Sometimes some cells of Rathke's pouch extend backward along the roof of the nasopharynx and form an accessory lobe of the anterior lobe in the pharyngeal wall called *pharyngeal hypophysis*.

- **Pituitary tumors:** The pituitary tumors occur commonly. The commonest tumor of the pituitary gland is *adenoma* arising from its chromophobe cells. Pituitary adenoma produces two types of symptoms: (a) symptoms due to pressure on adjacent structures, and (b) symptoms due to endocrine disturbances.

Symptoms due to pressure on adjacent structures:

- *Enlargement of hypophyseal fossa* due to downward growth (intracellular growth) of an adenoma. It is seen as ballooning of hypophyseal fossa (sella turcica) in plane radiograph of skull (lateral view).
- *Bitemporal hemianopia* (loss of vision in right and left temporal fields of vision) due to the upward growth of adenoma pressing the central part of the optic chiasma (Fig. 21.21).
- *Exophthalmos and ophthalmoplegia* due to pressure on the cavernous sinus.

Symptoms due to endocrine disturbances:

- *Gigantism* before puberty and *acromegaly* in adults, due to excessive secretion of growth (GH) hormone.
- *Cushing syndrome* due to excessive secretion ACTH.
- *Dwarfism* due to hyposecretion of GH in infants and children due to involvement of the posterior lobe.
- *Diabetes insipidus* due to involvement of the posterior lobe.

Surgical approaches for removal of pituitary adenoma: The pituitary tumors may be removed by the transfrontal operation or by the trans-sphenoidal route.

Trans-sphenoidal approach: In this approach, the surgeon enters the pituitary fossa from below through a sphenoidal air sinus, either via ethmoidal cells after raising the periosteum from the medial wall of the orbit (actually it should be termed transorbital–transethmoidal–trans-sphenoidal approach) or by elevating the nasal mucosa from the nasal septum and removing the nasal septum (note that nasal cavity itself is not entered) and rostrum of the sphenoid (*transnasal-trans-sphenoidal approach*).

Transfrontal (subfrontal) approach: In this, the gland is approached through the anterior cranial fossa by elevating the frontal lobe of the brain.

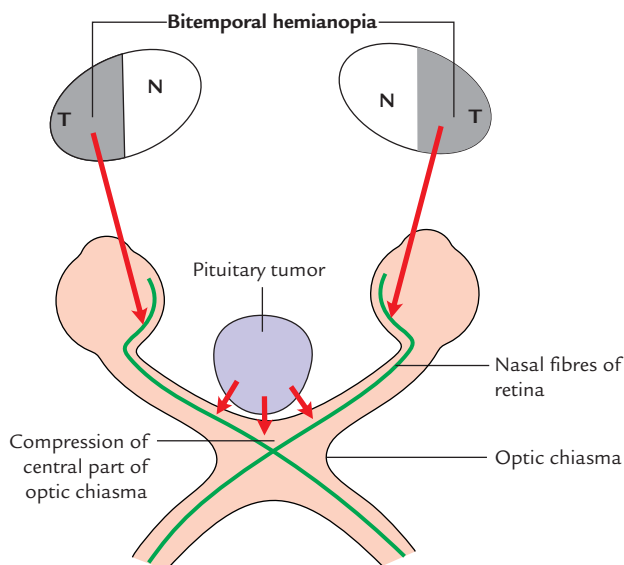


Fig. 21.21 Bitemporal hemianopia (T=temporal field of vision, N= nasal field of vision).

Golden Facts to Remember

- | | |
|--|---|
| ▶ Largest bony cavity in the body | Cranial cavity |
| ▶ Deepest cranial fossa | Posterior |
| ▶ Largest bony foramen in the body | Foramen magnum |
| ▶ Most common site of fracture of the base of skull | Middle cranial fossa |
| ▶ All the dural venous sinuses lie between the meningeal and endosteal layers of the dura mater except | Inferior sagittal and straight sinuses |
| ▶ Longest dural venous sinus | Superior sagittal sinus |
| ▶ Chief source of blood supply to the skull bone | Meningeal vessels |
| ▶ Commonest tumors of the pituitary gland | Adenoma arising from its chromophobe cells |
| ▶ Rathke's pouch | Ectodermal diverticulum from roof of stomodeum giving rise to adenohypophysis |
| ▶ Herring bodies | Nerve terminals of hypothalamo-hypophyseal tracts containing vasopressin and antidiuretic hormones |
| ▶ Commonest cause of extradural hematoma | Tear of the anterior trunk of middle meningeal vein and anterior branch of middle meningeal artery |
| ▶ Meckel's cave | Pouch of the inner layer of the dura mater over trigeminal impression on the anterior surface of the petrous temporal bone containing the trigeminal ganglion |
| ▶ Largest diploic vein | Occipital diploic vein |

Clinical Case Study



A 49-year-old man fell from the second floor terrace of his house. He became unconscious and there was bleeding from his head. He was immediately taken to the nearby hospital, where on examination, the doctors found that his occipital region was badly bruised. They also noticed bleeding from his right ear. On careful examination, it was noticed that his right eye was protruded and pulsating. The conjunctiva was engorged (chemosis). A CT scan revealed the fracture of the base of the skull in the region of middle cranial fossa.

Questions

1. What is the commonest site of fracture of the base of the skull? Mention the reason(s) for the same.
2. Why is fracture of middle cranial fossa often associated with bleeding from the ear?
3. What is the anatomical basis of pulsations in the right eye?

Answers

1. Middle cranial fossa; because the base of the skull in this region is weak due to the presence of a large number of foramina and canals.
2. In fracture of the middle cranial fossa, the roof of middle ear (tegmen tympani) is fractured and the tympanic membrane is torn, which results in bleeding from the ear.
3. If internal carotid artery within cavernous is torn in fracture, there occurs an **arteriovenous fistula**. The blood from the artery due to high arterial pressure rushes into the cavernous sinus, forcing the blood of cavernous sinus into the ophthalmic veins. As a result, the eye protrudes (**exophthalmos**) and the conjunctiva becomes engorged. The bulging eye pulsates (**pulsating exophthalmos**) in synchrony with the arterial pulse.

Cranial Nerves

There are 12 pairs of the cranial nerves, out of which the first two pairs arise from the **forebrain** and the next 10 pairs arise from the **brainstem**. They are numbered 1 to 12 in the craniocaudal sequence of their attachment on the brain. The cranial nerves are generally designated by Roman numerals.

The 12 pairs of nerves are:

I	Olfactory	VII	Facial
II	Optic	VIII	Vestibulo-cochlear
III	Oculomotor	IX	Glossopharyngeal
IV	Trochlear	X	Vagus
V	Trigeminal	XI	Accessory
VI	Abducent	XII	Hypoglossal

N.B.

- A minute bundle of nerve fibres closely related to the olfactory nerves is termed the **13th pair or 'O' pair of cranial nerves**. Each nerve is attached to the cerebrum, posterior to the olfactory stria of the olfactory tract close to anterior perforated substance and septal areas and distributed to the nasal mucous membrane. Its exact function is not known, but it is thought to provide a special chemo-sensory pathway of olfaction and affects the secretion of luteinizing hormone-releasing factor from the hypothalamus. In addition, it plays an important role in smell-mediated sex behavior.

Functional Components

A cranial nerve consists of motor fibres (**motor nerve**) or sensory fibres (**sensory nerve**) or both the motor and sensory fibres (**mixed nerve**).

The motor fibres of cranial nerves can be of the following three types:

1. **Somatic efferent (SE) or general somatic efferent (GSE) fibres**. They supply the striated muscles which develop from somites.
2. **Special visceral efferent (SVE) fibres**. They supply the muscles which develop from the mesoderm of pharyngeal arches.

3. **General visceral efferent (GVE) fibres**. They supply the glands, smooth muscles of viscera, and vessels. They are preganglionic parasympathetic fibres.

The sensory fibres of cranial nerves can be of the following four types:

1. **General somatic afferent (GSA) fibres**. They carry general sensations of pain, touch, and temperature from skin and proprioceptive sensations of vibration and muscle and joint sense.
2. **General visceral afferent (GVA) fibres**. They carry general sensations of distension and ischemic pain from viscera.
3. **Special visceral afferent (SVA) fibres**. They carry special sensations of taste from tongue.

In addition to the aforementioned three types, the sensory fibres may be **special somatic afferent (SSA)** which carry special sensations of smell, hearing, and balance.

N.B.

- The motor fibres of cranial nerves arise as outgrowths of axons from motor nuclei situated within the central nervous system (CNS).
- The sensory fibres arise as outgrowths of axons from cells situated within the sensory ganglia (situated outside the CNS) and terminate in the sensory nuclei situated within the CNS.
- The motor and sensory nuclei within the CNS are arranged in longitudinal columns called functional columns.

OLFACTORY NERVE

Olfactory nerve is the 1st cranial nerve. It is purely sensory and carries the sense of smell from nasal cavity (Fig. 22.1).

Unique Features

1. The primary sensory neurons of olfactory nerve lie on the body surface in the epithelial lining of the nasal cavity and their dendrites lie free in the mucous film.

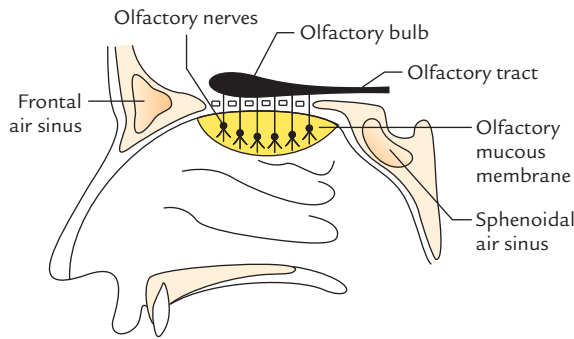


Fig. 22.1 Location of olfactory epithelium in the nasal cavity.

2. The primary sensory neurons of olfactory nerve (olfactory neurons) undergo continuous turnover, i.e., they are continuously replaced by stem cells in the olfactory neuroepithelium.

Functional Components

Special somatic afferent fibres: They carry special sensations of smell from the olfactory region of the nasal cavity and terminate in the olfactory bulb.

Course, Relations, and Distribution

Each olfactory nerve consists of about 20 minute bundles of non-myelinated nerve fibres. They arise from primary receptor neurons (modified bipolar neurons) of the olfactory epithelium of nasal cavity, pass through foramina in the cribriform plate of the ethmoid to enter the anterior cranial fossa, where they terminate in the olfactory bulb. In the olfactory bulb, they synapse with the mitral cells. The bundles of olfactory nerves are surrounded by three meninges (namely pia mater, arachnoid mater, and dura mater) near the cribriform plate. This provides a potential communication between the subarachnoid space and lymphatics of the nasal mucosa. Thus, infection from nose can spread into the meninges of the brain.

Distribution: olfactory region of the nasal cavity.

Clinical correlation

- **Anosmia:** The loss of sense of smell is called *anosmia*. Anosmia can occur for a number of reasons such as atrophic rhinitis (degenerative disorder of nasal mucosa), fracture of the anterior cranial fossa (ethmoidal fracture), etc. The ethmoidal fracture is often associated with blood-stained cerebrospinal fluid (CSF rhinorrhea).
- **Clinical testing of olfactory nerve:** The olfactory nerve is tested clinically by asking the patient to smell common odors such as peppermint, garlic, or cloves from each side of his nostril separately with eyes closed.

OPTIC NERVE

Optic nerve is the 2nd cranial nerve. It is purely sensory and responsible for vision; hence, it is also called the **nerve of sight**.

Unique Features

The optic nerve is not a true peripheral (cranial) nerve. It is actually a tract of brain for it develops as an outgrowth of diencephalon during embryonic life. Hence, it presents the following unique features:

1. It consists of second-order sensory neurons.
2. Its fibres are myelinated by oligodendrocytes.
3. It is surrounded by meninges.
4. Its fibres cannot regenerate if cut/damaged.

Functional Component

Special somatic afferent fibres: They carry sense of sight from the visual field of the corresponding eye.

Course and Relations

The fibres of optic nerve arise from ganglion cells (second-order neurons) in the neural layer of the retina of the eyeball, converge toward the optic disc at the posterior pole of the eyeball, pierce the outer layer of retina, choroid, and sclera to leave the eyeball. Immediately after emerging from the eyeball, the fibres unite to form the optic nerve, which passes posteromedially through the posterior half of the orbit and enters the middle cranial fossa through the optic canal. In the middle cranial fossa, optic nerves of two sides unite to form the **optic chiasma**. The midregion of optic chiasma is composed of crossed fibres from the medial/nasal halves of the retina of both eyes, while the lateral region is made up of fibres from the lateral/temporal half of the retina of the ipsilateral eye.

Diverging from the chiasma are the optic tracts. Most of the fibres of the optic tract relay in the lateral geniculate body. The third-order neurons arise in the lateral geniculate body, run in the retrolenticular part of the internal capsule, and form optic radiations. The fibres of optic radiation terminate in and around the calcarine sulcus of the occipital lobe (visual cortex). Some of the fibres from the lateral geniculate body reach the pretectal area of the midbrain and form a part of the pathway for **light reflex**.

Thus, **visual pathway** consists of the following components in craniocaudal order (Fig. 22.2):

Retina → **optic nerve** → **optic tract** → **lateral geniculate body** → **optic radiation** → **visual cortex**.

The optic nerve is 4 cm in length. It is divided into three parts: (a) intraorbital part, (b) canalicular part, and (c) intracranial part. It is enclosed by three meninges of the brain.

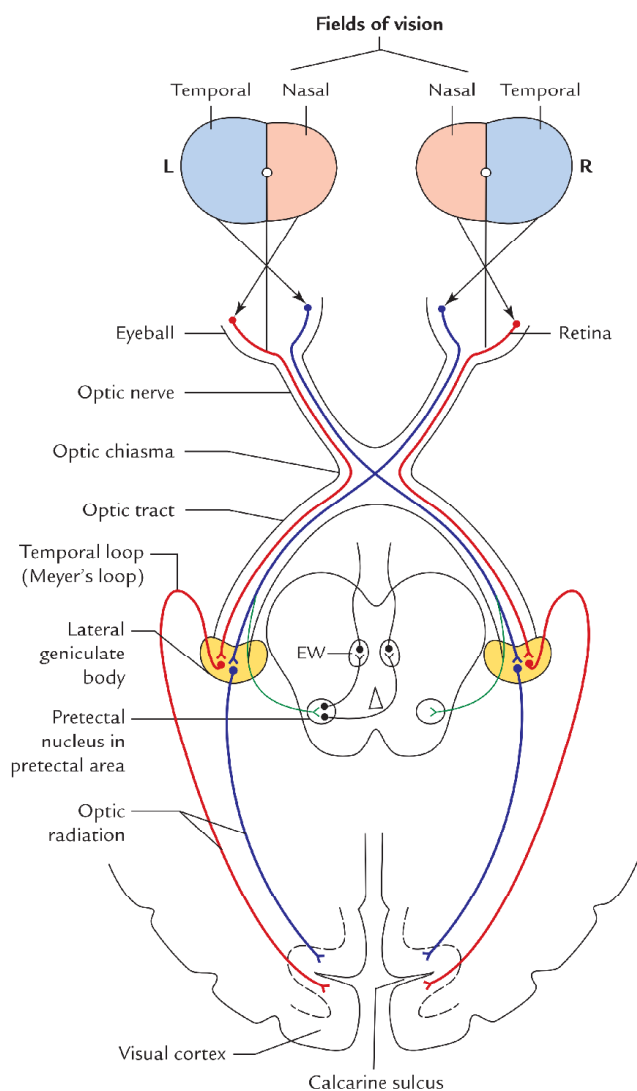


Fig. 22.2 Basic components of the visual pathway (EW = Edinger–Westphal nucleus).

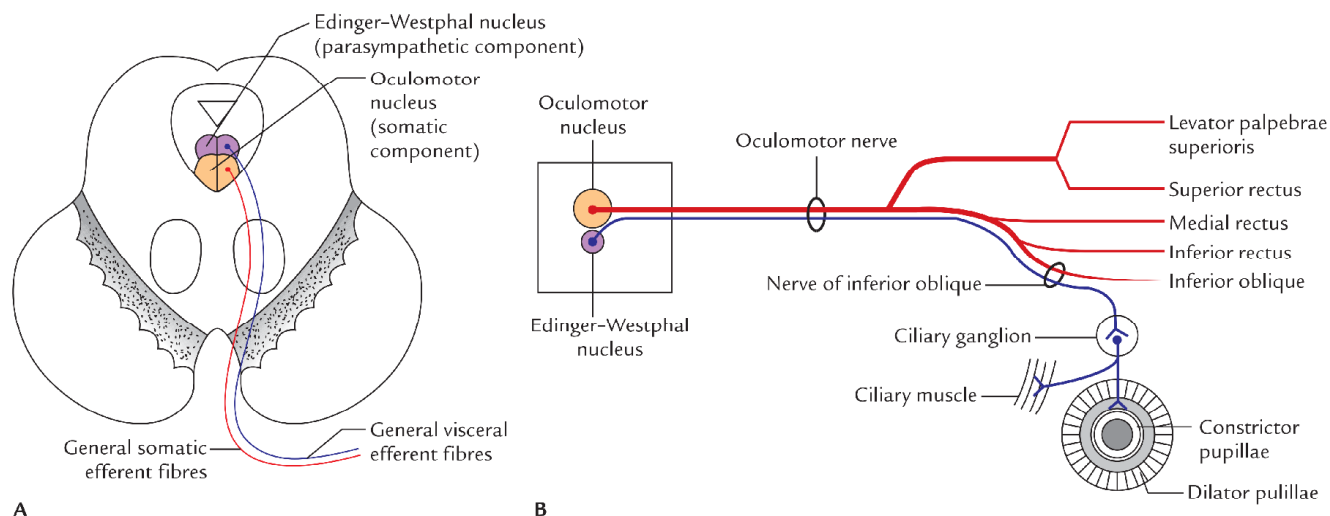


Fig. 22.3 Oculomotor nerve: A, the functional components and nuclei of the oculomotor nerve; B, the distribution of the constitutional fibres of the oculomotor nerve.

The thick fibrous dural sheath of optic nerve blends with the sclera of the eyeball. The subarachnoid space containing CSF surrounds the optic nerve and is continuous with the subarachnoid space of the brain.

Clinical correlation

- **Ipsilateral total blindness:** It may occur due to damage of optic nerve or blockage of central artery of retina. The compression of optic nerve results in *optic atrophy*, which subsequently leads to ipsilateral total blindness called *anopia*.
- **Papilledema:** The central vein of retina is enclosed in the meninges of the anterior part of optic nerve which is surrounded by CSF in the subarachnoid space. Therefore, an increased CSF pressure within the cranial cavity impedes the return of venous blood from the retina by pressing the central vein of retina and its tributaries. This results in swelling of optic disc owing to edema called *papilledema*. The papilledema is valuable clinical evidence of an increased intracranial pressure.
- **Clinical testing of optic nerve:** The optic nerve is tested clinically by performing tests for visual acuity, color perception, and loss of vision in different visual fields.

OCULOMOTOR NERVE

Oculomotor nerve is the 3rd cranial nerve. It is purely motor. As its name implies, it **moves the eye**. It supplies most of the muscles of the eye and plays a principal role in accommodation of the eye.

Functional Components and Nuclei (Fig. 22.3)

1. **General somatic efferent fibres:** They supply all extraocular muscles except lateral rectus (supplied by

6th cranial nerve) and superior oblique (supplied by 4th cranial nerve), *Mnemonic: A3, LR6S04*. The GSE fibres arise from the somatic component of oculomotor nucleus (also called the somatic motor nucleus).

2. **General visceral efferent fibres:** They supply the sphincter pupillae and ciliaris muscles. They arise from the parasympathetic component of oculomotor nucleus (also called the Edinger–Westphal nucleus). These are preganglionic parasympathetic fibres and relay in the ciliary ganglion. The postganglionic parasympathetic fibres arise from the ganglion and supply the sphincter pupillae and ciliaris muscles.

Course, Relations, and Distribution (Fig. 22.4)

The oculomotor nerve arises from the **oculomotor sulcus** on the medial aspect of the cerebral peduncle of the midbrain and appears in the interpeduncular fossa. It runs forward and laterally between the posterior cerebral and superior cerebellar arteries and lateral to the posterior communicating artery, passes through the tentorial notch of tentorium cerebelli to reach the middle cranial fossa. Here it pierces the dura mater in the **oculomotor triangle** lying in between the free and attached margins of tentorium cerebelli in the roof of the cavernous sinus and enters the lateral wall of the

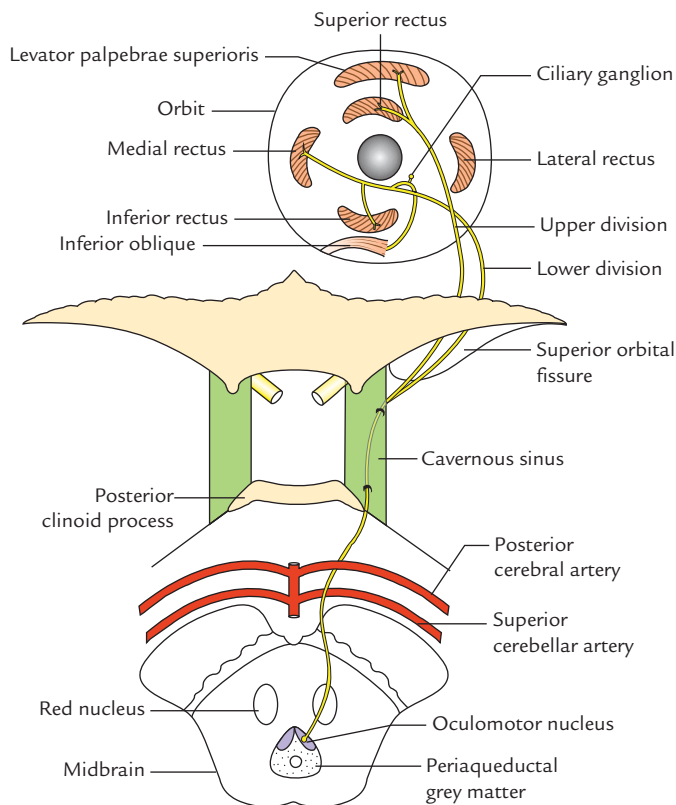


Fig. 22.4 Origin, course, and distribution of the oculomotor nerve.

cavernous sinus where it lies superior to the trochlear, ophthalmic, and maxillary nerves, and lateral to the internal carotid artery. In the anterior part of the cavernous sinus, the nerve divides into upper and lower divisions. The two divisions enter the orbit through the superior orbital fissure within the common tendinous ring. The nasociliary nerve intervenes between the two divisions. The smaller upper division passes above the optic nerve on the inferior surface of superior rectus (which it supplies), and then passes through the superior rectus to supply the levator palpebrae superioris.

The larger inferior division of the oculomotor nerve passes below the optic nerve and immediately gives three branches which supply the medial rectus, inferior rectus, and inferior oblique muscles. The nerve to inferior oblique gives motor root (parasympathetic root) to the ciliary ganglion located in the posterior part of the orbit. The postganglionic fibres from this ganglion run through short ciliary nerves and supply the sphincter pupillae and ciliaris muscles.

Clinical correlation

Lesions of oculomotor nerve: The damage of oculomotor nerve may occur due to the following factors:

- (a) *Compression by aneurysm of the posterior communicating artery* as it passes between posterior cerebral and superior cerebellar arteries.
- (b) *Compression by aneurysm of the internal carotid artery* as it passes through the lateral wall of the cavernous sinus.
- (c) *Compression by transtentorial uncal herniation* as it passes through the tentorial notch.

The damage of oculomotor nerve clinically presents as:

- *Ptosis* (drooping of the upper eyelid), due to paralysis of the levator palpebrae superioris.
- *Lateral strabismus (i.e., lateral squint)*, due to paralysis of the medial rectus and consequent unopposed action of the lateral rectus muscle.
- *Dilated and fixed pupil*, due to paralysis of the sphincter pupillae and consequent unopposed action of the dilator pupillae.
- *Loss of accommodation*, due to paralysis of the medial rectus, sphincter pupillae, and ciliaris muscles.
- *Double vision or diplopia occurs* on looking medially, inferiorly, and superiorly, due to paralysis of the medial rectus, inferior rectus, and inferior oblique muscles.
- *Proptosis* (prominence of the eyeball) due to relaxation of the muscles of the eyeball.

TROCHLEAR NERVE

Trochlear nerve is the 4th cranial nerve. It is purely motor and supplies only one muscle—the superior oblique muscle of the eyeball.

Unique Features

1. It is the only cranial nerve which emerges on the dorsal aspect of the brain.
2. It is the most slender of all the cranial nerves.
3. It is the smallest cranial nerve.
4. It is the only cranial nerve whose nuclear fibres decussate before emerging on the surface of the brain.
5. Its nucleus receives only ipsilateral corticonuclear fibres.
6. Phylogenetically, it is the nerve of 3rd eye.

Functional Components and Nuclei

General somatic efferent fibres: They arise from the trochlear nucleus in the midbrain and supply the superior oblique muscle of the eyeball.

Course, Relations, and Distribution (Fig. 22.5)

The trochlear nerves arise from the dorsal aspect of the midbrain, one on either side of **frenulum veli**. After emerging from the brain, the nerve winds round the superior cerebellar peduncle and cerebral peduncle just above the pons. It then passes between the posterior cerebral and superior cerebellar arteries to appear ventrally. It lies medial to and below the free margin to tentorium cerebelli. The nerve enters the cavernous sinus by piercing the posterior corner of its roof. In the cavernous sinus, it runs forward in its lateral wall between the oculomotor and ophthalmic nerves. In the

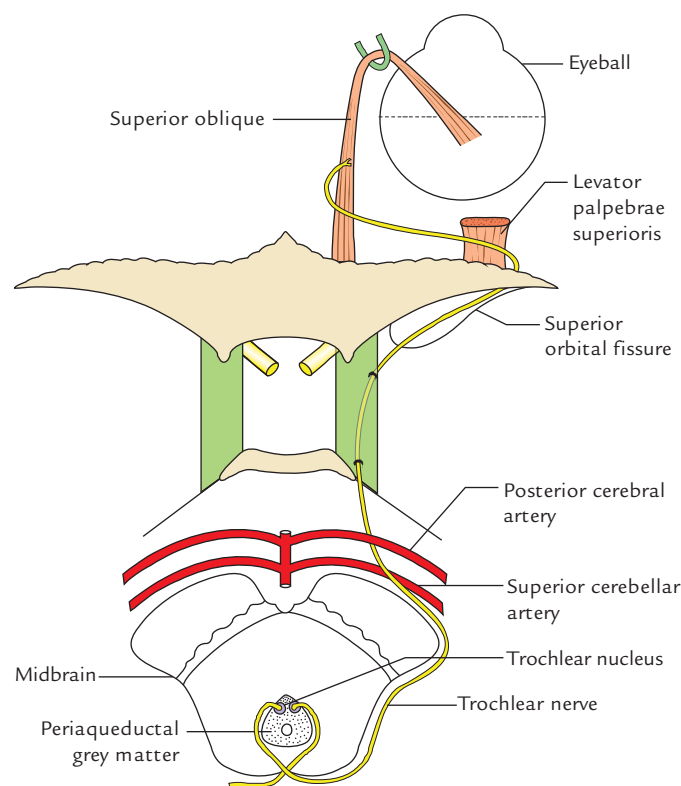


Fig. 22.5 Origin, course, and distribution of the trochlear nerve.

anterior part of the sinus, it crosses over the oculomotor nerve and becomes lateral to it. The nerve enters the orbit through the superior orbital fissure superolateral to the tendinous ring. It runs medially above the levator palpebrae superioris to enter the orbital surface of the superior oblique which it supplies.

Clinical correlation

Lesions of trochlear nerve: The injury of trochlear nerve will cause paralysis of the superior oblique muscle of the eyeball. This will clinically present as:

- (a) *extorsion of the eyeball and weakness of downward gaze.* As a result, the patient faces difficulty while going downstairs or reading newspaper, and
- (b) *diplopia* (double vision), which occurs when the patient looks laterally and in glances on looking downward. There is compensatory head-tilting to the opposite side.

ABDUCENT NERVE

Abducent nerve is the 6th cranial nerve. It is purely motor and supplies only one muscle—the lateral rectus of the eyeball. It is so named because it abducts the eye. It is also called **lover's nerve**, because in ancient times (non-verbal era between the teenager girls and boys), the boy used to call the girls from a gathering by sending signal through the action of this muscle.

Unique Feature

It is most susceptible to damage of all the cranial nerves during increased intracranial pressure.

Functional Components and Nuclei

1. **General somatic efferent fibres.** They arise from the abducent nucleus in the pons and supply the lateral rectus muscle of the eyeball.
2. **General somatic afferent fibres.** They carry proprioceptive sensations from the lateral rectus and terminate in the mesencephalic nucleus of the trigeminal nerve.

Course, Relations, and Distribution (Fig. 22.6)

The abducent nerve arises at the lower border of the pons opposite the pyramid of the medulla. The nerve runs upward, forward, and laterally dorsal to the anterior cerebellar artery and pierces the dura mater over the clivus inferolateral to the dorsum sellae. It then passes through the medial wall of the inferior petrosal sinus and arches forward directly over the sharp ridge of the petrous temporal bone, under the **petroclinoid ligament** and enters the fibro-osseous canal (**Dorello's canal**) formed by the apex of the petrous temporal bone and petroclinoid ligament (**Gruber's ligament**). The

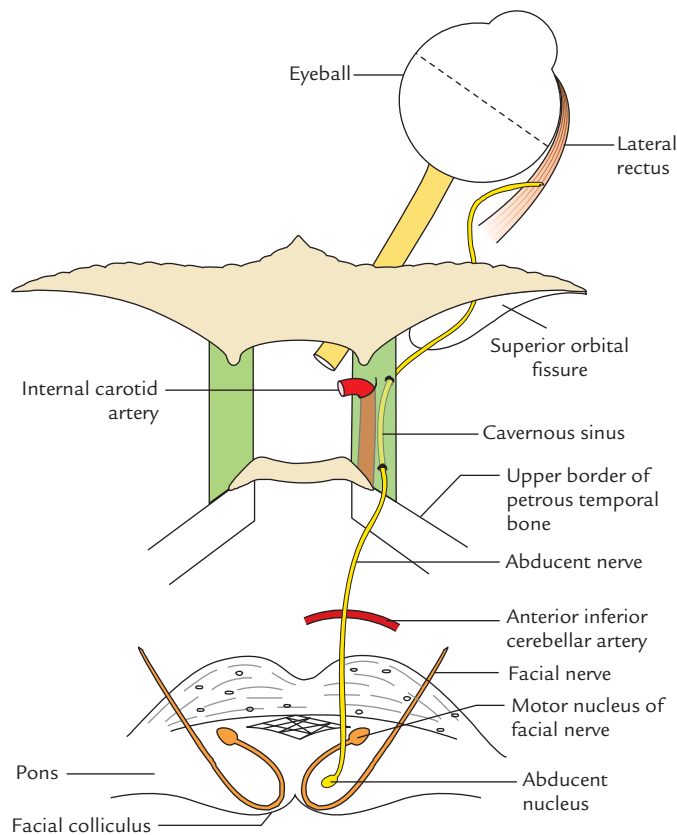


Fig. 22.6 Origin, course, and distribution of the abducent nerve.

nerve then enters the cavernous sinus by piercing the posterior wall close to the floor of the sinus. In the cavernous sinus, it runs forward inferolateral to the internal carotid artery.

The nerve enters the orbit through the superior orbital fissure within the tendinous ring lateral to two divisions of oculomotor and nasociliary nerves. In the orbit, it runs forward, toward the lateral side to enter the orbital surface of the lateral rectus muscle which it supplies.

Clinical correlation

Lesions of abducent nerve: The abducent nerve is generally damaged during increased intracranial pressure. During increased intracranial pressure, the nerve is stretched due to the descent of brainstem. Consequently, the nerve is cut by the sharp bony edge of the petrous temporal bone.

The paralysis of lateral rectus muscle following the injury to the abducent nerve leads to:

- convergent squint* due to the unopposed action of medial rectus,
- inability to abduct the eye, and
- diplopia* (double vision) with maximum separation of two images while looking toward the paralyzed side.

TRIGEMINAL NERVE

Trigeminal nerve is the 5th cranial nerve. It is a mixed nerve containing both the motor and sensory fibres but predominantly it is sensory. It consists of three large nerves: **ophthalmic, maxillary, and mandibular**, hence the name trigeminal nerve (L. *trigeminus* = triplet). It is a motor nerve to the muscles of mastication and several small muscles and the principal sensory nerve of the head and face.

Unique Features

- It is the largest cranial nerve.
- Its sensory ganglion (largest in the body) is located within the cranial cavity (cf. all the sensory ganglia are located outside the cranial cavity).

Functional Components and Nuclei (Fig. 22.7)

- Special visceral efferent fibres.** They arise from motor the nucleus of the trigeminal nerve in the pons and supply the muscles derived from the 1st pharyngeal arch, *viz.* the muscles of mastication, mylohyoid, anterior belly of digastric, tensor palati, and tensor tympani.
- General somatic afferent fibres:**
 - They carry *exteroceptive sensations* (i.e., pain, touch, and temperature) from skin of head and face, mucous membrane of mouth, nasal cavity, meninges, etc. and terminate in the **main sensory nucleus and spinal nucleus of the trigeminal nerve**.
 - They also carry *proprioceptive sensations* from the muscles of mastication, temporomandibular joint, and teeth and terminate in the **mesencephalic nucleus of the trigeminal nerve** and the reticular formation of brainstem.

The exteroceptive neurons are pseudounipolar and their cell bodies are located in the **trigeminal ganglion**.

The proprioceptive neurons are unipolar and their cell bodies are located in the **mesencephalic nucleus of the trigeminal nerve**.

The mesencephalic nucleus is the only site in the CNS which contains unipolar neurons/first-order sensory neurons.

Course, Relations, and Distribution

The trigeminal nerve arises by two roots (a smaller medial motor root and a larger lateral sensory root) from the ventrolateral aspect of the pons at its junction with the middle cerebellar peduncle (Fig. 22.8).

The sensory root passes forward and laterally over the apex of the petrous temporal bone to enter the middle cranial fossa. Here it exhibits a rounded enlargement, the **trigeminal (gasserian) ganglion**. The ganglion occupies a

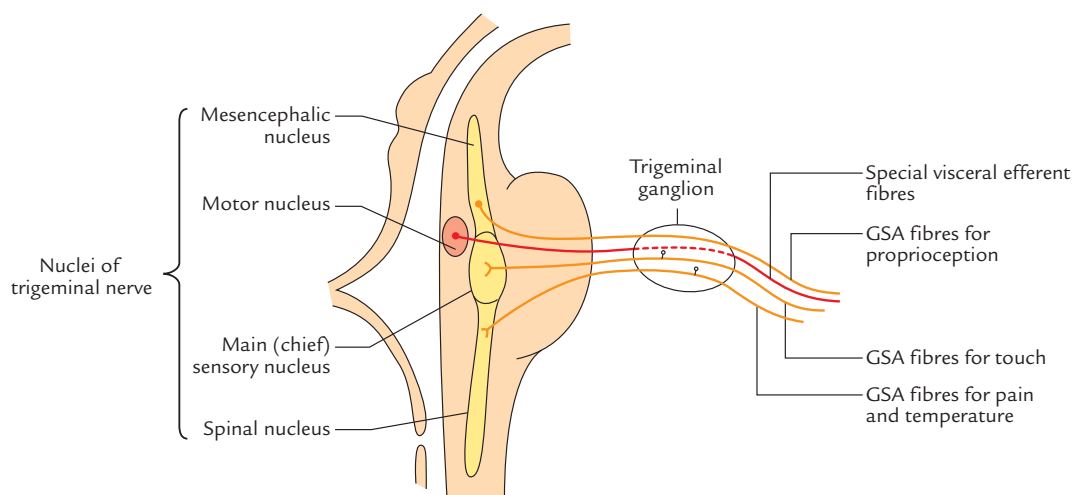


Fig. 22.7 Functional components of the trigeminal nerve.

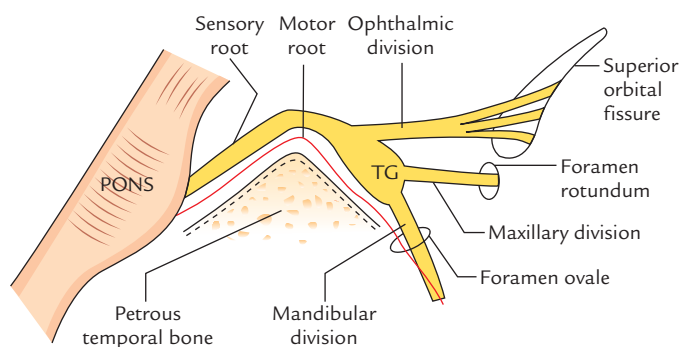


Fig. 22.8 Roots and divisions of the trigeminal nerve (TG = trigeminal ganglion).

dural invagination in a shallow fossa on the anterior surface of the petrous temporal bone.

The subarachnoid expansion over this portion of trigeminal nerve is called **Meckel's cave** (Fig. 21.14). The sensory root may be cut here in order to relieve the pain of trigeminal neuralgia.

The convex distal surface of ganglion gives origin to three large divisions of the trigeminal nerve—ophthalmic, maxillary, and mandibular:

1. The **ophthalmic nerve** (purely sensory) arises from the anterolateral aspect of the ganglion and enters the lateral wall of the cavernous sinus where it lies below the trochlear nerve.

In the cavernous sinus, it divides into three branches: nasociliary, lacrimal, and frontal. All these branches enter the orbit through the superior orbital fissure.

2. The **maxillary nerve** (purely sensory) arises from the ganglion and enters the lateral wall of the cavernous sinus

where it occupies the lowest position and leaves the cavernous sinus to enter the **pterygopalatine fossa** through the **foramen rotundum**.

3. The **mandibular nerve** (the largest division) arises from the trigeminal ganglion and immediately enters the infratemporal fossa through the foramen ovale.

The **motor root** of the trigeminal nerve after emerging from the pons passes forward and laterally deep to the sensory root and trigeminal ganglion and enters the infratemporal fossa through the foramen ovale. After emerging from the foramen ovale, it immediately joins the mandibular nerve and thus the mandibular nerve contains both the motor and sensory fibres.

The ophthalmic division of the maxillary nerve is described in detail in Chapter 19 and maxillary and mandibular divisions in Chapter 10.

Distribution (Fig. 22.9): The summary of distribution of the three divisions of the trigeminal nerve is presented in Table 22.1.

Clinical correlation

Trigeminal neuralgia (*tic douloureux*): It is a clinical condition which presents as a paroxysmal episodes of severe pain of sudden onset and short duration in the area of distribution of one or more of the three divisions of the trigeminal nerve.

The ophthalmic division (CN V1) is not commonly involved. The most commonly trigeminal neuralgia is associated with maxillary (CN V2) and mandibular divisions (CN V3) of the trigeminal nerve. It is often associated with dental caries.

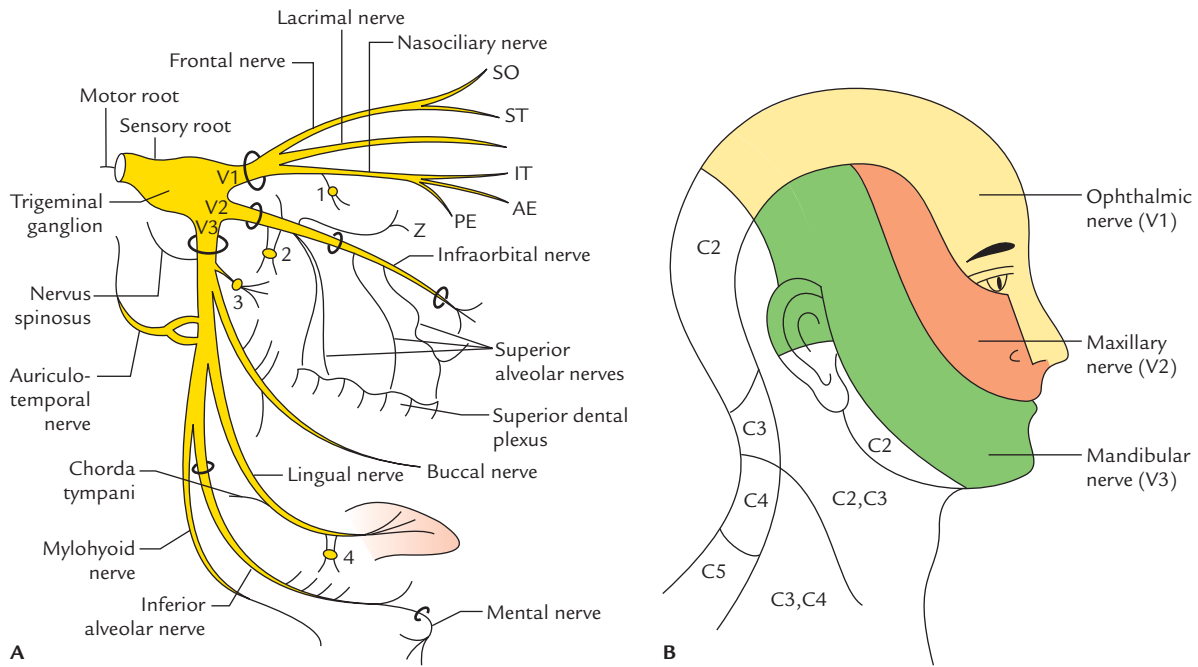


Fig. 22.9 Trigeminal nerve: A, divisions and branches; B, cutaneous distribution (AE = anterior ethmoidal, IT = infratrochlear, PE = posterior ethmoidal, SO = supraorbital, ST = supratrochlear, V1 = ophthalmic division, V2 = maxillary division, V3 = mandibular division 1 = ciliary ganglion, 2 = pterygopalatine ganglion, 3 = otic ganglion, 4 = submandibular ganglion).

Table 22.1 Summary of distribution of three divisions of the maxillary nerve

Nerve/Division	Distribution
Ophthalmic (sensory)	Upper third of the face including eyeball, conjunctiva, nasal cavity, lacrimal gland, scalp up to vertex. Ophthalmic nerve also forms the afferent limb of <i>corneal reflex</i>
Maxillary (sensory)	Middle third of the face including most of nasal cavity, upper teeth and gums, maxillary sinus, mucous membrane of pharynx, palate, dura mater of middle cranial fossa. Maxillary nerve conveys secretomotor fibres to the lacrimal gland and the glands of palate, nose, and oral cavity
Mandibular (mixed)	<i>Sensory:</i> Lower third of the face (except the small area over the angle of mandible) including part of auricle, temple <i>Motor:</i> Muscles of mastication, mylohyoid, anterior belly of digastric, tensor palati, and tensor tympani. Mandibular nerve forms both the limbs of masticatory reflex

FACIAL NERVE

Facial nerve is the 7th cranial nerve. It is a mixed (i.e., motor and sensory) nerve, but predominantly it is motor. It is named facial nerve because it supplies the muscles of facial

expression. *It is the most frequently paralyzed of all the peripheral nerves of the body.*

Functional Components and Nuclei (Fig. 22.10)

1. **Special visceral efferent fibres.** They arise from the motor nucleus of the facial nerve in the pons and supply the muscles of facial expression.

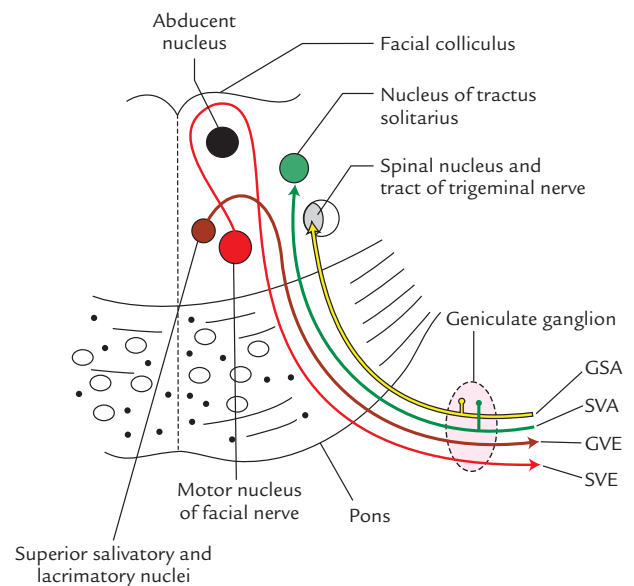


Fig. 22.10 Functional components and nuclei of the facial nerve.

2. **General visceral efferent fibres.** These are preganglionic parasympathetic fibres which arise from lacrimatory and superior salivatory nuclei in the brainstem. They supply the secretomotor fibres to lacrimal, submandibular, and sublingual glands.
3. **Special visceral afferent fibres.** They carry special sensations of taste from anterior two-third of the tongue except vallate papillae and terminate in the nucleus of tractus solitarius (gustatory nucleus) in the brainstem.
4. **General somatic afferent fibres.** They carry general sensations from the skin of the auricle and terminate in the spinal nucleus of the trigeminal nerve.

N.B. The cell bodies of SVA and GVA fibres are located in the geniculate ganglion.

Course and Relations (Fig. 22.11)

This nerve consists of two distinct roots: (a) a large medial motor root (the *facial nerve proper*) and (b) a small lateral sensory root (the *nervous intermedius*). The two roots arise from the pontomedullary junction lateral to the superior end of the olive of the medulla. The sensory root lies between the motor root of facial medially and the vestibulocochlear nerve laterally.

After emerging from the brainstem, the roots of the facial nerve pass laterally and forward in the cerebello-pontine angle, along with the vestibulocochlear and labyrinthine artery. All these structures then enter the internal acoustic meatus. In the meatus, the motor root is lodged in a groove on the vestibulocochlear nerve, while the sensory root remains separate. At the lateral end (bottom) of the internal acoustic meatus, two roots unite to form the trunk of the facial nerve. (Here it is important to note that the bottom or fundus of the internal acoustic meatus forms the medial wall of the bony labyrinth of the internal ear.) The facial nerve enters the facial canal in the petrous temporal bone through its opening in the fundus of the internal acoustic meatus.

The facial canals divide into three segments: labyrinthine, tympanic, and mastoid.

The labyrinthine segment of the facial canal lies above the vestibule of bony labyrinth and bends to reach the anterosuperior part of the medial wall of the middle ear (tympanum) near the processus cochleariformis. Here the canal bends sharply backward. The facial nerve coursing through the labyrinthine segment of canal also makes a sharp bend called the **external genu of the facial nerve** which possesses the geniculate ganglion.

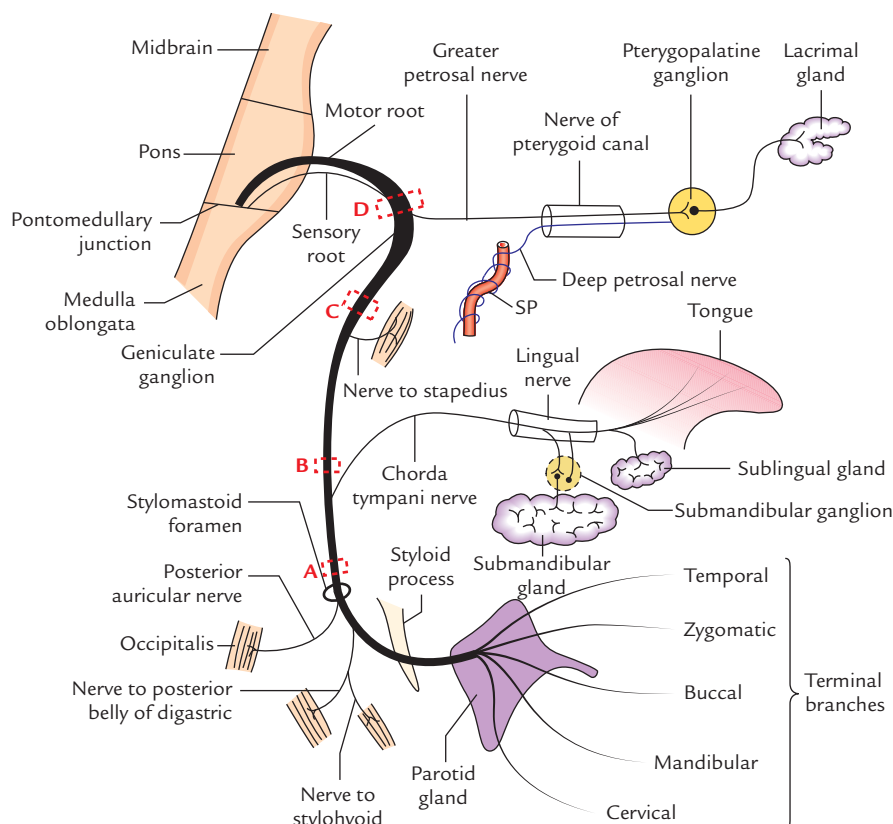


Fig. 22.11 Origin, course, and distribution of the facial nerve (SP = sympathetic plexus around internal carotid artery).

The **tympanic segment** of the facial canal runs horizontally backward in the medial wall of the middle ear till it reaches the junction of the medial and posterior wall of the middle ear. The bulge of the tympanic segment of the facial canal is seen in the medial wall of the middle ear above the promontory and fenestra vestibuli and below the bulge produced by the lateral semicircular canal.

The **mastoid segment** begins at the junction of the medial and posterior wall of the middle ear and passes vertically downward in the posterior wall of the middle ear till it reaches the stylomastoid foramen at the base of the skull.

The facial nerve comes out of cranial cavity through the stylomastoid foramen.

The external cranial of the facial nerve is described in Chapter 8.

Branches and Distribution (Fig. 22.11)

- Greater petrosal nerve**—arises from the geniculate ganglion. It consists of preganglionic parasympathetic fibres which relay in the pterygopalatine ganglion and supply the secretomotor fibres to the lacrimal gland and the mucous glands of nasal cavity and palate.
 - Nerve to stapedius**—arises from the vertical part of the facial nerve opposite the pyramidal eminence, runs forward through a short canal within it to reach the stapedius muscle to supply it.
 - Chorda tympani nerve**—arises from the vertical part of the facial nerve about 6 mm above the stylomastoid foramen, and enters the middle ear through the *posterior canaliculus* (on the posterior wall of the middle ear), runs across its lateral wall of the middle ear (pars flaccida of the tympanic membrane); passing between the long process of incus and the handle of malleus, and leaves the middle ear by entering the *anterior canaliculus* (on the anterior wall of the middle ear). It then traverses through the bony canaliculus and enters the inferotemporal fossa through the medial end of *petrotympanic fissure*. After emerging from the petrotympanic fissure, it runs medially forward and downward, crossing the medial aspect of the spine of sphenoid, to join the posterior aspect of the lingual nerve.
- The chorda tympani nerve consists of two types of fibres:
- Preganglionic parasympathetic (GVE) fibres*, which provide secretomotor supply to the submandibular and sublingual glands.
 - Special visceral afferent fibres*, which carry taste sensations from anterior two-third of the tongue.
- Posterior auricular nerve**—supplies the occipital belly of occipitofrontalis.
 - Nerve to the posterior belly of digastric**—supplies the concerned muscle.
 - Nerve to stylohyoid**—supplies the concerned muscle.
- Five terminal branches** (temporal, zygomatic, buccal, marginal, mandibular, and cervical)—supply the muscles of facial expression.

Clinical correlation

- **Lesions of facial nerve:** These can be supranuclear or infranuclear (Fig. 22.12).

A *supranuclear lesion* (i.e., in hemiplegia) spares the upper part of the face because nuclear fibres supplying the muscles of the upper part of the face are innervated by the corticonuclear fibres of both the cerebral hemispheres. In the supranuclear lesion, only lower half of the face on the opposite side is paralyzed.

All *infranuclear lesions* involve whole of the face on the same side.

The signs and symptoms of infranuclear lesions differ according to the site of the lesion:

Site A *At or just above the stylomastoid foramen:* It causes *Bell's palsy* which presents as loss of motor functions of all muscles of facial expression leading to the deviation of mouth toward the normal side, inability to close the mouth and eye, and accumulation of food in the vestibule of mouth flattening of expression lines (for details see page 58).

Site B *Above the origin of chorda tympani:* All the signs and symptoms of lesion A (i.e., Bell's palsy) plus decreased salivation and loss of taste sensations in the anterior two-third of the tongue.

Site C *Above the origin of nerve to stapedius:* All the signs and symptoms of lesion B plus *hyperacusis* (i.e., enhanced sensitivity to hearing).

Site D *At the geniculate ganglion:* All the signs and symptoms of lesion C plus loss of lacrimation.

- **Crocodile tears syndrome:** It is a clinical condition characterized by paroxysmal lacrimation during eating. It results in the facial nerve lesion proximal to the geniculate ganglion because regenerating preganglionic fibres meant to provide secretomotor supply to the submandibular and sublingual salivary glands during regeneration are misdirected and grow in the endoneural sheaths of preganglionic secretomotor fibres which supply the lacrimal gland.

- **Ramsay Hunt syndrome:** It occurs due to the involvement of geniculate ganglion in herpes zoster infection. Clinically, it presents with the following signs and symptoms:

- Herpetic vesicles on the auricle.
- Hyperacusis.
- Loss of lacrimation.
- Loss of taste sensations in the anterior two-third of the tongue.
- Complete ipsilateral facial palsy (Bell's palsy).

VESTIBULOCOCHLEAR NERVE

Vestibulocochlear nerve is the 8th cranial nerve. It consists of two distinct parts: (a) a vestibular part, called the **vestibular**

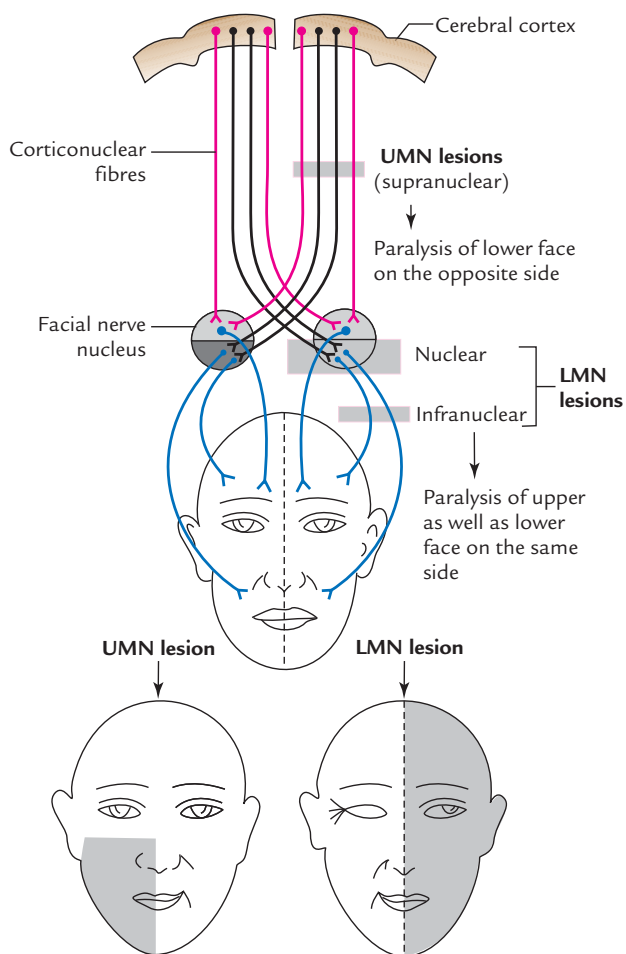


Fig. 22.12 Effects of supranuclear (UMN) and infranuclear (LMN) lesions of the facial nerve.

nerve, and (b) a cochlear part, called the cochlear nerve (Fig. 22.13). The vestibular nerve is concerned with the maintenance of **equilibrium**, while the cochlear nerve is concerned with **hearing**.

Functional Component and Nuclei

Special somatic afferent fibres: They carry sensory information necessary for the maintenance of equilibrium and hearing from the membranous labyrinth of the internal ear.

The fibres carrying the sensory information for equilibrium terminate in the vestibular nuclei within the brainstem.

The fibres carrying the sensory information for hearing terminate in the dorsal and ventral cochlear nuclei, located respectively on the dorsal and ventral aspects of the inferior cerebellar peduncle.

Course and Relations

The *vestibular nerve* arises from the lateral aspect of the pontomedullary junction, passes through the pontocerebellar angle and enters the internal acoustic meatus along with the facial nerve and labyrinthine vessels.

The *vestibular ganglion* (also called *Scarpa's ganglion*) is located on the vestibular nerve in the lateral part of the internal acoustic meatus. It consists of bipolar sensory neurons. In the lateral part of the internal acoustic meatus, the nerve divides into three distinct branches: superior and inferior divisions and singular nerve. These branches pass through the foramina in the fundus of the meatus and innervate the sensory receptors for equilibrium (cristae ampullaris and maculae) in the membranous labyrinth of the internal ear.

The *cochlear nerve* also arises from the lateral aspect of the pontomedullary junction and takes a similar course to enter the internal acoustic meatus. At the medial end of the internal acoustic meatus, it enters into bony labyrinth of the middle ear through *tractus spiralis foraminosus* in the fundus of the meatus and reaches the modiolus of the internal ear. In the modiolus, the cochlear nerve possesses a sensory ganglion called the *spiral ganglion* made of bipolar neurons. The peripheral process of these neurons innervates the sensory receptor of hearing—the *organ of Corti*.

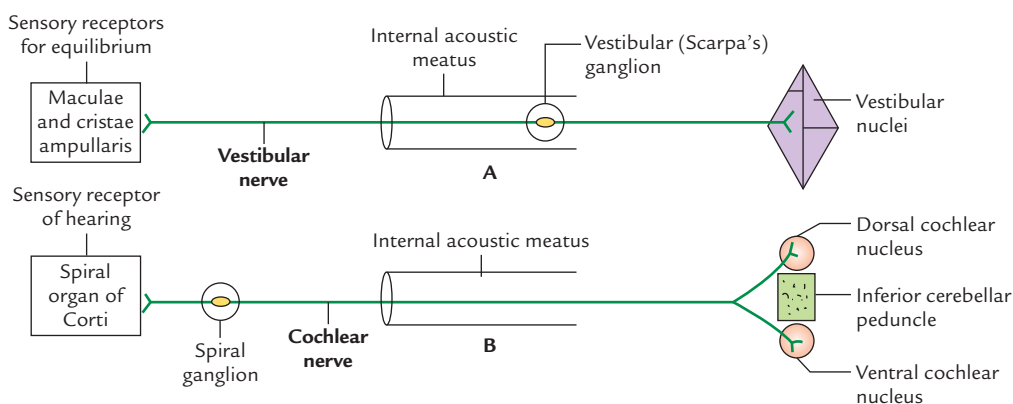


Fig. 22.13 Schematic diagram showing the course and distribution of the vestibular and cochlear nerves: A, vestibular nerve; B, cochlear nerve.

Clinical correlation

- **Lesions of vestibulocochlear nerve:** The lesions of the vestibulo-cochlear nerve clinically present as:
 - (a) *tinnitus* (ringing or buzzing in the ears),
 - (b) *impairment or loss of hearing*, and
 - (c) *loss of balance (vertigo)*.

The vestibular nerve is commonly involved by *acoustic neuroma*, which arises from the sheath cells of its constituent fibres in the region of cerebellopontine angle. The acoustic neuroma is one of the common intracranial tumors, and if large, it may involve the adjacent trigeminal, facial, and glossopharyngeal nerves and may compress cerebellum and medulla.

THE LAST FOUR CRANIAL NERVES

The last four cranial nerves are the nerves of the neck and closely related to each other, hence described together. The last four cranial nerves leave the skull close together, the glossopharyngeal, vagus, and accessory through the jugular foramen, and the hypoglossal nerve through the hypoglossal canal (Fig. 22.14).

At first, they lie between the internal jugular vein and the internal carotid artery, where the cranial root of the accessory nerve joins the vagus nerve and is distributed through it. Thereafter, the glossopharyngeal nerve passes forward across the internal carotid artery and then deep to the external carotid artery. The spinal accessory nerve passes backward

across the internal jugular vein and the vagus nerve passes straight down in the deeper plane between the internal jugular vein and the internal carotid artery. The hypoglossal nerve is medial to others, curves round behind the vagus nerve, and then passes forward, superficial to the vagus nerve, internal carotid, and external carotid arteries.

The close relationship of the last four cranial nerves can be well appreciated by studying the features of the base of the skull around the jugular foramen.

The **jugular foramen** is located in front of the jugular process of the occipital bone. The jugular fossa is a bony depression between the jugular foramen and base of the skull.

GLOSSOPHARYNGEAL NERVE

Glossopharyngeal nerve is the 9th cranial nerve. It is a mixed nerve, i.e., composed of both the motor and sensory fibres, but predominantly it is sensory. It derives its name from the fact that it provides sensory innervation to the tongue and pharynx.

Functional Components and Nuclei (Fig. 22.15)

1. **Special visceral efferent fibres:** They supply the stylopharyngeus muscle. They arise from *nucleus ambiguus*.
2. **General visceral efferent fibres:** They supply the secretomotor fibres to the parotid gland. They are

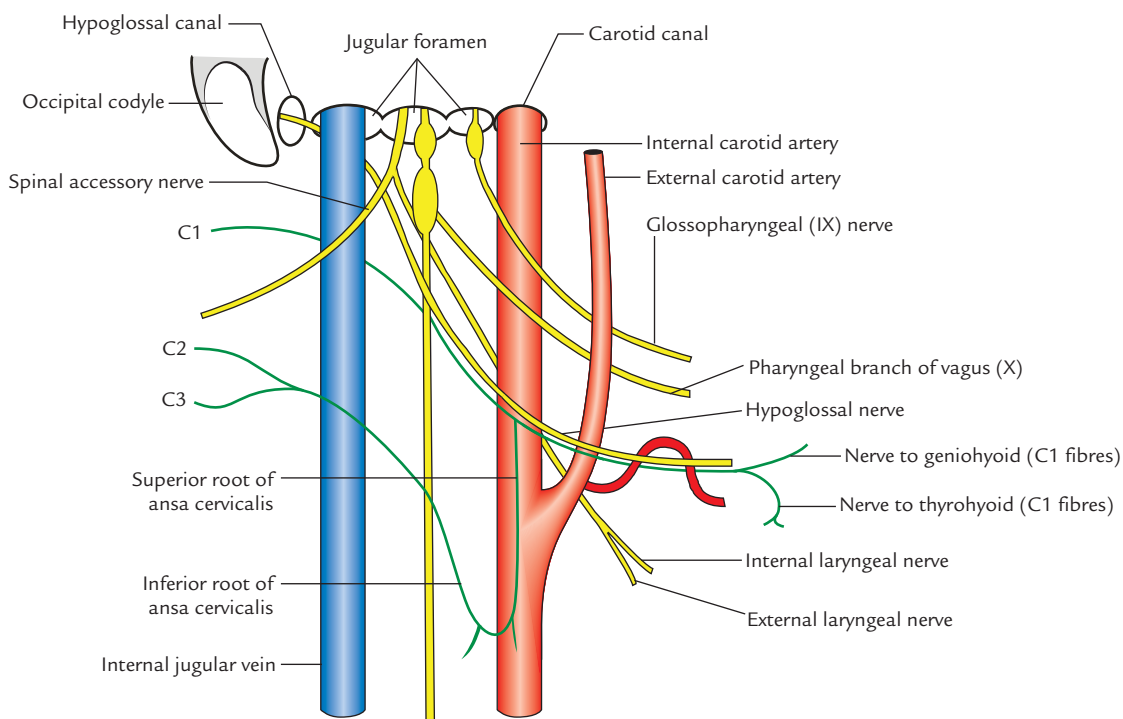


Fig. 22.14 Relationship of the last four cranial nerves at the base of the skull.

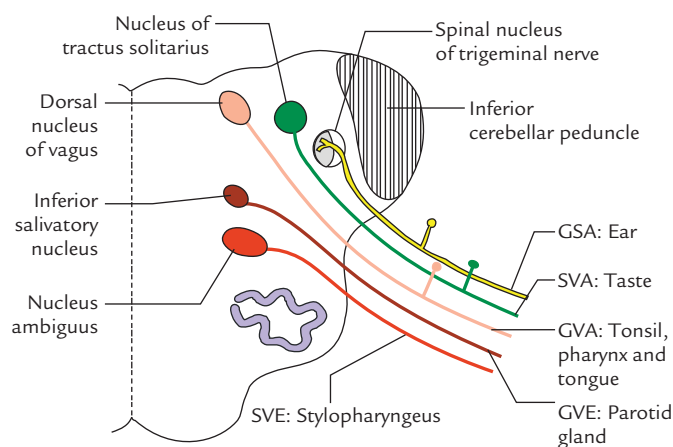


Fig. 22.15 Functional components and nuclei of the glossopharyngeal nerve.

preganglionic parasympathetic fibres and arise from the *inferior salivatory nucleus*.

3. **Special visceral afferent fibres:** They carry taste sensations from the posterior one-third of tongue including vallate papillae and terminate in the *nucleus tractus solitarius*.
4. **General visceral afferent fibres:** They carry general sensations of pain, touch, and temperature from the mucous membrane of the pharynx, tonsil, soft palate, and the posterior one-third of tongue and terminate in the dorsal nucleus of the vagus.
5. **General somatic afferent fibres:** They carry proprioceptive sensations from the stylopharyngeus and skin of the auricle and terminate in the *nucleus of the spinal tract of 5th nerve*.

Course and Relations (Fig. 22.16)

The glossopharyngeal nerve arises from the upper part of the lateral aspect of the medulla between the olive and the inferior cerebellar peduncle by three or four rootlets. The rootlets unite to form a single trunk which runs forward and laterally to leave the cranial cavity by passing through the intermediate compartment of the jugular foramen enclosed in a separate sheath of dura mater.

The **superior and inferior sensory ganglia** are located on the nerve as it passes through the jugular foramen.

The **smaller superior ganglion** lies within the jugular foramen and is considered the detached part of the inferior ganglion.

The **larger inferior ganglion** lies just below the jugular foramen and contains the cell bodies of most of the sensory fibres of the nerve.

After emerging from the jugular foramen at the base of the skull, the nerve passes downward and forward between the internal carotid artery and the internal jugular vein. It then descends anterior to the internal carotid artery to the styloid process and muscles attached to it (in this position,

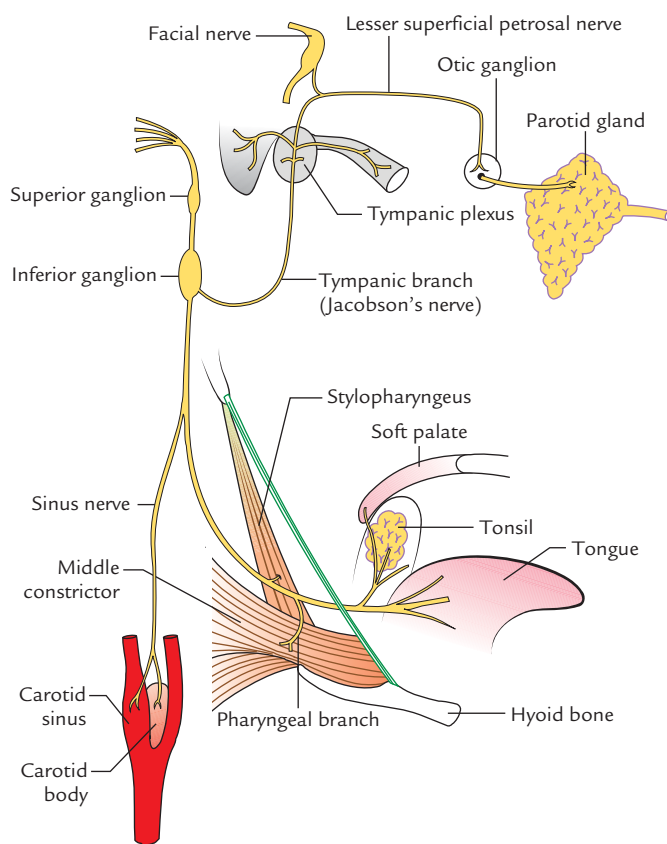


Fig. 22.16 Course and distribution of the glossopharyngeal nerve.

it lies lateral to the tonsillar bed formed by the superior constrictor) to reach the lower border of the stylopharyngeus. From here it passes along with the stylopharyngeus through the gap between the superior and middle constrictors of the pharynx.

It then curves forward along the lateral aspect of the stylopharyngeus muscle which it supplies, and then passes deep to the stylohyoid ligament and posterior edge of the hyoglossus muscle. Here it breaks up into terminal branches, which supply the mucous membrane of the posterior one-third of the tongue, pharynx, and tonsil.

Branches and Distribution

The glossopharyngeal nerve gives the following important branches:

1. **Tympanic branch (Jacobson's nerve):** It leaves the inferior ganglion and enters the middle ear through the tympanic canaliculus situated at the bony edge between the jugular foramen and carotid canal. It forms the tympanic plexus over the promontory of the middle ear. The tympanic plexus gives off:
 - (a) the lesser petrosal nerve and
 - (b) twigs to tympanic cavity, auditory tube, and mastoid air cells.

The lesser petrosal nerve carries the preganglionic parasympathetic fibres which relay in the otic ganglion. The postganglionic fibres from the ganglion supply the parotid gland.

2. **Carotid nerve (nerve of Herring):** It is a branch to carotid sinus and carotid body. It serves as an afferent limb for pressoreceptor and chemoreceptor reflexes from the carotid sinus and carotid body to regulate the heart rate and respiration, respectively.
3. **Pharyngeal branch:** It joins the pharyngeal branches of the vagus and the cervical sympathetic chain to form the *pharyngeal plexus* on the middle constrictor of the pharynx.
4. **Branch to stylopharyngeus:** It arises as the nerve, winds round the stylopharyngeus muscle. *It is the only motor branch of the glossopharyngeal nerve.*
5. **Tonsillar branches:** They supply the mucous membrane of tonsil, fauces, and palate.
6. **Lingual branches:** They supply the posterior one-third of the tongue and vallate papillae and convey taste and general sensations.

Clinical correlation

- **Lesions of glossopharyngeal nerve:** The lesion of the glossopharyngeal nerve is rare in isolation since there is often associated involvement of the vagus nerve. However, the complete lesion of the glossopharyngeal nerve results in:
 - (a) the loss of taste and general sensations over the posterior one-third of the tongue,
 - (b) difficulty in swallowing,
 - (c) the loss of the salivation from the parotid gland, and
 - (d) the unilateral loss of the gag reflex (see Chapter 14).
- **Glossopharyngeal neuralgia,** although rare, may occur. It is characterized by paroxysmal attacks of intractable pain in the area of the sensory distribution of the glossopharyngeal nerve, e.g., throat, tongue, and ear, precipitated by swallowing.
- **Clinical testing of glossopharyngeal nerve:** The glossopharyngeal nerve can be tested clinically by:
 - (a) *eliciting the gag reflex* (i.e., on tickling the posterior wall of the pharynx, soft palate, or tonsillar fossa, there is reflex contraction of pharyngeal muscles causing gagging and retching), and
 - (b) *testing the taste sensations in the posterior one-third of the tongue.*

VAGUS NERVE

Vagus nerve is the 10th cranial nerve. It is a mixed nerve, i.e., composed of both the motor and sensory fibres but predominantly it is motor. It is the longest and most widely distributed cranial nerve. It is so called because of its extensive vague course and distribution. It is a vagrant or

wandering nerve. Its field of distribution extends beyond the head and neck—to the thorax and abdomen. It conveys most of the efferent fibres of the cranial part of the parasympathetic outflow and distributes the fibres of an cranial part of the accessory nerve.

Functional Components and Nuclei (Fig. 22.17)

1. **Special visceral efferent fibres:** supply the muscles of palate, pharynx, and larynx. They arise from *nucleus ambiguus*.
2. **General visceral efferent fibres:** arise from the *dorsal nucleus of vagus*, and provide parasympathetic innervation to heart, bronchial tree, and most of the GIT.
3. **Special visceral afferent fibres:** carry taste sensations from the posteriormost part of the tongue and epiglottis and terminate in the *nucleus tractus solitarius*.
4. **General visceral afferent fibres:** carry general sensations from the mucous membrane of pharynx, larynx, trachea, esophagus, and thoracic and abdominal viscera and terminate in the nucleus tractus solitarius and some in the *dorsal nucleus of the vagus*.
5. **General somatic afferent fibres:** carry general sensations from skin of the auricle and terminate in the *nucleus of the spinal tract of the trigeminal nerve*.

Course and Relations (Fig. 22.18)

The vagus nerve arises from the lateral aspect of the medulla between the olive and inferior cerebellar peduncle by about 10 rootlets below and in line of the rootlets of the glossopharyngeal nerve. These nerve rootlets unite to form the nerve trunk which runs laterally, crosses the jugular tubercle, and leaves the cranial cavity by passing through the middle part of the jugular foramen enclosed in the common dural sheath with the 11th nerve.

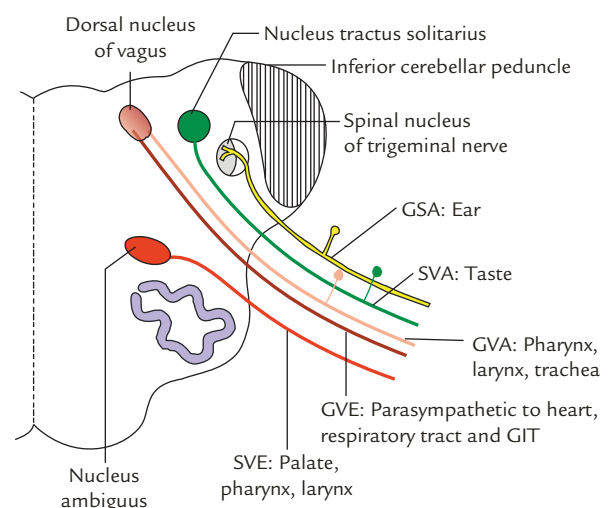


Fig. 22.17 Functional components and nuclei of the vagus nerve.

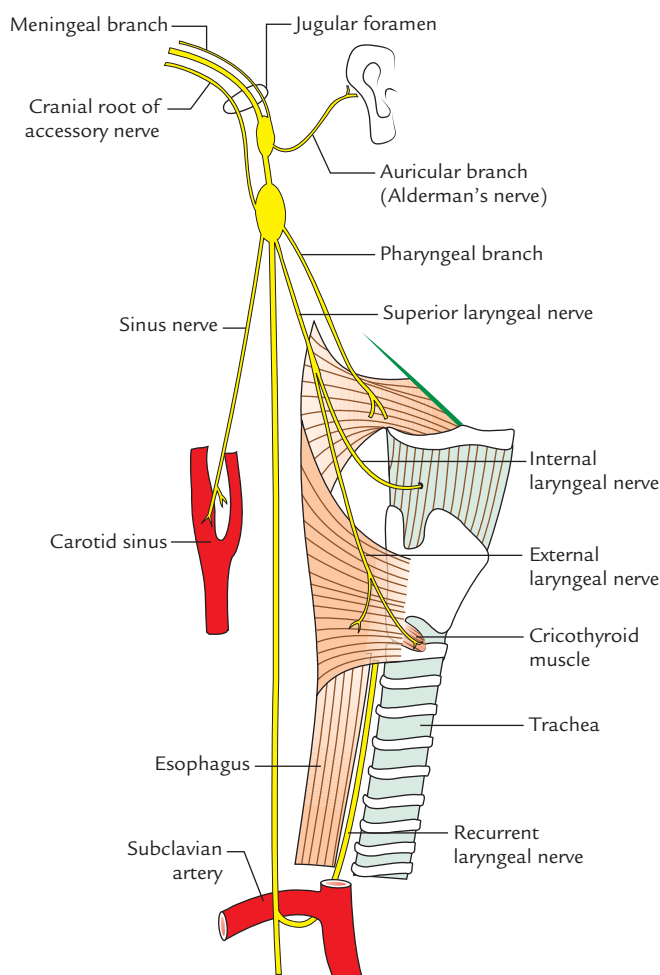


Fig. 22.18 Course and distribution of the vagus nerve (right) in the head and neck.

The superior and inferior sensory ganglia are located on the nerve as it passes through the jugular foramen:

1. A smaller **superior ganglion** lies within the jugular foramen.
2. The larger **inferior (nodose) ganglion** lies just below the jugular foramen. Both the ganglia contain the cell bodies of the sensory fibres of the vagus nerve. The *superior ganglion* contains the cell bodies of GSA fibres, whereas the inferior ganglion contains the cell bodies of visceral afferent fibres. The cranial root of the accessory (11th) nerve unites with the vagus nerve just below its inferior ganglion and thus transfers all its fibres to the vagus nerve for distribution.

After coming out of the cranial cavity through the jugular foramen, the nerve runs vertically downward within the carotid sheath in the neck first between the internal jugular vein laterally and the internal carotid artery medially and then between the internal jugular vein (laterally) and the common carotid artery (medially).

At the root of the neck, the nerve enters the thorax. The **right vagus nerve** enters the thorax by crossing in front of the right subclavian artery, whereas the **left vagus nerve** enters the thorax by passing between the left common carotid and left subclavian arteries.

For course of vagus nerves in the thorax, see *Textbook of Anatomy: Upper Limb and Thorax*, Vol. I by Vishram Singh.

Branches and Distribution (Fig. 22.18)

The branches and distribution of the vagus nerve in the region of head and neck are as follows:

1. **Meningeal branch:** It arises from the *superior ganglion*, takes a recurrent course, and enters the cranial cavity through the jugular foramen to supply the dura mater of the posterior cranial fossa.
2. **Auricular branch (Arnold's nerve or Alderman's nerve):** It arises from the *superior ganglion*, enters the *mastoid canaliculus* on the lateral wall of the jugular fossa, and emerges through the tympanomastoid fissure just behind the external auditory meatus to supply the skin on the back of the meatus and adjoining part of the auricle. Then it enters the meatus between its bony and cartilaginous parts to supply the floor of the meatus and the tympanic membrane. Stimulation of this nerve, as in syringing of the ear, may cause reflex coughing (**ear cough**), vomiting, and even cardiac arrest.
3. **Pharyngeal branch:** It arises from the *inferior ganglion*, passes forward between the internal and external carotid arteries, and takes part in the formation of pharyngeal plexus. It supplies:
 - (a) all the muscles of pharynx *except* the stylopharyngeus, which is supplied by the glossopharyngeal nerve, and
 - (b) all the muscles of soft palate *except* the tensor palati which is supplied by the mandibular nerve (through the nerve to medial pterygoid).
4. **Branches to carotid body:** It arises from the inferior ganglion.
5. **Superior laryngeal nerve (nerve of 4th arch):** It arises from the *inferior ganglion*, passes downward and forward deep to the internal carotid artery to reach the middle constrictor where it divides into external and internal laryngeal nerves:
 - (a) The *external laryngeal nerve (motor)* runs downward in company with superior thyroid vessels and supplies cricothyroid muscle. It also gives twigs to the inferior constrictor and pharyngeal plexus.
 - (b) The *internal laryngeal nerve (sensory)* passes downward and forward toward the gap between the middle and inferior constrictors. It pierces the thyrohyoid membrane to enter the larynx. It supplies the:

- (i) mucous membrane of larynx above the vocal cords, and
 - (ii) mucous membrane of the pharynx, epiglottis, vallecula, and the posteriormost part of the tongue.
6. **Superior and inferior cervical cardiac branches:** The *superior cardiac branch* arises in the upper part of the neck and the inferior cardiac branch in the lower part of the neck. They enter the thorax through the thoracic inlet. They carry preganglionic parasympathetic fibres to the heart and are cardio-inhibitory. The *inferior cervical cardiac branch* of the left vagus nerve joins the *superficial cardiac plexus*. The remaining cervical cardiac branches of both the vagus nerves join the *deep cardiac plexus*.
7. **Recurrent laryngeal nerve (nerve of 6th arch):**
- (a) *On the right side*, it arises in the root of the neck from the vagus nerve as it crosses in front of the subclavian artery, winds around the first part of the subclavian artery, and then ascends up (in a recurrent direction) in the tracheoesophageal groove.
 - (b) *On the left side*, it arises in the superior mediastinum from the vagus nerve as it crosses the arch of the aorta (lateral aspect). It hooks below the arch of the aorta on the left side of *ligamentum arteriosum* behind the arch of aorta on its way to the tracheoesophageal groove.

The recurrent laryngeal nerve provides motor innervation to all the intrinsic muscles of the larynx (*except* the cricothyroid which is supplied by the external laryngeal nerve) and sensory innervation to the mucous membrane of laryngeal cavity up to the vocal cord.

Each recurrent laryngeal nerve passes deep to the inferior constrictor muscle to enter the laryngeal cavity deep to the cricothyroid joint. Now it is called the *inferior laryngeal nerve*.

Clinical correlation

- **Alderman's nerve phenomenon:** The tickling of the cutaneous distribution of the vagus nerve stimulates jaded appetite. The Alderman in ancient Roman days used to stimulate their appetite by dropping cold water behind the ear supplied by the *auricular branch of the vagus nerve*. For this reason, the auricular branch of the vagus nerve is also called *Alderman's nerve*. Apparently, this occurs by a reflex increase in gastric motility supplied by the vagus nerve (to the stomach).
- **Lesions of vagus nerve:** The bilateral lesions of vagus nerve cause:
 - (a) nasal regurgitation of the swallowed liquids,
 - (b) nasal twang of voice,
 - (c) hoarseness of voice,
 - (d) flapping of palatal arches,
 - (e) cadaveric position of vocal cords,
 - (f) dysphagia, and
 - (g) loss of cough reflex.

- **Clinical testing of vagus nerve:** The vagus nerve can be tested clinically by asking the patient to open his mouth and say 'ah', and then comparing the palatal arches of the two sides. If the vagus is intact, the soft palate rises (is elevated) in the midline. In bilateral lesions, the soft palate drops. In the unilateral lesion, there is flattening (drooping) of palate arch on the side of paralysis and uvula pulled to the normal side.

ACCESSORY NERVE

Accessory nerve is the 11th cranial nerve. It is purely motor. It consists of two roots: cranial and spinal.

The **cranial root** is accessory to the vagus and its fibres are distributed through the vagus nerve.

The **spinal root** has an independent course and is generally regarded as **spinal accessory nerve**, or simply as **accessory nerve**.

Functional Components and Nuclei (Fig. 22.19)

1. **Special visceral efferent fibres:** provide motor supply to the muscles of soft palate, pharynx, and larynx. They arise from the *nucleus ambiguus* and form the cranial root.
2. **General somatic efferent fibres:** provide motor supply to the sternocleidomastoid and trapezius muscles. They arise from the *spinal nucleus of accessory nerve*, in the ventral horns of the upper five spinal segments and form the spinal root.

Course and Relations (Fig. 22.20)

The **cranial root** arises by four or five rootlets from the posterolateral sulcus of the medulla between the olive and inferior cerebellar peduncle. The rootlets are attached in line with the rootlets of the vagus nerve above. These rootlets

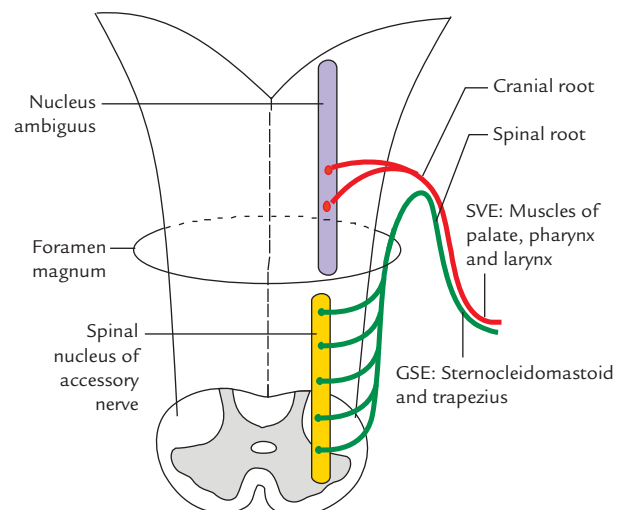


Fig. 22.19 Functional components and nuclei of the accessory nerve.

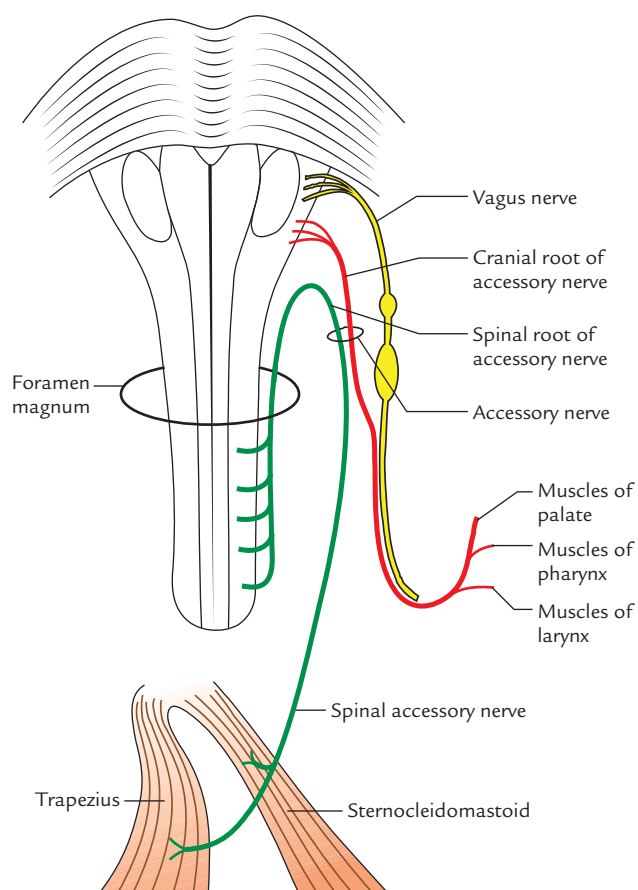


Fig. 22.20 Distribution of the cranial and spinal roots of the accessory nerve.

unite together to form a single trunk which runs laterally along with the 9th and 10th cranial nerves to reach the jugular foramen where it is joined by the spinal root.

The **spinal root** arises by a number of rootlets from the lateral aspect of the spinal cord (upper five cervical spinal segments) along a vertical line between the ventral and dorsal roots of the spinal nerves. These rootlets unite to form a single trunk which ascends in the vertebral canal to enter the cranial cavity through the foramen magnum behind the vertebral artery. The spinal root leaves the skull through the jugular foramen where it fuses with the cranial root. The combined trunk comes out of the cranial cavity through the middle compartment of the jugular foramen enclosed in the dural sheath along with the vagus nerve. Immediately after coming out of the cranial cavity, the two roots again separate. The cranial root joins the vagus nerve just below its inferior ganglion and is distributed through the branches of the vagus to the muscles of the palate, pharynx, and larynx.

The spinal root of the accessory nerve descends vertically downward between the internal jugular vein and the internal carotid artery. As it reaches a point midway between the angle of the mandible and the mastoid process, it turns downward and backward across (superficial or deep) the

internal jugular vein toward the carotid triangle. It crosses in front of the transverse process of the atlas under the posterior belly of the digastric muscle and occipital artery. Here it is accompanied by the upper sternomastoid branch of the occipital artery.

The nerve pierces the sternocleidomastoid muscle at the junction of its upper one-fourth with the lower three-fourth and supplies it. The nerve passes through the muscle and emerges through its posterior border a little above its middle to enter the posterior triangle where it runs downward and backward underneath the fascial roof of the posterior triangle, parallel to the fibres of levator scapulae.

It leaves the posterior triangle by passing deep to the anterior border of the trapezius about 5 cm above the clavicle.

The spinal accessory nerve communicates with the C2, C3, and C4 spinal nerves. The C2 and C3 spinal nerves carry proprioceptive fibres from the sternocleidomastoid while C3 and C4 carry proprioceptive fibres from the trapezius muscle.

Distribution (Fig. 22.20)

The **cranial root** of the accessory nerve via the vagus nerve and pharyngeal plexus of nerves supplies:

1. All the muscles of the palate *except* the tensor palati and tensor tympani which are supplied by the mandibular nerve (nerve to medial pterygoid):
 - (a) All the muscles of the pharynx *except* the stylopharyngeus which is supplied by the glossopharyngeal nerve.
 - (b) All the intrinsic muscles of larynx.

The **spinal root** of the accessory nerve supplies the following two muscles:

1. Sternocleidomastoid muscle along with C2 and C3 spinal nerves.
2. Trapezius muscle along with C3 and C4 spinal nerves.

Clinical correlation

- **Lesions of spinal accessory nerve:** It may be damaged by the fracture base of the skull through the jugular foramen or stab wounds in the neck or during the surgical removal of cervical lymph nodes.

Unilateral/lesion of the spinal accessory nerve proximal to sternocleidomastoid causes:

- *ipsilateral paralysis of the sternocleidomastoid*, with the result that the patient is unable to tilt his head toward the ipsilateral shoulder and unable to turn his face toward the opposite side,
- *paralysis of trapezius*, with the result that the patient is unable to shrug his shoulder against the resistance.

- **Spasmodic torticollis:** It may result from irritative central lesions of the spinal accessory nerve. It is characterized by clonic spasms of the sternocleidomastoid muscle.

- **Clinical testing of spinal accessory nerve:** The *sternocleidomastoid muscle* is tested by asking the patient to turn his face to the opposite against the resistance offered by the examiner's hand. In a normal condition, a person can do it and sternocleidomastoid stands out prominently.

The *trapezius muscle* can be tested by asking the patient to shrug his shoulder against the resistance.

HYPOGLOSSAL NERVE

Hypoglossal nerve is the 12th cranial nerve. It is purely a motor nerve.

Functional Components and Nuclei (Fig. 22.21)

General somatic efferent fibres: These fibres arise from the hypoglossal nucleus and supply all the muscles of the tongue (extrinsic and intrinsic) which develop from occipital myotomes.

Course and Relations

The hypoglossal nerve arises on the ventral aspect of the medulla from the anterolateral sulcus between the pyramid and the olive by 10–15 rootlets.

The rootlets of the hypoglossal nerve are attached in line with the rootlets of the ventral root of the 1st cervical spinal nerve.

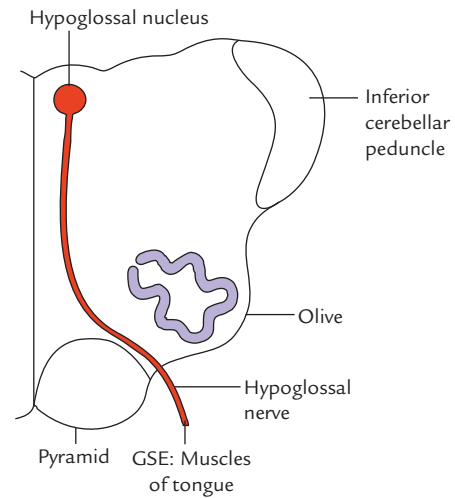


Fig. 22.21 Functional components and nucleus of the origin of the hypoglossal nerve.

The rootlets of the hypoglossal nerve run laterally and pass behind the vertebral artery to form two roots. The two roots pierce the dura mater separately near the anterior condylar (hypoglossal canal) in which they enter. In the canal, the two roots unite to form a single trunk and come out of the cranial cavity.

After coming out of the cranial cavity, the nerve lies deep to the internal carotid artery and the 9th and 10th cranial

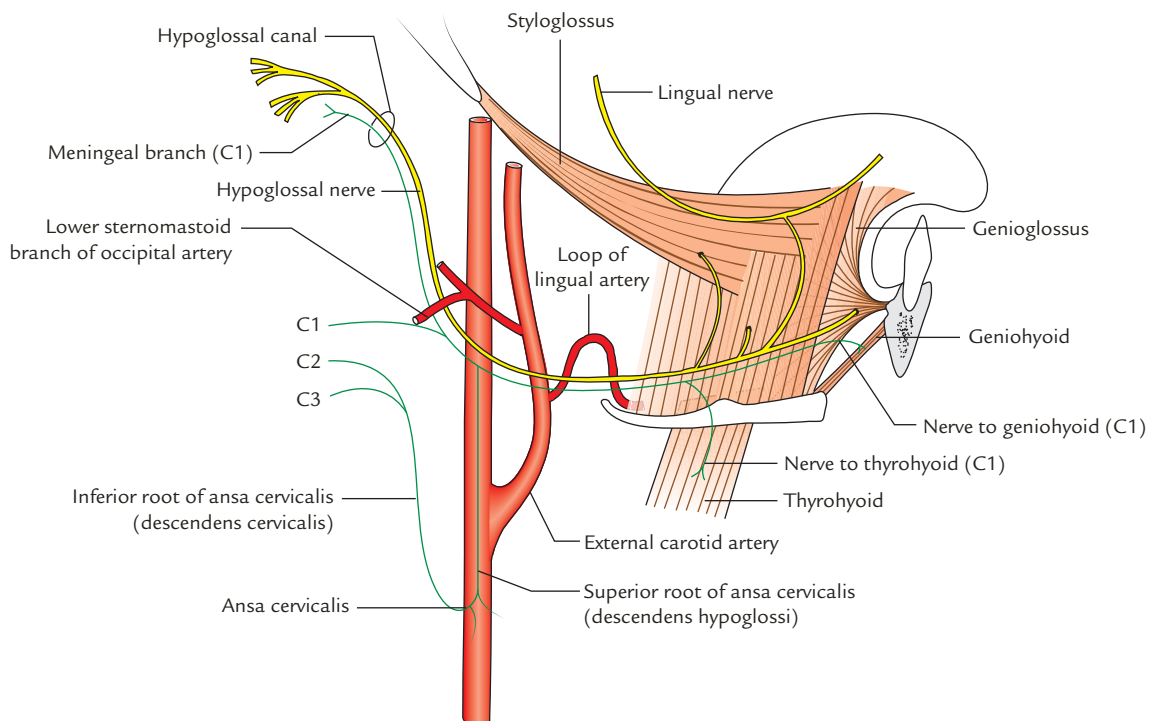


Fig. 22.22 Course and distribution of the hypoglossal nerve.

nerves. It then passes downward and laterally behind the internal carotid artery and the 9th and 10th cranial nerves to reach the interval between the internal jugular vein and the internal carotid artery. Now it descends vertically in this interval in front of the 10th nerve up to the level of the angle of the mandible. Here the nerve curves forward crossing in front of the internal and external carotid arteries, and the loop of the 1st part of the lingual artery to reach the posterior margin of the hypoglossal muscle by passing deep to the tendon of the posterior belly of the digastric. Now it runs on the superficial surface of the hypoglossus, muscle below the deep part of the submandibular gland. At the anterior margin of the hyoglossus it lies on the genioglossus and runs forward and upward up to the tip of the tongue and ends by dividing into its terminal branches which supply the muscles of the tongue.

N.B. Some fibres of the 1st cervical nerve (ventral ramus) join the hypoglossal nerve and are distributed through its branches.

Branches and Distribution (Fig. 22.22)

The hypoglossal nerve gives the following branches:

1. **Branches of the hypoglossal proper:** They supply all the muscles of the tongue *except* palatoglossus which is supplied by the cranial root of accessory via the pharyngeal plexus.
2. **Branches of the hypoglossal nerve containing C1 fibres:** These are as follows:
 - (a) *Meningeal branch:* It arises from the nerve as it comes out through the hypoglossal canal taking a recurrent course, enters the cranial cavity through the hypoglossal canal, and supplies the dura mater of the posterior cranial fossa.
 - (b) *Descendens hypoglossi* or *upper root of ansa cervicalis:* It arises as the nerve crosses in front of the internal carotid artery. It runs downward to join the inferior root of ansa cervicalis at the level of cricoid cartilage.
 - (c) *Nerve to thyrohyoid:* It crosses the greater cornu of the hyoid bone to reach the muscle.
 - (d) *Nerve to geniohyoid:* It arises from above the hyoid bone.

Clinical correlation

- **Lesions of hypoglossal nerve:** If the hypoglossal nerve is cut on one side, there will be *lower motor neuron type of paralysis* of muscles of the tongue on that side. On asking the patient to protrude his tongue, the tip of the tongue deviates to the paralyzed side due to the unopposed action of the muscles of the healthy side.
- **Supranuclear lesions** involve corticonuclear fibres (upper motor neuron type of paralysis); in addition to paralysis of the muscles, there will also be *fasciculations* in tongue on the affected side and the mucous membrane will show wrinkling due to wasting of muscles and their fasciculations.
- **Clinical testing of hypoglossal nerve:** To test the integrity of the hypoglossal nerve, the functions of genioglossus muscles are assessed. The patient is asked to protrude the tongue. If the hypoglossal nerves of both sides are intact, the protruded tongue lies in the midline.
 - If the hypoglossal nerve of one side is damaged, the tongue deviates to the side of the lesion/paralysis.
 - If the hypoglossal nerves of both sides are damaged, the patient cannot protrude his tongue. It lies motionless in mouth causing difficulty in speech and swallowing.

Golden Facts to Remember

- | | |
|---|---|
| ▶ Most slender cranial nerve | Trochlear nerve |
| ▶ All the cranial nerves arise from the ventral aspect of the brain <i>except</i> | Trochlear nerve, which arises from the dorsal aspect of the brain |
| ▶ Largest cranial nerve | Trigeminal nerve |
| ▶ Longest cranial nerve | Vagus nerve |
| ▶ Most frequently paralyzed cranial nerve | Facial nerve |
| ▶ Most commonly involved cranial nerve in increased intracranial pressure | Abducent nerve |
| ▶ All the branches of glossopharyngeal nerve are sensory <i>except</i> | Nerve to the stylopharyngeus which is motor |
| ▶ Most common condition affecting the sensory part of the trigeminal nerve | Trigeminal neuralgia (tic douloureux) |
| ▶ All the sensory ganglia lie outside the cranial cavity <i>except</i> | Trigeminal ganglion which lies within the cranial cavity |
| ▶ Only monosynaptic reflex is present in the brain | Masseteric reflex (or jaw jerk) |
| ▶ Cranial nerve having the longest bony course | Facial nerve |
| ▶ All the cranial nerves are true peripheral nerves <i>except</i> | Optic nerve which is (truelly speaking) a tract of brain |

Clinical Case Study



A 70-year-old patient having long standing high blood pressure suffered from a stroke. He was taken to the hospital where he was diagnosed as a case of hemiplegia. The hemiplegia was associated with the upper motor neuron type of facial palsy. On examination, the lower half of left half of the face was found to be paralyzed. He was able to smile normally when he enjoyed a joke.

Questions

1. Why in the upper motor neuron type of facial palsy the upper part of face is usually spared?
2. How could a hemiplegic patient smile normally?
3. What is Bell's palsy?

Answers

1. Due to the fact that it is innervated by both the cerebral hemispheres.
2. It is thought that such movements (e.g., smile) may have supranuclear connections separate from those commonly involved in hemiplegia, which probably do not descend in the internal capsule.
3. It is the lower motor neuron type of the facial palsy due to the compression of facial nerve at or just above the stylomastoid foramen.

General Plan and Membranes of the Brain

The central nervous system (CNS) consists of brain and the spinal cord. The brain lies within the cranial cavity and the spinal cord lies within the vertebral canal.

Structurally, both the brain and the spinal cord consist of grey and white matter. Therefore, sections through the CNS present greyish and whitish regions. The **grey matter** consists of nerve cell bodies and dendrites, and the **white matter** is made up predominantly of myelinated nerve fibres. In the brain (except the brainstem), the grey matter is present at the periphery and the white matter in the center. Contrary to it, in the spinal cord, the grey matter is present in the center and the white matter at the periphery.

Functionally, the CNS is concerned with (a) the **reception and integration of sensory information** from within and outside the body and (b) the **production of motor responses** which are appropriate to the sum of the sensory information received by it.

The CNS develops from a hollow **neural tube** whose cavity persists in the adult brain and spinal cord in form of different cavities. Developmentally, the brain consists of the **forebrain, midbrain, and hindbrain**. The forebrain consists of the cerebrum and diencephalon. The midbrain is a small region which connects the forebrain with the hindbrain. The hindbrain consists of the pons, medulla oblongata, and cerebellum. The midbrain, pons, and medulla collectively form the **brainstem**.

The parts of brain and cavities within them are listed in Table 23.1.

Table 23.1 Parts of the brain and their cavities

Part of Brain	Cavity
Cerebrum (right and left cerebral hemispheres)	Right and left lateral ventricles
Diencephalon (thalamus and hypothalamus)	Third ventricle
Midbrain	Cerebral aqueduct
Hind brain (pons, medulla, and cerebellum)	Fourth ventricle

PARTS OF THE BRAIN

The brain is that part of the CNS which lies within the cranial cavity.

The adult brain constitutes about 1/50th of the body weight and weighs about 1400 g in males and 1200 g in females. It consists of the following six major parts (Fig. 23.1):

1. Cerebrum.
2. Diencephalon.
3. Midbrain.
4. Pons.
5. Medulla oblongata.
6. Cerebellum.

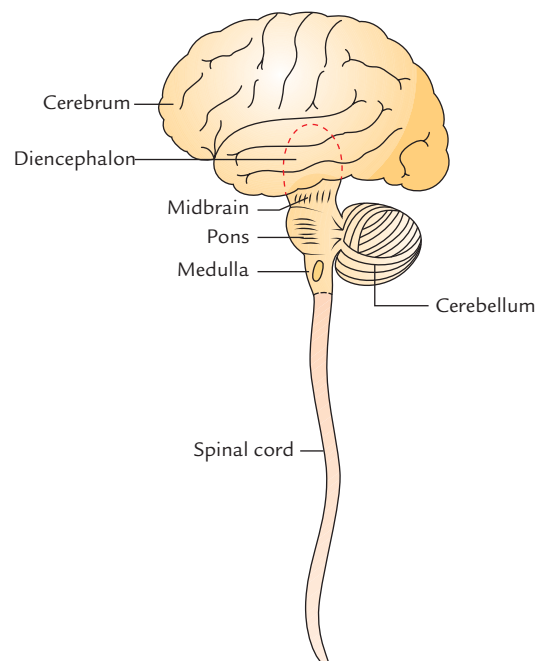


Fig. 23.1 Parts of the central nervous system.

CEREBRUM

The cerebrum is the largest part of the brain. It consists of two large hemispheres (the **left** and the **right cerebral hemispheres**), which occupy the anterior and middle cranial fossae, and the supratentorial region of the posterior cranial fossa.

Each cerebral hemisphere consists of a surface layer of grey matter, called the **cerebral cortex**, and a **central core** of white matter. In the basal part of the latter are located large masses of grey matter, known as **basal nuclei/ganglia**.

The two hemispheres are partly separated from each other by a deep median longitudinal fissure, called the **longitudinal cerebral fissure**. A massive commissure, the **corpus callosum**, whose fibres interconnect the corresponding cortical areas of the two cerebral hemispheres, lies in the floor of this fissure.

The surface of cerebral cortex is convoluted, i.e., it has a series of elevations, the **gyri**, separated by shallow depressions, the **sulci**, or deep grooves called **fissures** (Fig. 23.2).

There are individual differences in the appearance of the sulci and gyri, but some sulci are constant in their position and appearance and serve as important landmarks.

The **superolateral surface of each cerebral hemisphere** is divided into four lobes which are named after the overlying skull bones:

1. **Frontal lobe**—is anterior to the central sulcus and above the lateral sulcus.

2. **Parietal lobe**—is posterior to the central sulcus and above the lateral sulcus.
3. **Occipital lobe**—is behind a line extending from the parieto-occipital sulcus to the preoccipital notch.
4. **Temporal lobe**—is below the lateral sulcus and in front of preoccipital notch.

Frontal lobe: It is important for voluntary motor functions, motivation, aggression, emotions, affect, drive, and awareness of self.

Parietal lobe: It is the major center for reception and evaluation of all sensory information except smell, hearing, and vision.

Occipital lobe: It is responsible for reception and integration of visual input.

Temporal lobe: It receives and evaluates input for smell and hearing and plays an important role in memory.

N.B.

Deep within the lateral sulcus lies a submerged portion of cerebral cortex, the *insula* which is often referred to as the *5th lobe* or the *central lobe* of the cerebral hemisphere.

The so-called limbic lobe is a composite bordering zone (limbus = border) between the cerebrum and diencephalon. It is somewhat ring shaped. It is associated with basic survival instincts, *viz.* the acquisition of food and water and reproduction. It provides ability to store and retrieve

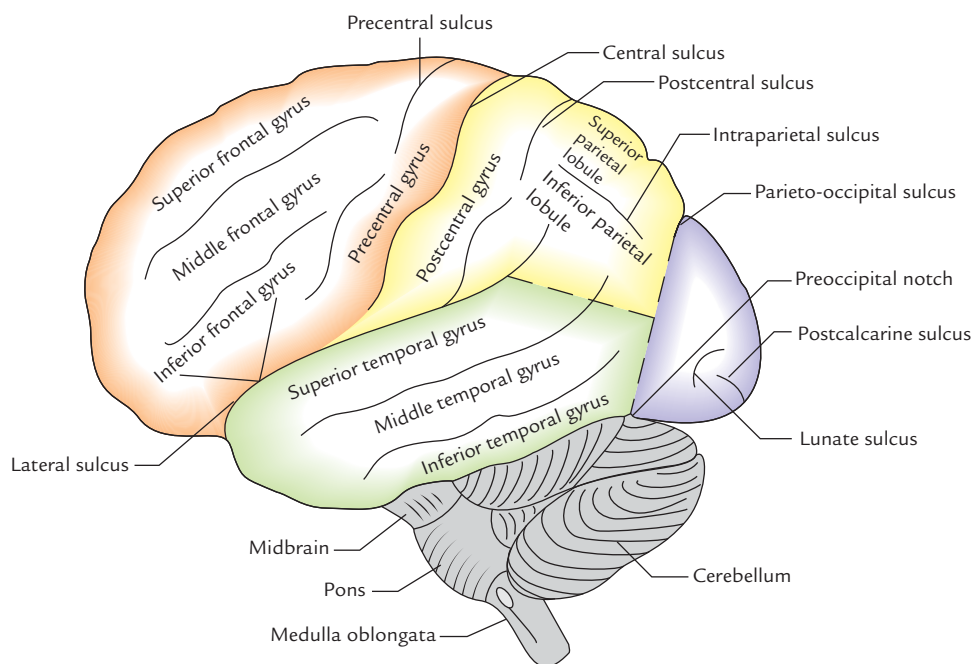


Fig. 23.2 Lateral aspect of the left side of the brain. Note the four lobes on the superolateral surface of the cerebral hemisphere.

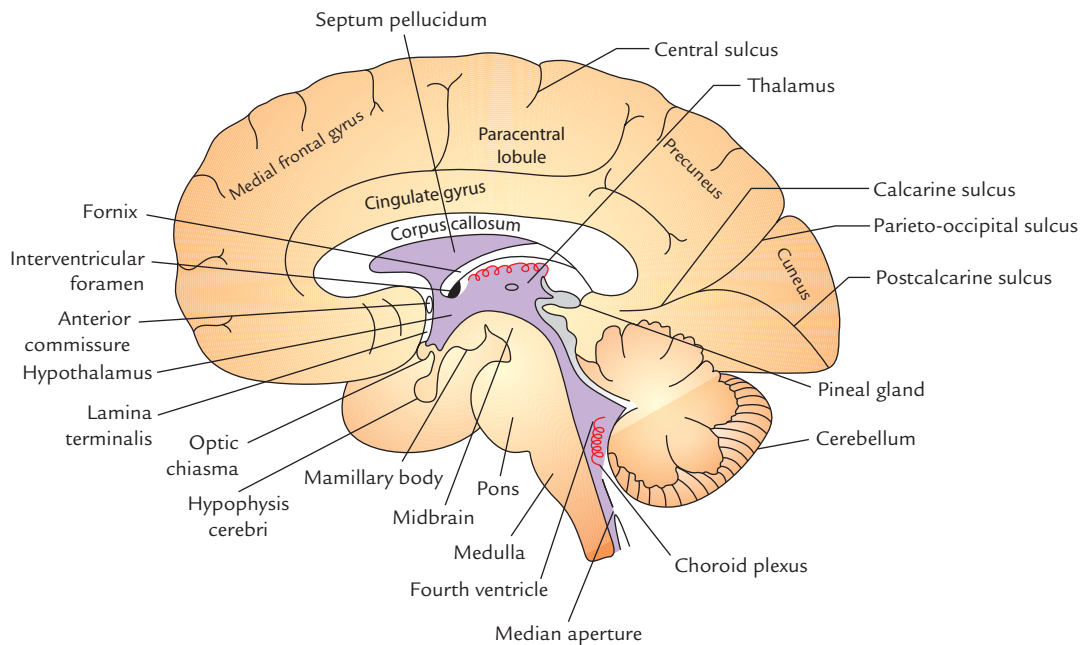


Fig. 23.3 Median sagittal section of the brain.

information and is particularly important for short-term memory.

The medial surface of the cerebral hemisphere is visualized in the sagittal section of the brain and presents a number of features shown in Figure 23.3.

The inferior surface of the cerebral hemisphere is uneven and presents orbital and tentorial surfaces.

Basal Ganglia/Basal Nuclei

The basal ganglia are subcortical masses of grey matter which are situated in the white core of each cerebral hemisphere. The basal ganglia include corpus striatum, claustrum, and amygdaloid body.

During the development of connections between the cerebral cortex and the brainstem, the bundles of fibres converging as **internal capsule** partly divide the corpus striatum into a medial **caudate nucleus** and a lateral **lentiform nucleus**. Between the internal capsule and the cerebral cortex, the nerve fibres diverge as the **corona radiata**.

Functionally, the basal ganglia also include the subthalamic nucleus of diencephalon, and the substantia nigra and red nucleus of midbrain.

The basal ganglia influence the quality of motor performance and are sometimes termed **extrapyramidal nuclei**.

DIENCEPHALON

The diencephalon is the part of brain between the cerebrum and the brainstem. It is almost entirely hidden from view by the cerebral hemispheres. The main components of the diencephalon are as follows:

1. Thalamus.
2. Hypothalamus.
3. Metathalamus.
4. Epithalamus.
5. Subthalamus.

Thalamus: The thalamus is a large ovoid mass of grey matter lying above the midbrain. The two thalami form by far the largest mass of the diencephalon and are separated from each other by a cavity of 3rd ventricle, and joined with each other by an **interthalamic adhesion**. It forms a great relay station for all sensory impulses *except* olfactory, visual, and auditory. It appreciates crude sensations such as pain and touch.

The thalamus also integrates motor functions.

Hypothalamus: The hypothalamus is the most inferior portion of the diencephalon and contains several small nuclei and nerve tracts. The most conspicuous nuclei called **mammillary bodies** appear as rounded elevations on the base of the brain in the region of interpeduncular fossa.

The hypothalamus regulates visceral activity through the autonomic nervous system and hormonal activity through the hypophysis cerebri.

Metathalamus: The metathalamus consists of two rounded medial and lateral geniculate bodies which protrude from the posteroinferior surface of the thalamus.

The medial and lateral geniculate bodies form relay stations for the special senses of hearing and vision, respectively.

Epithalamus: The epithalamus is a small area of diencephalon, posterosuperior to the thalamus. It consists of pineal gland and habenular nuclei. The pineal gland plays an important role in controlling the onset of puberty through its secretion. The reduction of pineal secretion precipitates puberty. The pineal gland is also involved in *sleep-wake cycle*.

The habenular nuclei have olfactory and limbic connections. They are influenced by smell and are involved in emotional and visceral responses to odors.

Subthalamus: The subthalamus is a small area of diencephalon that lies between the thalamus and the midbrain. It contains several nerve tracts, and the subthalamic nuclei which are associated with basal ganglia and are involved in controlling motor functions.

MIDBRAIN

The midbrain is the smallest segment of the brainstem. It is just superior to the pons and contains the nuclei of the 3rd (oculomotor), 4th (trochlear), and 5th (trigeminal) cranial nerves.

The midbrain is traversed by the **cerebral aqueduct**. The part dorsal to the aqueduct is called the **tectum** and consists of four surface elevations—the **corpora quadrigemina** (comprising *two superior and two inferior colliculi*). The superior and inferior colliculi receive visual and auditory impulses, respectively, and are concerned with reflexes involving these senses. The part ventral to the aqueduct is divided into right and left halves, the **cerebral peduncles**. Each cerebral peduncle consists of a central part, the tegmentum, which is separated ventrally from the crus cerebri by a mass of pigmented grey matter, the substantia nigra.

The crus cerebri continues ipsilaterally with the internal capsule above and contains descending fibres from the cerebral cortex to the brainstem and spinal cord. The space between the two crura is termed the **interpeduncular fossa**.

The tegmentum largely consists of ascending tracts from the spinal cord to the thalamus and contains two large cigar-shaped nuclei called **red nuclei**. In cross section, the red nuclei appear as oval masses of the pinkish grey matter.

The red nuclei help in unconscious regulation and coordination of motor activities.

PONS

The pons (L. *Pons* = bridge) is the large middle part of the brainstem. It is continuous above with the midbrain and below with the medulla oblongata. It is so named because it forms a broad bridge between the two cerebellar hemispheres by its transverse fibres constituting the middle cerebellar peduncles. The vertical median sulcus on its ventral aspect lodges the basilar artery, and therefore, termed the *basilar sulcus*.

In the transverse section, the pons is seen to consist of a large ventral and a smaller dorsal region.

The **ventral portion** contains a large number of nuclei, the **pontine nuclei**, and longitudinal bundles of descending fibres of the pyramidal tract. The pontine nuclei relay information from the cerebrum to cerebellum and form a **corticopontocerebellar pathway**.

The **dorsal portion** or tegmentum of pons contains **pontine sleep and respiratory centres**. The pontine respiratory centre functions with the respiratory centre in the medulla to help in controlling the respiratory movements.

MEDULLA OBLONGATA

The medulla oblongata is the lower part of the brainstem and is continuous inferiorly with the spinal cord at the foramen magnum.

On the ventral aspect of medulla, there are two pyramid-shaped elevations, one on either side of median plane called **pyramids**. These elevations are produced by the descending fibres of the corticospinal tracts involved in the conscious control of the skeletal muscles. Lateral to the pyramids, there are two oval elevations called **olives** containing inferior olivary nuclei. Dorsal to each olive is an *inferior cerebellar peduncle*.

On the dorsal aspect, on either side, the medulla has cuneate and gracile tubercles produced by similarly named nuclei beneath them.

Medulla contains various vital autonomic centres responsible for several reflexes, such as those involved in the regulation of heart rate, blood vessel diameter, breathing, swallowing, vomiting, coughing, and sneezing.

CEREBELLUM

The cerebellum lies dorsal to the pons and medulla and consists of **two lateral hemispheres**: the cerebellar hemispheres and a median worm-like part called **vermis**. It is connected to the midbrain, pons, and medulla by superior, middle, and inferior cerebellar peduncles, respectively. The surface of cerebellum has narrow transverse ridges called **folia** (leaf-like in sections) separated by deep fissures.

Functionally, the cerebellum is mainly concerned with the involuntary control of somatic motor activities, essential for the maintenance of equilibrium, muscle tone, and posture.

BASE OF THE BRAIN

The base of the brain presents: (a) orbital and tentorial surfaces of the frontal and temporal lobes of both the cerebral hemispheres, (b) interpeduncular fossa, (c) ventral aspects of the midbrain, pons, medulla oblongata and cerebellum, and (d) superficial attachment of the cranial nerves (Fig. 23.4).

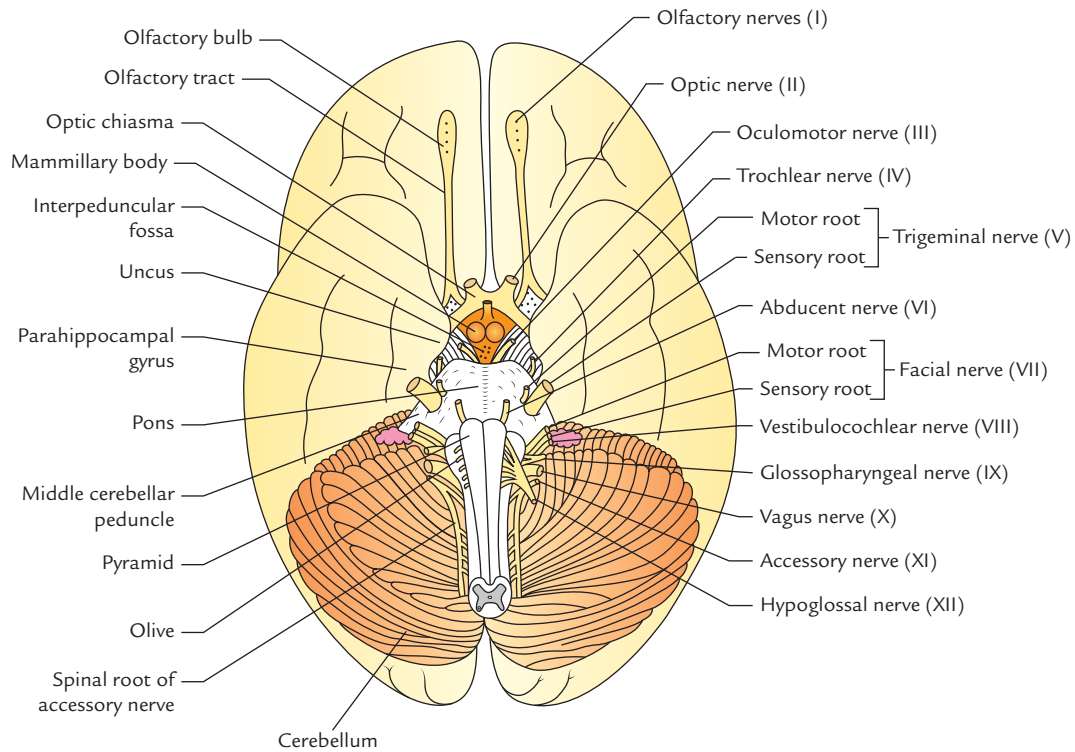


Fig. 23.4 Interior aspect of the brain. Note the attachment of cranial nerves.

The interpeduncular fossa and superficial attachment of cranial nerves are briefly described here.

Interpeduncular Fossa (Fig. 23.5)

The interpeduncular fossa is a rhomboidal space bounded on either side by the crus cerebri of cerebral peduncles, anteriorly by optic chiasma and optic tracts, and posteriorly by the pons. The interpeduncular fossa contains: (a) two small spherical bodies called **mammillary bodies**, (b) a raised area of grey matter lying anterior to the mammillary bodies called **tuber cinereum**, (c) a narrow stalk which connects the hypophysis cerebri with the tuber cinereum called **infundibulum**, (d) **posterior perforated substance**, which is a layer of grey matter in the angle between the crus cerebri and is pierced by the central branches of the posterior cerebral arteries, and (e) the **oculomotor nerve** which emerges immediately dorsomedial to the corresponding crus.

Superficial Attachments of the Cranial Nerves

All the 12 pairs of cranial nerves are attached on the ventral aspect of the brain *except* the 4th pair (trochlear nerves) which are attached on the dorsal aspect.

Each cranial nerve enters or leaves the brain surface at its superficial attachment and the fibres which it contains either arise from (efferent or motor fibres) or terminate in (afferent

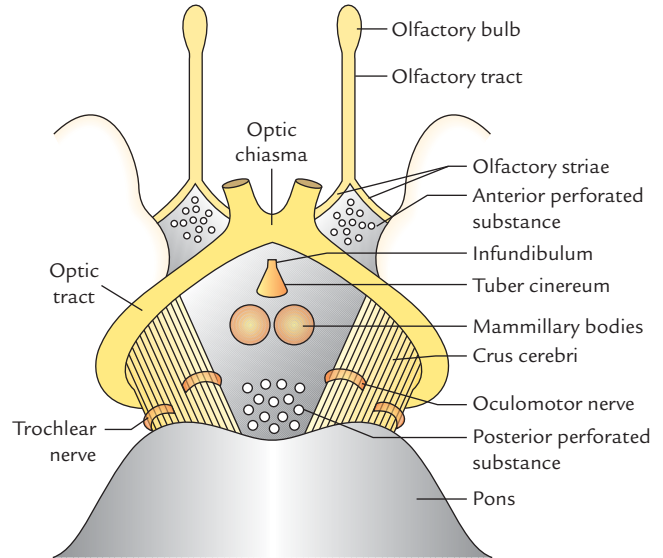


Fig. 23.5 Boundaries and contents of the interpeduncular fossa.

or sensory fibres) motor and sensory nuclei within the brain, respectively.

The first two pairs are attached to the forebrain; the 3rd and 4th to the midbrain; and the remainder to the hindbrain. The 11th cranial nerve also receives a root from the upper part of the spinal cord.

Sites of Attachments

Olfactory nerves

There are about 20 olfactory nerves on each side. They arise from the olfactory epithelium of nasal cavity and pass through the cribriform plate of ethmoid and end in the olfactory bulb which lies on the orbital surface of the frontal lobe. They are so delicate that no trace is seen on the olfactory bulb when the brain is removed from the cranial cavity.

Optic nerve

This is a thick cylindrical nerve which arises from the retina and joins the anterolateral angle of the optic chiasma.

Oculomotor nerve

It emerges from the groove on the medial aspect of the cerebral peduncle in the posterior part of the interpeduncular fossa.

Trochlear nerve

It is a slender nerve which emerges on the dorsal aspect of the midbrain, lateral to the median plane. It winds round the lateral aspect of the midbrain toward the interpeduncular fossa, immediately superior to the pons.

Trigeminal nerve

It is the largest of the cranial nerves and attached to the junction of the pons and middle cerebellar peduncle by two roots: a large lateral sensory root and a small medial motor root.

Abducent nerve

It emerges at the inferior border of the pons, opposite to the upper end of the medullary pyramid.

Facial nerve

It emerges at the inferior border of pons lateral to the abducent nerve by two roots: a thick medial motor root and a slender lateral sensory root called *nervus intermedius*.

Vestibulocochlear nerve

It consists of two nerves: vestibular and cochlear which are attached in the *cerebello-pontine angle*. The cochlear nerve lies posterior to the inferior cerebellar peduncle and vestibular anterior to it.

Glossopharyngeal nerve

It emerges by a number of rootlets from a groove between the olive and inferior cerebellar peduncle.

Vagus nerve

It also emerges by a number of rootlets from a groove between the olive and inferior cerebellar peduncle below the rootlets of the glossopharyngeal nerve.

Accessory nerve

It has two roots: cranial and spinal. The cranial root emerges by a number of rootlets from the medulla below the rootlets of the vagus nerve and it is joined by the spinal root, which

emerges by a number of rootlets from the upper five cervical spinal segments.

Hypoglossal nerve

It arises by a row of rootlets from a groove between the pyramid and olive.

VENTRICLES OF THE BRAIN

There are four ventricles of the brain (Fig. 23.6): two lateral ventricles, a third ventricle, and a fourth ventricle.

The two lateral ventricles, one in each cerebral hemisphere, form the largest component of the ventricular system. They occupy a considerable part of the cerebral hemisphere and are separated from each other by the septum pellucidum, extending between the corpus callosum and the fornix. The 3rd ventricle is a narrow slit-like cavity of the diencephalon. The two lateral ventricles are connected with the 3rd ventricle via the **interventricular foramina (of Monro)**. The 3rd ventricle communicates via the **cerebral aqueduct** of midbrain with the 4th ventricle, a cavity within the hindbrain. The 4th ventricle in turn is continuous with the central canal of the spinal cord. The central canal has a small dilatation at its inferior end, the **terminal ventricle**.

The cerebrospinal fluid (CSF) is formed in the ventricles by the choroid plexuses and passes through apertures in the roof of 4th ventricle into the subarachnoid space around the brain and spinal cord.

MEMBRANES OF THE BRAIN (MENINGES)

The brain and spinal cord are enclosed within three protective membranes called meninges (Fig. 23.7). From without inward these are as follows:

1. Dura mater.
2. Arachnoid mater.
3. Pia mater.

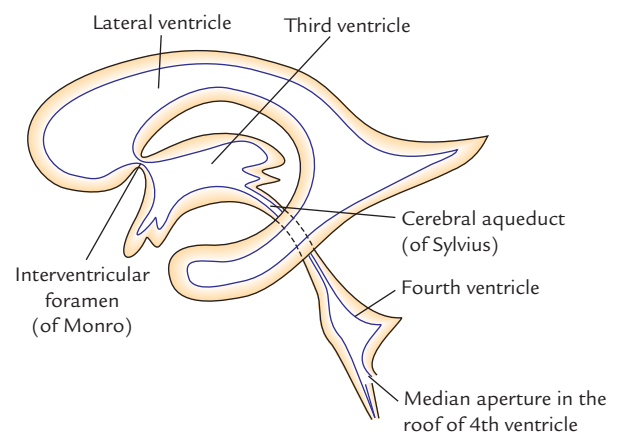


Fig. 23.6 Ventricles of the brain.

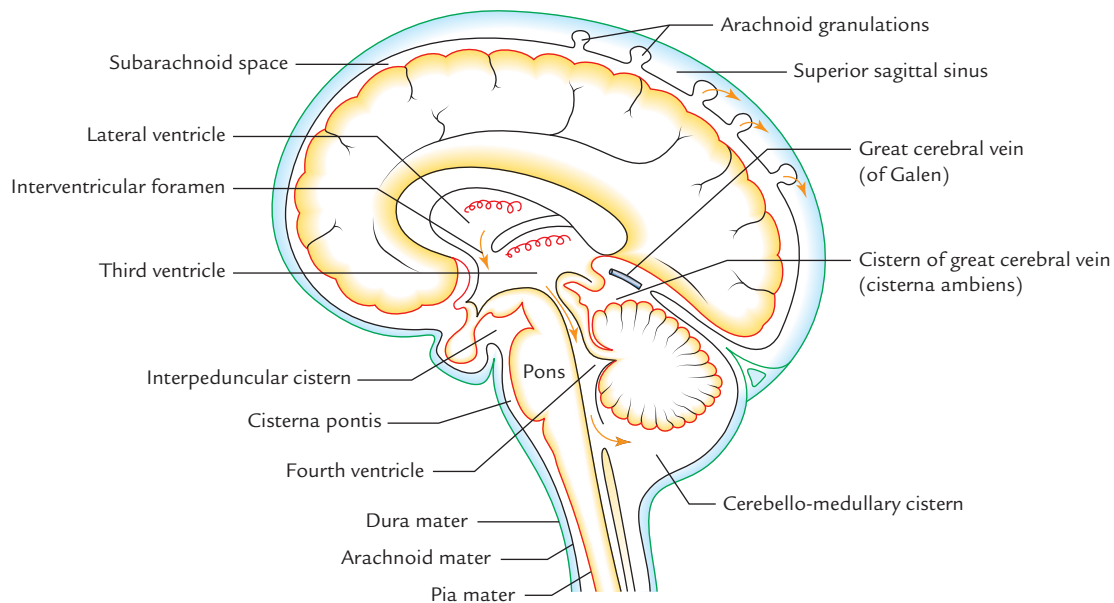


Fig. 23.7 Median section of the brain showing membranes and cisterns.

The dura mater is mesodermal in origin, whereas the arachnoid mater and pia mater are ectodermal in origin (derived from neural crests).

Dura mater: This has already been described in Chapter 21.

Arachnoid mater: The arachnoid mater is an exceedingly thin, a transparent membrane, which invests the brain loosely and continues as the spinal arachnoid at the foramen magnum, which ends at the level of second sacral vertebra. It is closely related to the internal surface of the dura mater and has exactly the same shape as the dural sac except where its arachnoid granulations pierce the dura mater.

The arachnoid mater is separated from the dura mater by a capillary space called the **subdural space** containing a film of fluid. This forms a sliding plane where movement is possible between the dura mater and brain enclosed in the arachnoid and pia mater.

The subdural space is traversed by cerebral veins on their route to the dural venous sinuses.

Processes of arachnoid

Arachnoid villi: These are fine finger-like processes which arise from the surface of arachnoid. They push the dura before them and eventually perforate it to project into the dural venous sinuses. They are covered by specialized mesothelial cells which convey the CSF to bloodstream, thus leading to the absorption of CSF.

Arachnoid granulations (pacchionian bodies): With advancing age, the arachnoid villi enlarge in size and form pedunculated tufts called **arachnoid granulations**. Some consider that these are aggregations of arachnoid villi,

clumped together, i.e., arachnoid granulations are the large clusters of arachnoid villi. Arachnoid granulations like arachnoid villi are concerned with the absorption of CSF. They project into the venous lacunae of the superior sagittal sinus.

Pia mater: Pia mater is a thin transparent vascular membrane which closely invests the surface of the brain. It is adherent to the surface of the brain and follows closely the irregularities of its surface.

All the blood vessels to the brain run in the subarachnoid space on the surface of the pia mater before entering the brain.

In certain situations, the walls of the cavities of the brain (ventricles) are very thin and made up of only a single layer of its lining epithelium, the **ependyma**. In these regions, the pia mater lying on its external surface invaginates into ventricular cavities as a series of vascular tufts of capillaries which carry the ependyma before them, thus forming the **choroid plexuses of the brain**. The pial component of choroid plexus is termed **tela choroidea**.

SUBARACHNOID SPACE

The subarachnoid space is the space between the arachnoid mater and pia mater. It is filled with CSF which enters it from the ventricular system of the brain.

The subarachnoid space is traversed by thread-like trabeculae passing from the arachnoid to pia, giving it a **spider's-web appearance**, hence the name arachnoid (arachnoid = like spider's web), and forms a kind of fluid-filled sponge. The arteries and veins of the brain lie in this space.

The subarachnoid space around the brain is continuous with the subarachnoid space around the spinal cord at the foramen magnum and communicates with the ventricular system only through the foramina in the roof of the 4th ventricle.

The cerebrospinal fluid in the subarachnoid space acts as a mobile buffer to distribute and equalize pressures within the skull.

SUBARACHNOID CISTERNS

The enlargements of subarachnoid space, in certain situations, around the brain are termed **subarachnoid cisterns**. They contain large amount of CSF forming 'pools of CSF'. The cisterns are found where the brain, closely covered with pia mater, lies at some distance from the arachnoid lining the dura mater. The cisterns act as a water-bed to the brain.

The various types of subarachnoid cisterns are as follows:

1. **Cerebellomedullary cistern (cisterna magna)**: It is the largest cistern and formed by the arachnoid, bridging the interval between the medulla oblongata and the inferior surface of the cerebellum. Thus, it lies in the triangle formed by the cerebellum, the medulla oblongata, and the occipital bone. It is directly continuous inferiorly with the posterior part of the spinal subarachnoid space.

The cerebellomedullary cistern is easily accessible to a needle introduced anterosuperiorly through the posterior atlanto-occipital membrane, between the posterior arch of atlas and the posterior margin of the foramen magnum. Therefore, it is utilized for **cisternal puncture** if lumbar puncture is not possible to withdraw CSF by clinicians for therapeutic and diagnostic purposes.

This cistern is triangular in sagittal section. It is the only cistern which directly communicates with the ventricular system of the brain through openings (*foramen of Magendie and foramina of Luschka*) in the roof of the 4th ventricle.

2. **Pontine cistern (cisterna pontis)**: This is an extensive subarachnoid space on the ventral surface of the pons and contains the basilar artery and its branches. It is continuous below with the subarachnoid space of the spinal cord, behind with the cerebellomedullary cistern and rostrally with the interpeduncular cistern.
3. **Interpeduncular cistern (basal cistern)**: It is formed by the arachnoid mater bridging across the two temporal lobes on the inferior aspect of the brain and contains the circle of Willis (*circulus arteriosus*).

Interpeduncular cistern is continuous laterally with the subarachnoid spaces surrounding the middle and posterior cerebral arteries, and anteriorly with the subarachnoid spaces around the anterior cerebral arteries.

4. **Cistern of lateral sulcus/fossa (sylvian cistern)**: It lies in front of each temporal pole and is formed by the

arachnoid mater bridging the lateral sulcus. It contains the middle cerebral artery.

5. **Cistern of great cerebral vein (cisterna superior or cisterna ambiens)**: It occupies the interval between the splenium of corpus callosum and the superior surface of cerebellum. This cistern contains the great cerebral vein of Galen and pineal gland and is widely used as a **neurosurgical landmark**.

N.B. The various cisterns are large pools of CSF and communicate freely with each other. The pulsations of arteries within CSF help to force the CSF from cisterns onto the superolateral surfaces of the cerebral hemispheres and then into arachnoid villi and granulations.

CEREBROSPINAL FLUID

Cerebrospinal fluid is somewhat similar to blood plasma and interstitial fluid. It is present in the ventricular system within the CNS and in the subarachnoid space surrounding the CNS. It bathes both the external and internal surfaces of the brain and spinal cord and provides a protective cushion between the CNS and the surrounding bones.

In an adult, the total volume of CSF is about 150 ml, out of which only 30 ml is in the ventricular system and the remainder in the subarachnoid space.

Production

About 80–90% of the CSF is produced by the choroid plexuses within the lateral ventricles, with remaining being produced by the choroid plexuses in the 3rd and 4th ventricles. The process of production whether by secretion, filtration, or dialyzation is uncertain. The average amount of CSF formed per day is about 500 ml.

Circulation and Absorption

The CSF is produced mainly in the lateral ventricles from their choroid plexuses, from where it passes through the interventricular foramina (of Monro) into the 3rd ventricle, and then via cerebral aqueduct into the 4th ventricle. Here the fluid escapes via the median aperture (foramen of Magendie) and lateral apertures (foramina of Luschka) in the roof of the lateral ventricle, into the cerebellomedullary and pontine cisterns, respectively. From these sites, the fluid flows slowly in the subarachnoid space over the brain and spinal cord.

Most of the CSF flows upward through the gap in the tentorium cerebelli and then forward, laterally over the inferior surface of the cerebrum. Finally, it ascends on the superolateral aspect of each cerebral hemisphere to reach the arachnoid villi and granulations which penetrate into the superior sagittal sinus. The CSF enters into the bloodstream

of the sinus through the mesothelial cell lining of these villi and granulations.

Some of the CSF moves inferiorly in the subarachnoid space around the spinal cord and cauda equina. Small amount of absorption may also occur into the pial veins.

The flow of CSF is facilitated by the pulsations of cerebral and spinal arteries present in the subarachnoid space and the movements of the head and spine.

Functions

The CSF performs the following functions:

1. It serves as a cushion between the CNS and the surrounding bones.
2. It acts as a shock absorber, i.e., it prevents or diminishes the transmission of jarring or shocking forces to the CNS.

Clinical correlation

Hydrocephalus: The *hydrocephalus* is an abnormal increase in the volume of cerebrospinal fluid (CSF) within the skull.

- *Types of hydrocephalus:* Two varieties of hydrocephalus are described: (a) non-communicating and (b) communicating.

If the CSF accumulates within the ventricular system, the condition is called **internal (non-communicating) hydrocephalus**. It occurs due to blockage at some point between its site of formation at the choroid plexuses and its site of exit through the foramina in the roof of the 4th ventricle.

If the CSF accumulates in the subarachnoid space, the condition is called **external (communicating) hydrocephalus**, as there is no obstruction within or to the outflow from the ventricular system. It commonly occurs due to blockage of arachnoid villi and granulations.

- *Clinical features of hydrocephalus in infants and children:* Disproportionately large size of the head (increased skull circumference).
 - Bossing of the forehead.
 - Widely separated cranial sutures.
 - Enlarged and tense anterior fontanelle.
 - Thin scalp with dilated scalp veins.
 - Eyes look downward giving a typical *setting-sun appearance*.
 - *Cracked-pot sound* on skull percussion.

N.B. There is a natural tendency to the arrest of infantile hydrocephalus. The renowned scientists Cuvier and Helmholtz are examples of arrested hydrocephalus.

Golden Facts to Remember

- | | |
|---|---|
| ▶ Largest part of the brain | Cerebrum |
| ▶ Second largest part of the brain | Cerebellum |
| ▶ Most of the CSF is formed by | Choroid plexuses of the lateral ventricles |
| ▶ Narrowest cavity within the brain | Cerebral aqueduct (aqueduct of Sylvius) |
| ▶ Main blood vessels of the brain and their principal branches lie in the | Subarachnoid space |
| ▶ Part of the brain which is almost entirely hidden from view by the cerebral hemispheres | Diencephalon |
| ▶ Only communication between the cavities of the brain and subarachnoid space around brain is through | Three small openings in the roof of the 4th ventricle |

Clinical Case Study



A 2-year and 6-month-old boy was taken by his mother to a neurologist and complained that the size of head of her son is unusually large and his eyes look different from other children. On examination, the neurologist found enlarged and tense anterior fontanelle, widely separated cranial sutures, and typical setting-sun appearance of the eyes. He made the diagnosis of *hydrocephalus*.

Questions

1. What is hydrocephalus?
2. Enumerate the openings through which cavities within the brain communicate with the subarachnoid space around the brain.

3. What is the difference between internal and external hydrocephalus?

Answers

1. Abnormal increase in the volume of cerebrospinal fluid (CSF) within the skull.
2. Foramen of Magendie (median aperture) and foramina of Luschka (lateral apertures) in the roof of the 4th ventricle.
3. *Internal hydrocephalus*: Excessive accumulation of CSF within the ventricular system of brain.
External hydrocephalus: Excessive accumulation of CSF in the subarachnoid space around the brain.

Brainstem

The brainstem is the stalk-like part of the brain which connects the forebrain (diencephalon and cerebrum) with the spinal cord. It consists, from below upward, of the medulla oblongata, pons, and midbrain.

The brainstem consists of nerve fibres and nerve cells. Most of the fibres in the brainstem are arranged longitudinally in the form of tracts as in the spinal cord. The nerve cells like spinal cord do not form a single central mass of grey matter; rather most of them are aggregated to form well-defined nuclei.

The brainstem nuclei are of the following two types:

1. Nuclei of last 10 cranial nerves (i.e., 3rd–12th cranial nerves).
2. Other named nuclei such as red nucleus, substantia nigra, pontine nuclei, olivary nuclei, etc.

In addition to well-defined tracts and nuclei, the brainstem consists of the diffuse system of cells and fibres called **reticular formation**. Some of the cells of reticular formation form **vital centres**, viz. cardiac, respiratory, vasomotor, etc. Although these centres are not anatomically demonstrable, they are of great physiological importance.

The external features of the brainstem are shown in Figs. 24.1 and 24.2.

MEDULLA OBLONGATA

The medulla oblongata is the direct upward continuation of the spinal cord, extending from the foramen magnum to the upper border of the pons. It forms the lowest part of the brainstem and lies almost vertically in the anterior part of the posterior cranial fossa between the clivus (superior surface of the basiocciput) in front and the vallecula of the cerebellum behind.

Medulla provides attachment to the last four cranial nerves.

The lower part of the medulla, like the spinal cord, contains the central canal. In the upper part of the medulla,

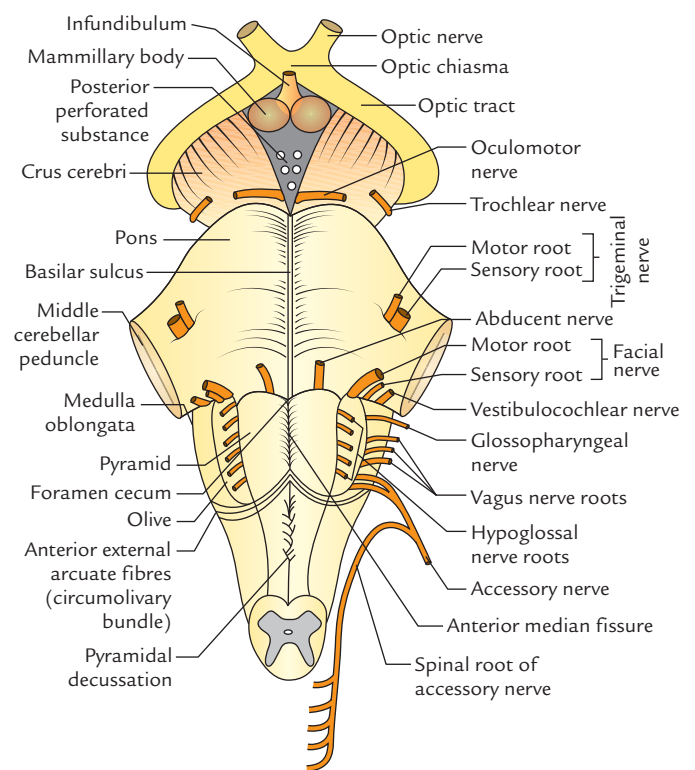


Fig. 24.1 External features on the anterior (ventral) aspect of the brainstem.

this canal widens and moves dorsally to form the lower part of the 4th ventricle. Thus, the medulla is divided into two parts: a **lower closed part** of medulla and an **upper open part**.

EXTERNAL FEATURES

The medulla is divided into right and left symmetrical halves by the **anterior median fissure** and **posterior median sulcus**.

The anterior median fissure is continuous below with the corresponding fissure on the spinal cord, and above it ends into a small triangular depression called the **foramen cecum**

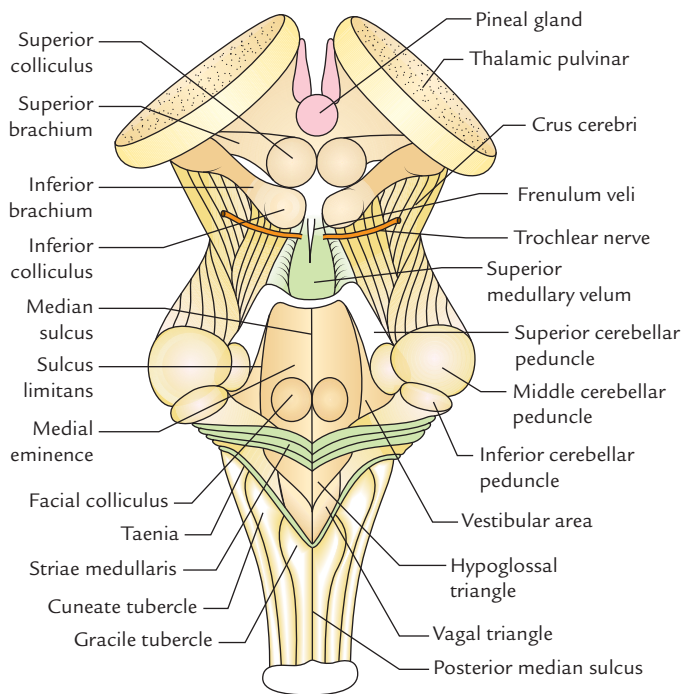


Fig. 24.2 External features on the posterior (dorsal) aspect of the brainstem.

at the lower border of the pons. It is interrupted in its lower part by the bundles of fibres crossing obliquely from one side to the other, the **decussation of pyramids**.

The posterior median sulcus continues below with the corresponding sulcus of the cord and is present only in the lower half of the medulla. Above, its lips diverge to form the boundaries of a triangular area, the lower part of the floor of the 4th ventricle.

Each half of the medulla is marked by two sulci, anterolateral and posterolateral, which are direct upward continuations of the corresponding sulci of the cord.

The anterolateral sulcus extends along the lateral border of the pyramid and along it emerge the rootlets of the hypoglossal (12th cranial) nerve.

The posterolateral sulcus lies between the olive and the inferior cerebellar peduncle and along it emerge the rootlets of the glossopharyngeal (9th), vagus (10th), and cranial root of accessory (11th) cranial nerves.

Features on the Ventral Aspect

The ventral aspect of medulla presents the following features:

1. **Pyramids:** These are two elongated elevations, one on either side of the anterior median fissure, and are produced by the underlying corticospinal (pyramidal) fibres.

2. **Olives:** These are oval elevations, posterolateral to the pyramids and are produced by an underlying mass of grey matter called *inferior olivary nucleus*.
3. **Rootlets of the hypoglossal nerve:** These emerge from the anterolateral sulcus between the pyramid and the olive.
4. **Inferior cerebellar peduncles:** These are thick bundles of fibres lying posterolateral to the olive, and attach the medulla with the cerebellum.
5. **Rootlets of the 9th, 10th, and 11th (cranial part) cranial nerves:** These emerge through the posterolateral sulcus separating the olive from the inferior cerebellar peduncle.

Features on the Dorsal Aspect

The dorsal aspect of the medulla is well demarcated into lower closed and upper open parts.

Features of the Closed Part

The closed part, on either side of the posterior median sulcus, presents three longitudinal elevations. From medial to lateral these are: fasciculus gracilis, fasciculus cuneatus, and inferior cerebellar peduncle. The upper ends of the fasciculus gracilis and fasciculus cuneatus expand to form the gracile and cuneate tubercles, respectively, due to underlying nuclei of the same name.

Another elevation present lateral to cuneate tubercle; the **tuber cinereum** is produced by the spinal nucleus of the trigeminal nerve.

Features of the Open Part

The open part of the medulla forms the lower part of the floor of the 4th ventricle which presents a number of features such as, median sulcus, hypoglossal and vagal triangles, vestibular areas, area postrema, stria medullaris, etc. (for details, see floor of the 4th ventricle in Chapter 25, page 379).

INTERNAL STRUCTURE

The internal structure of medulla is well appreciated by examining its transverse sections (T.S.) at the following three levels:

1. At the level of decussation of pyramids.
2. At the level of sensory decussation.
3. At the level of the olives.

T.S. of Medulla at the Level of Decussation of Pyramids

The transaction at this level passes through the inferior half of the medulla, and closely resembles that of the spinal cord. However, the following important features are observed at this level (Fig. 24.3):

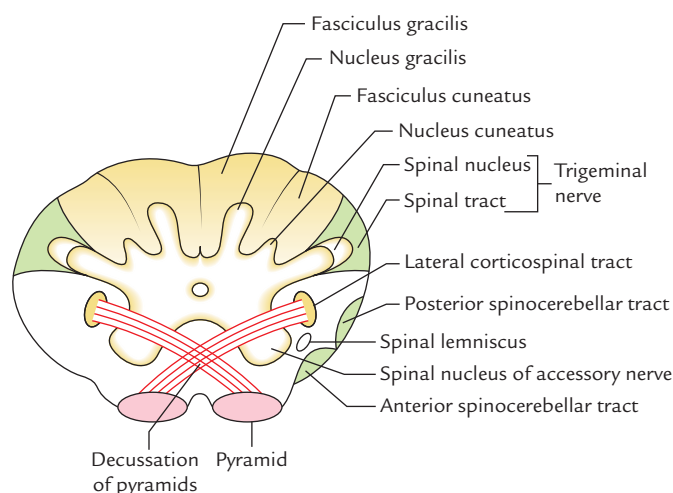


Fig. 24.3 Transverse section of medulla at the level of pyramidal decussation.

1. The **nucleus gracilis** and **nucleus cuneatus** appear as narrow strip-like projections from the posterior aspect of the central grey matter.
2. The apex of posterior horn swells up to form the *nucleus of the spinal tract of the trigeminal nerve*.
3. The **spinal tract of the trigeminal nerve** is a bundle of fibres, which caps the nucleus of the spinal tract of the trigeminal nerve.
4. **Decussation of pyramidal tracts forms the most important feature of medulla at this level.** About 75% fibres of pyramidal tract run backward and laterally across the midline to reach the lateral white column of the opposite side of the spinal cord where they run downward as the lateral corticospinal tract. In doing so, the anterior horns are detached from the central grey matter.
5. Each detached anterior horn divides to form the **spinal nucleus of the accessory nerve** and the **supraspinal nucleus of the 1st cervical nerve**.
6. Diffuse zone appears containing a network of fibres and scattered nerve cells within it, in the lateral white column adjacent to the nucleus of the spinal tract of the trigeminal nerve is called **reticular formation**.

T.S. of Medulla at the Level of Sensory Decussation

This section passes through the middle of medulla and displays the following features (Fig. 24.4):

1. The **nucleus gracilis** and **nucleus cuneatus** become more pronounced and are separated from the central grey matter. The fibres of fasciculus gracilis and fasciculus cuneatus terminate in these nuclei.
2. The **internal arcuate fibres** arising from gracile and cuneate nuclei course forward and medially around the

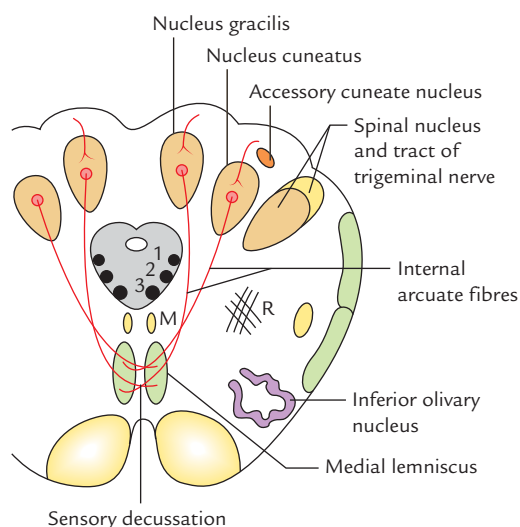


Fig. 24.4 Transverse section of medulla at the level of sensory decussation (1 = nucleus tractus solitarius, 2 = dorsal nucleus of vagus, 3 = hypoglossal nucleus; M = medial longitudinal fasciculus, R = reticular formation).

- central grey matter and decussate with corresponding fibres of opposite side in the median plane (*sensory decussation*) and then turn upward to ascend as the *medial lemniscus* on the opposite side close to the median plane.
3. The **internal arcuate fibres** cut off the spinal nucleus and tract of the trigeminal nerve from the central grey matter.
4. Immediately dorsolateral to the cuneate nucleus lies the **accessory cuneate nucleus** which receives the more lateral fibres (derived from the cervical segments of the cord) of the fasciculus cuneatus and gives rise to posterior external arcuate fibres conveying proprioceptive impulses to the cerebellum of the same side through inferior cerebellar peduncle.
5. The separated **spinal nucleus and tract of trigeminal nerve** lies ventrolateral to the cuneate nucleus.
6. The lower part of **inferior olivary nucleus** is seen.
7. The **pyramids** lie on either side of the anterior median fissure.
8. The central grey matter contains the: (a) **hypoglossal nucleus**, (b) **dorsal nucleus of vagus**, and (c) **nucleus of tractus solitarius**.
9. The **medial longitudinal bundle/fasciculus** fasciculus lies posterior to the medial lemniscus. It is a small compact tract of nerve fibres which interconnect the 3rd, 4th, 6th, 8th, and spinal nucleus of the 11th cranial nerve nuclei.
10. **Spinocerebellar and lateral spinothalamic tracts** lie in the anterolateral area of lateral white column.
11. **Lateral and anterior spinothalamic tracts** are very close to each other and collectively form **spinal lemniscus**.

T.S. of Medulla at the Level of Olives

Transverse section passes across the floor of the 4th ventricle and through the middle of olives and presents the following features (Fig. 24.5):

Medulla at the level of olives: Transverse section passes across the floor of the 4th ventricle and through the middle of olives and presents the following features (Fig. 24.5):

1. The central grey matter is spread over the floor of the 4th ventricle and contains the nuclei of several cranial nerves. From medial to lateral, these are: **hypoglossal nucleus, nucleus intercalatus, dorsal nucleus of vagus, and vestibular nuclei** (inferior and medial).
2. The **nucleus of tractus solitarius** lies ventral to vestibular nuclei.
3. The **nucleus ambiguus** lies deep within the reticular formation and gives origin to the motor fibres of 9th, 10th, and 11th cranial nerves.
4. On either side of the midline (paramedian region) from dorsal to ventral lie **medial longitudinal fasciculus (MLF), tectospinal, medial lemniscus, and pyramidal (corticospinal) tracts**.
5. The **arcuate nuclei**, thought to be inferiorly displaced pontine nuclei, are situated on the anteromedial aspect of the pyramids.
6. Laterally, from dorsal to ventral lie two prominent structures: (a) **inferior cerebellar peduncle** and (b) **inferior olivary nucleus**.
 - The *inferior cerebellar peduncle* occupies posterolateral part.
 - The *inferior olivary nucleus* is the largest mass of grey matter, and forms the most prominent feature

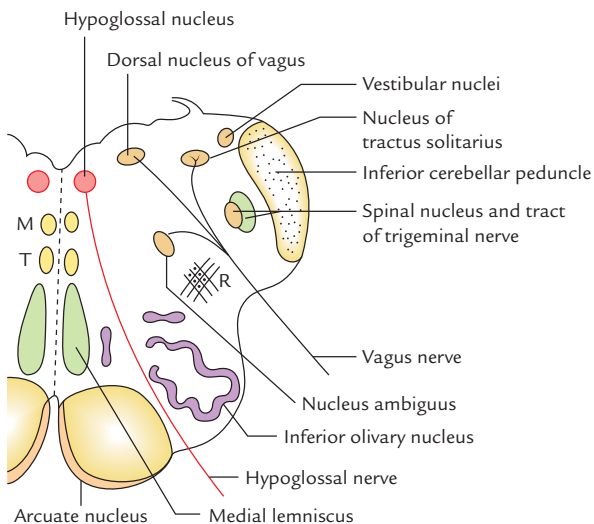


Fig. 24.5 Transverse section of medulla at the level of olives (M = medial longitudinal bundle, R = reticular formation, T = tectospinal tract).

in the section through the upper part of medulla. It presents crumpled bag-like appearances. Close to the main nucleus lies medial and dorsal accessory olivary nuclei.

N.B. Transverse section of medulla just inferior to the pons presents the same features as those seen in the transverse section of medulla at the level of the olives, except that:

- The *lateral vestibular nucleus* replaces the inferior vestibular nucleus.
- The *cochlear nuclei* are now visible. The dorsal and ventral cochlear nuclei lie on the dorsolateral and ventrolateral aspects of the inferior cerebellar peduncle, respectively.

ARTERIAL SUPPLY OF THE MEDULLA

The medulla is supplied by the following arteries:

1. Two vertebral arteries.
2. Anterior and posterior spinal arteries.
3. Anterior and posterior inferior cerebellar arteries.
4. Basilar artery.

Clinical correlation

- **Lateral medullary (posterior inferior cerebellar artery) syndrome of Wallenberg:** It occurs due to thrombosis of the posterior inferior cerebellar artery, thus affecting a wedge-shaped area on the dorsolateral aspect of the medulla and the inferior surface of the cerebellum, and produces the following main signs and symptoms:
 - *Contralateral loss of pain and temperature sensation in the trunk and limbs*, due to involvement of spinothalamic tract.
 - *Ipsilateral loss of pain and temperature sensation over the face*, due to involvement of the spinal nucleus and tract of the trigeminal nerve.
 - *Ipsilateral paralysis of muscles of palate, pharynx, and larynx*, due to involvement of nucleus ambiguus.
 - *Ipsilateral ataxia*, due to involvement of inferior cerebellar peduncle and cerebellum.
 - *Giddiness*, due to involvement of vestibular nuclei.
- **Medial medullary syndrome:** It occurs due to involvement of the paramedian region of the medulla following damage to penetrating branches of the anterior spinal branch of the vertebral artery. It produces the following signs and symptoms:
 - *Contralateral hemiplegia/paralysis of arm and leg*, due to damage of pyramid.
 - *Ipsilateral paralysis and atrophy of the half of the tongue*, due to damage of hypoglossal nerve.
 - *Contralateral loss of position and vibration sense* due to damage of medial lemniscus.

PONS

The pons is a bulky broad transverse mass of the brainstem between the midbrain and medulla.

On either side, the pons is continuous as the middle cerebellar peduncle, thus forming a bridge between the two cerebellar hemispheres, hence its name pons (L. *pons* = bridge).

EXTERNAL FEATURES

The pons has **two surfaces**: ventral and dorsal, and **two borders**: superior and inferior.

Features on the Ventral Aspect

The ventral surface of pons is **convex** in both the directions, i.e., from before backward and from side to side. It is transversely striated due to underlying pontocerebellar fibres.

In the median plane, it presents a vertical groove, the **basilar groove** which lodges the basilar artery.

The **trigeminal nerve** is attached to this surface by two roots: a small motor and a large sensory root (the motor root lies medial to the sensory root).

Rostrally, the junction between the midbrain and pons is marked by **cerebral peduncles** and the intervening interpeduncular fossa; caudally the pontomedullary junction is marked by a shallow groove. In this groove, from medial to lateral, the abducent (6th), facial (7th), and vestibulocochlear (8th) nerves emerge.

The superior cerebellar arteries curve along the superior border, intervening between the oculomotor and trochlear nerves. The anterior inferior cerebellar arteries curve round the inferior border.

Features on the Dorsal Aspect

The dorsal surface of the pons is covered by the cerebellum, and separated from it by the cavity of the 4th ventricle. The dorsal surface of the pons is triangular and forms the upper part of the floor of the 4th ventricle. For details of features on the dorsal surface of pons, see the floor of the 4th ventricle described in detail in Chapter 25.

INTERNAL STRUCTURE

A cross section at any level of pons shows two distinct regions:

1. A large ventral or **basilar part**.
2. A small dorsal or **tegmental part**.

The **ventral or basilar part** is continuous inferiorly with the pyramids of the medulla and on each side with the middle cerebellar peduncle.

The **dorsal or tegmental part** is a direct upward continuation of the medulla excluding the pyramids.

The structure of basilar part is the same at all levels of pons, but the structure of tegmental part varies considerably in the upper and lower parts of the pons.

Basilar part

Basilar part is composed of the longitudinal bundles of fibres, the transverse fibres, and the pontine nuclei:

1. **Longitudinal bundles of fibres** include corticopontine, corticonuclear, and corticospinal fibres.
 - (a) The *corticopontine fibres* relay in the ipsilateral pontine nuclei.
 - (b) The *corticonuclear fibres* terminate in the contralateral (and to some extent ipsilateral) motor nuclei of the cranial nerves.
 - (c) The *corticospinal fibres* converge toward the lower part of the pons and form the pyramids of the medulla.
2. **Transverse fibres** arise in the pontine nuclei and cross to the opposite side to form the middle cerebellar peduncle. These are *pontocerebellar fibres*.
3. **Pontine nuclei** are scattered among the longitudinal and transverse fibres.

Tegmental part

Tegmental part is traversed by a number of ascending and descending tracts and contains a decussation of transversely running fibres, the **trapezoid body**. It also contains the nuclei of trigeminal (5th), abducent (6th), facial (7th), and vestibulocochlear (8th) nerves.

Since the structure of tegmentum differs in the lower (caudal) and upper (cranial) parts of the pons, it is studied by examining transverse sections at these two levels.

T.S. Through Lower Part of the Pons

Transverse section through the lower part of the pons passes through the facial colliculi (Fig. 24.6).

The tegmentum at this level presents the following features:

Grey Matter

The grey matter at this level comprises:

1. The *abducent nerve nucleus* lying beneath the facial colliculus in the floor of the 4th ventricle.
2. The **motor nucleus of the facial nerve** lying ventrolateral to the abducent nucleus. The fibres of the facial nerve first wind round the abducent nucleus, producing the **facial colliculus**, then pass anteriorly between the facial nucleus and the nucleus of the spinal tract of the trigeminal nerve.
3. The **superior salivatory, inferior salivatory, and lacrimatory nuclei** lying medial to the motor nucleus of the facial nerve.

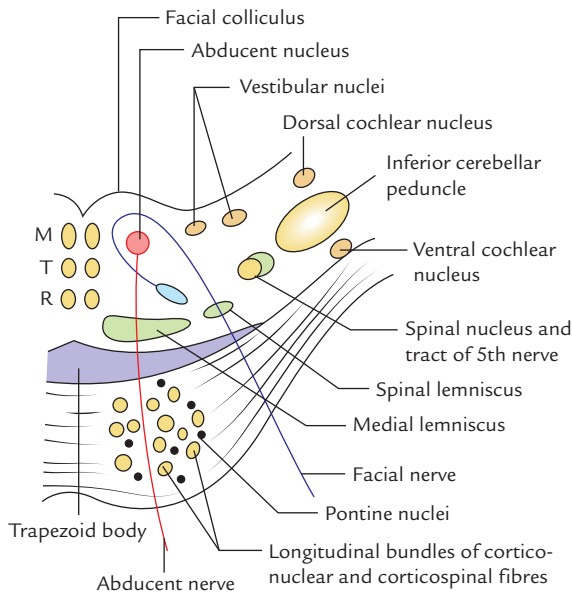


Fig. 24.6 Transverse section through the lower part of the pons (M = medial longitudinal bundle, R = rubrospinal tract, T = tectospinal tract).

4. The **nucleus of tractus solitarius** lying lateral to the superior salivatory nucleus.
5. The **vestibular nuclei** lying beneath the vestibular area in the floor of the 4th ventricle.
6. The **dorsal and ventral cochlear nuclei** situated dorsal and ventral to the inferior cerebellar peduncle, respectively.
7. The **spinal nucleus of the trigeminal nerve and its tract** located on the anteromedial aspect of the inferior cerebellar peduncle.

White Matter

The white matter at this level comprises:

1. The **trapezoid body** that is a trapezium-shaped mass of white fibres lying in the anterior part of the tegmentum, just posterior to the basilar part of the pons. It is formed by the decussation of transversely running fibres arising from the cochlear nuclei of both the sides.
2. The **medial lemniscus** situated in the most anterior part of the tegmentum with its long axis running transversely.
3. The **spinal lemniscus** lying lateral to the medial lemniscus and occupying the same peripheral position as in the medulla.
4. The **medial longitudinal bundle** occupying a paramedian position in the most posterior part.
5. The **tectospinal tracts** located ventral to the medial longitudinal bundles.
6. The **spinal tract of the trigeminal nerve** lying lateral and dorsal to the motor nucleus of the facial nerve.

T.S. Through Upper Part of the Pons (Fig. 24.7)

Transverse section through the upper part of the pons passes through the trigeminal nuclei.

The tegmentum at this level presents the following features:

Grey Matter

The grey matter at this level comprises:

1. The **motor nucleus of trigeminal nerve** situated in the dorsolateral part, beneath the lateral part of the 4th ventricle. The emerging motor fibres travel anteriorly through the substance of the pons and exit on its anterior surface.
2. The **principal (main) sensory nucleus of the trigeminal nerve** situated lateral to the motor nucleus.

White Matter

The white matter at this level consists of the same ascending tracts as in the lower part. However, the **lateral lemniscus** is well formed here. The spinal lemniscus lies between the medial and lateral lemnisci.

The **trigeminal lemniscus** consisting of trigeminothalamic fibres is also seen between medial lemniscus and spinal lemniscus.

N.B. The ventral part of tegmentum, immediately posterior to the basilar part, presents four lemnisci. From the medial to lateral side, these are: medial lemniscus, trigeminal lemniscus, spinal lemniscus, and lateral lemniscus.

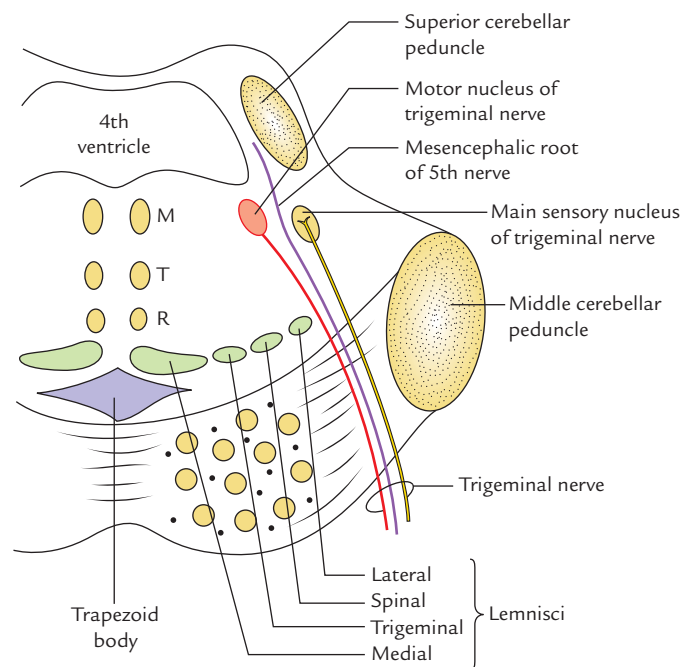


Fig. 24.7 Transverse section through the upper part of the pons (M = medial longitudinal bundle, R = rubrospinal tract, T = tectospinal tract).

ARTERIAL SUPPLY

The pons is supplied by the following arteries:

1. Numerous (pontine) branches from the basilar artery.
2. Anterior inferior cerebellar artery.

Clinical correlation

Millard–Gubler syndrome: It results from a lesion in the lower part of the pons which is so placed that it includes the pyramidal tract and the emerging fibres of the abducent and facial nerves.

The characteristic features of this syndrome are as follows:

- *Ipsilateral medial squint* due to involvement of the abducent nerve.
- *Ipsilateral facial palsy*, due to involvement of facial nerve fibres.
- *Contralateral hemiplegia*, due to involvement of the corticospinal tract.

MIDBRAIN

The midbrain is the shortest segment of the brainstem. It connects the pons to the diencephalon and cerebrum. Its cavity, the **cerebral aqueduct** (**aqueduct of Sylvius**) connects the 3rd ventricle with the 4th ventricle.

EXTERNAL FEATURES

Features on the Ventral Aspect

The ventral surface of the midbrain presents two **crura cerebri** which emerge from the cerebral hemispheres and converge downward to enter the pons forming the posterolateral boundaries of the interpeduncular fossa.

The superficial surface of the crus cerebri is finely corrugated by the underlying longitudinal fibres.

The oculomotor nerve emerges on either side from a groove on the medial side of the crus cerebri.

Features on the Dorsal Aspect

The dorsal surface of the midbrain presents four rounded elevations: two superior and two inferior colliculi (or *corpora quadrigemina*). The colliculi are separated from each other by a cruciform sulcus. The vertical limb of sulcus when traced above, forms a surface depression which lodges the **pineal body** and when traced below, it becomes continuous with the **frenulum veli** (a median ridge on the dorsal surface of *superior medullary velum*).

The trochlear nerves emerge one on each side of the upper part of frenulum veli after decussation in the superior medullary velum. Thick ridges of white matter extending from the lateral side of each colliculus constitute their brachia.

The **superior brachium** connects the superior colliculus to the lateral geniculate body and the optic tract and is made up of optic tract fibres. The **inferior brachium** connects the inferior colliculus to the medial geniculate body, and is made up of auditory fibres.

INTERNAL STRUCTURE

The internal structure of the midbrain is studied conveniently by examining its transverse sections. The transverse section of the midbrain shows a tiny canal, called **cerebral aqueduct**. A coronal plane passing through the aqueduct divides the midbrain into two parts: a small posterior part and a large anterior part.

The small posterior part is called **tectum** and consists of four colliculi. The large anterior part is divided into two equal right and left halves, the **cerebral peduncles** by a vertical plane. Each cerebral peduncle is further subdivided into three parts; from dorsal to ventral, these are: (a) tegmentum, (b) substantia nigra, and (c) crus cerebri.

The structures in the tectum and tegmentum vary at different levels of the midbrain, but those of the crus cerebri and substantia nigra are nearly the same throughout the length of the midbrain.

Crus Cerebri (Basis Pedunculi)

The crus cerebri is the part of the cerebral peduncle situated anterolateral to substantia nigra. It contains important descending tracts which connect the cerebral cortex to the anterior horn cells of the spinal cord, cranial nerve nuclei, and pontine nuclei.

Substantia Nigra

The substantia nigra is a curved (crescent shaped) pigmented band of grey matter (thicker medially than laterally) situated between tegmentum and crus cerebri. Its concavity is smooth and directed toward the tegmentum.

The substantia nigra is made up of deeply pigmented nerve cells which contain melanin (a polymerized form of dopamine) and iron.

The structure of tectum and tegmentum vary at different levels; therefore, it is again best studied by examining the T.S. of the midbrain at the following two levels: (a) at the level of the inferior colliculi, and (b) at the level of superior colliculi.

T.S. of Midbrain at the Level of Inferior Colliculi

The grey and white matter at this level present the following features (Fig. 24.8):

Grey Matter

1. The central grey matter (grey matter around the cerebral aqueduct) contains two nuclei: (a) the nucleus of the

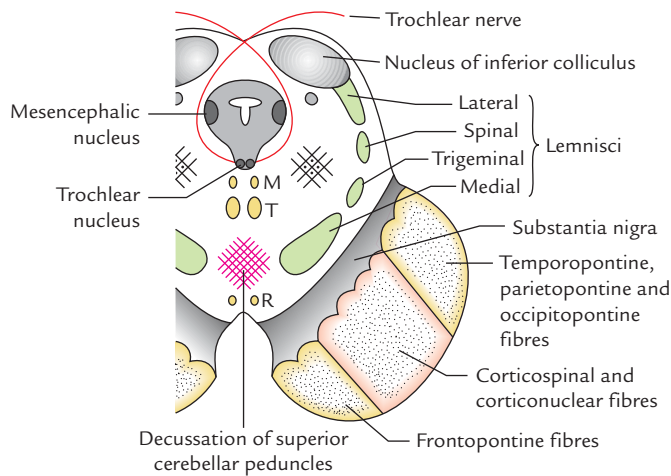


Fig. 24.8 Transverse section of the midbrain at the level of inferior colliculi (M = medial longitudinal bundle, R = rubrospinal tract, T = tectospinal tract).

trochlear nerve, and (b) the mesencephalic nucleus of the trigeminal nerve.

- The *trochlear nerve nucleus* is situated close to the median plane just posterior to the MLF. The emerging fibres of the trochlear nerve pass laterally and posteriorly around the central grey matter and leave the midbrain just below the inferior colliculi. The fibres of the trochlear nerve now decussate in the superior medullary vellum before emerging on the surface.
 - The *mesencephalic nucleus of the trigeminal nerve* lies in the lateral edge of the central grey matter.
2. An ovoid mass of grey matter underneath the inferior colliculus forms the **nucleus of inferior colliculus**.

White Matter

1. The **decussation of the superior cerebellar peduncles** occupies the central part of the tegmentum and forms the most important feature in the lower part of the midbrain.
2. The **lemnisci** are arranged in the form of a curved compact band of white fibres in the ventrolateral part of the tegmentum, lateral to cerebellar decussation and dorsal to the substantia nigra. From medial to lateral side, these are: *medial lemniscus*, *trigeminal lemniscus*, *spinal lemniscus*, and *lateral lemniscus*.
3. The MLF lies on the side of the median plane ventral to the trochlear nerve nucleus.

T.S. of Midbrain at the Level of Superior Colliculi

The grey and white matter in the midbrain at this level present the following features (Fig. 24.9):

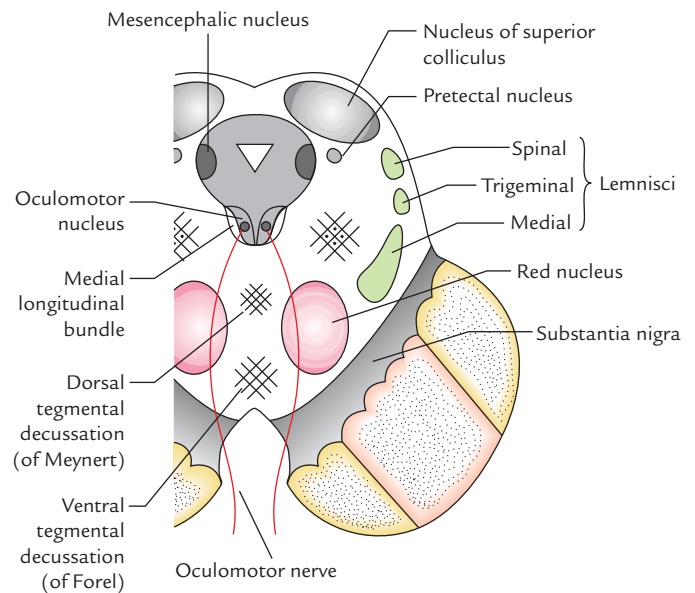


Fig. 24.9 Transverse section of the midbrain at the level of superior colliculi.

Grey Matter

1. The **central grey matter** in each half contains two nuclei: the oculomotor nerve nucleus and the mesencephalic nucleus.
 - The *oculomotor nucleus* lies in the ventromedial part. The nuclei of two sides fuse together forming a single complex having a triangular outline. The emerging fibres of oculomotor nerve pass ventrally through the tegmentum, intersecting red nucleus and medial part of the substantia nigra and emerge in the posterior part of the interpeduncular fossa through the sulcus on the medial aspect of crus cerebri.
 - The *mesencephalic nucleus* occupies the same position as in the lower part of the midbrain.
2. The nucleus of **superior colliculus** consists of cells which are involved in *general light reflexes*.
3. **Pretectal nucleus** is a small group of nerve cells and lies deep to the superolateral part of the superior colliculus.
4. **Red nucleus** is a cigar-shaped mass of grey matter which appears ovoid in cross section. It is about 0.5 cm in diameter. It is situated in the tegmentum, ventral to the 3rd nerve nucleus and dorsomedial to the substantia nigra. It is an important nucleus of the extrapyramidal system.

White Matter

1. Decussation of fibres (tectospinal and tectobulbar tracts) arising from superior colliculi forming **dorsal tegmental decussation (of Meynert)**.

- Decussation of fibres (rubrospinal tracts) arising from red nuclei forming **ventral tegmental decussation** (of Forel).
- Medial longitudinal fasciculus** lying ventrolateral to the oculomotor nucleus.
- Tegmentum at this level also containing the same lemnisci (i.e., medial, trigeminal, and spinal) as those at the level of inferior colliculus *except* for the lateral lemniscus.
- Emerging fibres of the oculomotor nerve.**

Medial Longitudinal Fasciculus

Medial longitudinal fasciculus is a heavily myelinated composite tract found in the paramedian plane of the brainstem.

The fibres of MLF interconnect the nuclei of the 3rd, 4th, 6th, and 8th cranial nerves and the spinal nucleus of the accessory nerve.

The chief function of MLF is to coordinate the movements of eyes, head, and neck in response to stimulation of the vestibulo-cochlear nerve.

ARTERIAL SUPPLY

The midbrain is supplied by the following arteries:

- Basilar artery through its posterior cerebral and superior cerebellar arteries. Basilar artery also supplies the midbrain through direct branches.
- Branches of posterior communicating and anterior choroidal arteries.

Clinical correlation

- Weber's syndrome:** This syndrome is produced by a vascular lesion in the basal region of the cerebral peduncle due to occlusion of a branch of the posterior cerebral artery. This lesion involves the oculomotor nerve and the crus cerebri.

The characteristic features of this syndrome are as follows:

- *Ipsilateral lateral squint*, due to involvement of the 3rd cranial nerve.
- *Contralateral hemiplegia*, due to involvement of corticospinal tract in the crus cerebri.
- Benedikt's syndrome:** It occurs due to the vascular ischemia of the tegmentum of the midbrain, involving medial lemniscus, spinal lemniscus, red nucleus, superior cerebellar peduncle, and fibres of the oculomotor nerve. It is characterized by the following signs and symptoms:
 - *Ipsilateral lateral squint and ptosis*, due to involvement of oculomotor nerve fibres.
 - *Contralateral loss of pain and temperature sensation*, due to involvement of trigeminal and spinal lemnisci.
 - *Contralateral loss of tactile, muscle, joint, and vibration sense*, due to involvement of medial lemniscus.
 - *Contralateral tremors and involuntary movements in the limbs*, due to involvement of the red nucleus and fibres of superior cerebellar peduncle entering into it.

- Perinaud's syndrome:** It results from a lesion of the superior colliculi which occurs when this area becomes compressed by the tumors of the pineal gland. It is characterized by the loss of upward gaze without affecting the other eye movements.

DEVELOPMENT OF FUNCTIONAL COLUMNS AND NUCLEI

The brain and spinal cord develop from the neural tube. The cranial end of the neural tube forms the brain, while the caudal end forms the spinal cord.

The nerve cells in the wall of the neural tube arrange themselves into functional groups.

FUNCTIONAL GROUPS/COLUMNS OF CELLS IN THE SPINAL CORD

In cross section, the central canal projects laterally into a groove on the inner wall of the spinal cord as **sulcus limitans** and divides the wall of the spinal cord on each side into two parts: dorsal and ventral laminae. The dorsal and ventral laminae are also frequently termed **alar** and **basal laminae**, respectively.

The alar lamina consists of sensory cells and basal lamina consists of motor cells. The cells in each lamina are arranged into two columns: the one near the sulcus limitans, concerned with the innervation of viscera, is called the **visceral column** and the one away from sulcus limitans, concerned with innervation of somatic structures, is called the **somatic column**.

Thus, there are four functional columns on either side in the lateral wall of the spinal cord (Fig. 24.10): two sensory columns in the alar lamina and two motor columns in the basal lamina, namely

- General somatic afferent.
- General visceral afferent.
- General somatic efferent.
- General visceral efferent.

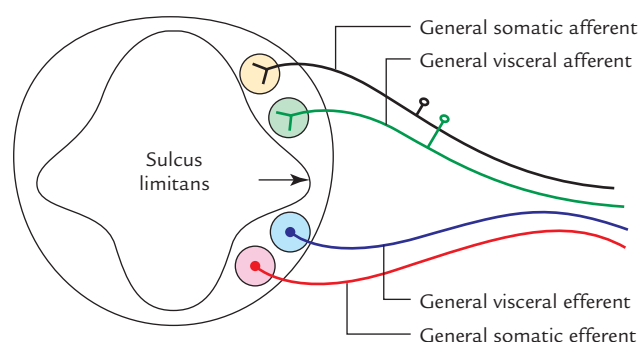


Fig. 24.10 Functional columns in the lateral wall of the spinal cord.

FUNCTIONAL COLUMNS AND NUCLEI IN THE BRAINSTEM

There is a similar arrangement in the brainstem, but here a third type of cell column appears in each lamina between the visceral and somatic column to innervate the derivatives of pharyngeal arches. This column is termed the **special visceral column**.

Apart from this, an extra **special somatic column** appears in the most lateral part of the alar lamina to innervate the vestibular and cochlear apparatuses. Thus, there are seven functional columns in the brainstem: four in the alar lamina and three in the basal lamina (Fig. 24.11), namely

1. Special somatic afferent (SSA).
2. General somatic afferent (GSA).
3. Special visceral afferent (SVA).
4. General visceral afferent (GVA).

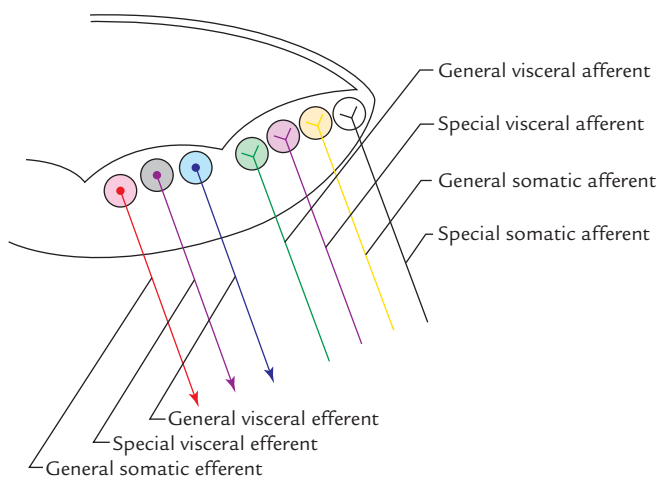


Fig. 24.11 Functional columns in the brainstem.

5. General somatic efferent (GSE).
6. Special visceral efferent (SVE).
7. General visceral efferent (GVE).

As the development proceeds, each column differentiates into two or more discrete cranial nerve nuclei (Table 24.1).

RETICULAR FORMATION

The reticular formation is a diffuse ill-defined mass of nerve cell clusters and interlacing nerve fibres occupying the entire core of the brainstem.

Phylogenetically, it represents the old reticular core of the brain and contains within it the 'vital centres'.

Reticular formation extends cranially to the diencephalon and caudally to the spinal cord.

The reticular formation receives data from most of the sensory systems of the body and relay them to all the levels of the neuraxis. It is important for the maintenance of sleep-wake cycle, level of consciousness, and alertness or mutism.

Although reticular formation is described as a network of nerve fibres intermingled with nerve cells, on careful examination it reveals fairly localized cell groups called *reticular nuclei* in certain regions.

The reticular pathways are polysynaptic, both ascending and descending, and crossed and uncrossed. As a result, unilateral stimulation produces bilateral responses.

FUNCTIONAL COMPONENTS OF RETICULAR FORMATION

Functionally, the reticular formation is divided into subgroups, *viz.*

1. Ascending reticular activating system (ARAS).
2. Descending reticular system (DRS).

Table 24.1 Cranial nerve nuclei derived from various functional columns in the brainstem

GSE column	SVE column	GVE column	GVA/SVA column	GSA column	SSA column
Oculomotor nucleus	Motor nucleus of the trigeminal nerve	Edinger–Westphal nucleus	Nucleus of the solitary tract (nucleus tractus solitarius)	Sensory nuclei of the trigeminal nerve 1. Chief 2. Mesencephalic 3. Spinal	Vestibular nuclei
Trochlear nucleus	Motor nucleus of the facial nerve	Lacrimary nucleus			Cochlear nuclei
Abducent nucleus		Superior salivatory nucleus			
Hypoglossal nucleus	Nucleus ambiguus	Inferior salivatory nucleus			
		Dorsal nucleus of the vagus nerve			

The ARAS is believed to be responsible for the maintenance of alertness and consciousness of the brain. It is generally termed simply a **reticular activity system (RAS)** by clinicians.

The DRS consists of descending pathways to autonomic centres of the brainstem and plays a critical role in regulating the functions of the vital centres, *viz.* respiratory centre, cardiac centre, and vasomotor centre.

Clinical correlation

The visual and acoustic stimuli can stimulate the reticular activating system and thus maintain alertness and attention.

For this reason, the stimuli such as sound of ringing alarm clock or sudden bright light can arouse consciousness. The sleep is thought to occur due to decrease in the activity of RAS. A coma is a state of unconsciousness due to the inactivity of RAS.

Golden Facts to Remember

- | | |
|---|--|
| ▶ Most important part of the brain for survival | Medulla oblongata |
| ▶ All the cranial nerves arise from the brainstem except | Olfactory and optic |
| ▶ Shortest segment of the brainstem | Midbrain |
| ▶ All the nuclei of the last four cranial nerves are located in the medulla oblongata except | Nucleus of spinal part of the accessory (11th) nerve which is located in the upper five cervical spinal segments |
| ▶ Most prominent feature in the transverse section of the midbrain at the level of superior Colliculi | Presence of red nuclei |
| ▶ Largest segment of the brainstem | Pons |
| ▶ All the cranial nerves arise from the ventral aspect of the brain except | Trochlear nerve which arises from the dorsal aspect of the brain |
| ▶ Nuclei of brainstem which functionally belong to basal nuclei | Substantia nigra, red nucleus |
| ▶ Most important centres present in the reticular formation | Vital centres (respiratory, cardiac, vasomotor) |

Clinical Case Study



A 55-year-old man went to his family physician and complained that for the past few days he has been having difficulty in walking. He also noted that when he walks, his left arm remains flexed and his left leg remains extended. Further, he has to swing his left lower limb outward to avoid dragging the foot on the ground. His family physician referred him to the neurologist.

On examination, the neurologist found: (i) no signs of facial palsy, (ii) deviation of tongue to the right side on protrusion, (iii) atrophy of tongue on the right side, and (iv) loss of position and vibration sense on the left side. A diagnosis of right-sided *medial medullary syndrome* was made.

Questions

1. Name the area of medulla involved in medial medullary syndrome.
2. What is the commonest cause of this syndrome?
3. Mention the cause of weakness of left arm and left leg (left-sided hemiplegia).
4. What is the cause of loss of position and vibration sense on the left side?

Answers

1. Paramedian region.
2. Occlusion of anterior spinal artery.
3. Destruction of right pyramid.
4. Destruction of medial lemniscus on the right side.

Cerebellum and Fourth Ventricle

CEREBELLUM

The cerebellum (L. *cerebellum* = little brain) is the largest part of the hindbrain and the second largest part of the brain as a whole. It weighs about 150 g. It is located in the posterior cranial fossa underneath the tentorium cerebelli and behind the pons and medulla oblongata. It is separated from the pons and medulla by the cavity of the 4th ventricle (Fig. 25.1). Its surface is indented by numerous fine slit-like sulci called **fissures**. Between the fissures lie more or less parallel folds called **folia**. In general, the *fissures and folia* of the cerebellum lie transversely from side-to-side across the whole extent of the cerebellum.

The cerebellum consists of two hemispheres united in the midline by the vermis.

Each hemisphere of the cerebellum is connected to three parts of the brainstem by three pairs of the large fibre tracts called **cerebellar peduncles**.

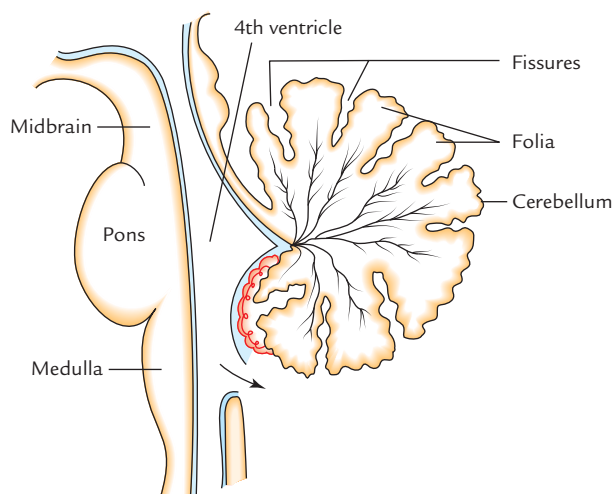


Fig. 25.1 Sagittal section through the brainstem and cerebellum. The arrow is in the median aperture of the 4th ventricle.

The basic functions of the cerebellum are as follows:

1. Maintenance of equilibrium.
2. Regulation of muscle tone.
3. Coordination of somatic motor activities.

The cerebellar disease is manifested by motor disturbances, including inability to stand upright, staggering gait, hypotonia, and failure of coordination.

EXTERNAL FEATURES

The external features of the cerebellum comprise three parts: two surfaces, two notches, and three well-marked fissures (Fig. 25.2).

Parts

The cerebellum consists of three parts: two large lateral hemispherical lobes, the **cerebellar hemispheres**, and a narrow

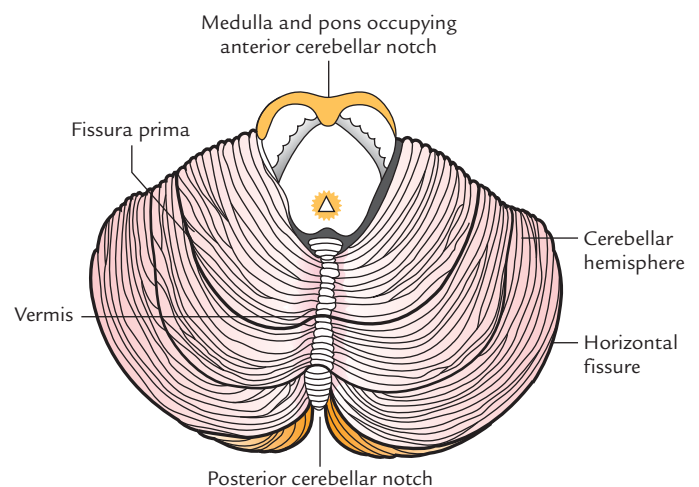


Fig. 25.2 Superior view of the cerebellum. Note the fissures and folia on the surface of the cerebellum.

median worm-like portion, called **vermis**. The superior and inferior aspects of vermis are termed *superior* and *inferior vermis*, respectively. The ridge-like superior vermis is continuous on either side with the superior surface of cerebellar hemisphere imperceptively. The inferior vermis is more clearly demarcated from the hemispheres in the floor of *vallecula cerebelli*.

Surfaces

The **superior surface** of the cerebellum is convex. The two cerebellar hemispheres are continuous with each other on this surface. The **inferior surface** presents a deep median notch called **vallecula** which separates the two cerebellar hemispheres. The floor of the vallecula is formed by the inferior vermis and is limited on each side by *sulcus valleculae* (Fig. 25.4).

Notches

The anterior aspect of cerebellum is marked by a wide shallow **anterior cerebellar notch** which accommodates pons and medulla. The **posterior cerebellar notch** is deep and narrow, and lodges the falx cerebelli.

Fissures

1. The **horizontal fissure** is most conspicuous and runs along the lateral and posterior margins of the cerebellum. It marks the junction between the superior and inferior surfaces of the cerebellum.
2. The **posterolateral fissure** lies on the inferior surface of the cerebellum and separates the *flocculonodular lobe* from the rest of the cerebellum (*corpus cerebelli*).
3. The V-shaped **fissura prima** on the superior surface cuts the superior vermis at the junction of its anterior two-third and posterior one-third. It divides the corpus cerebelli into *anterior* and *posterior (middle) lobes*.

N.B. There are several other fissures which subdivide the vermis and cerebellar hemispheres into lobules and given fanciful names. Most of them are ignored to lessen the complexity of the cerebellum and only those which have a functional or descriptive value are given.

SUBDIVISIONS OF THE CEREBELLUM

ANATOMICAL SUBDIVISIONS

Anatomically the cerebellum is divided into the following three lobes (Fig. 25.3):

1. Anterior.
2. Posterior.
3. Flocculonodular.

Anterior lobe: It lies on the superior surface anterior to the fissura prima.

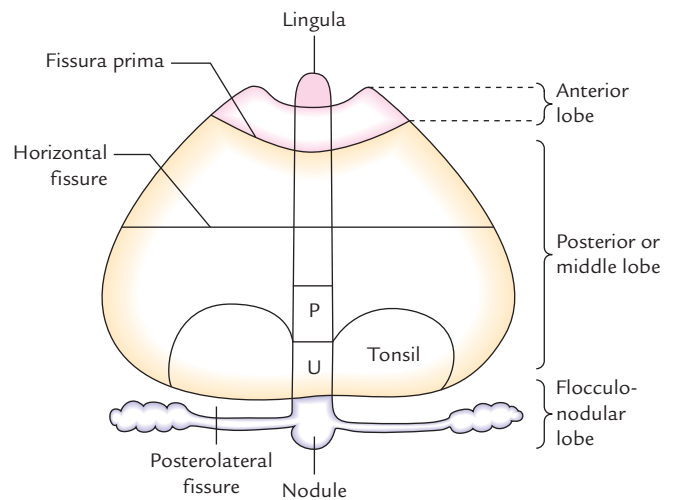


Fig. 25.3 Anatomical lobes of the cerebellum.

Posterior/middle lobe: It lies between the fissura prima on the superior surface and posterolateral fissure on the inferior surface.

Flocculonodular lobe: It is the smallest of all and lies on the inferior surface in front of the posterolateral fissure.

MORPHOLOGICAL SUBDIVISIONS

Based on phylogenetic and functional criteria, the cerebellum is divided into the following three parts:

1. Archicerebellum.
2. Paleocerebellum.
3. Neocerebellum.

Archicerebellum (Vestibular cerebellum): Phylogenetically, it is the oldest part of the cerebellum. It consists of flocculonodular lobe and lingula.

The archicerebellum is chiefly vestibular in connections and concerned with the maintenance of equilibrium, tone, and posture of trunk muscles.

Paleocerebellum (Spinal cerebellum): Phylogenetically, it is the next part of the cerebellum to appear. It consists of anterior lobe (except lingula) and pyramid, and the uvula of inferior vermis.

The paleocerebellum is chiefly spinocerebellar in connections and is concerned with the tone, posture, and crude movements of the limbs.

Neocerebellum (Cerebral cerebellum): Phylogenetically, it is the most recent part of the cerebellum to develop. It is made up of middle lobe, the largest part of the cerebellum (except the pyramid and the uvula of inferior vermis).

The neocerebellum is chiefly corticopontocerebellar in connections and is concerned with the smooth performance of skilled voluntary movements.

INTERNAL STRUCTURE

The cerebellum is made up of a thin surface layer of grey matter, the **cerebellar cortex**, and a **central core** of white matter. Embedded within the central core of white matter are masses of grey matter called **intracerebellar nuclei**.

The cerebellar cortex is folded in such a way that the surface of cerebellum presents a series of parallel transverse **fissures** and intervening narrow leaf-like bands called **folia**. Each folium consists of a slender branched lamina of central core of white matter covered by a thin layer of grey matter. The central core of white matter being arranged in the form of branching pattern of a tree is called **arbor vitae cerebelli** (arbor vitae = tree of life).

STRUCTURE OF THE CEREBELLAR CORTEX

The structure of the cerebellar cortex is uniform throughout (homotypical).

Cerebellar cortex consists of the following three distinct layers:

1. Outer molecular layer.
2. Intermediate Purkinje cell layer.
3. Inner granular layer.

Molecular (plexiform) layer: It mainly consists of numerous dendritic arborizations of Purkinje cells and relatively few nerve cells which are widely spaced. The nerve cells are of two types: (a) the basket cells and (b) the stellate cells.

Purkinje cell layer: It consists of a single row of large flask-shaped cells, the **Purkinje cells**.

The outgoing Purkinje axons constitute the sole output from the cerebellar cortex and exert an inhibitory influence on the intracerebellar nuclei.

Granular layer: The inner granular layer consists of numerous closely packed small **granule cells**. This layer also contains few large **Golgi cells**.

Intrinsic Neurons of the Cerebellar Cortex

There are five types of intrinsic neurons in the cerebellar cortex, *viz.*

1. Purkinje cells.
2. Granule cells.
3. Stellate cells.
4. Basket cells.
5. Golgi cells.

All the intrinsic neurons of cerebellar cortex are inhibitory except granule cells. Such a collection of inhibitory neurons is not found anywhere else in the central nervous system except in the cerebellum.

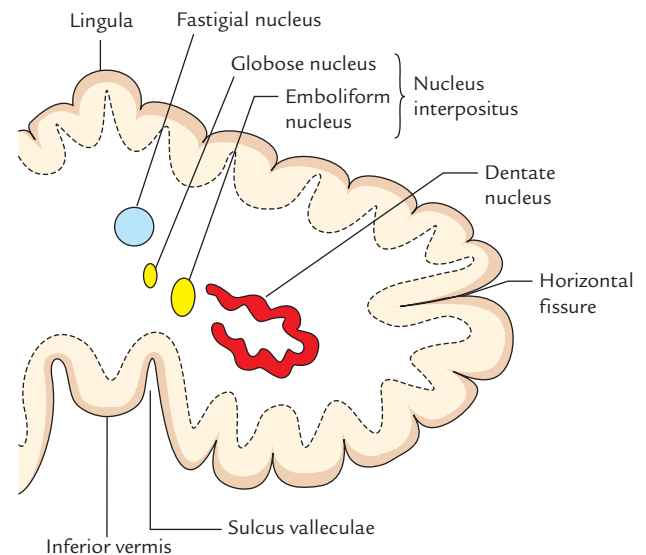


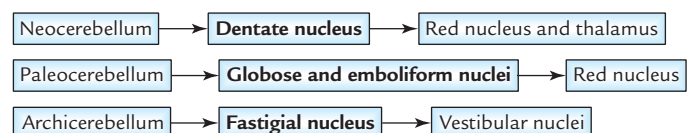
Fig. 25.4 Transverse section of the cerebellum showing intracerebellar nuclei.

INTRACEREBELLAR NUCLEI

The intracerebellar nuclei (also called central nuclei) are masses of grey matter embedded in the white matter of the cerebellum. On each side of the midline they are four in number. From lateral to medial side, these are: dentate nucleus, emboliform nucleus, globose nucleus, and fastigial nucleus (Fig. 25.4).

1. The **dentate nucleus** is the most prominent of the intracerebellar nuclei and largest in primates, especially in humans. It is the nucleus of *neocerebellum*, and therefore receives afferent fibres from it.
2. The **emboliform nucleus** is oval in shape and situated medial to the dentate nucleus, partially covering its hilum. It is the nucleus of *paleocerebellum*, hence receives afferent fibres from it.
3. The **globose nucleus** is rounded in shape and lies between the emboliform and fastigial nuclei. It has similar connections to that of the emboliform nucleus. The globose and emboliform nuclei together are sometimes referred to as **nucleus interpositus**.
4. The **fastigial nucleus** lies near the midline in the vermis and close to the roof of the 4th ventricle is the nucleus of archicerebellum, hence receives afferent fibres from the flocculonodular lobe (archicerebellum).

The nuclear connections of the cerebellum are summarized in Flowchart 25.1.



Flowchart 25.1 Nuclear connections of the cerebellum.

CEREBELLAR PEDUNCLES

The afferent and efferent fibres of the cerebellum are grouped together on each side into three large bundles called cerebellar peduncles.

The *superior cerebellar peduncles* connect the cerebellum to the midbrain, the *middle cerebellar peduncles* to the pons, and the *inferior cerebellar peduncles* to the medulla oblongata.

The *inferior cerebellar peduncle* is formed on the posterolateral aspect of the upper half of the medulla oblongata. It consists of a large number of afferent and efferent fibres. *The inferior cerebellar peduncle consists mainly of afferent fibres to the cerebellum from the spinal cord, the olivary nuclei, the reticular formation of the medulla, and the vestibular nuclei and nerve.* It also transmits a few efferent fibres from the cerebellum to the medulla, principally to the vestibular nuclei and reticular formation.

The *middle cerebellar peduncle* is the largest of the three peduncles. It is formed at the posterolateral margin of the pons. *The middle cerebellar peduncle consists of only afferent fibres which arise from the pontine nuclei of the opposite side.*

The *superior cerebellar peduncle* emerges from the anterior cerebellar notch and forms the lateral boundary of the upper half of the 4th ventricle. *It mainly consists of efferent fibres passing from the dentate nucleus to the red nucleus, thalamus and cerebral cortex of the opposite side. It is the principal efferent pathway from the cerebellum and its fibres arise mainly in the dentate nucleus.*

ARTERIAL SUPPLY OF THE CEREBELLUM

The cerebellum is supplied by three pairs of cerebellar arteries:

1. **Superior cerebellar artery:** a branch of basilar artery supplies the superior surface of the cerebellum.
2. **Anterior inferior cerebellar artery:** a branch of basilar artery supplies the anterior part of the inferior surface of the cerebellum.
3. **Posterior inferior cerebellar artery:** a branch of vertebral artery supplies the posterior part of the inferior surface of the cerebellum.

Clinical correlation

Lesions of cerebellum: The cerebellar lesions due to trauma, vascular occlusion, tumors, etc. produce a number of signs and symptoms, which together constitute the *cerebellar syndrome*.

The characteristic signs and symptoms of the cerebellar syndrome are as follows:

- (a) *Generalized muscular hypotonia*, leading to staggering gait (i.e., the patient walks with legs well apart) and *ataxia* (i.e., inability to maintain balance while walking).
- (b) *Intention tremors* at the end of a voluntary act, and disappear with rest.

- (c) *Adiadochokinesis*, i.e., inability to perform rapidly alternating opposite movements, e.g., pronation and supination.
- (d) *Dysarthria or scanning speech*, i.e., speech is slurred, monotonous with pauses at wrong places.
- (e) *Nystagmus*, i.e., involuntary 'to and fro' oscillatory movements of the eyeballs while looking to either side due to defective postural fixation of the conjugate gaze.
- (f) *Swaying* toward the side of lesion on walking.
- (g) Falling on the side of lesion on closing the eyes (*Romberg's sign*).

FOURTH VENTRICLE

The 4th ventricle is a tent-like cavity of the hindbrain lined with ependyma and filled with cerebrospinal fluid (CSF). It is situated in the posterior cranial fossa in front of the cerebellum and behind the pons and the upper part of medulla oblongata. The cavity of the ventricle presents a triangular outline in the sagittal section and appears rhomboidal (lozenge shaped) in the horizontal section. It is continuous inferiorly with the central canal of medulla oblongata and superiorly with the cerebral aqueduct of the midbrain (Fig. 25.1).

The understanding of the 4th ventricle is essential, firstly because it is strategically placed in the midst of **vital structures** present in the medulla, pons, and cerebellum, and secondly because its roof possesses three important openings which permit the CSF to escape from the ventricular system of the brain to the subarachnoid space.

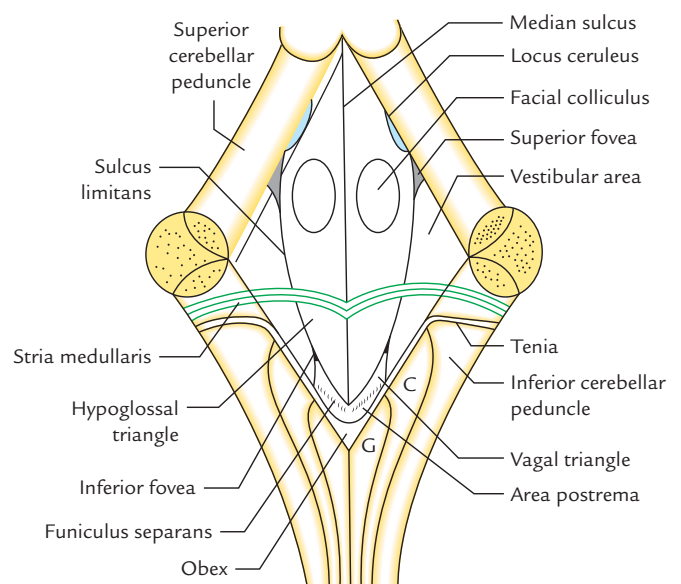


Fig. 25.5 Rhomboid fossa (floor of the 4th ventricle) (C = cuneate tubercle, G = gracile tubercle).

BOUNDARIES

The boundaries of the 4th ventricle include lateral boundaries, a roof, and a floor.

Lateral Boundaries (Lateral Walls)

On each side, the 4th ventricle is bounded,

- (a) *inferolaterally* by the inferior cerebellar peduncle, supplemented by gracile and cuneate tubercles, and
- (b) *superolaterally* by the superior cerebellar peduncle.

Roof (Posterior Wall)

The roof of the 4th ventricle is tent-shaped and has upper and lower sloping surfaces. The apex of the tent extends posteriorly into the white core of the cerebellum.

The *upper part of the roof* is formed by a thin sheet of white matter, the **superior medullary velum** that stretches between the two superior cerebellar peduncles.

The *lower part of the roof* is formed by a thin sheet of non-nervous tissue, the **inferior medullary velum** that is formed conjointly by the ventricular ependyma and the pia mater.

The lower part of the roof is perforated by a *midline slit*, the **median aperture** (the **foramen of Magendie**) through which the cavity of the 4th ventricle communicates with the subarachnoid space of the *cerebellomedullary cistern* (*cisterna magna*).

The cavity of the 4th ventricle is prolonged laterally as a narrow *lateral recess* behind and around the inferior cerebellar peduncle which opens as *lateral aperture* (foramen of Luschka) into the subarachnoid space in the region of cerebellopontine angle.

Through these three apertures in the lower part of the roof of the 4th ventricle, CSF escapes from the ventricular system into the subarachnoid space for absorption by the arachnoid villi and granulations.

Choroid Plexuses of the Fourth Ventricle

The choroid plexus is a tuft of capillaries that project into the cavity of the 4th ventricle through the lower part of its roof. It receives its blood supply from a branch of posterior inferior cerebellar artery. The entire plexus is 'T-shaped', where the vertical limb of 'T' is double with foramen of Magendie intervening between the two limbs. The horizontal limb of plexus on either side extends into the lateral recess and protrudes through the lateral aperture, the **foramen of Luschka** into the subarachnoid space, and can be seen on the surface of the brain, near the flocculus of the cerebellum.

Floor (Rhomboid Fossa)

The floor of the 4th ventricle is formed by the posterior surface of the pons and the upper part of the medulla. It is rhomboid in shape (diamond shaped) and because of its shape, the floor of the 4th ventricle is often called **rhomboid fossa** (Fig. 25.5). It is divisible into two parts.

The upper triangular part is bounded on each side by the superior cerebellar peduncle, while the lower triangular part is bounded on each side by gracile and cuneate tubercles and the inferior cerebellar peduncle.

Features of the floor of the fourth ventricle (Rhomboid fossa)

The floor of the 4th ventricle exhibits the following features:

1. The entire floor is divided into right and left symmetrical halves by a **median sulcus**, which extends from the aperture of the aqueduct of the midbrain above to the commencement of the central canal below.
2. At its widest part, the floor is crossed transversely by glistening white fibres, the **stria medullaris**. These fibres are derived from arcuate nuclei, which emerge from the median sulcus and run transversely across the floor to enter into the inferior cerebellar peduncle.
3. On either side of the median sulcus, there is a longitudinal elevation called **medial eminence**.
4. The medial eminence is bounded laterally by **sulcus limitans**.
5. At the lateral angle of the floor, the region lateral to sulcus limitans overlies the vestibular nuclei and hence it is termed the **vestibular area**.
6. The upper end of sulcus limitans widens into a triangular depression called **superior fovea**. Above the superior fovea, the sulcus limitans flattens out and presents a bluish grey area called **locus ceruleus**. The color is imparted by the underlying group of nerve cells containing melanin pigment which constitute the **substantia ferruginea**.
7. The lowermost part of sulcus limitans presents a small depression called **inferior fovea**.
8. On either side, the medial eminence presents an oval swelling in the pontine part of floor at the level of superior fovea, the **facial colliculus**. The swelling is produced by the fibres from the motor nucleus of facial nerve hooking around the abducent nucleus (**internal genu of the facial nerve**).
9. From inferior fovea, the sulcus limitans descends obliquely toward the median sulcus. This sulcus divides the medial eminence in the medullary part of the floor into two triangles: the hypoglossal triangle above and the vagal triangle below.

10. The **hypoglossal triangle** is divided by a faint oblique furrow into a medial part overlying the *nucleus of the hypoglossal nerve* and a lateral part overlying the *nucleus intercalatus*.
11. The **vagal triangle** overlies the nuclei of vagus, glossopharyngeal, and cranial accessory nerves.
12. The **vagal triangle** is crossed by a narrow translucent ridge called **funiculus separans**. A small area between the funiculus separans above and the gracile tubercle below is called **area postrema**.
13. The inferolateral margins of the 4th ventricle are marked by a narrow white ridge called **tenia**. The two teniae meet at the inferior angle of the ventricle to form a small fold called **obex**. The obex forms the roof of the inferior angle of the 4th ventricle. The term obex is often used to denote the inferior angle of the 4th ventricle.

Clinical correlation

Tumors of the fourth ventricle: The tumors in the region of the 4th ventricle are not uncommon. The tumors of fourth ventricle are *ependymoma* and *medulloblastoma*. The most common tumor in this region is *medulloblastoma*. It arises from the poorly differentiated primitive neuroectodermal cells of cerebellar vermis and occurs mostly in children.

The medulloblastoma is highly malignant and produces the signs and symptoms of cerebellar lesions. It may press upon the vital centres located beneath the floor of the ventricle causing cardiac irregularities, tachycardia, irregular respiration, and vasomotor disturbances.

The *ependymoma* arises from proliferation of ependymal cells. It may cause obstruction to the flow of CSF which may lead to the formation of *internal hydrocephalus*.

Golden Facts to Remember

- | | |
|--|--|
| ▶ Oldest part (phylogenetically) of the cerebellum | Archicerebellum |
| ▶ Most recent part (phylogenetically) of the cerebellum | Neocerebellum |
| ▶ Largest cerebellar peduncle | Middle cerebellar peduncle |
| ▶ Largest and the most prominent intracerebellar nucleus | Dentate nucleus |
| ▶ All the afferent fibres of the cerebellum are mossy fibres <i>except</i> | Olivocerebellar and par-olivocerebellar fibres which are <i>climbing fibres</i> |
| ▶ All the intrinsic neurons of the cerebellar cortex are inhibitory <i>except</i> | Granule cells |
| ▶ Most conspicuous fissure of the cerebellum | Horizontal fissure |
| ▶ Arbor vitae cerebelli | Central core of white matter of the cerebellum arranged in the form of the branching pattern of a tree |
| ▶ Largest intrinsic neurons of the cerebellum | Purkinje cells |
| ▶ Only neurons of cerebellar cortex which can transmit efferent impulses to intracerebellar nuclei | Purkinje cells |
| ▶ Parts of the cerebellum liable to herniate through the foramen magnum | Tonsils |

Clinical Case Study



A 45-year-old person visited his family physician and complained that he noticed clumsiness in his right hand. The symptoms had started 3 months back but now they were getting worse day by day. He also noticed tremors when he wrote, which disappeared as he stopped writing. He also told that he tends to sway toward the right side while walking. He was referred to a neurologist who on examination found hypotonia of muscles on the right side. When asked to walk along a straight line on the floor, he swayed over to the right side and when he was asked to touch the tip of his nose with his right index finger, the finger started trembling as it was nearing the nose and overshot the target. When he was asked to perform rapidly alternating opposite movements (e.g., supination and pronation), he could not do so by his right hand. The MRI of skull revealed a large tumor in his right cerebellar hemisphere.

Questions

1. What are the three parts of the cerebellum?

2. What are the main functions of the cerebellum?
3. Enumerate the three morphological subdivisions of the cerebellum and mention the primary function of each subdivision.

Answers

1. Two cerebellar hemispheres and a vermis.
2. The main functions of the cerebellum are: the maintenance of equilibrium and posture, the regulation of muscle tone, and the coordination of somatic motor activities.
3. The three morphological subdivisions of the cerebellum are: archicerebellum, paleocerebellum, and neocerebellum.

The maintenance of equilibrium is the primary function of the *archicerebellum*, the regulation of muscle tone and posture of trunk and limbs is the primary function of the *paleocerebellum*, and the smooth performance of fine voluntary movements is the primary function of the *neocerebellum*.

Diencephalon and Third Ventricle

DIENCEPHALON

The diencephalon is a part of brain situated cranial to the midbrain and is more or less completely surrounded by the cerebrum. The only part of diencephalon which is exposed to the surface is at the base of the brain in the region of interpeduncular fossa. The cavity within the diencephalon is termed the **3rd ventricle**. It communicates on either side with the lateral ventricle of the cerebral hemisphere.

The cavity of the 3rd ventricle divides the diencephalon into two (right and left) symmetrical halves.

DIVISIONS AND SUBDIVISIONS

The diencephalon is divided into two major parts: **pars dorsalis** and **pars ventralis**. These subdivisions are seen in midsagittal view of the brain and are separated from each other by a shallow groove, the *hypothalamic sulcus*, which extends from interventricular foramen to the rostral end of the cerebral aqueduct of the midbrain (Fig. 26.4).

Pars dorsalis lies above (dorsal) the **hypothalamic sulcus** and consists of: (a) thalamus, (b) metathalamus, and (c) epithalamus.

Pars ventralis lies below (ventral) the **hypothalamic sulcus** and consists of: (a) subthalamus and (b) hypothalamus.

Thus the diencephalon is divided into five parts: thalamus, metathalamus, epithalamus, subthalamus, and hypothalamus. Each of these parts has further subdivisions.

The main divisions and subdivisions of the diencephalon are listed in Table 26.1.

THALAMUS

Anatomically, thalamus is a large ovoid mass of grey matter lying above the midbrain, from which it is separated by a small amount of neural tissue, the **subthalamus**. There are two thalami situated one on each side of a slit-like cavity, the **3rd ventricle** (Fig. 26.1).

Table 26.1 Divisions and subdivisions of the diencephalon

Divisions	Subdivisions
Pars dorsalis	
• Thalamus (dorsal thalamus)	
• Metathalamus	Medial and lateral geniculate bodies
• Epithalamus	Pineal gland, habenular nuclei and commissure, and posterior commissure
Pars ventralis	
• Subthalamus (ventral thalamus)	Subthalamic nucleus and zona inserta
• Hypothalamus	

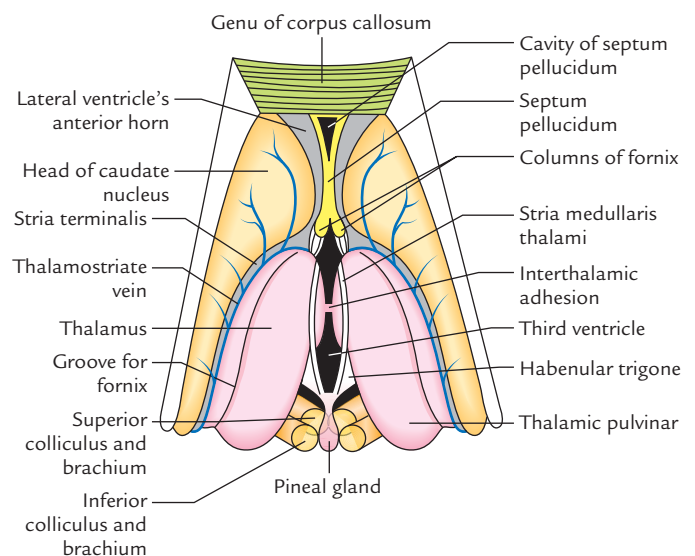


Fig. 26.1 The thalami and 3rd ventricle as seen from above, after removing the overlying tela choroidea.

Each thalamus is 3.5 cm in length and 1.5 cm in breadth.

The long axes of the thalami are set obliquely, running backward and laterally. The pointed anterior ends are nearer to the median plane, whereas the wider posterior ends are separated from each other by pineal body, superior colliculi, and habenular triangles. The thalami are usually attached across the median plane by a narrow **interthalamic connexus** of grey matter (also called **interthalamic adhesion**). Each thalamus forms most of the lateral wall of the 3rd ventricle and floor of the central part of the lateral ventricle.

Functionally, thalamus is considered as the great sensory gateway to the cerebral cortex. It receives impulses from the opposite half of the body and transmits most of them to the sensory area of the cerebral cortex (Brodmann areas 3, 2 and 1).

External Features

Each thalamus has **two ends** and **four surfaces**.

Ends

Anterior end

The anterior end is narrow and constitutes the **tubercle of thalamus**. It forms the posterior boundary of the interventricular foramen.

Posterior end

The posterior end is expanded and is known as **pulvinar**. It overhangs the medial and lateral geniculate bodies and superior colliculi with their brachia.

Surfaces

Superior surface

Its lateral part forms the floor of the central part of the lateral ventricle and its medial part is covered by the tela choroidea of the 3rd ventricle.

Inferior surface

Its anterior part is fused with the subthalamus while its posterior part is free, forming the inferior aspect of the pulvinar.

Medial surface

It forms the greater part of the lateral wall of the 3rd ventricle.

Lateral surface

It forms the medial boundary of the posterior limb of the internal capsule.

Parts of the Thalamus

The thalamus is traversed anteroposteriorly by a vertical sheet of white fibres, the **internal medullary lamina** which bifurcates anteriorly to assume a Y-shaped configuration. This Y-shaped internal medullary lamina divides the thalamus into three main parts: anterior, medial and lateral.

The **anterior part** includes the anterior tubercle and lies between the 'limbs' of the 'Y'. The **medial and lateral parts** lie on either side of the 'stem' of the 'Y'. Each of these parts consists of a number of nuclei.

Nuclei of the Thalamus (Fig. 26.2)

Nuclei in the anterior part

The nuclei in this part are collectively referred to as **anterior nucleus**.

Nuclei in the medial part

Nuclei in medial part consist of a large **medial dorsal nucleus** and a small **medial ventral nucleus**.

Nuclei in the lateral part

The lateral part is divided into dorsal and ventral parts.

The dorsal part is subdivided craniocaudally into three nuclei: (a) *lateral dorsal* (LD), (b) *lateral posterior* (LP), and (c) a large caudal nuclear mass, the *pulvinar* (P). These nuclei are termed **dorsal tier of nuclei**.

The ventral part is also subdivided craniocaudally into three nuclei: (a) *ventral anterior* (VA), (b) *ventral lateral* (VL) or *ventral intermediate* (VI), and (c) *ventral posterior* (VP). These nuclei are termed **ventral tier of nuclei**.

The *ventral posterior nucleus* (VP) is further subdivided into a lateral part, the *ventral posterolateral nucleus* (VPL) and a medial part, the *ventral posteromedial nucleus* (VPM).

The thalamic nuclei are summarized in Table 26.2.

Connections of the Thalamic Nuclei

The important connections of thalamic nuclei are as follows:

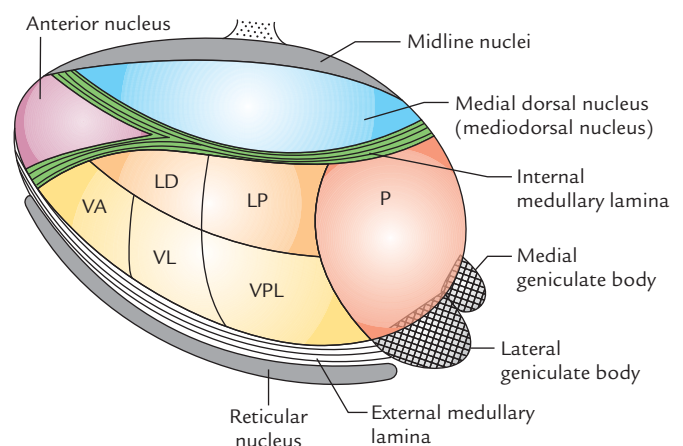


Fig. 26.2 Horizontal section of the thalamus (schematic) to show the location of various thalamic nuclei (LD = lateral dorsal nucleus, LP = lateral posterior nucleus, P = pulvinar, VA = ventral anterior nucleus, VL = ventral lateral nucleus, VPL = ventral posterolateral nucleus).

Table 26.2 Nuclei in different parts of the thalamus

Part	Nuclei
Anterior part	Anterior nucleus
Medial part	Medial dorsal nucleus, medial ventral nucleus
Lateral part	
• Dorsal tier nuclei	Lateral dorsal, lateral posterior, pulvinar
• Ventral tier nuclei	Ventral anterior (VA), ventral lateral (VL), ventral posterior: (a) ventral posterolateral (VPL), (b) ventral posteromedial (VPM)

From a clinical point of view the connections of ventral posterior nucleus are most important because its smaller medial portion, the **ventral posteromedial nucleus (VPM)** receives general sensory modalities from the head and face through *trigeminal lemniscus* and tastes sensations from taste buds through *solitariothalamic tract*; and its larger lateral portion, the **ventral posterolateral nucleus (VPL)** receives exteroceptive sensations (pain, touch, temperature) through *spinal lemniscus* and proprioceptive sensations (muscle and joint sense, vibration, two-point discrimination) through *medial lemniscus*, from the rest of the body except face and head.

All the sensations reaching the ventral posterior nucleus are carried to the primary sensory area of the cerebral cortex by fibres passing through the posterior limb of the internal capsule (**superior thalamic radiation**). The vascular lesions involve posterior limb of the internal capsule which sometimes cause impairment of all forms of sensibility on the opposite side of the body.

The integrity of **anterior nucleus** and its connections is necessary for attention and recent memory, therefore, a lesion involving it can lead to **loss of recent memory**.

Since the **medial dorsal nucleus** is associated with 'moods' and *emotional balance*, depending on the nature of the present sensory input and past experience, the mood may be that of well-being or malaise, or of euphoria or mild depression.

Functions of the Thalamus

The main functions of the thalamus are as follows:

1. It is a sensory integration and relay station of all the sensory pathways except for the olfactory pathway which is projected directly to the cerebral cortex without being relayed in the thalamus.
2. It is capable of recognition, though poorly, of pain, thermal and some tactile sensations at its own level.

Clinical correlation

Thalamic syndrome: It usually occurs subsequent to a vascular lesion of the thalamus, when the patient is recovering from a thalamic infarct.

Characteristic features

In thalamic syndrome, the threshold for pain, touch, and temperature is decreased on the opposite side of the body (*thalamic overreaction*), but when the threshold is reached, the sensations are exaggerated, perverted, and disagreeable. For example, the prick of a pin may be felt as a severe burning sensation and music that is ordinarily pleasing may be disagreeable. Sometimes even light touch may produce excruciating pain, which may become intractable and fail to respond to powerful analgesics (pain-relieving) drugs. There may be emotional instability with spontaneous laughing and crying.

METATHALAMUS

The metathalamus consists of medial and lateral geniculate bodies. These are small rounded elevations on the inferior aspect of the posterior part of the thalamus, lateral to each side of the midbrain. The medial and lateral geniculate bodies are relay stations for the auditory and visual pathways, respectively.

Medial Geniculate Body

Medial geniculate body is an oval elevation on the inferior aspect of the pulvinar of the thalamus, lateral to the superior colliculus. It is more prominent than the lateral geniculate body. The inferior brachium runs upward, laterally and forward from inferior colliculus of the midbrain to the medial geniculate body.

The inferior brachium conveys auditory impulses to the lateral geniculate body for onward transmission to the (primary auditory area of the) cerebral cortex.

Lateral Geniculate Body

Lateral geniculate body is a small ovoid prominence visible at the terminal end of the optic tract. It is situated on the inferior surface of the pulvinar, anterolateral to the medial geniculate body. It is smaller than the medial geniculate body and connected to the superior colliculus by the superior brachium.

The fibres of superior brachium are concerned with the production of visual reflexes such as turning of head and eyes toward the sudden flash of light and constriction of pupil when light falls or is thrown on the retina.

The lateral geniculate body receives retinal fibres of both the eyes (from temporal half of the retina of the same side and nasal half of the retina of the opposite side) through optic tract and gives rise to fibres of the *optic radiation* which convey visual impulses to the visual cortex of the occipital lobe.

EPITHALAMUS

Pineal Gland (Epiphysis Cerebri)

Pineal gland is a midline cone-shaped reddish grey structure (only 3 mm × 5 mm in size) occupying the vertical groove between the two superior colliculi below the splenium of corpus callosum. It projects back from the posterior wall of the 3rd ventricle, below the splenium of the corpus callosum. It has a stalk which divides into two laminae. The ventral (or inferior) lamina continues with the **posterior commissure** and the dorsal (or superior) lamina continues with the **habenular commissure**. The extension of the cavity of the 3rd ventricle between the two laminae is termed **pineal recess**.

Structure and Functions

The pineal gland is a **neuroendocrine gland** and consists of parenchymal cells, called *pinealocytes* and neuroglial cells. The pinealocytes secrete a hormone called **melatonin**. The calcium phosphates and carbonates are deposited in the gland with age in the form of multilaminar corpuscles called **corpora arenacea** or **brain sand**. They are often seen as tiny shadows in radiographs of the skull. A displaced calcified pineal gland indicates a space-occupying lesion within the brain.

Pineal secretions including melatonin have an **inhibitory effect** on other endocrine glands and gonads.

Unique Features

Pineal gland is the only part of the brain which has no neural tissue in it.

It is the only part of the brain which is supplied by a nerve (*nervus conarii*) which arises from outside the brain from superior cervical sympathetic ganglion in the neck.

SUBTHALAMUS

Subthalamus is described in detail on page 401.

HYPOTHALAMUS

The hypothalamus is a part of the diencephalon which lies below the thalamus. It forms the floor and the lower parts of lateral walls of the 3rd ventricle. Anatomically, hypothalamus is small in size weighing only 4 g and forming only 0.3% of the total brain mass, but physiologically there is hardly any activity in the body that is not influenced by it. Thus, the functional significance of hypothalamus is disproportionate to its size. The hypothalamus controls the autonomic and endocrine systems at the highest level, and is also involved in some affective or emotional behavior. *Being the principal autonomic centre of the brain, it has been regarded as the head ganglion of the autonomic nervous system by Sherrington.*

Boundaries of the Hypothalamus

The boundaries of the hypothalamus are as follows:

- Anteriorly:* Lamina terminalis (lamina terminalis extends from the optic chiasma to the anterior commissure).
- Posteriorly:* Subthalamus.
- Inferiorly:* Structures in the floor of the 3rd ventricle, *viz.* tuber cinereum, infundibulum and mammillary bodies. (These structures are actually the parts of hypothalamus itself.)
- Superiorly:* Thalamus.
- Laterally:* Internal capsule.
- Medially:* Cavity of the 3rd ventricle.

Subdivisions of the Hypothalamus

The hypothalamus is also subdivided anteroposteriorly into the following four regions:

1. **Preoptic region**—adjoining the lamina terminalis.
2. **Supraoptic region**—above the optic chiasma.
3. **Tuberal region**—includes the tuber cinereum, infundibulum and area around it.
4. **Mammillary region**—includes the mammillary bodies and area around it.

The *preoptic region* lies anterior to the hypothalamus between the optic chiasma and anterior commissure. Anatomically, it belongs to telencephalon but functionally it belongs to hypothalamus.

The *tuber cinereum* is the region bounded caudally by mammillary bodies and rostrally by optic chiasma. The *infundibulum* connects the posterior lobe of the hypophysis cerebri with the tuber cinereum. The tuber cinereum around the base of the infundibulum is raised to form a **median eminence**.

Hypothalamic Nuclei

The hypothalamus consists of numerous cell groups called **hypothalamic nuclei**. The nuclei present in different regions of the hypothalamus are listed in Table 26.3 and shown in Figure 26.3.

Table 26.3 Hypothalamic regions and nuclei in them

Region	Nucleus/nuclei
Preoptic region	• Preoptic nucleus
Supraoptic region	• Supraoptic nucleus • Anterior nucleus • Paraventricular nucleus
Tuberal region	• Arcuate (infundibular) nucleus • Ventromedial nucleus • Dorsomedial nucleus
Mammillary region	• Posterior nucleus • Mammillary nuclei

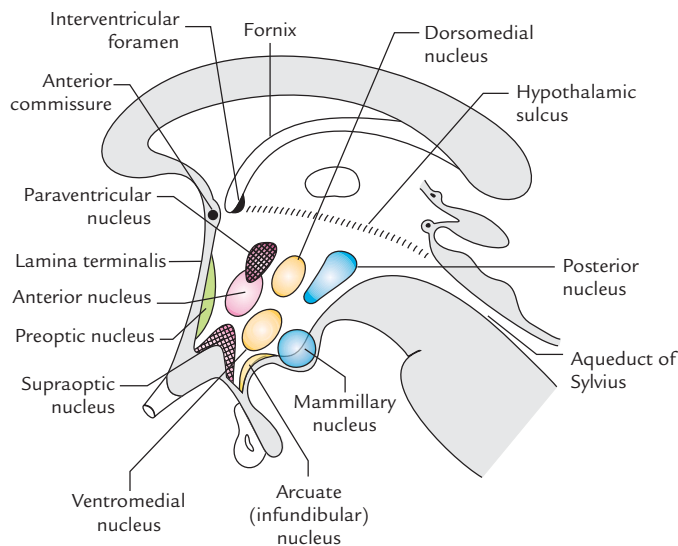


Fig. 26.3 Different nuclei of the hypothalamus as seen in the sagittal section.

Connections of the Hypothalamus

The connections of the hypothalamus are numerous and complex, therefore, only main connections are described below:

1. The axons of supraoptic and paraventricular nuclei run in the pituitary stalk to reach the posterior pituitary (neurohypophysis) and form the **hypothalamohypophyseal tract**. These axons transport the neurohormones—vasopressin and oxytocin—synthesized in supraoptic nucleus and paraventricular nucleus, respectively, to the posterior pituitary.
2. The axons of other cell groups, e.g., tuberal nuclei enter the region of median eminence to deliver their neurosecretory material to the **hypothalamohypophyseal portal system** of blood vessels to control the secretion of hormones from the anterior pituitary (adenohypophysis).
3. The long axons from thalamus pass through the brainstem and spinal cord to synapse with the preganglionic sympathetic cells in the lateral horns of the thoracic and upper two lumbar spinal segments and with the preganglionic parasympathetic cells in the lateral horns of the S2, S3, and S4 spinal segments to form hypothalamospinal tract.
4. **Mammillothalamic tract** connects the mammillary body to the anterior nucleus of the thalamus, which in turn projects to the cingulate gyrus.

Functions of the Hypothalamus

1. **Autonomic control:** The anterior part of the hypothalamus controls the parasympathetic nervous system while posterior part controls the sympathetic nervous system.

2. **Endocrine control:** Regulates the hormonal secretion of the anterior pituitary by forming the releasing factors or release inhibiting factors which in turn control the endocrine activities of the body.
3. **Neurosecretion:** Secretes neurohormones: oxytocin and vasopressin.
4. **Regulation of food and water intake:** The lateral part of the hypothalamus acts as **hunger centre** while the medial part acts as **satiety centre**. A **thirst centre** in the lateral part regulates water intake.
5. **Emotional expression:** *Plays an important role in the expression of autonomic emotions* like laughing, crying, sweating, or blushing mediated by the integrated activity of the ANS and somatic efferent system.
6. **Sexual behavior and reproduction:** Regulates the sexual behavior and reproduction by influencing the secretion of gonadotrophic hormones by the pituitary gland.
7. **Temperature regulation:** The anterior portion of the hypothalamus prevents the rise in body temperature while posterior portion promotes heat conservation and heat production.
8. **Biological clock:** Regulates the cyclic activities of the body (*circadian rhythm*), viz. sleeping and waking cycle, but itself affected by diurnal rhythms. The circadian rhythm for many body functions is about 24 hours.

THIRD VENTRICLE

The 3rd ventricle is the cavity of **diencephalon**. It is a midline slit-like cavity situated between two thalami and part of hypothalamus. It extends from the lamina terminalis anteriorly to the superior end of the cerebral aqueduct of the midbrain posteriorly. The cavity of the 3rd ventricle is lined by ciliated columnar epithelium, the **ependyma** and traversed horizontally by a mass of grey matter, the **interthalamic adhesion**, connecting the two thalami. The outline of the cavity is irregular due to the presence of several diverticula or recesses.

Anteriorly on each side, the 3rd ventricle communicates with the lateral ventricle through **interventricular foramen (of Monro)**, and posteriorly with the 4th ventricle through **cerebral aqueduct (of Sylvius)**.

BOUNDARIES

The 3rd ventricle has anterior wall, posterior wall, roof, floor and two lateral walls (Fig. 26.4).

Anterior wall is formed from above downward by:

- (a) anterior column of fornix,
- (b) anterior commissure, and
- (c) lamina terminalis.

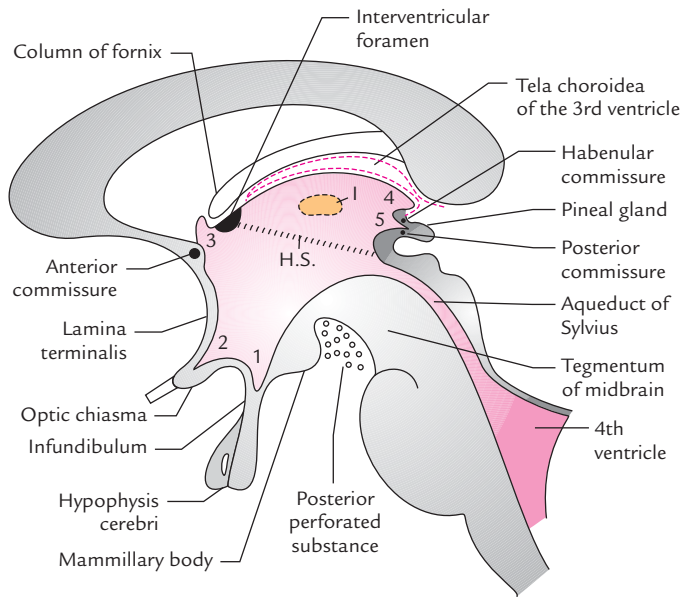


Fig. 26.4 Boundaries and recesses of the 3rd ventricle as seen in sagittal section (HS = hypothalamic sulcus, I = interthalamic adhesion, 1 = infundibular recess, 2 = optic recess, 3 = anterior recess, 4 = suprapineal recess, 5 = pineal recess).

Posterior wall: formed from above downward by:

- pineal gland,
- posterior commissure, and
- commencement of cerebral aqueduct

Roof: Formed by the ependyma that stretches across the upper limits of two thalami

Floor: Formed from before backward by:

- optic chiasma,
- tuber cinereum and infundibulum,
- mammillary bodies,
- posterior perforated substance, and
- tegmentum of the midbrain.

N.B. All structures of the floor belong to interpeduncular fossa except the optic chiasma and tegmentum of the midbrain.

Lateral wall: marked by a curved sulcus, the **hypothalamic sulcus** extending from the interventricular foramen to the upper end of the cerebral aqueduct. The sulcus divides the lateral wall into a larger upper part and a smaller lower part.

The larger **upper part of the lateral wall** is formed by the medial surface of the anterior two-third of the thalamus.

The smaller **lower part of the lateral wall** is formed by the hypothalamus and it is continuous with the ventricular floor.

N.B. The two lateral walls of the 3rd ventricle are normally closely approximated, hence in coronal section of the brain the cavity of the 3rd ventricle appears as a *median vertical slit* (Fig. 26.1).

RECESSES

The cavity of the 3rd ventricle extends into the surrounding structures as pocket-like protrusions called recesses (Fig. 26.4). These are as follows:

- Infundibular recess:** It is a deep tunnel-shaped recess extending downward through the tuber cinereum into the infundibulum, i.e., the stalk of the pituitary gland.
- Optic (or chiasmatic) recess:** It is an angular recess situated at the junction of the anterior wall and the floor of the ventricle just above the optic chiasma.
- Anterior recess (vulva of the ventricle):** It is a triangular recess which extends anteriorly in front of interventricular foramen and behind anterior commissure between the diverging anterior columns of the fornix.
- Suprapineal recess:** It is a fairly capacious blind diverticulum, which extends posteriorly above the stalk of the pineal gland and below the tela choroidea.
- Pineal recess:** It is a small diverticulum which extends posteriorly between the superior and inferior laminae of the stalk of the pineal gland.

CHOROID PLEXUS AND TELA CHOROIDEA

The tela choroidea in the roof of the 3rd ventricle is triangular in shape. The choroid plexus of the 3rd ventricle hangs downward from the tela choroidea as two longitudinal anteroposterior vascular fringes.

Clinical correlation

Obstruction of third ventricle: The 3rd ventricle being a narrow slit-like space is easily obstructed by local brain tumors or congenital defects. The obstruction results in excessive accumulation of CSF inside the brain, resulting in an *increased intracranial pressure* in adults and in *hydrocephalus* in children.

The site of obstruction can be found out by *ventriculography*.

Golden Facts to Remember

▶ Great sensory gateway to the cerebral cortex	Thalamus
▶ Largest somatosensory relay nucleus of the thalamus	Ventral posterior
▶ Thalamus is the final relay station of all the sensory modalities <i>except</i>	Olfaction
▶ Seat of soul	Pineal gland
▶ Biological clock in human body	Pineal gland
▶ All the parts of the brain consist of neural cells <i>except</i>	Pineal gland
▶ Only part of the brain which is supplied by a nerve arising from outside the brain	Pineal gland (it is supplied by nervus conarii which arises from superior cervical sympathetic ganglion in the neck)
▶ Head ganglion of the autonomic nervous system	Hypothalamus
▶ Anatomically, all the regions of hypothalamus belong to the diencephalon <i>except</i>	Preoptic region which belongs to telencephalon

Clinical Case Study



A 55-year-old patient was admitted in the neurology ward with complaints of loss of sensation on the left side of his body. After a few days the patient started improving and there was an evidence of return of sensations on the affected side. Both, the treating doctors and relatives were very happy. Few days later he suddenly started complaining of agonizing pain in his left arm and leg. The pain would start spontaneously or may be initiated by the light touch of even bed sheet or by little exposure to the cold. The pain failed to respond even to powerful analgesics. He was diagnosed as a case of *thalamic syndrome*.

Questions

1. What is thalamus? What is its main function?
2. Enumerate the ventral tier of the thalamic nuclei.
3. Name the nucleus of thalamus concerned with the general sensations of pain, touch, and temperature from opposite half of the body.
4. What is thalamic syndrome?

Answers

1. The thalamus is a large ovoid mass of grey matter lying above the brainstem from which it is separated by a small amount of neutral tissue—the *subthalamus*. The main function of thalamus is that it is a great sensory relay station in which all the sensory pathways relay *except* olfactory.
2. The ventral tier of thalamic nuclei include ventral anterior (VA), ventral lateral (VL) or ventral intermediate (VI), and ventral posterior (VP). The ventral posterior nucleus is further divided into ventral posterolateral (VPL) and ventral posteromedial (VPM) nuclei.
3. Ventral posterolateral (VPL) nucleus.
4. The thalamic syndrome is thalamic overreaction to the sensations of pain, touch, and temperature. It occurs when the patient is recovering from thalamic infarct following a vascular lesion of the thalamus.

Cerebrum

The cerebrum (Latin = *brain*) is the largest part of the brain that fills most of the cranial cavity above the floors of anterior and middle cranial fossae and above the tentorium cerebelli of posterior cranial fossa.

The cerebrum is a heavily convoluted bilobed structure.

A deep median cleft, the **longitudinal cerebral fissure**, incompletely separates the cerebrum into two lateral halves, called **cerebral hemispheres**. The cleft lodges a sickle-shaped fold of the dura mater, the *falx cerebri* and the anterior cerebral vessels. Both in front and behind, the cleft is complete, but in the central part it extends downwards up to the *corpus callosum* which is a large mass of white fibres joining the two cerebral hemispheres across the median plane.

The left hemisphere in right handed individuals is slightly larger than the right and usually termed **dominant hemisphere**.

Each cerebral hemisphere consists of: (a) an outer layer of grey matter called **cerebral cortex**, (b) an inner mass of **white matter**, (c) large masses of grey matter embedded in the basal part of the white matter called **basal ganglia/basal nuclei**, and (d) a cavity within it called **lateral ventricle**.

EXTERNAL FEATURES OF THE CEREBRAL HEMISPHERE

The external features of the cerebral hemisphere include: poles, surfaces, borders, sulci, and gyri.

POLES

Each cerebral hemisphere presents the following three poles:

1. The **frontal pole**, the anterior end of the hemisphere is more rounded than the occipital pole.
2. The **occipital pole**, the posterior end of the hemisphere is more pointed than the frontal pole.
3. The **temporal pole** between frontal and temporal poles points forwards. It fits into the anterior part of the middle cranial fossa.

SURFACES

Each cerebral hemisphere has the following three surfaces:

1. The **superolateral surface** is most convex and most extensive. It faces upwards and laterally and conforms to the corresponding half of the cranial vault.
2. The **medial surface** is flat and vertical. It presents a thick C-shaped cut surface of the *corpus callosum*.
3. The **inferior surface** is irregular to adopt the floors of anterior and middle cranial fossae. It is divided into two parts by a deep horizontal groove or sulcus, the **stem of lateral sulcus**, viz. (a) a small anterior part, the *orbital surface*, and (b) a large posterior part, the *tentorial surface*.

BORDERS

Each cerebral hemisphere presents the following six borders:

1. The **superomedial border** separates the superolateral surface from the medial surface.
2. The **superciliary border** is at the junction of superolateral and orbital surfaces.
3. The **inferolateral border** separates the superolateral surface from the tentorial surface.
4. The **medial orbital border** separates the medial surface from the orbital surface.
5. The **inferomedial/hippocampal border** surrounds the cerebral peduncle.
6. The **medial occipital border** separates the medial surface from the tentorial surface.

SULCI AND GYRI

The cerebral cortex is thrown into a complicated series of tortuous folds, called **gyri or convolutions**. The grooves between the gyri are termed as sulci. The convolutions greatly increase the surface area of the cerebral cortex. Most of the gyri and sulci are named but only important ones are described here.

Each gyrus consists of a central core of white matter covered by an outer layer of grey matter.

Main Cerebral Sulci

Main cerebral sulci are fairly constant in position and shape and include lateral, central, calcarine and parieto-occipital sulci.

Lateral sulcus (of Sylvius) is the most conspicuous of all the cerebral sulci and has a **stem** and **three rami**. The stem of the sulcus begins as a deep cleft on the inferior surface of the cerebral hemisphere at the anterior perforated substance and extends laterally to reach the superolateral surface. On reaching the superolateral surface it divides into three rami: (a) *anterior horizontal*, (b) *anterior ascending*, and (c) *posterior*.

N.B. The three rami of lateral sulcus diverge from each other at a point called *Sylvian point*.

Central sulcus (of Rolando) begins by cutting the superomedial border of the hemisphere about 1 cm behind the midpoint between the frontal and occipital poles, runs sinuously downwards and forwards, and ends just above the posterior ramus of the lateral sulcus. Its upper end usually extends into the medial surface.

Calcarine sulcus is present on the medial surface of the cerebral hemisphere. It begins as a deep fissure, a little below the posterior end of the corpus callosum, the splenium, and follows an arched course with a convexity upwards to the occipital pole and may extend slightly onto the superolateral surface.

Parieto-occipital sulcus is present on the medial surface of the hemisphere. It begins at the midpoint of the calcarine sulcus and courses upwards and slightly backwards to cut the superomedial border of the hemisphere about 5 cm in front of the occipital pole, and may extend slightly onto the superolateral surface.

SULCI AND GYRI ON SUPEROLATERAL SURFACE

In the frontal lobe

1. The **prefrontal sulcus**, often broken into two or three parts, runs downwards and forwards parallel and little anterior to the central sulcus. The area between the central and precentral sulci is called **precentral gyrus**.
2. Anterior to the precentral sulcus there are two sulci called **superior** and **inferior frontal sulci** which run horizontally. These sulci divide the region of frontal lobe in front of precentral sulcus into **superior**, **middle**, and **inferior frontal gyri**.
3. The **anterior** and **ascending rami of lateral sulcus** divide the inferior frontal gyrus into three parts. The part below the anterior ramus is called *pars orbitalis*, the part

between the anterior and ascending rami is *pars triangularis*, and the part posterior to the ascending ramus, the *pars opercularis*.

In the parietal lobe

1. The **postcentral sulcus** runs downwards and forwards, a little behind and parallel to the central sulcus. The area between these two sulci is called *postcentral gyrus*.
2. The rest of the parietal lobe is divided into **superior** and **inferior parietal lobules** by an *intraparietal sulcus*.

In the temporal lobe

There are two sulci in this lobe that run parallel to the posterior ramus of the lateral sulcus. These are termed **superior** and **inferior temporal sulci**, and divide the temporal lobe into **superior**, **middle**, and **inferior temporal gyri**.

The superior surface of superior temporal gyrus presents *two transverse temporal gyri*. The anterior transverse temporal gyrus also called **Heschl's gyrus** forms the primary auditory area of the cortex.

In the occipital lobe

The occipital lobe possesses rather three short sulci, lateral, and transverse occipital sulci, and lunate sulcus.

SULCI AND GYRI ON MEDIAL SURFACE

These are as follows:

1. **Cingulate sulcus:** It is the most prominent sulcus which follows a curved course about 1 cm above and parallel to the upper convex margin of corpus callosum. Anteriorly it ends below the genu of corpus callosum, posteriorly it turns upwards to reach the superomedial border of the hemisphere, a little behind the upper end of the central sulcus.
 - The area between the cingulate sulcus and corpus callosum is termed **cingulate gyrus**.
2. **Callosal sulcus:** It separates the cingulate gyrus from corpus callosum.
 - (a) The anterior part of medial surface between the cingulate sulcus and the superomedial border of the hemisphere is divided by a short offshoot sulcus ascending from the cingulate sulcus above the middle of the trunk of corpus callosum into two parts:
 - a small part around the upper part of the central sulcus, the *paracentral lobule*, and
 - a large medial part the *medial frontal gyrus*.
 - (b) The posterior part of medial surface behind the paracentral lobule has two main sulci: the calcarine sulcus, and the parieto-occipital.
 - *Calcarine sulcus* (already described). A small region between the splenium and calcarine sulcus is termed **isthmus**.
 - *Parieto-occipital sulcus* (already described).

- The triangular area between the posterior part of the calcarine sulcus (also called **postcalcarine sulcus**) and the parieto-occipital sulcus is called *cuneus*.
 - The quadrangular area between the parieto-occipital sulcus and paracentral lobule is termed *precuneus*.
3. A small sulcus a little above and parallel to the splenium is called **suprasplenic sulcus**. It separates the precuneus from the cingulate gyrus.

SULCI AND GYRI ON INFERIOR SURFACE

On the orbital part of inferior surface (orbital surface)

1. **Olfactory sulcus:** It is a straight sulcus which runs anteroposteriorly close to the medial border of the orbital surface. It is called olfactory sulcus because it lodges the olfactory bulb and tract.
The area medial to this sulcus is called **gyrus rectus**.
2. **Orbital sulcus:** It is an irregular H-shaped sulcus and divides the rest of the orbital surface into **anterior, posterior, medial, and lateral orbital gyri**.

On the tentorial part of inferior surface (tentorial surface)

1. The tentorial surface is marked by two major sulci that run anteroposteriorly. The medial one is called **collateral sulcus** and the lateral one, the **occipitotemporal sulcus**. The latter is continuous around the inferolateral margin with the inferior temporal gyrus.
2. Posteriorly the collateral sulcus is parallel to the calcarine sulcus and here the area between these two sulci is termed *lingual gyrus*. Anteriorly the lingual gyrus is continuous with the **parahippocampal gyrus**. Anterior end of parahippocampal gyrus hooks sharply backwards and is limited laterally by a short *rhinal sulcus*. This hook-like anterior end of parahippocampal gyrus is called **uncus**.

Posteriorly the parahippocampal gyrus is continuous with the cingulate gyrus through the isthmus.

The area between the *occipitotemporal sulcus* laterally and the *collateral* and *rhinal* sulci medially is known as **medial occipitotemporal gyrus**. The area lateral to the occipitotemporal sulcus is termed **lateral occipitotemporal gyrus**. This gyrus is continued around the inferolateral margin of the hemisphere with the inferior temporal gyrus.

LOBES OF THE CEREBRAL HEMISPHERE

The superolateral surface of each cerebral hemisphere is arbitrarily divided into four lobes, *viz.* frontal, parietal, temporal, and occipital with the help of: (a) three main sulci: central, lateral and parieto-occipital, and (b) two imaginary lines (Fig. 23.2).

The *first imaginary line* is a vertical line joining the parieto-occipital sulcus to the preoccipital notch, and the second *imaginary line* is a backward continuation of the horizontal part of the posterior ramus of the lateral sulcus till it joins the first line.

The **frontal lobe** lies anterior to the central sulcus and above the posterior ramus of the lateral sulcus.

The **parietal lobe** lies behind the central sulcus and in front of the upper part of the first imaginary line. Below it is bounded by the posterior ramus of the lateral sulcus and the second imaginary line.

The **temporal lobe** lies below the posterior ramus of lateral sulcus and second imaginary line. It is separated from the **occipital lobe** by the lower part of the first imaginary line.

The **occipital lobe** lies behind the vertical line joining the parieto-occipital sulcus and preoccipital notch.

Insula/Island of Reil (Also Called Central Lobe)

It is customary to consider the insula separately from the four main lobes (*vide supra*) of the cerebral hemisphere.

The insula is the submerged (hidden) portion of the cerebral cortex in the floor of the lateral sulcus. It has been submerged from the surface during development of brain due to the overgrowth of the surrounding cortical areas and can be seen only when the lips of the lateral sulcus are widely pulled apart. It is triangular in shape and surrounded all around by a sulcus, the **circular sulcus**, except anteroinferiorly at its apex called **limen insulae** which is continued with the anterior perforated substance.

The insula is divided into two regions, anterior and posterior by a **central sulcus**. The anterior region presents 3 or 4 short gyri called **gyri brevia** and the posterior region presents 1 or 2 long gyri called **gyri longa**.

The insula is hidden from the surface view by the overgrown cortical areas of frontal, parietal, and temporal lobes. These areas are termed **frontal, frontoparietal, and temporal opercula** (operculum = lid). The superior surface of the temporal operculum presents the **anterior and posterior transverse temporal gyri**.

CEREBRAL CORTEX

The cerebral cortex is the surface layer of grey matter covering the cerebral hemisphere. The cortex represents the highest degree of evolutionary development of the human brain both in its relative size to other parts of the brain and its range of functions.

The main functions of the cerebral cortex include:

1. **Mental activities** involved in memory, learning, speech, language, intelligence, and creative thinking.

2. **Sensory perception**, such as perception of pain, touch, temperature, sight, hearing, taste, smell, etc.
3. **Initiation of motor commands** to control activities of skeletal muscles.

N.B. In general, each cerebral hemisphere controls the opposite half of the body, i.e., it sends motor commands to and receives sensory information from the contralateral half of the body.

FUNCTIONAL AREAS

The surface of cerebral cortex was demarcated by Brodmann (1909) into 47 areas according to their function.

Types of cortical areas: according to classical teaching, the cerebral cortex possesses three types of functional areas:

1. **Motor areas:** primarily concerned with the motor functions.
2. **Sensory areas:** primarily concerned with the sensory functions.
3. **Association areas:** not concerned with primary motor or sensory functions but have more important associative, integrative, and cognitive functions.

N.B. Association areas occupy over 75% of the total surface area of the cerebral cortex in human beings.

Functional Areas in the Frontal Lobe (Figs 27.1 and 27.2)

Primary Motor Area (Area 4 of Brodmann)

Primary motor area is located in the precentral gyrus on the superolateral surface and extends to the anterior part of paracentral lobule on the medial surface of the cerebral hemisphere. *About 40% pyramidal (corticospinal and corticonuclear) fibres arise from this area.*

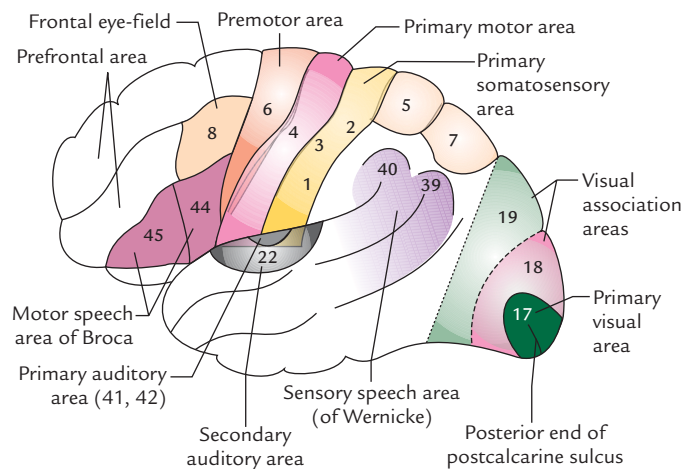


Fig. 27.1 Functional cortical areas on the superolateral surface of the cerebral hemisphere.

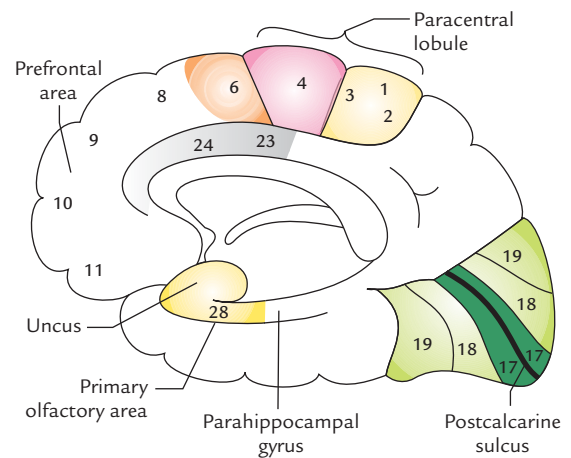


Fig. 27.2 Functional cortical areas on the inferomedial surface of the cerebral hemisphere.

Specific regions within the area are responsible for movements in the specific parts of the body. Only movements are represented in this area and not the muscles.

In the motor area of the cerebrum, the human body is represented upside down, i.e. uppermost part controls the feet and the lowermost part controls the head, neck, face, and fingers.

Clinical correlation

Lesions of primary motor area in one hemisphere produce spastic paralysis of the extremities of the opposite half of the body (*hemiplegia*). The masticatory, laryngeal, pharyngeal, upper facial, and extraocular muscles are spared for being represented bilaterally.

Premotor Area (Area 6 of Brodmann)

Premotor area is located anterior to the primary motor area in the posterior parts of superior, middle, and inferior frontal gyri and extends on to the medial surface of the hemisphere.

The premotor area is responsible for successful performance of the voluntary motor activities initiated in the primary motor area.

Frontal Eye Field (Area 8 of Brodmann)

The frontal eye field is located in the posterior part of the middle frontal gyrus just anterior to the facial area of the precentral gyrus. It is responsible for **conjugate movements of the eyes** to the opposite side.

Motor Speech Area of Broca (Areas 44 and 45 of Brodmann)

The motor speech area is usually located in the pars triangularis (area 45) and pars opercularis (area 44) of inferior frontal gyrus of frontal lobe of left hemisphere (the *dominant hemisphere* in right handed and most of the left handed individuals).

Clinical correlation

Lesions of motor speech area of Broca result in loss of ability to produce proper speech, called *expressive aphasia* (also called *motor aphasia*). The patients face difficulty in finding the right words to express what they wish to say, but they can understand what others say.

Primary Sensory Area (Areas 3, 1, and 2 of Brodmann)

Primary sensory area is located in the postcentral gyrus and extends into the posterior part of the paracentral lobule on the medial surface of the hemisphere. The opposite half of the body is represented upside down exactly in same fashion as in the primary motor area. *The primary sensory area is concerned with the perception of exteroceptive (pain, touch, and temperature) and proprioceptive (vibration, muscle, and joint sense) sensations from the opposite half of the body.*

Clinical correlation

Lesions of primary sensory area lead to loss of appreciation of exteroceptive and proprioceptive sensations from the opposite half of the body.

Sensory Association Area (Fig. 27.1)

Sensory association area occupies the superior parietal lobule corresponding to the Areas 5 and 7 of Brodmann. *It is concerned with the perception of shape, size, roughness, and texture of the objects.* Thus it enables the individual to recognize the objects placed in his/her hand without seeing. Such ability is referred to as **stereognosis**.

Sensory Speech Area of Wernicke (Fig. 27.1)

Sensory speech area is located in the left dominant hemisphere occupying the posterior part of the superior temporal gyrus of temporal lobe and angular (Area 39) and supramarginal (Area 40) gyri of the inferior parietal lobule.

The Wernicke's area is concerned with the understanding of speech, i.e. interpretation of language through visual and auditory input.

Clinical correlation

Lesions of Wernicke's area in the dominant hemisphere produce loss of ability to understand the spoken and written speech. This condition is called *receptive aphasia*.

N.B. Recently, it has been found that traditional motor and sensory areas are not exclusively motor or sensory but sensorimotor in nature. The motor areas are predominantly motor while the sensory areas are predominantly sensory, and they are abbreviated as **M_s** and **S_m** respectively according to *relative* significance of their functional

attributes. Thus primary somatomotor area is abbreviated as M₁, supplementary motor area as M₁^{II}, first somatosensory area as S₁ and second somatosensory area as S₁^{II}.

Functional Areas in the Temporal Lobe

Primary Auditory Area (Areas 41 and 42)

Primary auditory area is located on the superior surface of the superior temporal gyrus occupying the anterior transverse temporal gyrus (**Heschl's gyrus**) and extends slightly to the adjacent part of the superior temporal gyrus (Fig. 27.1).

Secondary Auditory Area/Auditory Association Area (Brodmann's Area 22)

Secondary auditory area is situated on the lateral surface of the superior temporal gyrus, slightly posterior to the primary auditory area which it surrounds (Fig. 27.1).

The primary and secondary auditory areas receive fibres from the medial geniculate body via the auditory radiation. The cochleae are bilaterally represented. Therefore, a lesion in one cortex does not cause unilateral deafness.

Functional Areas in the Occipital Lobe

Primary Visual Area/Striate Area (Area 17)

Primary visual area is situated mainly on the medial surface of the occipital lobe in the walls and floor of the posterior part of the calcarine sulcus (**postcalcarine sulcus**) and extends around the occipital pole onto the lateral surface of the occipital lobe as far as the **lunate sulcus** (Figs 27.1 and 27.2).

The most marked structural feature of the visual cortex is the presence of **white line/visual stria** (of Gennari), hence the name—**striate area**.

Secondary Visual Area (Area 18 and 19)

The cortex adjacent to the primary visual area on the medial and lateral surfaces of the occipital lobe is occupied by secondary visual area (visual association area).

The visual cortex receives afferent fibres from lateral geniculate body via optic radiations. The visual cortex receives fibres from temporal half of the ipsilateral retina and the nasal half of the contralateral retina, i.e. it registers impulses from opposite field of vision. Thus right half of the field of vision is represented in the visual cortex of the left cerebral hemisphere and vice versa. It is also important to note that impulses from the superior retinal quadrants (inferior field of vision) pass to the superior wall of the calcarine sulcus, while the inferior retinal quadrants (superior field of vision) pass to the inferior wall of the calcarine sulcus.

The **macular area** which is the central area of retina and responsible for maximum visual acuity (*keenest vision*) has extensive cortical representation, occupying approximately posterior one-third of the visual cortex.

WHITE MATTER OF THE CEREBRUM

The white matter of the cerebrum is a compact mass of a vast number of myelinated nerve fibres.

TYPES OF FIBRES IN WHITE MATTER

They are classified into the following three types, on the basis of the types of connections they provide:

1. Association fibres.
2. Commissural fibres.
3. Projection fibres.

Association Fibres

The association fibres interconnect the different regions of the cerebral cortex in the same hemisphere (*intra-hemispheric fibres*). These are of the following two types:

1. **Short association fibres**, which interconnect the adjacent gyri by hooking around the sulcus, hence they are also called *arcuate fibres*.
2. **Long association fibres**, which travel for long distances and interconnect the widely separated gyri, *viz.* gyri of different lobes.

Commissural Fibres

The commissural fibres interconnect the identical cortical areas of the two cerebral hemispheres (*inter-hemispheric fibres*). The bundles of such fibres are termed commissures.

The important commissures of the brain are as follows:

1. Corpus callosum.
2. Anterior commissure.
3. Posterior commissure.
4. Hippocampal commissure.
5. Habenular commissure.

Corpus callosum (Fig. 27.3): The corpus callosum is the largest commissure of the brain. It consists of about 100 million fibres.

External features of corpus callosum: Corpus callosum forms a massive arched interhemispheric bridge in the floor of the median longitudinal cerebral fissure connecting the medial surfaces of the two cerebral hemispheres.

In sagittal section of cerebrum it is seen as C-shaped mass of white fibres on the medial surface of the hemisphere forming the roof of the lateral ventricle (Fig. 27.3).

The concave inferior aspect of corpus callosum is attached with the convex superior aspect of the fornix by *septum pellucidum*.

Parts of the corpus callosum: The corpus callosum is divided from before backwards into the following four parts (Fig. 27.3A).

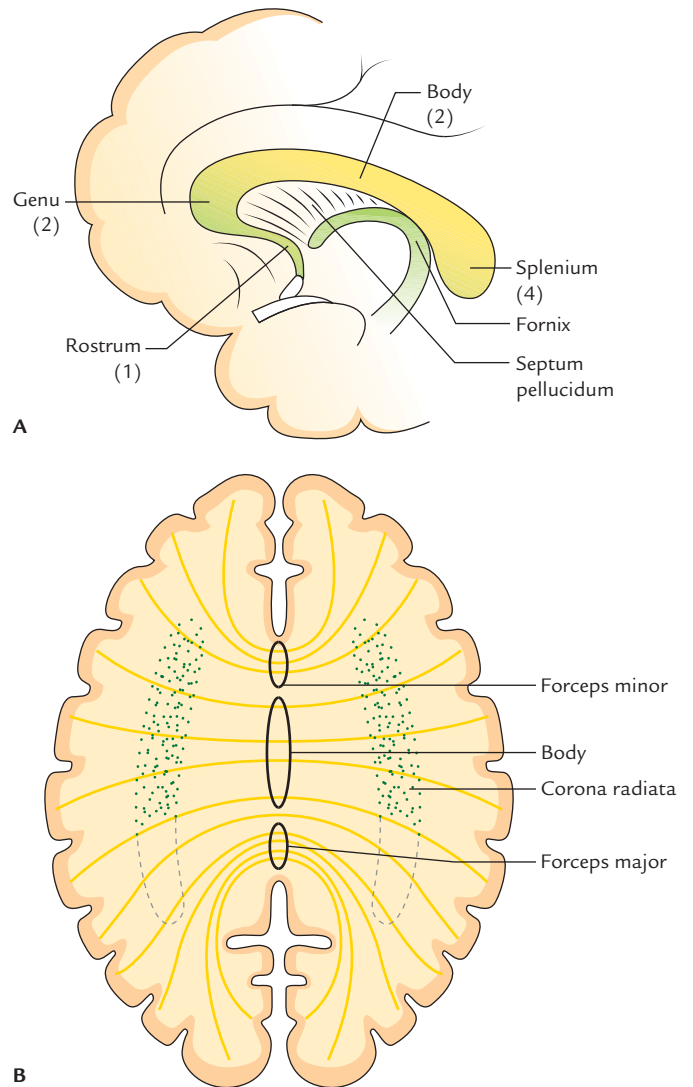


Fig. 27.3 Corpus callosum: A, parts of corpus callosum as seen in median sagittal section of the cerebrum; B, fibres of corpus callosum as seen in transverse section of cerebrum through corpus callosum.

1. **Genu:** It is thick curved anterior extremity of corpus callosum which lies 4 cm behind the frontal pole. The fibres of genu sweep (curve) forwards on either side into the anterior parts of the frontal lobes, forming a fork-like structure, the **forceps minor** (Fig. 27.3B).
2. **Rostrum:** The genu extends downwards and backwards as a thin prolongation to join the lamina terminalis forming, rostrum of corpus callosum.
3. **Trunk:** The trunk is the main (middle) part of the corpus callosum between its thick anterior (genu) and massive posterior (splenium) extremities.
4. **Splenium:** The splenium is the massive posterior extremity of the corpus callosum, lying 6 cm in front of the occipital pole. The fibres of the splenium connect

the parietal (posterior parts), temporal, and occipital lobes of the two hemispheres. The fibres connecting the occipital lobes sweep backwards on either side above the calcarine sulcus forming a large fork-like structure, the *forceps major* (Fig. 27.3B).

Functions of the corpus callosum: The corpus callosum is largely responsible for **interhemispheric transfer of information** which is essential for bilateral responses and learning processes.

Anterior commissure: The anterior commissure is a small round bundle of white fibres which crosses the midline in the upper part of the lamina terminalis, immediately in front of the anterior column of the fornix and interventricular foramen.

Anterior commissure consists of two components:

1. A large **posterior neocortical component**, which interconnects the lower and anterior parts of the temporal lobes.
2. A smaller **anterior paleocortical component**, which interconnects the olfactory regions of the two hemispheres.

Posterior commissure: The posterior commissure is a slender bundle of white fibres which crosses the midline through the inferior lamina of the stalk of pineal gland.

Hippocampal commissure (commissure of fornix): Hippocampal commissure interconnects the crura of fornix of the two sides and thus forms the **hippocampal formation**.

Habenular commissure: The habenular commissure is a slender bundle of white fibres which crosses the midline through the superior lamina of the stalk of pineal gland.

Projection Fibres

The projection fibres connect the cerebral cortex to the subcortical centres (such as the corpus striatum, thalamus, brainstem) and spinal cord. These fibres are of the following two types:

1. **Corticofugal fibres**, which go away from the cortex (cortical efferents) to centres in the other parts of the CNS.
2. **Corticopetal fibres**, which come to the cerebral cortex from the other centres in the CNS.

The projection fibres of neocortex constitute the *corona radiata* and *internal capsule* while those of allocortex (i.e., archicortex and paleocortex) constitute the *fimbria* and *fornix*.

The most important bundles of projection fibres are: **internal capsule and fornix**.

Internal Capsule (Fig. 27.4)

The internal capsule is a compact bundle of projection fibres between the thalamus and caudate nucleus medially and the lentiform nucleus laterally. It consists of ascending and

descending nerve fibres which connect the cerebral cortex to the brainstem and spinal cord.

The afferent (sensory) fibres pass up from thalamus to the cerebral cortex and efferent (motor) fibres pass down from the cerebral cortex to the cerebral peduncle of the midbrain.

These sensory and motor fibres of internal capsule are mainly responsible for the sensory and motor innervation of the opposite half of the body.

N.B. The sensory fibres radiate from thalamus in different directions to reach the widespread areas of the cerebral cortex and constitute the *thalamic radiation*.

Clinical correlation

Because of high concentration of motor and sensory nerve fibres within the internal capsule, even a small lesion in internal capsule may produce widespread paralytic effects and sensory loss in the opposite half of the body.

Shape and parts of internal capsule

In a horizontal section of the cerebral hemisphere, the internal capsule appears as a V-shaped compact bundle of white fibres with its concavity directed laterally (Fig. 27.4).

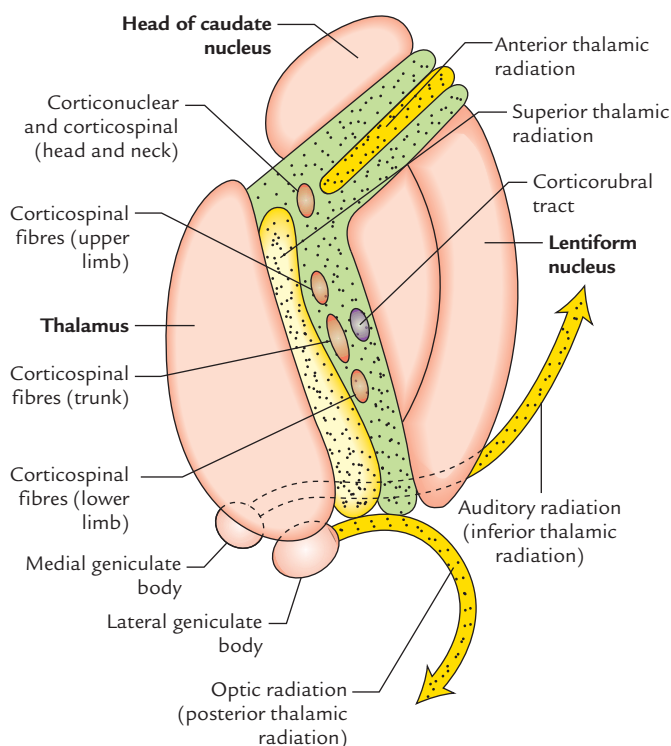


Fig. 27.4 Main components of internal capsule and their constituent fibres (yellow = thalamocortical, green = corticopontine fibres, red = corticonuclear and corticospinal fibres, violet = corticorubral fibres).

The internal capsule is divided into the following five parts (Fig. 27.4):

1. **Anterior limb**—between the head of caudate nucleus and the anterior part of the lentiform nucleus.
2. **Posterior limb**—between the thalamus and the posterior part of the lentiform nucleus.
3. **Genu**—the bend between the anterior and posterior limbs with concavity of the bend facing laterally.
4. **Retrolentiform part**—behind the lentiform nucleus.
5. **Sublentiform part**—below the lentiform nucleus.

Constituent fibres of internal capsule (Fig. 27.4)

The constituent motor and sensory fibres in different parts of the internal capsule are summarized in Table 27.1 and shown in Figure 27.4.

Table 27.1 Constituent motor and sensory fibres in different parts of the internal capsule

Part	Motor fibres	Sensory fibres
Anterior limb	Corticopontine fibres	Anterior thalamic radiation
Genu	Corticopontine fibres Corticonuclear and corticospinal fibres for head and neck	Superior thalamic radiation (anterior part only)
Posterior limb	Corticopontine fibres Corticospinal (pyramidal) fibres for upper limb, trunk and lower limb Corticorubral (extrapyramidal) fibres	Superior thalamic radiation
Retrolentiform part	Corticopontine fibres	Posterior thalamic radiation (optic radiation)
Sublentiform part	Corticopontine fibres	Inferior thalamic radiation (auditory radiation)

Arterial supply of internal capsule

The different parts of the internal capsule are supplied by the following arteries:

1. **Anterior limb:** by medial striate branches of the anterior cerebral artery and lateral striate branches of the middle cerebral artery.
2. **Genu:** by recurrent artery of the Heubner or direct branches from internal carotid artery.
3. **Posterior limb:** by lateral striate branches of the middle cerebral artery and branches of the anterior choroidal artery.

Clinical correlation

Lesions of internal capsule: The internal capsule is frequently involved in the cerebrovascular disorders.

The most common cause of arterial hemorrhage is atheromatous degeneration of an artery in individuals suffering from high blood pressure.

The hemorrhage commonly occurs due to rupture of the Charcot's artery, the larger lateral striate branch of the middle cerebral artery (also called *Charcot's artery of cerebral hemorrhage*), which supplies the posterior limb of the internal capsule.

Damage to the internal capsule caused by hemorrhage or infarction, leads to loss of sensations and spastic paralysis of the opposite half of the body (contralateral hemiplegia).

N.B. Rupture of Charcot's artery of cerebral hemorrhage is the most common cause of the hemiplegia.

Fornix

The fornix is described in detail in Chapter 28.

LATERAL VENTRICLES

There are two lateral ventricles, one in each cerebral hemisphere. Each lateral ventricle is a C-shaped cavity lined with ependyma within each cerebral hemisphere.

Each lateral ventricle communicates with the 3rd ventricle through the interventricular foramen (of Monro).

PARTS OF THE LATERAL VENTRICLE (Fig. 27.5)

For descriptive purposes, each lateral ventricle is divided into four parts, *viz.*

1. Central part.
2. Anterior horn.
3. Posterior horn.
4. Inferior horn.

Central part: The central part or body lies mostly within the parietal lobe and extends from interventricular foramen in front to the splenium of the corpus callosum behind. In coronal section, it is triangular and presents floor, roof, and medial wall.

The floor from lateral to medial side is formed by: body of caudate nucleus, stria terminalis, thalamostriate vein, and thalamus. The roof is formed by the body of the corpus callosum and the medial wall is formed by septum pellucidum.

Anterior horn: It is the anterior extension of the central part into the frontal lobe and lies in front of interventricular foramen and behind the posterior surface of the genu of corpus callosum.

It is triangular in coronal section and presents roof, floor, and anterior, medial, and lateral walls.

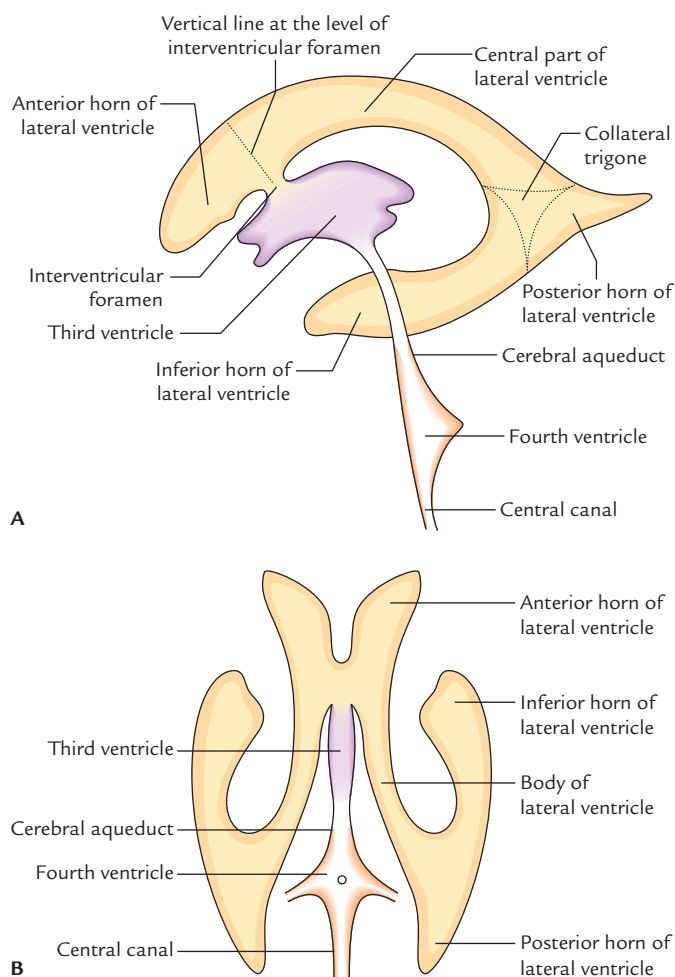


Fig. 27.5 Ventricular system of the brain showing different parts of lateral ventricle: **A**, lateral view; **B**, superior view.

The roof is formed by anterior part of the body of corpus callosum, the floor by rostrum of corpus callosum, anterior wall by genu of corpus callosum. The medial and lateral walls

are formed by septum pellucidum and head of caudate nucleus, respectively.

Posterior horn: It is the backward extension of the central part into the occipital pole.

In coronal section, the posterior horn presents: medial wall, lateral wall, roof, and floor.

The medial wall consists of two convexities, the upper one—the *bulb of posterior horn* is formed by the forceps major of corpus callosum and the lower one—the *calcar avis* is formed by the calcarine sulcus. The roof, lateral wall, and floor are formed by the tapetum of the corpus callosum.

Inferior horn: It is the largest horn and is considered as direct continuation of the main ventricular cavity into the temporal lobe.

In coronal section, it appears as a transverse slit and presents the roof and the floor. The floor is formed medially by the hippocampus and laterally by collateral eminence. The lateral part of the roof is formed by tapetum of the corpus callosum and medial part by the tail of caudate nucleus and stria terminalis.

N.B. The area where inferior and posterior horns diverge is called *collateral trigone*.

CHOROID PLEXUS AND CHOROID FISSURE

On the medial aspect of the cerebral hemisphere, along the C-shaped line between the diencephalon and hemisphere, the medial wall of the central part and inferior horn of the lateral ventricle is made up of only ependyma. The pia mater covering the ependyma along this C-shaped line is invaginated by the fringe-like tuft of capillaries of blood vessels into the central part and inferior horn to form the **choroid plexus of the lateral ventricle**. The line of invagination of the choroid plexus into the lateral ventricle is called **choroid fissure**.

Golden Facts to Remember

▶ Largest part of the brain	Cerebrum
▶ Most conspicuous cerebral sulcus	Lateral sulcus (of Sylvius)
▶ Dominant cerebral hemisphere (in right handed people)	Left cerebral hemisphere
▶ Largest bundle of commissural fibres of the brain	Corpus callosum
▶ Most important and largest bundle of projection fibres of the brain	Internal capsule
▶ Most common cause of hemiplegia	Infarction of the posterior limb of the internal capsule
▶ Largest part of the lateral ventricle	Central part or body
▶ Largest horn of the lateral ventricle	Inferior horn
▶ Most variable horn of the lateral ventricle	Posterior horn
▶ Island of Reil	Insula (also called central lobe)
▶ Most marked structural feature of the visual cortex	Visual stria (of Gennari)

Clinical Case Study



A 57-year-old executive officer with a history of hypertension developed paralysis in the left side of his body. He was taken to the nearby neurocentre, where on examination the neurosurgeon found increased muscle tone, increased tendon reflexes and positive Babinski sign on the affected side. The sensory examination revealed altered sensations on the affected side. The CT scan of his head revealed a small lesion in his right cerebral hemisphere in the region of the internal capsule.

Questions

1. What did the executive officer suffer from? UMN or LMN type of paralysis? Substantiate your answer with reasons.
2. Name the parts of the internal capsule and mention the part in which the lesion was likely to be located.
3. Which is the most commonly ruptured artery of the cerebral hemisphere?

Answers

1. The UMN type of paralysis, because the typical features of upper motor neuron (UMN) type of paralysis are: increased muscle tone, increased tendon reflexes and positive Babinski sign.
2. The internal capsule consists of the following five parts: anterior limb, genu, posterior limb, sublenticular part, and retrolenticular part. The lesion was likely to be located in the posterior limb because it contains corticospinal fibres and fibres of superior thalamic radiation providing motor and sensory innervation to the opposite half of the body respectively.
3. Charcot's artery of cerebral hemorrhage. It is the larger lateral striate (lenticulostriate) branch of the middle cerebral artery.

Basal Nuclei and Limbic System

BASAL NUCLEI

The basal nuclei (or ganglia) are large subcortical masses of grey matter located inside the white matter in the basal part of the cerebral hemisphere.

Anatomically, the term *basal ganglia* include:

- corpus striatum,
- claustrum, and
- amygdaloid body.

Functionally, basal ganglia also include substantia nigra, red nucleus, and subthalamus.

The basal nuclei are important in organizing and coordinating motor movements. The major function of the basal nuclei is to decrease muscle tone and inhibit unwanted muscular activity.

CORPUS STRIATUM

The corpus striatum is situated lateral to the thalamus. Topographically, it is almost completely divided into the caudate nucleus and the lentiform nucleus by a band of

nerve fibres, the *internal capsule*. However, anteroinferior ends of these nuclei remain connected by a few bands of grey matter across the anterior limb of the internal capsule. These bands give it a striated appearance, hence the name corpus striatum (Figs 28.1 and 28.2).

The lentiform nucleus consists of two parts: a darker lateral part *putamen* and a medial paler part *globus pallidus*.

Phylogenetically, corpus striatum forms two distinct functional units, the **paleostriatum** and the **neostriatum**.

The globus pallidus is relatively ancient and termed *paleostriatum/pallidum*. The caudate nucleus and putamen being recent in development, together form the *neostriatum/striatum*.

These features of the corpus striatum are summarized in Flowchart 28.1.

CAUDATE NUCLEUS

Caudate nucleus is a large comma-shaped mass of grey matter, which surrounds the thalamus and is itself surrounded by the lateral ventricle. The whole length of its convexity projects into the cavity of lateral ventricle.

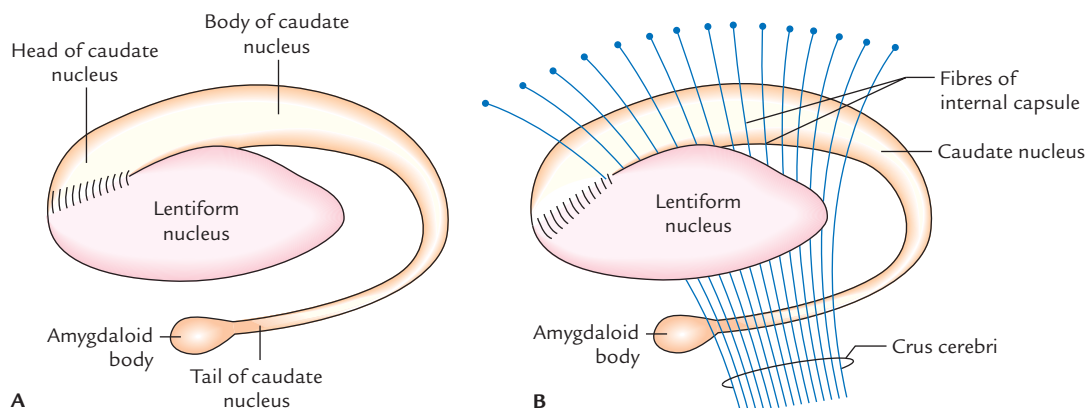


Fig. 28.1 Corpus striatum: A, as seen from lateral aspect; B, relationship of the corpus striatum to the internal capsule.

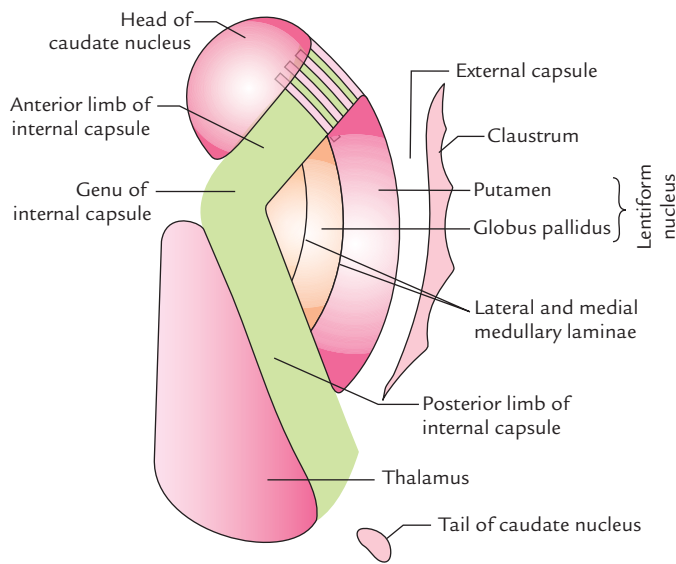
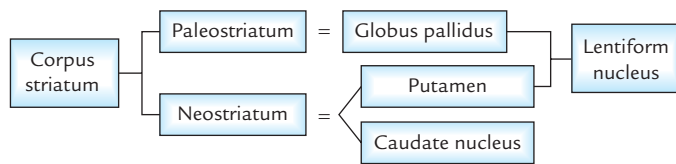


Fig. 28.2 Corpus striatum, thalamus, claustrum, and internal capsule—as seen in horizontal section of the cerebral hemisphere.



Flowchart 28.1 Features of the corpus striatum.

Its rounded anterior part in front of interventricular foramen is called its **head**. The head gradually and imperceptibly tapers caudally into the **body** and then into a **tail**, which merges at its anterior extremity with an almond-shaped mass of grey matter called *amygdaloid body* (Fig. 28.3).

LENTIFORM NUCLEUS

Lentiform nucleus is a large lens-shaped (biconvex) mass of grey matter beneath the insula forming the lateral boundary of the internal capsule. In horizontal section of cerebrum, it appears wedge shaped with broad convex base directed laterally.

It is divided into two parts by a vertical plate of white matter (*external medullary lamina*): an outer darker part, the **putamen** and an inner lighter part the **globus pallidus**.

The larger lateral part, the **putamen** consists of densely packed small cells, and is structurally similar to the caudate nucleus.

The **globus pallidus** is smaller medial part and consists of large (motor) cells. It is also known as *pallidum* as it appears pale in section (pallid = pale). The globus pallidus is further

subdivided by an *internal medullary lamina of white matter* into outer and inner segments.

CONNECTIONS OF CORPUS STRIATUM

The striatum (caudate nucleus and putamen) is the receptive part while globus pallidus is the efferent part (outflow centre) of the corpus striatum.

The striatum receives fibres mainly from the cerebral cortex, thalamus, and substantia nigra. The globus pallidus sends fibres to the thalamus, subthalamus, substantia nigra, reticular formation, and red nucleus.

Different pathways involve different neurotransmitters, which include dopamine, acetylcholine, glutamate, and γ -aminobutyric acid (GABA).

CLAUSTRUM

Clastrum is a thin saucer-shaped mass of grey matter situated between the putamen and insula.

Its significance is not known.

AMYGDALOID BODY (OR AMYGDALA)

Amygdaloid body is an almond-shaped mass of grey matter in the temporal lobe, lying anterosuperior to the tip of inferior horn of lateral ventricle. It is situated deep to uncus, which serves as a surface landmark for its location.

The fibres arising from amygdaloid body form stria terminalis, which follow the inner curve of the caudate nucleus and terminate into septal area, anterior perforated substance, and anterior hypothalamic nuclei (Fig. 28.3). The stria terminalis is the main efferent tract of the amygdaloid body.

Developmentally it is related to the basal nuclei but functionally it is included in the limbic system, and therefore, shares its functions (for details see limbic system on page 401).

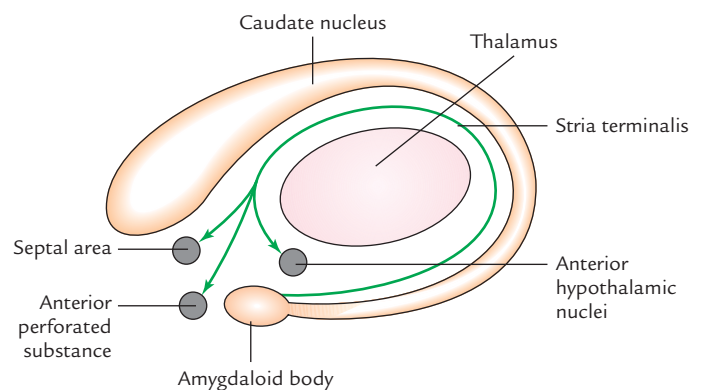


Fig. 28.3 Caudate nucleus, amygdaloid body, and stria terminalis.

SUBSTANTIA NIGRA AND RED NUCLEUS

Substantia nigra and red nucleus are described in detail in Chapter 24.

SUBTHALAMUS (SUBTHALAMIC NUCLEUS)

This small nucleus in the ventral part of the diencephalon, which looks like a biconvex lens in coronal section. It is located caudal to the lateral half of the thalamus and inferomedial to globus pallidus. It is separated from thalamus by a smaller nucleus called *zona inserta*.

FUNCTIONS OF THE BASAL NUCLEI

The functions of the basal nuclei are as follows:

1. Concerned with planning and programming of voluntary movements.
2. Determine how rapidly a movement is to be performed and how large the movement must be.
3. Decrease muscle tone and inhibit unwanted muscular activity.
4. Regulate the muscle tone and thus help in smoothening the voluntary motor activities of the body.
5. Control automatic associated movements, like swinging of arms during walking.
6. Control group of movements responsible for emotional expression.
7. Control reflex muscular activity.

Clinical correlation

Lesions of basal ganglia: The lesions of basal ganglia result in various forms of unwanted involuntary movements and disturbance in the muscle tone. These disorders include Parkinsonism chorea, athetosis, and ballismus. The Parkinsonism being the commonest disorder is described in detail in the following text.

- **Parkinsonism** (also called Parkinson's disease/paralysis agitans): This disease usually occurs after 50 years of age due to deficiency of the neurotransmitter dopamine in the corpus striatum following a lesion in substantia nigra and/or its nigrostriate fibres.

Characteristic features of Parkinsonism:

- Resting tremors.
- Lead-pipe or cogwheel type of muscular rigidity.
- Pill-rolling movements of hands.
- Mask-like face or loss of facial expression.
- Stiff, shuffling gait.
- Stooped posture.
- General slowing-down of movements and absence of associated movements, such as arm swinging during walking.

LIMBIC SYSTEM

The word *limbus* means ring, the term **limbic system** is applied to the parts of the cortical and subcortical structures that form a ring around the upper end of the brainstem.

The limbic region was formerly called **rhinencephalon** because of its association to olfaction, but only a small part of it is actually concerned with smell.

Phylogenetically, limbic cortex is the oldest part of the cerebral cortex and is made up of primitive type of cortical tissue called **allocortex**, which consists of only three layers and surrounds the hilum of the cerebral hemisphere.

The limbic system plays a vital role in **abstract functions** such as emotions, behavior, drive, and memory.

FUNCTIONS OF THE LIMBIC SYSTEM

The limbic system is functionally associated with the following neural activities:

1. Emotional aspects of behavior together with visceral responses accompanying these emotions, particularly the reactions of fear and anger, and emotions associated with sexual behavior which are necessary for:
 - (a) survival of an individual including procuring of food and eating behavior, and
 - (b) survival of the species including the sexual behavior.
2. Brain mechanisms responsible for recent memory.
3. Integration of olfactory, visceral, and somatic impulses reaching the brain.

N.B. Because of visceral responses to activities in the limbic system, it is also known as *visceral brain*. The main object of limbic system is to meet the needs of primitive life, i.e., food and sex.

COMPONENTS OF THE LIMBIC SYSTEM

A large number of structures of the brain are included in the limbic system. However, a fairly accepted list of these structures is described here.

Regions of Grey Matter in Limbic System

Cortical Structures

1. **Limbic lobe**, consisting of cingulate gyrus, isthmus, parahippocampal gyms, and uncus (anterior part of the parahippocampal gyrus).
2. **Hippocampal formation** (Fig. 28.4), which includes hippocampus (cornu ammonis), dentate gyrus, gyrus fasciolaris, and indusium griseum.

Subcortical Nuclei

1. Amygdaloid nuclear complex (also called *amygdaloid body*).

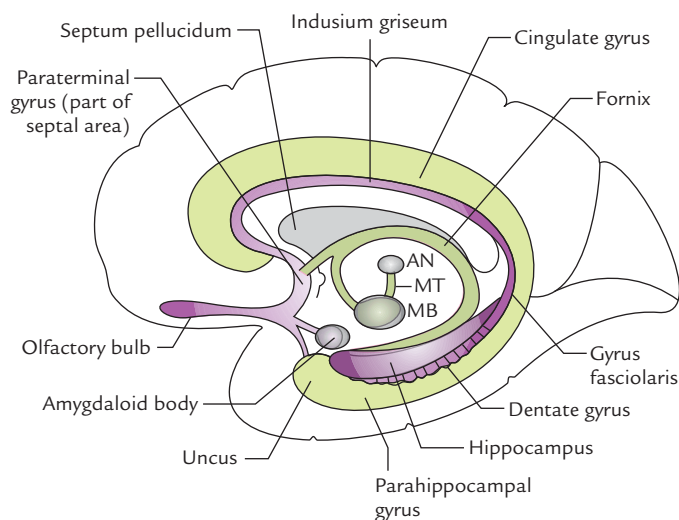


Fig. 28.4 Limbic lobe and hippocampal formation (AN = anterior nucleus of thalamus, MB = mamilary body, MT = mamillothalamic tract).

2. Septal region and nuclei.
3. Olfactory areas.
4. Hypothalamus especially the mamilary bodies.
5. Anterior nucleus of thalamus.

Fibre Bundles of the Limbic System

1. Fornix.
2. Mamillothalamic tract.
3. Stria terminalis.
4. Anterior commissure.

AMYGDALOID NUCLEAR COMPLEX

Amygdaloid nuclear complex consists of lateral, central, and basal nuclei. It is an almond-shaped mass of grey matter underlying the rostral part of the parahippocampal gyrus on the anteriormost part of the roof of the inferior horn of lateral ventricle.

Posteriorly, amygdaloid body becomes continuous with the tail of the caudate nucleus and stria terminalis (Fig. 28.3).

CONNECTIONS

Afferents: Main afferents to amygdaloid body are from primary olfactory regions.

Efferents: Stria terminalis forms the main efferent tract of the amygdaloid body. It takes a circuitous route along with (but not functionally related to) the tail of caudate nucleus in close relation to the lateral ventricle until the level of anterior commissure, where majority of its fibres terminate in the septal area and anterior portion of the hypothalamus (Fig. 28.3). The others join the anterior commissure and are distributed to the contralateral amygdaloid body.

In general, amygdaloid body plays an important role in controlling the somatic responses to internal needs, drives or instincts. Since part of it receives olfactory input, it is believed that the amygdaloid body plays an important role in smell-mediated sexual behavior.

Stimulation of amygdaloid body produces excitability, fear, and rage. Bilateral damage of amygdaloid body reduces fear and increases sexual activity.

N.B. People in late sixties become pervasive in their sexual behavior, probably due to atrophy of amygdaloid bodies.

HIPPOCAMPAL FORMATION

The hippocampal formation consists of (a) hippocampus, (b) dentate gyrus, (c) indusium griseum, gyrus fasciolaris and (d) medial and lateral longitudinal striae.

HIPPOCAMPUS

Hippocampus (also called **Ram's horn** or **Ammon's horn**) is an area of cerebral cortex which has rolled into the floor of the inferior horn of the lateral ventricle during fetal life. In an adult brain, it forms a longitudinal elevation in the floor of inferior horn of the lateral ventricle and is continuous medially with the subiculum and parahippocampal gyrus.

The name "hippocampus" meaning "sea horse", is derived from its appearance in coronal section.

In the frontal section the hippocampus is C-shaped and its outline bears a resemblance to a Ram's horn, hence the name **Ram's horn**. It is also called **Ammon's horn** after an Egyptian deity with Ram's head. Its anterior extremity is expanded and bears few grooves and intervening ridges. Because of its resemblance to an animal's paw it is termed **pes hippocampi** (pes = foot). Traced posteriorly the hippocampus gradually narrows and ultimately ends beneath the splenium of corpus callosum.

The ventricular surface of the hippocampus is covered by a thin layer of white fibres called **alveus**. The fibres of alveus originate in the hippocampal cortex, course towards the medial border of hippocampus where they converge to form a narrow strip of white matter, the **fimbria of hippocampus**.

Phylogenetically, hippocampus represents the archicortex and consists of the following three layers:

1. Superficial molecular layer.
2. Middle pyramidal cell layer.
3. Deep polymorphic cell layer.

N.B. The parahippocampal cortex (neocortex) is made up of six layers. In the region known as subiculum, there is gradual transition from six-layered neocortex to the three-layered archicortex.

Connections

Afferents: Hippocampus receives fibres mainly from entorhinal area (area 28).

Efferents: The fornix is the main efferent tract of the hippocampus.

The fibres leaving the hippocampus pass to:

- the opposite hippocampus through the *commissure of fornix/hippocampal commissure*,
- the septal and anterior hypothalamic regions, and
- the mammillary body, which sends impulses to cingulate gyrus through anterior nucleus of thalamus.

Functions of Hippocampus

- Formerly hippocampus was regarded as the part of olfactory system but it has no direct connections with the sense of smell in man.
- In man it is an integrative centre, which influences endocrine and visceral functions and emotional states through its connections with hypothalamus, septal nuclei, and the cingulate gyrus.

It plays an important role in *recent memory*.

DENTATE GYRUS, INDUSIUM GRISEUM, AND MEDIAL AND LATERAL LONGITUDINAL STRIAE

In the fetal brain, the **dentate gyrus** develops as a further extension of the hippocampus and occupies the interval between the hippocampus and the parahippocampal gyri, lying deep to fimbria. Its surface is toothed, hence the name **dentate gyrus**. When traced anteriorly, dentate gyrus runs medially across the inferior surface of the uncus. This part is called **tail of dentate gyrus**. The posterior end of dentate gyrus is continuous with the **splenial gyrus or gyrus fasciolaris**, which continues as a thin layer of grey matter over the corpus callosum called **indusium griseum**.

The indusium griseum is the vestigial grey matter and contains two delicate longitudinal bands of fibres buried in it, the **medial and lateral longitudinal striae**.

FORNIX

The fornix is a large bundle of projection fibres, which connects the hippocampus with the mammillary body. It constitutes the sole efferent system of the hippocampus (Fig. 28.5).

On the medial surface of the cerebral hemisphere, it is seen as an arched prominent bundle of white fibres below the corpus callosum, along the lower border of septum pellucidum.

There is one fornix in each cerebral hemisphere but two are so closely related/fused beneath the middle of the body

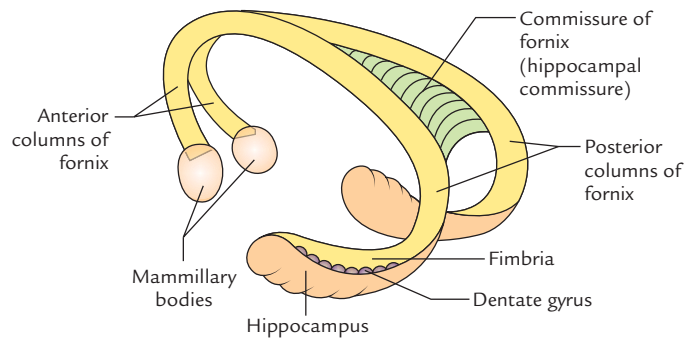


Fig. 28.5 Main parts of the fornix.

of corpus callosum that they are usually described as a single structure.

Origin, Course, and Distribution of the Fibres

The fibres of fornix arise mainly from the pyramidal cells of the hippocampus and form a thin layer of white fibres on its ventricular surface called **alveus**.

The fibres of *alveus* collect on the medial margin of hippocampus to form a narrow strip of white matter, the **fimbria**, lying flat over the dentate gyrus. The fimbria becomes a rounded band, the **crus of fornix** as it arches upwards, medially and forwards underneath the splenium of corpus callosum. The two crura, one of each hemisphere, curving over the thalamus, converge and unite in the midline beneath the trunk of corpus callosum to form the **body of fornix**.

Anteriorly, the body of fornix divides into two columns, the **columns of fornix**. Each column of fornix arches downwards towards the anterior commissure, and forms the anterior boundary of interventricular foramen. Then it curves posteriorly through the hypothalamus to end in the mammillary body. These fibres being located posterior to anterior commissure are referred to as **postcommissural fornix**. Some fibres of column pass in front of anterior commissure to end in the septal area and anterior hypothalamic region, etc. to constitute the **precommissural fornix**.

To summarize, the main parts of the fornix are fimbria, crura, body, and anterior columns (Fig. 28.5).

N.B. Fornix is the only tract of the cerebrum, which contains all the three types of its fibres such as projection fibres, commissural fibres, and association fibres.

MAMMILLOTHALAMIC TRACT

Mammillothalamic tract, also called, Félix Vicq d'Azyr, is a prominent bundle of fibres, which carry impulses from mammillary body to the anterior, nucleus of the thalamus.

Golden Facts to Remember

- | | |
|--|------------------|
| ▶ Most common disease of the basal nuclei | Parkinsonism |
| ▶ Great efferent pathway of hippocampus | Fornix |
| ▶ Ammon's horn/Ram's horn | Hippocampus |
| ▶ Main efferent tract of the amygdaloid body | Stria terminalis |
| ▶ Two main needs of primitive life | Food and sex |
| ▶ Neural tract containing all 3 types of white fibres of brain | Fornix |

Clinical Case Study



A 65-year-old patient presented with resting tremors of the hands, mask-like facies, shuffling gait. A careful physical examination by a neurologist revealed increased muscle tone and cogwheel type of rigidity of the joints. The patient had a stooped posture and his speech was slurred. It was also observed that he lacked associated movements (i.e., no swinging of arms during walking). A clinical diagnosis of *Parkinsonism* was made.

Questions

1. What is the anatomical basis of Parkinsonism?
2. Deficiency of which neurotransmitter is found in this condition?

3. Enumerate characteristic clinical features of Parkinsonism.

Answers

1. Parkinsonism occurs due to degeneration of substantia nigra or nigrostriate fibres.
2. Dopamine.
3. The characteristic clinical features of Parkinsonism are mask-like facies, pill-rolling movements of hands with resting tremors (i.e., slight shaking of hands when person is not performing a task), stooped posture, and stiff shuffling gait.

Blood Supply of the Brain

The brain is one of the most metabolically active organs of the body as it depends on aerobic metabolism of glucose.

Although the brain constitutes only 2% (1/50) of the total body weight, it receives 20% (1/5) of the total cardiac output and consumes 20% of the total O₂ used by the body.

The **cerebrovascular diseases** (thrombosis, embolism, and hemorrhage) are the third most common cause of death and the neurological signs depend on the site of lesion. Therefore, an adequate knowledge of the blood supply of the brain is essential for proper diagnosis and treatment of these diseases.

ARTERIES OF THE BRAIN

The blood supply to the brain is provided by four arteries: two vertebral arteries and two internal carotid arteries (Fig. 29.1).

The two **vertebral arteries** enter the skull through the foramen magnum and unite at the lower border of the pons to form the *basilar artery*, which ascends in the midline on the ventral surface of the pons and at its upper border terminates by dividing into right and left posterior cerebral arteries.

Each **internal carotid artery** enters the cranial cavity through carotid canal and the superior part of the foramen lacerum. It then takes a sinuous course through the cavernous sinus, pierces the dural roof of the sinus, and ends immediately lateral to the optic chiasma in the region of anterior perforated substance by dividing into a larger middle cerebral artery and a smaller anterior cerebral artery.

Circle of Willis (Circulus Arteriosus)

The branches of basilar and internal carotid arteries anastomose at the base of brain around the interpeduncular fossa forming a six-sided polygon of arteries called **circulus arteriosus** or **circle of Willis** (Fig. 29.2). The circle of Willis lies in the *interpeduncular subarachnoid cistern* and contributes most of the arterial blood supply to the brain.

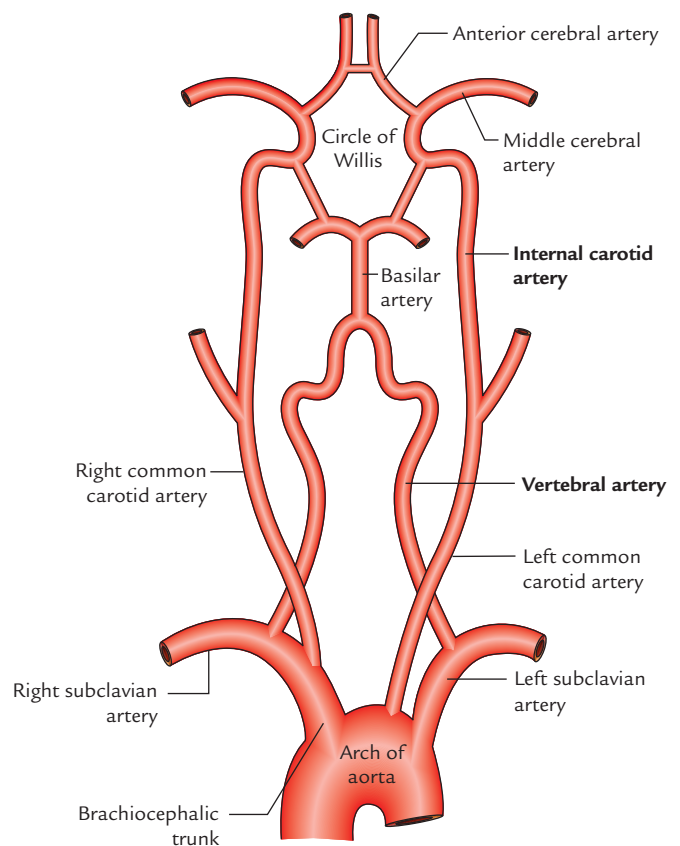


Fig. 29.1 Four arteries supplying the brain.

Formation

The circle of Willis is formed:

Anteriorly, by the anterior communicating and the anterior cerebral arteries.

Posteriorly, by the basilar artery dividing into two posterior cerebral arteries.

Laterally on each side, by the posterior communicating artery connecting the internal carotid artery with the posterior cerebral artery.

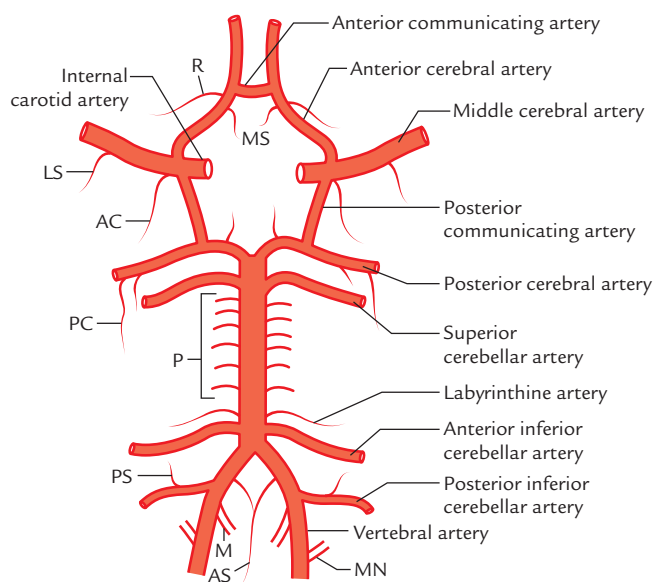


Fig. 29.2 Circle of Willis (AS = anterior spinal artery, LS = lateral striate artery, M = medullary branches, MN = meningeal branches, MS = medial striate arteries, P = pontine branches, PC = posterior choroidal artery, PS = posterior spinal artery, R = recurrent artery of Heubner, AC = anterior choroidal artery).

Functional Significance

Normally there is little or no mixing of blood streams of (a) two vertebral arteries in the basilar artery, (b) two anterior cerebral arteries in the anterior communicating artery, and (c) internal carotid and posterior cerebral arteries in the posterior communicating artery. Therefore, right half of the brain is supplied by right vertebral and right internal carotid arteries and left half of the brain is supplied by left vertebral and left internal carotid arteries.

However, if one of the major arteries forming the circle of Willis is blocked, the circle of Willis provides the various alternative routes for **collateral circulation** like an **arterial traffic circle**.

Clinical correlation

- **Congenital cerebral aneurysms:** These occur mostly at the sites where two arteries join in the formation of the circle of Willis. The basic abnormality at these points is the congenital deficiency of the tunica media (elastic tissue) in the arterial wall. The aneurysms are berry shaped, hence they are generally termed as *berry aneurysms*.
- **Subarachnoid hemorrhage:** The subarachnoid hemorrhage commonly, but not exclusively, results from rupture of congenital berry aneurysms in the interpeduncular cistern.

The subarachnoid hemorrhage produces a sudden severe pain in head followed by mental confusion. The death may quickly occur, or the patient may survive the first bleeding only to die a few days or weeks later.

Branches of the Cranial Part of Vertebral Artery

These are as follows:

1. **Posterior spinal artery** (first intracranial branch) arises from vertebral artery and sometimes from posterior inferior cerebellar artery. It passes downwards on the posterior surface of the spinal cord after dividing into two branches; one along the medial side and the other along the lateral side of the dorsal roots of the spinal nerves.
2. **Posterior inferior cerebellar artery** is the largest branch of the cranial (4th) part of the vertebral artery. It arises near the lower end of the olive, winds backwards around the medulla oblongata, and then ascends to the pontomedullary junction.
3. **Anterior spinal artery** is a small branch. It arises near the termination of the vertebral artery. It descends in front of the medulla and unites with its fellow of the opposite side—the lower end of the olive to form a single median trunk that descends along the anterior longitudinal fissure of the spinal cord.
4. **Meningeal branches** are small and supply the dura mater of the posterior cranial fossa.
5. **Medullary arteries** are several minute vessels which supply the medulla oblongata.

Branches of the Basilar Artery

These are as follows:

1. **Pontine branches** are numerous short, slender paramedian vessels, which pierce the pons to supply it.
2. **Anterior-inferior cerebellar artery** arises close to the lower border of the pons and runs backwards, and laterally usually ventral to the 7th and 8th cranial nerves. Then it forms a loop over the flocculus of the cerebellum and peeps into the internal acoustic meatus for a variable distance lying below the 7th and 8th cranial nerves. After exit from the meatus, it supplies the anterolateral portion of the inferior surface of the cerebellum.
3. **Labyrinthine artery** is a long slender branch which arises either from basilar artery or from anterior-inferior cerebellar artery. It accompanies the vestibulocochlear nerve and enters the internal auditory meatus to supply the internal ear. It is an end artery.
4. **Superior cerebellar artery** arises close to the superior border of the pons, runs laterally below the oculomotor nerve (which is interposed between this artery and the posterior cerebral artery) and winds round the cerebral peduncle below the trochlear nerve to reach the superior surface of the cerebellum, which it supplies.
5. **Posterior cerebral artery** passes laterally along the superior border of the pons parallel to the superior cerebellar artery, curves around the midbrain to reach

the medial surface of the cerebral hemisphere beneath the splenium of corpus callosum. The artery gives off central branches into the ventral surface of the midbrain and temporal lobe of the corresponding cerebral hemisphere. Then it passes towards the occipital pole giving cortical branches.

Branches of the Cerebral Part of Internal Carotid Artery

These are as follows:

1. **Ophthalmic artery** arises from internal carotid artery immediately after it comes out of cavernous sinus and makes a U-shaped bend. The ophthalmic artery enters the orbit through optic canal to supply structures of the orbit including eyeball.
2. **Posterior communicating artery** arises close to the termination of the internal carotid artery. It runs backwards and anastomoses with the proximal part of the posterior cerebral artery.
3. **Anterior choroidal artery** is a long slender branch, which arises just distal to the origin of the posterior communicating artery. It courses backwards above and along the optic tract to enter the inferior horn of the lateral ventricle through the choroid fissure to end in the choroid plexus.
Due to its long subarachnoid course and a relatively small lumen, the anterior choroidal artery is most susceptible to thrombosis and is often referred to as artery of cerebral thrombosis.
4. **Anterior cerebral artery** is a smaller terminal branch of the internal carotid artery. It runs forwards and medially above the optic nerve to the commencement of the median longitudinal cerebral fissure, where it comes very close to its fellow of the opposite side and gets joined with it by a short transverse *anterior communicating artery*. The anterior cerebral artery then curves around the genu of corpus callosum.

The branches given off just distal to the anterior communicating artery supply the medial part of the orbital surface of the frontal lobe.

The artery continues along the upper surface of the corpus callosum and gives branches which supply the whole of the medial surfaces of the hemisphere above the corpus callosum as far back as the parieto-occipital sulcus.

5. **Middle cerebral artery** is the larger terminal branch of the internal carotid artery. It appears to be the direct continuation of the internal carotid artery and carries about 30% of the carotid blood flow.

The middle cerebral artery first runs laterally in the stem of the lateral sulcus and then turns backwards and upwards in the posterior ramus of the lateral sulcus, where it breaks up into frontal, parietal, and temporal branches, which emerge from the lateral sulcus and run towards the areas of their supply.

The branches of main arteries supplying the brain are summarized in Table 29.1.

It is interesting to note from Table 29.1 that each main artery supplying the brain gives off **five sets of branches**, thus making a total of **15 sets**, out of which there are **three pairs of cerebral arteries (anterior, middle, and posterior)** and **three pairs of cerebellar arteries (posteroinferior, anteroinferior, and superior)**.

Clinical correlation

Cerebral thrombosis most commonly affects the middle cerebral artery or its main branches because it is a direct continuation of the internal carotid artery.

ARTERIAL SUPPLY OF CEREBRUM

The cerebrum is supplied by three pairs of cerebral arteries, *viz.* anterior, middle, and posterior.

Branching Pattern of Cerebral Arteries

The cerebral arteries give three types of branches, *viz.*

1. Cortical branches.
2. Central branches.
3. Choroidal branches.

Table 29.1 Branches of the main arteries of the brain

Cerebral part of internal carotid artery	Cranial (fourth) part of vertebral artery	Basilar artery
Ophthalmic artery	Meningeal arteries	Anterior inferior cerebellar artery
Anterior cerebral artery	Anterior spinal artery	Labyrinthine artery
Middle cerebral artery	Posterior spinal artery	Pontine arteries
Posterior communicating artery	Posterior inferior cerebellar artery	Superior cerebellar artery
Anterior choroidal artery	Medullary arteries	Posterior cerebral artery

Cortical branches: The cortical branches supply the outer portion of the cerebrum. The cortical vessels freely anastomose and form a network in the pia mater on the surface of the cerebral cortex. From this network branches arise and pierce the cortex at right angle. Once they enter the cortex, they become the *end arteries*. There are two types of these end arteries: (a) short, which confine themselves only to the cortex and (b) long, which pass through the cortex and reach the outer portion of the white matter.

Central branches: They are numerous slender thin-walled perforating branches, which supply the centrally located parts of the cerebrum, *viz.* corpus striatum, internal capsule, etc. They are *end arteries*. The central arteries arise in the region of arterial circle of Willis, and are arranged into the following four groups:

1. Anteromedial group.
2. Anterolateral group (lateral striate arteries).
3. Posteromedial group.
4. Posterolateral group.

Choroidal arteries: The choroidal arteries form a network of capillaries which project into the ventricles after invaginating the layers of pia mater and ependyma forming **choroid plexuses**. They are:

1. Anterior choroidal artery.
2. Posterior choroidal artery.

ARTERIAL SUPPLY OF DIFFERENT SURFACES OF CEREBRAL HEMISPHERE

Arterial Supply of Superolateral Surface (Fig. 29.3A)

The superolateral surface of the cerebral hemisphere is supplied by the following arteries:

1. **Middle cerebral artery:** Most of the superolateral surface (about 2/3rd) is supplied by the middle cerebral artery. The region of cerebral cortex supplied by it includes the greater parts of primary motor and sensory areas, and frontal eye field. In the left (dominant) hemisphere it includes the Broca and Wernicke's speech areas.
2. **Anterior cerebral artery:** A narrow strip of the cerebral cortex (about 2.5 cm in width) adjoining superomedial border up to the parieto-occipital sulcus is supplied by anterior cerebral artery. The upper parts of primary motor and sensory areas lie in this region.
3. **Posterior cerebral artery:** A narrow strip along the lower border of temporal lobe (excluding temporal pole) and occipital lobe are supplied by **posterior cerebral artery**. The posterior parts of visual area fall in this area.

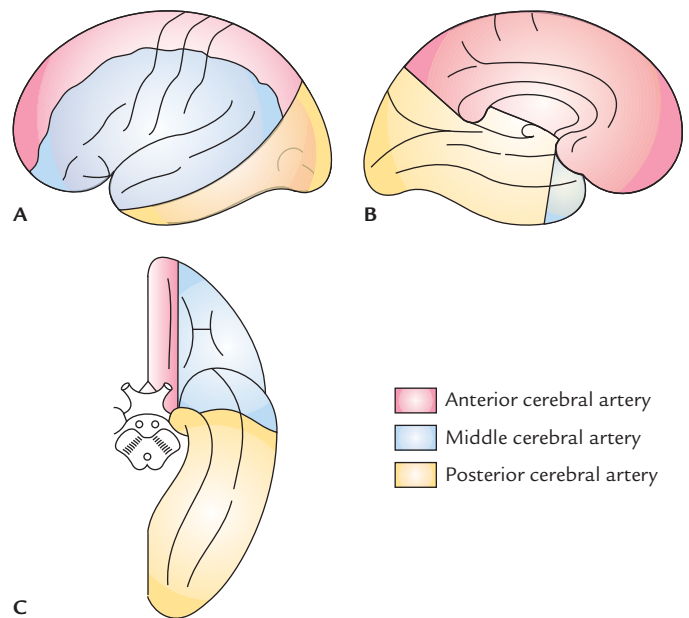


Fig. 29.3 Arterial supply of the different surfaces of the cerebral hemisphere: **A**, superolateral surface; **B**, medial surface; **C**, inferior surface.

Arterial Supply of Medial Surface (Fig. 29.3B)

The medial surface of the cerebral hemisphere is supplied by the following arteries:

1. **Anterior cerebral artery:** Most of the medial surface (anterior 2/3rd) is supplied by the anterior cerebral artery. The region of cerebral cortex supplied includes the parts of motor and sensory areas (paracentral lobule) concerned with perineum, leg, and foot.
2. **Middle cerebral artery:** Temporal pole of the temporal lobe is supplied by the middle cerebral artery.
3. **Posterior cerebral artery:** Occipital lobe is supplied by the posterior cerebral artery. The area supplied includes the visual cortex.

Arterial Supply of Inferior Surface (Fig. 29.3C)

The inner surface of the cerebral hemisphere is supplied by the following arteries:

1. **Posterior cerebral artery:** Most of the inferior surface except the temporal pole is supplied by the posterior cerebral artery.
2. **Middle cerebral artery:** Lateral part of the orbital surface of the frontal lobe and temporal pole of the temporal lobe are supplied by the middle cerebral artery.
3. **Anterior cerebral artery:** Medial part of the orbital surface of the frontal lobe is supplied by the anterior cerebral artery.

N.B. Each surface of the cerebral hemisphere is supplied by three cerebral arteries, viz. anterior, middle, and posterior.

Most of the superolateral surface is supplied by middle cerebral artery, most of the medial surface by the anterior cerebral artery, and most of the inferior surface by the posterior cerebral artery.

Clinical correlation

Occlusion of middle cerebral artery: The *occlusion of middle cerebral artery* occurs commonly. It produces the following signs and symptoms:

- *Contralateral hemiplegia and hemianesthesia* involving mainly the face and arm, due to involvement of most of the primary motor and sensory areas.
- *Aphasia*, if left dominant hemisphere is involved—due to involvement of motor and sensory speech areas.
- *Contralateral homonymous hemianopia* due to involvement of optic radiation.

ARTERIAL SUPPLY OF OTHER PARTS OF THE BRAIN

The arterial supply of the other parts of the brain as are follows:

1. The **corpus striatum** and **internal capsule** are supplied mainly by the central branches of middle cerebral artery and to some extent by the central branches of anterior cerebral artery.
2. The **thalamus** is supplied mainly by the central branches of posterior communicating, posterior cerebral, and basilar arteries.
3. The **midbrain** is supplied by the posterior cerebral, superior cerebellar, and basilar arteries.
4. The **pons** is supplied by the basilar, superior cerebellar, and anterior inferior cerebellar arteries.
5. The **medulla oblongata** is supplied by the vertebral, anterior spinal, posterior spinal, posterior inferior cerebellar, and basilar arteries.
6. The **cerebellum** is supplied by the superior, anterior inferior, and posterior inferior cerebellar arteries.

VENOUS DRAINAGE OF THE BRAIN

The veins of the brain drain into the intracranial dural venous sinuses, which eventually drains into the internal jugular veins of the neck.

The characteristic features of the venous drainage of the brain are as follows:

1. The venous return in the brain does not follow the arterial pattern.
2. The veins of the brain are extremely thin walled due to absence of muscular tissue in their walls.

3. The veins of the brain possess no valves.
4. The veins of the brain run mainly in the subarachnoid space.

The veins of the brain comprise cerebral veins, cerebellar veins, and veins of the brainstem.

CEREBRAL VEINS

The cerebral veins are divided into external (superficial) and internal cerebral veins, which drain the external surfaces and the internal regions of the cerebral hemisphere, respectively.

External Cerebral Veins

The external cerebral veins drain the surface (cortex) of the hemisphere and are divided into three groups, viz.

1. Superior.
2. Middle.
3. Inferior.

Superior cerebral veins (Fig. 29.4): The superior cerebral veins are about 8–12 and drain the upper parts of the superolateral and medial surfaces of the cerebral hemisphere. They ascend upwards, pierce the arachnoid mater, and traverse the subdural space to enter the superior sagittal sinus.

The anterior veins open at right angle, while the posterior open obliquely against the flow of bloodstream in the superior sagittal sinus, thereby preventing their collapse by increased CSF pressure.

Middle cerebral veins: The middle cerebral veins are four, two on each side: superficial middle cerebral vein and deep middle cerebral vein.

The **superficial middle cerebral vein** (Fig. 29.4) lies superficially in the lateral sulcus. Anteriorly, it runs forwards to drain into the cavernous sinus while posteriorly, it communicates with the superior sagittal sinus via **superior**

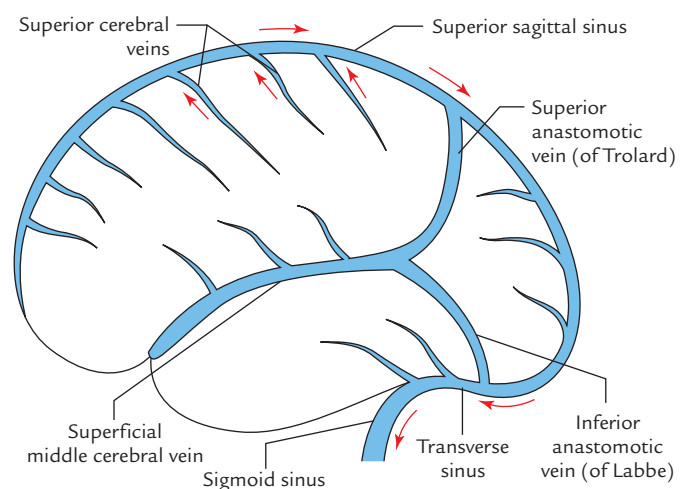


Fig. 29.4 Veins on the superolateral surface of the cerebral hemisphere.

anastomotic vein (of Trolard) and with the transverse sinus via **inferior anastomotic vein (of Labbe)**.

The **deep middle cerebral vein** lies deep in the lateral sulcus on the insula along with middle cerebral artery. It runs downwards and forwards and joins the *anterior cerebral vein* to form the **basal vein**.

Inferior cerebral veins: The inferior cerebral veins are many in number but smaller in size. They drain the inferior surface and lower parts of medial and superolateral surfaces of the cerebral hemisphere into nearby intracranial dural venous sinuses, e.g., transverse sinus.

Other Veins

Anterior cerebral vein

It accompanies the anterior cerebral artery around the corpus callosum and drains the parts of medial surface, which cannot be drained into the superior and inferior sagittal sinuses.

Basal vein (of Rosenthal)

It is formed at the base of the brain in the region of anterior perforated substance by the union of three veins: *anterior cerebral*, *deep middle cerebral*, and *striate veins*. The striate veins emerge from the anterior perforated substance.

The basal vein runs posteriorly around the midbrain, medial to the uncus and parahippocampus, and terminates into the **great cerebral vein (of Galen)** below the splenium of corpus callosum.

Besides the formative three veins, the basal vein receives the tributaries from:

1. Cerebral peduncle.
2. Uncus and parahippocampus.
3. Structures of interpeduncular fossa.
4. Optic tract and olfactory trigone.
5. Inferior horn of the lateral ventricle.

Internal Cerebral Veins

There are two **internal cerebral veins** located one on either side of midline in the tela choroidea of the 3rd ventricle (Fig. 29.5).

Each internal cerebral vein is formed at the **interventricular foramen (of Monro)** by the union of three veins: thalamostriate, septal, and choroidal. The two internal cerebral veins run posteriorly, one on either side of midline, between the two layers of tela choroidea of 3rd ventricle and unite together beneath the splenium of corpus callosum to form the **great cerebral vein (of Galen)**, which empties into the straight sinus.

The **thalamostriate**, **septal**, and **choroidal veins** are the most important deep veins of the cerebrum. As their names imply, the thalamostriate (striothalamic) vein drains the thalamus and basal ganglia; the septal vein drains the septum

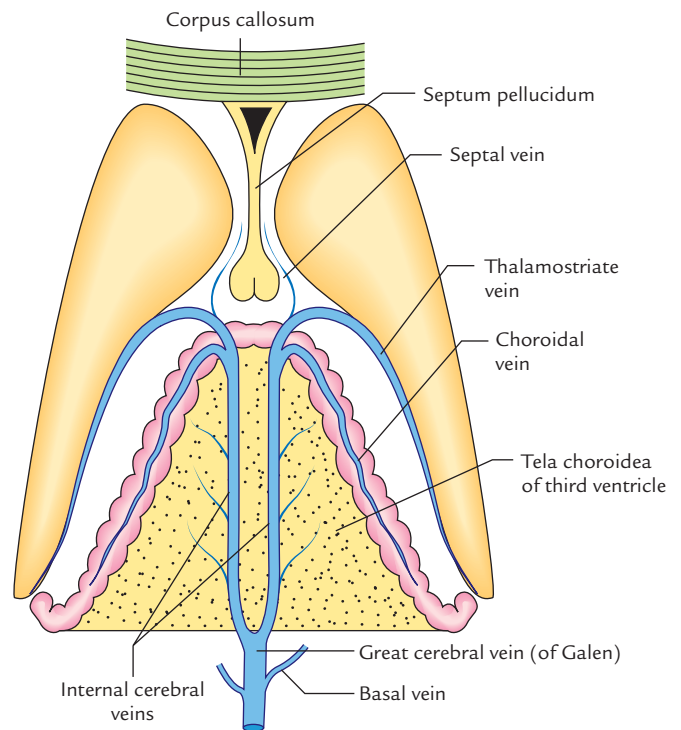


Fig. 29.5 Formation, course, and tributaries of the internal cerebral veins.

pellucidum, and the choroidal vein drains the choroids plexus.

Great Cerebral Vein (of Galen)

Great cerebral vein is a single vein (about 2 cm in length). It is formed by the union of two internal cerebral veins below and behind the splenium of corpus callosum. It immediately receives the two basal veins and after a short backward course it joins the inferior sagittal sinus to form the **straight sinus**.

The tributaries of the great cerebral vein are:

1. Internal cerebral veins.
2. Basal veins.
3. Veins from colliculi (tectum of midbrain).
4. Veins from cerebellum and adjoining parts of the occipital lobes of the cerebrum.

VENOUS DRAINAGE OF DIFFERENT SURFACES OF CEREBRAL HEMISPHERE

Venous Drainage of Superolateral Surface (Fig. 29.4)

Superolateral surface of the cerebral hemisphere is drained by the following veins:

1. **Superior cerebral veins:** They drain the upper part into the *superior sagittal sinus*.

2. **Inferior cerebral veins:** They drain the lower part into the *superficial middle cerebral vein*, however some from the posteroinferior part drain into the *transverse sinus*.

Venous Drainage of Inferior Surface

Inferior surface of the cerebral hemisphere is drained by the inferior cerebral veins:

1. **Inferior cerebral veins from the orbital part:** They drain into the superficial, middle cerebral, and anterior cerebral veins.
2. **Inferior cerebral veins from the tentorial part:** They drain into:
 - (a) venous sinuses at the base of skull, *viz.* cavernous, superior petrosal, straight and transverse sinuses, and
 - (b) superficial middle cerebral vein, which drains into cavernous sinus and basal vein, which drains into the straight sinus.

Venous Drainage of Medial Surface

Medial surface of the cerebral hemisphere is drained by the following veins:

1. **Superior cerebral veins:** They drain the upper part into superior sagittal sinus.

2. **Inferior cerebral veins:** They drain the lower part into the inferior sagittal sinus.
3. **Some of the veins from the posterior part:** These veins drain into the great cerebral vein.
4. **Anterior cerebral vein:** It drains the anterior part.

N.B. In conclusion, the superficial veins drain mainly into the superior sagittal sinus, which ultimately drains into the right internal jugular vein. On the other hand, the deep veins drain mainly into the great cerebral vein, which ultimately drains into the left internal jugular vein.

Clinical correlation

Subdural hemorrhage: It occurs due to rupture of cerebral veins in the subdural space. The cerebral veins while traversing the subdural space en route to drain into the dural venous sinuses have little support and are torn following moderate trauma on head. The superior cerebral veins are most commonly torn, where they enter the superior sagittal sinus. The cause is usually a blow on the front or back of the head, resulting in excessive anteroposterior displacement of the brain within the skull. Consequently the cerebral veins in the subdural space (called *bridging veins*) are unduly stretched and torn. The subdural hemorrhage is generally extensive because of the loose attachment between the dura and arachnoid.

Golden Facts to Remember

▶ Most metabolically active organ in the body	Brain
▶ Circle of Willis	Polygonal arterial anastomosis between the branches of carotid and basilar arteries at the base of the brain
▶ Commonest cause of subarachnoid hemorrhage	Rupture of berry aneurysms in the circle of Willis
▶ Largest branch of cranial part of the vertebral artery	Posterior-inferior cerebellar artery
▶ Artery of cerebral thrombosis	Anterior choroidal artery
▶ Artery of cerebral hemorrhage	Charcot's artery (larger lateral striate branch of middle cerebral artery)
▶ Most of the superolateral surface of the cerebral hemisphere is supplied by	Middle cerebral artery
▶ Most of the medial surface of the cerebral hemisphere is supplied by	Anterior cerebral artery
▶ Most of the inferior surface of the cerebral hemisphere is supplied by	Posterior cerebral artery
▶ Commonest cause of subdural hemorrhage	Rupture of superior cerebral veins (<i>bridging veins</i>)

Clinical Case Study



A 65-year-old individual who was suffering from chronic high blood pressure suddenly suffered from contralateral hemiplegia, hemianesthesia, and loss of speech. He was taken to the hospital, where he was diagnosed as a case of *cerebral stroke*.

Questions

1. What is cerebral stroke?
2. Name the arteries which supply the cerebral hemisphere.

3. Which cerebral artery is likely to be involved in the given case?

Answers

1. A neurological deficit that follows the deprivation of the cerebral blood flow.
2. Anterior, middle, and posterior cerebral arteries.
3. Left middle cerebral artery, because it supplies the motor speech area.

Multiple Choice Questions

CHAPTER 1

- The smooth elevated area between the eyebrows is called:
 - Bregma
 - Glabella
 - Nasion
 - Medial canthus
- The tragus of auricle is located in:
 - Frontal region of head
 - Nasal region of head
 - Temporal region of head
 - Zygomatic region of head
- The most prominent part of occipital regions of the head is called:
 - Inion
 - Opisthocranium
 - Superior nuchal lines
 - Basion
- Select *incorrect statement* regarding the auricle of the ear:
 - It helps to collect the sound waves
 - The upper end of helix lies at the level of lateral canthus of eye
 - The lobule is approximately at the level of the apex of the nose
 - The tragus is located anterior to the opening of external auditory meatus
- Regarding the lips, which of the following statement is *not correct*:
 - Each lip is demarcated from the surrounding skin by vermillion border
 - The philtrum is a triangular median depression in upper lip
 - The width of lips is approximately the same as that between the two irises
 - The lower lip is separated from the chin by labial commissure
- All of the following structures can be palpated in the anterior median region of the neck *except*:
 - Hyoid bone
 - Thyroid cartilage
 - Transverse process of atlas vertebra
 - Cricoid cartilage
- The junction between the labial/buccal mucosa and alveolar mucosa is called:
 - Mucogingival junction
 - Mucobuccal fold
 - Vermillion border
 - Labial frenulum
- Floor of the mouth presents all of the following features *except*:
 - Sublingual papillae
 - Sublingual folds
 - Parotid papillae
 - Frenulum linguae
- A midline ridge of tissue on the oral aspect of the hard palate is called:
 - Incisive papilla
 - Palatine rugae
 - Median palatine raphe
 - Sulcus terminalis
- All of the following structures traverse through the anterior compartment of the neck *except*:
 - Digestive tract
 - Respiratory tract
 - Internal jugular veins
 - Spinal cord

11. Into which cervical triangles does the sternocleidomastoid divide the neck:

- (a) Medial and lateral
- (b) Superior and inferior
- (c) Anterior and posterior
- (d) Proximal and distal

Answers

1. *b*, 2. *c*, 3. *b*, 4. *b*, 5. *d*, 6. *c*, 7. *b*, 8. *c*, 9. *c*, 10. *d*, 11. *c*

CHAPTER 2

1. Bones of the skull which permit free movement are all *except*:

- (a) Mandible
- (b) Malleus
- (c) Incus
- (d) Vomer

2. The area of the lateral aspect of skull that overlies the anterior division of middle meningeal artery is called:

- (a) Bregma
- (b) Asterion
- (c) Pterion
- (d) Inion

3. Regarding pterion, all of the following statements are true *except*:

- (a) It overlies the posterior division of middle meningeal artery
- (b) It is region where four bones meet
- (c) It is located 4 cm above the midpoint of the zygomatic arch
- (d) Bones meeting at pterion form 'H-shaped suture'

4. Regarding spine of sphenoid, all of the following statements are true *except*:

- (a) It is located on the base of skull posterolateral to the foramen spinosum
- (b) It is related to auriculotemporal and chorda tympani nerves
- (c) It provides attachment to levator palati muscle
- (d) It provides attachment to sphenomandibular ligament

5. All of the following structures pass through foramen ovale *except*:

- (a) Mandibular nerve
- (b) Anterior division of middle meningeal artery
- (c) Lesser superficial petrosal nerve
- (d) Emissary vein connecting pterygoid venous plexus to cavernous sinus

6. Regarding mastoid process, all of the following statements are correct *except*:

- (a) It is absent at birth
- (b) It begins to develop at the end of the 2nd year after birth
- (c) It contains tympanic cavity
- (d) It provides attachment to posterior belly of digastric

7. All of the following are common sites of fracture of the mandible *except*:

- (a) Neck of mandible
- (b) Angle of mandible
- (c) Canine region of the body
- (d) Symphysis menti

8. All of the following foramina are present in the greater wing of sphenoid *except*:

- (a) Foramen rotundum
- (b) Foramen ovale
- (c) Foramen lacerum
- (d) Foramen spinosum

9. Which of the following bones is not a sutural bone?

- (a) Epipteric bone
- (b) Inca bone
- (c) OS Kerckring
- (d) Interparietal bone

10. In articulated skull, maxillary hiatus is reduced in size by all of the following bones *except*:

- (a) Uncinate process of ethmoid
- (b) Descending process of lacrimal
- (c) Horizontal palate of palatine
- (d) Maxillary process of inferior nasal concha

Answers

1. *d*, 2. *c*, 3. *a*, 4. *c*, 5. *b*, 6. *c*, 7. *d*, 8. *c*, 9. *d*, 10. *c*

CHAPTER 3

1. Which layer of scalp is regarded as the 'dangerous layer':

- (a) Subcutaneous layer
- (b) Aponeurotic layer
- (c) Layer of loose areolar tissue
- (d) Pericranium

2. Select the *incorrect statement* about the scalp:

- (a) It extends posteriorly up to superior nuchal line
- (b) Epicranial aponeurosis forms its second layer
- (c) Its motor supply is derived from facial nerve
- (d) Its vessels fail to retract if cut

3. All of the following nerves innervate the posterior quadrant of the scalp *except*:

- (a) Auriculotemporal
 - (b) Great auricular
 - (c) Greater occipital
 - (d) Lesser occipital
4. All of the following arteries supply the anterior quadrant of the scalp *except*:
- (a) Supratrochlear
 - (b) Supraorbital
 - (c) Posterior auricular
 - (d) Superficial temporal
5. Superficial surface of temporal fascia is related to all of the following structures *except*:
- (a) Auriculotemporal nerve
 - (b) Great auricular nerve
 - (c) Superficial temporal vessels
 - (d) Temporal branches of facial nerve
6. Regarding muscles of facial expression, which of the following statements is *incorrect*:
- (a) They are present in the superficial fascia
 - (b) They are developed from first pharyngeal arch
 - (c) Their motor supply is derived from facial nerve
 - (d) Morphologically they represent panniculus carnosus
7. Regarding Bell's palsy, which of the following statements is *not correct*:
- (a) It is a lower motor neuron type of paralysis of facial muscles
 - (b) The upper facial muscles are not affected
 - (c) It occurs due to compression of facial nerve in the facial canal
 - (d) It leads to accumulation of food in the vestibule of mouth
8. Regarding lacrimal gland, which of the following statements is *not correct*:
- (a) It consists of larger orbital and smaller palpebral part
 - (b) It is a mucous gland
 - (c) It receives its secretomotor supply through lacrimal nerve
 - (d) The two parts of lacrimal glands are separated from each other by levator palpebrae superioris
9. Regarding eyelids which of the following statements is *not correct*:
- (a) Tarsi forms the skeleton of the eyelids
 - (b) Free margin of eyelids carries eyelashes along its whole extent
 - (c) Openings of tarsal glands are present along the posterior edge of free margins of eyelids

- (d) Openings of ciliary glands are located along the anterior edge of the free margin of eyelids

Answers

1. *c*, 2. *b*, 3. *a*, 4. *c*, 5. *b*, 6. *b*, 7. *b*, 8. *b*, 9. *b*

CHAPTER 4

1. Regarding skin of neck, all of the following statements are correct *except*:
- (a) Cleavage lines of skin in the neck are disposed transversely
 - (b) It receives cutaneous innervation from C1 to C7 spinal nerves
 - (c) It receives cutaneous innervation from C2 to C4 spinal nerves
 - (d) It is thin and drains its lymph into superficial lymph nodes
2. Regarding platysma, all of the following statements are correct *except*:
- (a) It is present deep to investing layer of deep cervical fascia
 - (b) Morphologically it represents panniculus carnosus
 - (c) It is innervated by the facial nerve
 - (d) Its contraction relieves the pressure of skin on superficial veins of the neck
3. All of the following statements about external jugular vein are correct *except*:
- (a) It is formed by the union of posterior division of retromandibular vein and posterior auricular vein
 - (b) It crosses sternocleidomastoid on its superficial aspect
 - (c) It pierces the deep cervical fascia about 2.5 cm above the clavicle
 - (d) It drains into internal jugular vein
4. Select the *incorrect statement* regarding anterior jugular vein:
- (a) It is formed below the chin in submental region
 - (b) It runs about 1 cm lateral to anterior midline of the neck
 - (c) It is joined with its counter part of opposite side by the jugular venous arch
 - (d) It drains into subclavian vein
5. All of the following are derivatives of deep cervical fascia *except*:
- (a) Pretracheal fascia
 - (b) Prevertebral fascia
 - (c) Stylomandibular ligament
 - (d) Sphenomandibular ligament

6. Superficial lymph nodes of neck consist of all of the following groups of lymph nodes *except*:
- Submental
 - Submandibular
 - Retroauricular
 - Retropharyngeal
7. 'Suprasternal space of Burns' contains all of the following structures *except*:
- Jugular venous arch
 - Interclavicular ligament
 - Terminal ends of external jugular veins
 - Sternal heads of sternocleidomastoid muscles
8. All of the following are contents of carotid sheath *except*:
- Internal carotid artery
 - External carotid artery
 - Internal jugular vein
 - Vagus nerve
9. Select the *incorrect statement* about the carotid sheath:
- It extends from base of skull to the clavicle
 - The ansa cervicalis is embedded in its anterior wall
 - It is ill defined over the internal jugular vein
 - The cervical sympathetic chain is posterior to it
10. Select the *incorrect statement* regarding cold abscess due to tubercular caries of cervical vertebrae:
- Produces paramedian bulge in the posterior pharyngeal wall
 - Produces median bulge in the posterior pharyngeal wall
 - It may extend into posterior triangle of the neck
 - It may extend into axilla and arm
- Occipital artery
 - Third part of subclavian artery
3. Select the *incorrect statement* regarding the spinal accessory nerve:
- It emerges in the posterior triangle by piercing the posterior border of sternocleidomastoid
 - It is related to lymph nodes belonging to upper deep cervical lymph nodes
 - It runs parallel to the fibres of scalenus medius
 - It supplies sternocleidomastoid and trapezius muscles
4. All of the following nerves arise from cervical part of the brachial plexus *except*:
- Dorsal scapular nerve
 - Nerve to serratus anterior
 - Musculocutaneous nerve
 - Suprascapular nerve
5. Select the *incorrect statement* regarding the sternocleidomastoid muscle:
- It tilts the head to the same side
 - It overlaps the carotid sheath
 - It is supplied by the cranial root of accessory nerve
 - It is crossed superficially by the external Jugular vein
6. The sternocleidomastoid is crossed superficially by all of the following structures *except*:
- Lesser occipital nerve
 - Great auricular nerve
 - External jugular vein
 - Transverse cervical nerve
7. Which of the following lymph nodes are termed *Virchow's lymph nodes*:
- Left infraclavicular
 - Left supraclavicular
 - Right infraclavicular
 - Right supraclavicular
8. All of the following structures pierce the roof of posterior triangle *except*:
- Anterior jugular vein
 - External jugular vein
 - Supraclavicular nerves
 - Great auricular nerve

Answers

1. **b**, 2. **a**, 3. **d**, 4. **d**, 5. **d**, 6. **d**, 7. **c**, 8. **b**, 9. **a**, 10. **a**

CHAPTER 5

1. All of the following muscles forms the floor of posterior triangle *except*:
- Splenius capitis
 - Levator scapulae
 - Scalenus medius
 - Scalenus anterior
2. All of the following structures lie deep to fascial carpet of posterior triangle *except*
- Trunks of brachial plexus
 - Spinal accessory nerve
3. All of the following structures pierce the roof of posterior triangle *except*:
- Anterior jugular vein
 - External jugular vein
 - Supraclavicular nerves
 - Great auricular nerve

Answers

1. **d**, 2. **b**, 3. **c**, 4. **c**, 5. **c**, 6. **a**, 7. **b**, 8. **a**

CHAPTER 6

1. Select the **incorrect statement** about the mental triangle:
 - (a) It is located in the anterior median region of the neck
 - (b) Its floor is formed by the oral diaphragm
 - (c) It is bounded on either side by the posterior belly of digastric muscle
 - (d) Its base is formed by the body of hyoid bone
2. All of the following structures form the boundaries of digastric triangle **except**:
 - (a) Posterior belly of digastric muscle
 - (b) Anterior belly of digastric muscle
 - (c) Superior belly of omohyoid muscle
 - (d) Base of the mandible
3. All of the following structures pass between external and internal carotid arteries **except**:
 - (a) Stylopharyngeus muscle
 - (b) Superior laryngeal nerve
 - (c) Glossopharyngeal nerve
 - (d) Pharyngeal branch of vagus nerve
4. Select the **incorrect statement** regarding the carotid sinus:
 - (a) It is fusiform dilatation at the beginning of the internal carotid artery
 - (b) It is innervated by vagus nerve
 - (c) It is innervated by glossopharyngeal nerve
 - (d) It acts as a pressure receptor
5. All of the following arteries are present in the carotid triangle **except**:
 - (a) Ascending pharyngeal artery
 - (b) Lingual artery
 - (c) Sublingual artery
 - (d) Facial artery
6. All of the following statements are true about the ansa cervicalis **except**:
 - (a) It is present in the region of carotid triangle
 - (b) It is formed by the ventral rami of C1, C2, and C3 spinal nerves
 - (c) It supplies all the infrahyoid muscles
 - (d) It is embedded in the anterior wall of the carotid sheath
7. 'Strap' muscles of the neck include all of the following muscles **except**:
 - (a) Sternocleidomastoid
 - (b) Sternothyroid
 - (c) Sternohyoid
 - (d) Thyrohyoid
8. Which of the following strap muscles of the neck can elevate the larynx if hyoid is fixed:
 - (a) Sternohyoid
 - (b) Omohyoid
 - (c) Sternothyroid
 - (d) Thyrohyoid
9. The thyrohyoid muscle is supplied by:
 - (a) Superior root of ansa cervicalis
 - (b) Inferior root of ansa cervicalis
 - (c) Ventral ramus of first cervical nerve through hypoglossal nerve
 - (d) Ventral ramus of first cervical nerve through superior laryngeal nerve
10. Hypoglossal nerve crosses superficial to all of the following arteries **except**:
 - (a) Internal carotid artery
 - (b) External carotid artery
 - (c) Facial artery
 - (d) Loop of lingual artery

Answers

1. *c*, 2. *c*, 3. *b*, 4. *b*, 5. *c*, 6. *c*, 7. *a*, 8. *d*, 9. *c*, 10. *c*

CHAPTER 7

1. All of the following nerves provide cutaneous innervation on the back of neck **except**:
 - (a) Lesser occipital nerve
 - (b) Greater occipital nerve
 - (c) Third occipital nerve
 - (d) Cutaneous branches of C4 and C5
2. Regarding ligamentum nuchae, all of the following statements are correct **except**:
 - (a) Its free posterior border extends from external occipital protuberance to the spine of the cervical vertebra
 - (b) It is better developed and more elastic in humans than in quadruped
 - (c) It forms the septum between the muscles of the two sides of the back of the neck
 - (d) It consists of a number of elastic fibres
3. From the following statements select the **incorrect statement** about the trapezius muscle:
 - (a) It arises from lateral third of the superior nuchal line
 - (b) Its lower part is inserted into the tubercle on the spine of scapula
 - (c) It is supplied by the spinal accessory nerve
 - (d) Its upper fibres help in shrugging the shoulder

4. The contents of suboccipital triangle includes all **except**:
- Third part of vertebral artery
 - Suboccipital nerve
 - Occipital artery
 - Suboccipital venous plexus
5. All of the following statements regarding suboccipital triangle are correct **except**:
- Its roof is covered by semispinalis capitis and longissimus capitis
 - Its floor is formed by anterior arch of the atlas
 - It is bounded inferiorly by oblique capitis inferior
 - It is bounded superolaterally by obliquus capitis superior
6. The dorsal ramus first cervical nerve supplies all of the following muscles **except**:
- Rectus capitis posterior major
 - Rectus capitis posterior minor
 - Semispinalis capitis
 - Splenius capitis
7. The joints of neck include all of the following varieties **except**:
- Symphyses
 - Syndesmoses
 - Sutures
 - Synovial
8. Select the **incorrect statement** about the intervertebral disc:
- Its outer part is made up of annulus fibrosus
 - Its inner part is made up of nucleus pulposus
 - It along with hyaline cartilages forms the intervertebral symphysis
 - It is thicker posteriorly in the cervical region
9. All of the following are **true statements** about the ligamentum nuchae **except**:
- Its posterior border extends from external occipital protuberance to the spine of C7
 - It is bilaminar in nature
 - It is predominantly made up fibroelastic tissue
 - It is weak in quadrupeds
10. Select the **incorrect statement** about the atlanto-occipital joints:
- They are synovial joints of ellipsoid variety
 - They are two in number
 - They are responsible for rotatory movements of the head
 - They are supplied by first cervical nerve
11. Select the **incorrect statement** about the median atlanto-axial joint:
- It is a synovial joint of pivot variety
 - It has two joint cavities
 - It is formed between the dens of axis and osseoligamentous ring formed by the anterior arch and transverse ligament of atlas
 - It is responsible for 'yes movement' of head
12. Select the **incorrect statement** about the atlantoaxial joints:
- They are 3 in number
 - Lateral atlantoaxial joints are synovial joints of plane variety
 - Median atlantoaxial joint is a synovial joint of pivot type
 - The movements at all the atlantoaxial joints do not occur simultaneously
13. Which of the following structures represents the remnant of notochord?
- Alar ligaments of dens
 - Membrana tectoria
 - Apical ligament of dens
 - Upper longitudinal band of transverse ligament of atlas

Answers

1. **a**, 2. **b**, 3. **a**, 4. **c**, 5. **b**, 6. **d**, 7. **c**, 8. **d**, 9. **d**, 10. **c**, 11. **d**, 12. **d**, 13. **c**

CHAPTER 8

1. The parotid gland develops from:
- Ectoderm
 - Endoderm
 - Mesoderm
 - None of the above
2. Select the **correct statement** about the parotid gland:
- It is located in the retromandibular fossa
 - It is composed mainly of mucous acini
 - It gets its secretomotor supply through facial nerve
 - It is devoid of capsule
3. All of the following structures emerge underneath the anterior border of the parotid gland **except**:
- Zygomatic branch of the facial nerve
 - Parotid duct
 - Retromandibular vein
 - Transverse facial vessels
4. All of the following structures lie within the parotid gland **except**:
- Facial nerve
 - Retromandibular vein

- (c) Internal carotid artery
(d) External carotid artery
5. All of the following structures are pierced by the parotid duct *except*:
- (a) Buccal pad of fat
(b) Buccinator muscle
(c) Pharyngobasilar fascia
(d) Buccopharyngeal fascia
6. Select the *incorrect statement* about the parotid duct:
- (a) It is 5 cm long
(b) It is also called Wharton duct
(c) It emerges from the middle of the anterior border of the parotid gland
(d) It turns inwards at the anterior border of masseter
7. The parotid duct opens in the vestibule of mouth opposite the crown of which of the following tooth:
- (a) Upper first molar
(b) Upper second molar
(c) Upper third molar
(d) Upper first premolar
8. The secretory function of parotid gland is likely to be affected by:
- (a) Severe or prolonged middle ear infection
(b) Facial nerve palsy
(c) Severing of the glossopharyngeal nerve as it winds around the stylopharyngeus muscle
(d) None of the above
9. The deep lamina of parotid capsule thickens to form:
- (a) Sphenomandibular ligament
(b) Stylohyoid ligament
(c) Stylomandibular ligament
(d) All of the above
10. The secretomotor fibres to the parotid are conveyed through the:
- (a) Greater superficial petrosal nerve
(b) Auriculotemporal nerve
(c) Chorda tympani nerve
(d) Pharyngeal branch of the glossopharyngeal nerve
11. Select the *incorrect statement* about the parotid capsule:
- (a) It is derived from investing layer of deep cervical fascia
(b) It consists of superficial and deep laminae
(c) Its superficial lamina is thick and unyielding
(d) It is derived from prevertebral layer of deep cervical fascia
12. Bony boundaries of the parotid bed are formed by all *except*:
- (a) Posterior border of the ramus of mandible
(b) Mastoid process
(c) Styloid process
(d) Internal acoustic meatus
13. 'Mixed parotid tumor' commonly involves:
- (a) Superficial part of the parotid gland including facial nerve
(b) Superficial part of the parotid gland without involving facial nerve
(c) Deep part of the parotid gland including facial nerve
(d) Deep part of the parotid gland without involving facial nerve

Answers

1. *a*, 2. *a*, 3. *c*, 4. *c*, 5. *c*, 6. *b*, 7. *b*, 8. *a*, 9. *c*, 10. *b*, 11. *d*, 12. *d*, 13. *b*

CHAPTER 9

1. Regarding digastric muscle, all of the following statement are true *except*:
- (a) Its posterior belly is bipinnate and is supplied by the facial nerve
(b) Its anterior belly is unipinnate and is supplied by the mandibular nerve
(c) Its intermedial tendon is anchored to hyoid bone of a fascial sling
(d) It helps to elevate the mandible
2. The superficial relation of hyoglossus muscle includes all *except*:
- (a) Lingual nerve
(b) Lingual artery
(c) Hypoglossal nerve
(d) Deep part of sublingual gland
3. All of the following structures pass deep to posterior border of hyoglossus *except*:
- (a) Glossopharyngeal nerve
(b) Stylohyoid muscle
(c) Stylohyoid ligament
(d) Lingual artery
4. All of the following statements regarding genioglossus muscle are correct *except*:
- (a) It arises from superior genial tubercle
(b) It is called 'safety-muscle' of the tongue
(c) It along with its counterpart of opposite side protrude the tongue
(d) It alone protrudes the tongue to the same side
5. The swellings of submandibular gland are bimanually palpable because:

- (a) It lies superficial to mylohyoid muscle outside the oral cavity
 (b) Its deep part lies in the oral cavity and superficial part outside the oral cavity
 (c) It is wedged between the mandible and mylohyoid muscle
 (d) It is immediately deep to the oral mucosa
6. Select the **incorrect statement** about the submandibular gland:
 (a) It develops from endoderm
 (b) It consists of superficial and deep parts
 (c) Its duct opens into the vestibule of the oral cavity
 (d) It is grooved by the facial artery
7. Which of the following nerves crosses the duct of the submandibular gland?
 (a) Glossopharyngeal nerve
 (b) Hypoglossal nerve
 (c) Lingual nerve
 (d) Chorda tympani nerve
8. Select the **correct statement** about the sublingual gland:
 (a) It is drained by a single duct
 (b) It lies inside the oral cavity between mucous membrane and genioglossus muscle
 (c) It receives postganglionic secretomotor fibres from otic ganglion
 (d) It is composed mainly of serous acini
9. The postganglionic secretomotor fibres to sublingual gland pass through which of the following nerves:
 (a) Lingual nerve
 (b) Chorda tympani nerve
 (c) Glossopharyngeal nerve
 (d) Hypoglossal nerve
10. A **correct statement** about the submandibular ganglion is:
 (a) It is functionally related to the facial nerve
 (b) It is situated on the inner surface of the hyoglossus muscle
 (c) It lies above the lingual nerve
 (d) It supplies preganglionic parasympathetic fibres to submandibular and sublingual salivary glands
- (b) It contains medial and lateral pterygoid muscles
 (c) It communicates with pterygopalatine fossa
 (d) It contains submandibular parasympathetic ganglion
2. All of the following structures occupy the infratemporal fossa **except**:
 (a) Mandibular nerve
 (b) Chorda tympani nerve
 (c) Pterygoid venous plexus
 (d) Masseter muscle
3. All of the following structures lie deep to lateral pterygoid muscle **except**:
 (a) Middle meningeal artery
 (b) Mandibular nerve
 (c) Superficial head of medial pterygoid
 (d) Sphenomandibular ligament
4. All of the following nerves derived from anterior division of the mandibular nerve are motor **except**:
 (a) Masseteric nerve
 (b) Buccal nerve
 (c) Nerve to lateral pterygoid
 (d) Deep temporal nerves
5. All of the following arteries arise from the first part of maxillary artery **except**:
 (a) Middle meningeal artery
 (b) Posterior superior alveolar artery
 (c) Inferior alveolar artery
 (d) Accessory middle meningeal artery
6. Select the **incorrect statement** about the otic ganglion:
 (a) It is functionally related to mandibular nerve
 (b) Its topographically related to mandibular nerve
 (c) It is 2–3 mm in size
 (d) It is located lateral to tensor palati muscle
7. Nerve to medial pterygoid supplies all of the following muscles **except**:
 (a) Tensor palati
 (b) Medial pterygoid
 (c) Lateral pterygoid
 (d) Tensor tympani
8. Select the **incorrect statement** about the temporomandibular joint:
 (a) It is synovial joint of condylar variety
 (b) Its cavity is divided into two compartments by an intra-articular disc
 (c) Its articular surfaces are covered by hyaline cartilage
 (d) It is innervated by auriculotemporal and masseteric nerves
9. Which of the following muscles opens the mouth:
 (a) Temporalis

Answers

1. **d**, 2. **b**, 3. **b**, 4. **d**, 5. **b**, 6. **c**, 7. **c**, 8. **b**, 9. **a**, 10. **a**

CHAPTER 10

1. Select the **incorrect statement** about the infratemporal fossa:
 (a) It is located deep to the ramus of mandible

9. Which of the following muscles opens the mouth:
 (a) Temporalis

- (b) Lateral pterygoid
 - (c) Medial pterygoid
 - (d) Posteriorly
10. The temporomandibular joint is commonly dislocated:
- (a) Medially
 - (b) Laterally
 - (c) Anteriorly
 - (d) Posteriorly

Answers

1. *d*, 2. *d*, 3. *c*, 4. *b*, 5. *b*, 6. *a*, 7. *c*, 8. *c*, 9. *b*, 10. *c*

CHAPTER 11

1. The *true statement* about the thyroid gland is:
- (a) It develops from the thyroglossal duct
 - (b) It lies opposite to C3–C7 cervical vertebrae
 - (c) Its isthmus lies opposite cricoid cartilage
 - (d) It is the least vascular endocrine gland in the body
2. Select the *incorrect statement* regarding the isthmus of thyroid gland:
- (a) It lies in front of the 2nd, 3rd, and 4th tracheal rings
 - (b) It connects the upper parts of the two lateral lobes of thyroid gland
 - (c) Its anterior surface is related to sternothyroid and sternohyoid muscles
 - (d) Anastomosis between the anterior branches of superior thyroid arteries lies along its upper border
3. The inferior thyroid artery is a branch of:
- (a) External carotid artery
 - (b) Internal carotid artery
 - (c) Thyrocervical trunk
 - (d) Brachiocephalic trunk
4. The suspensory ligaments of Berry are derived from:
- (a) Prevertebral fascia
 - (b) Pretracheal fascia
 - (c) Condensation of fibrous stroma of thyroid gland
 - (d) Investing layer of deep cervical fascia
5. The thyroid venous plexus lies:
- (a) Between true and false capsules of thyroid gland
 - (b) Deep to true capsule of thyroid gland
 - (c) Outside the false capsule of the gland
 - (d) Within the substance of the gland
6. The *true statement* regarding the inferior thyroid veins is that they:
- (a) Arise from the inferior poles of the thyroid lobes
 - (b) Arise from the isthmus of thyroid gland
 - (c) Drain into the internal jugular vein
 - (d) Drain into the right brachiocephalic vein

7. The medial surface of the thyroid lobe is related to all the following structures *except*:
- (a) Trachea
 - (b) Esophagus
 - (c) Carotid sheath
 - (d) Thyropharyngeus muscle
8. Select the *true statement* about the inferior parathyroid gland:
- (a) It develops from the third pharyngeal pouch
 - (b) It develops from the fourth pharyngeal pouch
 - (c) It is more constant in position as compared to the superior parathyroid gland
 - (d) It is closely related to external laryngeal nerve
9. Select the *true statement* about cervical part of trachea:
- (a) It extends from the lower border of cricoid cartilage to the superior border of manubrium sterni
 - (b) It is related to esophagus on its anterior aspect
 - (c) It is related on each side to the external laryngeal nerve
 - (d) It is related on its posterior aspect to the isthmus of the thyroid gland
10. Select the *incorrect statement* about the cervical part of esophagus:
- (a) It extends from the lower border of the cricoid cartilage to the superior border of the manubrium sterni
 - (b) Its lumen normally remains collapsed, except during swallowing
 - (c) It projects from behind the trachea on the left side
 - (d) It is supplied by the superior thyroid arteries

Answers

1. *a*, 2. *b*, 3. *c*, 4. *b*, 5. *b*, 6. *b*, 7. *c*, 8. *a*, 9. *a*, 10. *d*

CHAPTER 12

1. The prevertebral muscles include all of the following muscles *except*:
- (a) Longus colli
 - (b) Longus capitis
 - (c) Longissimus capitis
 - (d) Rectus capitis lateralis
2. The lateral vertebral group of muscles does not include:
- (a) Scalenus anterior
 - (b) Scalenus medius
 - (c) Scalenus posterior
 - (d) Levator scapulae
3. The key muscle at the root of neck is:
- (a) Scalenus anterior

- (b) Scalenus medius
 - (c) Scalenus posterior
 - (d) Longus cervicis
4. Select the **incorrect statement** about the scalenus anterior muscle:
- (a) Arises from anterior tubercles of the transverse processes of C3 to C6 vertebrae
 - (b) Is inserted on the scalene tubercle of first rib
 - (c) Lies superficial to prevertebral fascia
 - (d) Forms the lateral boundary of triangle of vertebral artery
5. All of the following structures form the boundary of scalenovertebral triangle **except**:
- (a) Lower oblique part of longus colli
 - (b) Medial border of scalenus anterior
 - (c) Transverse process C6 vertebra
 - (d) First rib
6. All of the following structures cross in front of the neck of first rib **except**:
- (a) Sympathetic chain
 - (b) First posterior intercostal vein
 - (c) First posterior intercostal artery
 - (d) First thoracic spinal nerve
7. Select the **incorrect statement** about the cervical plexus:
- (a) It is formed of the ventral rami of C1 to C4 cervical spinal nerves
 - (b) It is called plexus of loops
 - (c) It lies superficial to prevertebral fascia
 - (d) Its superficial branches are cutaneous in nature
8. All of the following statement about the cervical sympathetic trunk are true **except**:
- (a) It lies in front of the transverse processes of cervical vertebrae and neck of the first rib
 - (b) It receives the preganglionic fibre through the white rami communicates of cervical spinal nerves
 - (c) It possesses three ganglia
 - (d) Its injury leads to Horner's syndrome
9. Select the **incorrect statement** about the inferior cervical sympathetic ganglion:
- (a) It is formed by the fusion of 7th and 8th primitive cervical sympathetic ganglia
 - (b) It lies in front of transverse process of C6 vertebra
 - (c) It is also called stellate ganglion
 - (d) It is connected to middle cervical sympathetic ganglia by ansa cervicalis.

CHAPTER 13

1. All of the following glands pour their secretion into the vestibule of mouth **except**:
 - (a) Parotid glands
 - (b) Sublingual glands
 - (c) Labial and buccal mucous glands
 - (d) Molar glands
2. Select the **incorrect statement** about the lips:
 - (a) They bound the orifice of mouth
 - (b) They are lined externally by the skin and internally by the mucous membrane
 - (c) Their red portions are called vermillion zones
 - (d) Lymphatics from lateral part of lower lip drain into submental lymph nodes
3. Which of the following types of teeth are not found in deciduous dentition?
 - (a) Incisors
 - (b) Canines
 - (c) Premolars
 - (d) Molars
4. All of the following tissues develop from neural crest cells **except**:
 - (a) Enamel
 - (b) Dentin
 - (c) Dental pulp
 - (d) Cementum
5. Select the **incorrect statement** above the gums:
 - (a) They are composed of fibrous tissue covered with a vascular mucous membrane
 - (b) They envelop the roots of teeth
 - (c) Fibrous tissue of gum becomes continuous with the periodontal membrane
 - (d) Lymphatic from gums drains into submental and submandibular lymph nodes
6. Select the **incorrect statement** about the root of the tongue:
 - (a) It is the part of tongue that rests on the floor of the mouth
 - (b) It is attached by the extrinsic muscles to the mandible and hyoid bone
 - (c) The nerves and vessels of tongue enter or leave through the root
 - (d) It is attached by the intrinsic muscles to the mandible and hyoid bone
7. All the muscles of the tongue are supplied by the hypoglossal nerve **except**:
 - (a) Palatoglossus
 - (b) Styloglossus

Answers

1. c, 2. d, 3. a, 4. c, 5. d, 6. c, 7. c, 8. b, 9. b

- (c) Hyoglossus
(d) Genioglossus
8. All of the following cranial nerves carry taste sensations from tongue *except*:
- (a) Facial nerve
(b) Glossopharyngeal nerve
(c) Vagus nerve
(d) Hypoglossal nerve
9. The most abundant papillae on the dorsum of tongue are:
- (a) Filiform
(b) Fungiform
(c) Foliate
(d) Vallate
10. The pain from tongue is referred to the ear through:
- (a) Mandibular nerve
(b) Facial nerve
(c) Glossopharyngeal nerve
(d) Hypoglossal nerve
- (a) Salpingopharyngeus
(b) Stylopharyngeus
(c) Palatopharyngeus
(d) Thyropharyngeus
6. All of the following structures pass between the base of the skull and upper border of superior constrictor *except*:
- (a) Auditory tube
(b) Levator palati muscle
(c) Tensor palati muscle
(d) Ascending palatine artery
7. Motor nerve supply of pharyngeal muscles is derived from:
- (a) Vagoaccessory complex
(b) Glossopharyngeal nerve
(c) External laryngeal nerve
(d) All of the above
8. Inferior constrictor of pharynx is supplied by all of the following nerves *except*:
- (a) Pharyngeal plexus
(b) Glossopharyngeal nerve
(c) External laryngeal nerve
(d) Recurrent laryngeal nerve

Answers

1. *b*, 2. *d*, 3. *c*, 4. *a*, 5. *b*, 6. *d*, 7. *a*, 8. *d*, 9. *a*, 10. *a*

CHAPTER 14

1. Select the *incorrect statement* about the pharynx:
- (a) It extends from base of skull to the lower border of C6 vertebra
(b) It lies behind the nasal, oral, and laryngeal cavities
(c) It is about 25 cm long
(d) It is a common channel for both deglutition and respiration
2. The pharyngeal wall consists of all the following *except*:
- (a) Mucous membrane
(b) Pharyngobasilar fascia
(c) Buccopharyngeal fascia
(d) Prevertebral fascia
3. The weakest region in the posterior pharyngeal wall is between:
- (a) Superior and middle constrictors
(b) Middle and inferior constrictors
(c) Thyropharyngeus and cricopharyngeus
(d) Inferior constrictor and esophagus
4. All of the following are features of nasopharynx *except*:
- (a) Pharyngeal tonsil
(b) Tubal tonsil
(c) Pharyngeal recess
(d) Piriform recess
5. The Passavant's ridge is formed by:
- (a) Pharyngobasilar fascia
(b) Stylopharyngeus
(c) Superior constrictor
(d) Styloglossus
9. Select the *incorrect statement* about the palatine tonsil:
- (a) It is located in the lateral wall of oropharynx
(b) Its medial surface is lined by keratinized stratified squamous epithelium
(c) Its lateral surface is covered by a capsule
(d) Its apex extends upwards into the soft palate
10. Tonsillar-bed is formed by all of the following structures *except*:
- (a) Pharyngobasilar fascia
(b) Stylopharyngeus
(c) Superior constrictor
(d) Styloglossus
11. Select the *incorrect statement* about the pharyngo-tympanic tube:
- (a) It is about 36 mm long
(b) Its tympanic end is wider than its pharyngeal end
(c) It is lined by pseudostratified ciliated columnar epithelium
(d) It maintains the equilibrium of air pressure on each side of tympanic membrane
12. Median cleft of upper lip occurs if:
- (a) Maxillary process fails to fuse with frontonasal process
(b) Both maxillary processes do not fuse with philtrum
(c) Philtrum fails to develop from frontonasal process
(d) Mandibular processes fail to fuse with each other

Answers

1. *c*, 2. *d*, 3. *c*, 4. *d*, 5. *c*, 6. *c*, 7. *d*, 8. *b*, 9. *b*, 10. *b*, 11. *b*, 12. *c*

CHAPTER 15

- Which of the following cartilages completely encircle the laryngeal cavity?
 - Thyroid
 - Cricoid
 - Epiglottis
 - Arytenoid
- All of the following cartilages of larynx are composed of hyaline cartilage *except*:
 - Epiglottis
 - Thyroid
 - Cricoid
 - Arytenoid (basal part)
- All of the following structures form the boundaries of laryngeal inlet *except*:
 - Epiglottis
 - Interarytenoid fold
 - Lamina of thyroid cartilage
 - Aryepiglottic fold
- Select the *incorrect statement* about the cricothyroid muscle:
 - It is placed externally on the laryngeal wall
 - It tenses the vocal cord
 - It is supplied by the internal laryngeal nerve
 - It causes adduction of vocal cord
- Select the *incorrect statement* about the vocal cord:
 - It is made up of vocal ligament
 - It is devoid of mucous glands
 - It extends between arytenoid and epiglottis
 - It is lined by stratified squamous epithelium
- The space between the right and left vocal fold is called:
 - Vestibule
 - Rima vestibuli
 - Ventricle
 - Rima glottidis
- All of the following muscles adduct the vocal folds *except*:
 - Lateral cricoarytenoid
 - Posterior cricoarytenoid
 - Thyroarytenoid
 - Interarytenoid
- Select the *correct statement* about the cricothyroid joint:
 - It is a synovial joint

- It is a primary cartilaginous joint
- It is a secondary cartilaginous joint
- It is a fibrous joint

- The vocal folds lie in cadaveric position if:
 - Internal laryngeal nerves of both sides are involved
 - External laryngeal nerves of both sides are involved
 - External laryngeal nerve of right side and internal laryngeal nerve of left side are involved
 - External and internal laryngeal nerves of both sides are involved
- All of following areas are covered by stratified squamous epithelium *except*:
 - Anterior surface of epiglottis
 - Lower half of the posterior surface of epiglottis
 - Upper parts of aryepiglottic folds
 - Vocal folds

Answers

1. *b*, 2. *a*, 3. *c*, 4. *c*, 5. *c*, 6. *d*, 7. *b*, 8. *a*, 9. *d*, 10. *b*

CHAPTER 16

- Which of the following statements is not correct regarding the subclavian arteries?
 - They are the principal source of arterial supply to the upper limbs
 - Right subclavian artery arises from brachiocephalic trunk
 - Left subclavian artery arises from the arch of aorta
 - Both the subclavian arteries have thoracic as well as cervical part
- All of the following arteries arise from the first part of subclavian artery *except*:
 - Thyrocervical trunk
 - Dorsal scapular artery
 - Internal mammary artery
 - Vertebral artery
- Vertebral artery does not pass through the foramen transversarium of:
 - First cervical vertebra
 - Second cervical vertebra
 - Sixth cervical vertebra
 - Seventh cervical vertebra
- All of the following arteries arise from thyrocervical trunk *except*:
 - Inferior thyroid artery
 - Suprascapular artery
 - Dorsal scapular artery
 - Superficial cervical artery

5. The subclavian artery is divided into three parts by:
- Scalenus posterior muscle
 - Scalenus medius muscle
 - Scalenus anterior muscle
 - Scalenus minimus muscle
6. Select the **true statement** about the vertebral artery:
- It is the smallest branch of the subclavian artery
 - It traverses foramen transversaria of all cervical vertebrae except that of C1
 - It does not give any branch in the neck
 - It winds backwards around the lateral mass of the first cervical vertebra.
7. Select the **incorrect statement** about the carotid sinus:
- It is a dilatation at the beginning of internal carotid artery
 - It acts as a chemoreceptor
 - It is innervated by glossopharyngeal nerve
 - It regulates the blood pressure in the cerebral arteries.
8. The cervical part of facial artery gives all of the following branches **except**:
- Inferior alveolar artery
 - Tonsillar artery
 - Glandular branches to submandibular gland
 - Submental artery
9. The cerebral part of internal carotid artery gives all of the following branches **except**:
- Anterior cerebral artery
 - Posterior communicating artery
 - Posterior choroidal artery
 - Middle cerebral artery
10. Select the **incorrect statement** about the internal jugular vein:
- It begins as the direct continuation of sigmoid sinus
 - It presents two dilatations
 - It is crossed by two muscles on its superficial aspect
 - Its lower part lies in the greater supraclavicular fossa
- Middle meatus of the nose
 - Superior meatus of the nose
 - Inferior meatus of the nose
 - Vestibule of the nose
3. All of the following structures form nasal septum **except**:
- Perpendicular plate of ethmoid
 - Perpendicular plate of palatine
 - Vomer
 - Septal cartilage
4. All are parts of ethmoid bone **except**:
- Superior nasal concha
 - Middle nasal concha
 - Inferior nasal concha
 - Cribriform plate
5. The chief artery supplying the nasal mucosa is:
- Greater palatine
 - Sphenopalatine
 - Anterior ethmoidal
 - Posterior ethmoidal
6. All arteries take part in the formation of Kiesselbach's plexus **except**:
- Septal branch of sphenopalatine
 - Septal branch of greater palatine
 - Septal branch of posterior ethmoidal
 - Septal branch of anterior ethmoidal
7. The chief nerve providing innervation to the nasal mucosa is:
- Anterior ethmoidal
 - Greater palatine
 - Nasopalatine
 - Posterior ethmoidal
8. The infection from the nasal cavity may spread to all of the following regions **except**:
- Conjunctival sac
 - Paranasal air sinuses
 - Internal ear
 - Anterior cranial fossa
9. The **incorrect statement** about nasal mucosa is that it is:
- Lined by pseudostratified ciliated columnar epithelium
 - Loosely adherent to the nasal septum
 - Lined by olfactory epithelium
 - Richly supplied with blood and contains cavernous spaces
10. The artery called rhinologist's artery is a septal branch of:
- Anterior ethmoidal artery

Answers

1. **d**, 2. **b**, 3. **d**, 4. **c**, 5. **c**, 6. **d**, 7. **b**, 8. **a**, 9. **c**, 10. **d**

CHAPTER 17

1. The olfactory receptor cells are:

- Unipolar neurons
- Bipolar neurons
- Pseudounipolar neurons
- Multipolar neurons

2. The nasolacrimal duct opens into:

- (b) Superior labial artery
 - (c) Greater palatine artery
 - (d) Sphenopalatine artery
11. All of the following sinuses open into hiatus semilunaris *except*:
- (a) Frontal
 - (b) Anterior ethmoidal
 - (c) Middle ethmoidal
 - (d) Maxillary
12. The sinus that drains by gravity when the head is erect is:
- (a) Sphenoidal
 - (b) Frontal
 - (c) Maxillary
 - (d) None of above
13. The *incorrect statement* about maxillary sinus is that:
- (a) It is first sinus to develop
 - (b) It is the largest air sinus
 - (c) It is rarely affected by the sinusitis
 - (d) Its ostium lies near the roof
14. The size of the maxillary hiatus is reduced by all of the following bones *except*:
- (a) Ethmoid
 - (b) Sphenoid
 - (c) Lacrimal
 - (d) Inferior nasal concha
15. Toothache in maxillary sinusitis occurs due to stimulation of:
- (a) Inferior alveolar nerve
 - (b) Superior alveolar nerves
 - (c) Greater palatine nerve
 - (d) Nasopalatine nerve
16. All of the following structures open into the middle meatus of nose *except*:
- (a) Frontonasal duct
 - (b) Anterior ethmoidal air sinus
 - (c) Middle ethmoidal air sinus
 - (d) Nasolacrimal duct
17. The postural drainage of maxillary sinus is best when:
- (a) The head is erect
 - (b) Lying on the affected side
 - (c) Lying on the unaffected side
 - (d) Head is tilted forwards
18. Which is an independent bone:
- (a) Superior nasal concha
 - (b) Middle nasal concha
 - (c) Inferior nasal concha
 - (d) Cribriform plate

19. All the statements about sphenoidal air sinus are correct *except*:
- (a) It drains into sphenoidal recess
 - (b) It lies above and behind the nasal cavity
 - (c) It is related laterally to the cavernous sinus
 - (d) It drains into middle meatus
20. Select the *incorrect statement* about the maxillary sinus:
- (a) Its floor is formed by the lateral wall of the nose
 - (b) It is the largest air sinus
 - (c) Its apex extends into the zygomatic process
 - (d) It is most commonly infected of all the sinuses

Answers

1. *b*, 2. *c*, 3. *b*, 4. *c*, 5. *b*, 6. *c*, 7. *c*, 8. *c*, 9. *b*, 10. *d*, 11. *c*, 12. *b*, 13. *c*, 14. *b*, 15. *b*, 16. *d*, 17. *c*, 18. *c*, 19. *d*, 20. *a*

CHAPTER 18

1. Select the *incorrect statement* about the auricle of the ear:
- (a) Its skeleton is made up of yellow-elastic cartilage
 - (b) Its skeleton is made up of fibrocartilage
 - (c) Its lobule is devoid of cartilage
 - (d) Thick hair on auricle in males represents Y-linked inheritance
2. All of the following nerves provide sensory innervation to the pinna/auricle of the external ear *except*:
- (a) Great auricular nerve
 - (b) Greater occipital nerve
 - (c) Auriculo-temporal nerve
 - (d) Alderman's nerve
3. The lateral surface of the auricle presents all of the following features *except*:
- (a) Tragus
 - (b) Cymba conchae
 - (c) Eminentia triangularis
 - (d) Concha
4. Select the *incorrect statement* about the external auditory meatus:
- (a) It measures about 24 mm along its posterior wall
 - (b) Its outer one-third is bony and inner two-third is cartilaginous
 - (c) It is narrowest where the bony and cartilaginous parts meet
 - (d) Its floor is longer than its roof
5. Select the *incorrect statement* about the tympanic membrane:
- (a) Its lateral surface is concave

- (b) Its point of maximum convexity on medial surface is called umbo
- (c) It provides attachment to the handle of malleus
- (d) It forms an obtuse angle with the floor of external auditory meatus
6. Embryologically the tympanic membrane is derived from:
- (a) Ectoderm
- (b) Mesoderm
- (c) Endoderm
- (d) All of the above
7. Which of the following quadrants of tympanic membrane is relatively safe for giving surgical incision to drain pus from middle ear?
- (a) Antero-superior
- (b) Postero-superior
- (c) Antero-inferior
- (d) Postero-inferior
8. The contents of middle ear include all *except*:
- (a) Tensor tympani
- (b) Tegmen tympani
- (c) Chorda tympani
- (d) Tympanic plexus
9. All of the following structures are of an adult size at birth *except*:
- (a) External ear
- (b) Middle ear
- (c) Internal ear
- (d) Ear ossicles
10. Medial wall of the middle ear presents all of the following features *except*:
- (a) Oval window
- (b) Round window
- (c) Pyramidal prominence
- (d) Prominence of lateral semicircular canal
11. The membranous labyrinth of internal ear consists of all *except*:
- (a) Cochlear canal
- (b) Utricle
- (c) Saccule
- (d) Cochlear duct
12. The organ of Corti is located within:
- (a) Semicircular ducts
- (b) Utricle
- (c) Saccule
- (d) Cochlear duct
13. Select the *incorrect statement* about the internal ear:
- (a) Sensory receptor for hearing is located in the cochlear duct
- (b) Sensory receptors for static balance are located in the saccule and utricle
- (c) Sensory receptors for kinetic balance are located in the semicircular canals
- (d) Sensory receptor, for kinetic balance is maculae
14. All of the following structures are components of spiral organ of Corti, *except*:
- (a) Tunnel of Corti
- (b) Hair cells
- (c) Dieter's cell
- (d) Otolith membrane

Answers

1. *b*, 2. *b*, 3. *c*, 4. *b*, 5. *d*, 6. *d*, 7. *d*, 8. *b*, 9. *a*, 10. *c*, 11. *a*, 12. *d*, 13. *d*, 14. *d*

CHAPTER 19

1. The medial wall of the bony orbit is formed by all of the following bones *except*:
- (a) Frontal process of maxilla
- (b) Lacrimal bone
- (c) Orbital surface of the greater wing of sphenoid
- (d) Orbital plate of the ethmoid
2. Which of the following nerves lies in the orbit outside the orbital periosteum (or periorbita):
- (a) Oculomotor
- (b) Trochlear
- (c) Abducent
- (d) Zygomatic
3. Select the *incorrect statement* about the levator palpebrae superioris:
- (a) It arises from the under surface of the greater wing of sphenoid near the apex of the orbit
- (b) It is supplied by oculomotor nerve and cervical sympathetic fibres
- (c) Its paralysis causes ptosis
- (d) It consists of both voluntary and involuntary muscle fibres
4. Select the *incorrect statement* about the ciliary ganglion:
- (a) It lies between the optic nerve and lateral rectus near the apex of the orbit
- (b) It is functionally connected to the oculomotor nerve
- (c) It lies between optic nerve and medial rectus near the apex of the orbit
- (d) Topographically it is connected to the nasociliary nerve

5. All of the following statements regarding cornea are correct *except*:
 - (a) It forms the anterior one-sixth of the outer coat of the eyeball
 - (b) It consists of five layers
 - (c) Its refractive power is less than that of the lens
 - (d) It is devoid of blood and lymph vessels
6. The (refractive apparatus) of eye consists of all of the following structures *except*:
 - (a) Cornea
 - (b) Iris
 - (c) Lens
 - (d) Vitreous body
7. The uveal tract consists of all of the following structures *except*:
 - (a) Choroid
 - (b) Ora serrata
 - (c) Ciliary body
 - (d) Iris
8. Which of the following branches of the ophthalmic artery is most important?
 - (a) Lacrimal artery
 - (b) Central artery of retina
 - (c) Supraorbital artery
 - (d) Supratrochlear artery
9. All of the following muscles of eyeball are supplied by the oculomotor nerve *except*:
 - (a) Superior rectus
 - (b) Superior oblique
 - (c) Inferior rectus
 - (d) Inferior oblique
10. All of the following structures are derived from Tenon's capsule *except*:
 - (a) Medial check ligament
 - (b) Lateral check ligament
 - (c) Lacrimal fascia
 - (d) Ligament of Lockwood
2. Select the *incorrect statement* about the internal vertebral venous plexus:
 - (a) It is a network of veins in the subdural space
 - (b) It receives basivertebral veins
 - (c) It drain into segmental veins
 - (d) It continuous with the intracranial dural venous sinuses
3. All of the following statements are true regarding the spinal dura *except*:
 - (a) The spinal dura consists of single layer
 - (b) The lower end of spinal dura is pierced by the filum terminale
 - (c) The spinal dura consists of two layers
 - (d) The spinal dura end below at the level of S2 vertebra
4. Select the *incorrect statement* about the spinal cord:
 - (a) Its average length is about 45 cm
 - (b) Its average length is about 35 cm
 - (c) In adults its lower end extends up to the lower border of L1 vertebra
 - (d) In foetus its lower end extends up to the lower border of S2 vertebra
5. The total number of spinal segments is:
 - (a) 30
 - (b) 31
 - (c) 32
 - (d) 33
6. Regarding cervical enlargement of spinal cord, which of the following statement is not correct?
 - (a) It extends from C5 to T1 spinal segments
 - (b) Its vertebral level extends from C5 to T1 vertebrae
 - (c) Its vertebral level extends from C3 to T1 vertebrae
 - (d) The spinal nerves arising from cervical enlargement supply upper limbs
7. Which of the following statements is *not correct* regarding the anterior spinocerebellar tract?
 - (a) It carries unconscious proprioceptive sensations from spinal cord to cerebellum
 - (b) The cell bodies of its second order sensory neurons lie in the nucleus dorsalis (Clarke's column)
 - (c) Its fibres enter the cerebellum through inferior cerebellar peduncle
 - (d) Its fibres enter the cerebellum through superior cerebellar peduncle
8. Select the *incorrect statement* regarding the fasciculus gracilis and fasciculus cuneatus:
 - (a) They carry conscious proprioceptive sensations
 - (b) They are formed by axons arising from cells in nucleus dorsalis

Answers

1. *c*, 2. *d*, 3. *a*, 4. *c*, 5. *c*, 6. *b*, 7. *b*, 8. *b*, 9. *a*, 10. *c*

CHAPTER 20

1. The contents of vertebral canal include all of the following structures *except*:
 - (a) Spinal nerve roots
 - (b) Spinal cord
 - (c) Spinal ganglia
 - (d) Spinal meninges
8. Select the *incorrect statement* regarding the fasciculus gracilis and fasciculus cuneatus:
 - (a) They carry conscious proprioceptive sensations
 - (b) They are formed by axons arising from cells in nucleus dorsalis

- (c) They are formed by axons arising from cells in the posterior root ganglia
- (d) Their fibres terminate in the nucleus gracilis and nucleus cuneatus within the medulla

Answers

1. *c*, 2. *a*, 3. *c*, 4. *b*, 5. *b*, 6. *b*, 7. *c*, 8. *b*

CHAPTER 21

1. All of the following statements about diploic veins are correct *except*:
 - (a) They drain blood from spongy bones skull-vault
 - (b) They mostly drain into intracranial dural venous sinuses
 - (c) They possess valves in their lumen
 - (d) There are only four pairs of recognizable diploic veins
2. Commonest site of fracture of the base of skull is
 - (a) Anterior cranial fossa
 - (b) Middle cranial fossa
 - (c) Posterior cranial fossa
 - (d) None of the above
3. Select the *incorrect statement* about the dural venous sinuses:
 - (a) They are lined by endothelium
 - (b) They have no valves
 - (c) They communicate with extracranial veins
 - (d) They possess thin muscle coat in their wall
4. All of the following dural venous sinuses are paired *except*:
 - (a) Superior petrosal
 - (b) Inferior petrosal
 - (c) Inferior sagittal
 - (d) Cavernous
5. Lateral wall of cavernous contains all of the following nerves *except*:
 - (a) Oculomotor
 - (b) Trochlear
 - (c) Ophthalmic
 - (d) Abducent
6. Which of the following dural venous sinuses is more likely to be affected in mastoiditis?
 - (a) Superior petrosal
 - (b) Inferior petrosal
 - (c) Sigmoid
 - (d) Transverse
7. All of the following dural venous sinuses lie in between the two layers of dura mater *except*:
 - (a) Superior sagittal sinus
 - (b) Inferior sagittal sinus
 - (c) Superior petrosal sinus
 - (d) Inferior petrosal sinus
8. Regarding pituitary gland all of the following statements are correct *except*:
 - (a) It lies in the sella turcica
 - (b) It develops from two different sources
 - (c) It is supplied by branches of middle meningeal artery
 - (d) It is related on each side to the cavernous sinus
9. All of the following hormones are secreted by adenohypophysis *except*:
 - (a) Growth hormone
 - (b) Prolactin
 - (c) Oxytocin
 - (d) ACTH
10. Which of the following hormones is secreted by pars intermedia of pituitary gland?
 - (a) Oxytocin
 - (b) Melanocyte stimulating hormone (MSH)
 - (c) Antidiuretic hormone (ADH)
 - (d) Vasopressin

Answers

1. *c*, 2. *b*, 3. *d*, 4. *c*, 5. *d*, 6. *c*, 7. *b*, 8. *c*, 9. *c*, 10. *b*

CHAPTER 22

1. All of the following structures pass through jugular foramen *except*:
 - (a) Glossopharyngeal nerve
 - (b) Vagus nerve
 - (c) Inferior petrosal sinus
 - (d) Hypoglossal nerve
2. All of the following muscles are not supplied by glossopharyngeal nerve *except*:
 - (a) Palatopharyngeus
 - (b) Salpingopharyngeus
 - (c) Stylopharyngeus
 - (d) Superior constrictor of pharynx
3. Select the *incorrect statement* about glossopharyngeal nerve:
 - (a) It arises from medulla oblongata
 - (b) It supplies only one muscle
 - (c) It is involved in 'gag reflex'
 - (d) It carries taste sensations from anterior two-third of the tongue

4. Select the **incorrect statement** about vagus nerve:
- It carries taste sensation from posteriormost part of the tongue
 - It provides secretomotor fibres to the gland of respiratory and digestive tracts
 - It is the largest cranial nerve
 - It carries general sensations from the skin of auricle
5. The functional components of vagus nerve include all of the following **except**:
- General visceral efferent (GVE)
 - Special visceral efferent (SVE)
 - General somatic afferent (GSA)
 - Special somatic afferent (SSA)
6. All of the following branches of left vagus nerve arise in the neck **except**:
- Pharyngeal branch
 - Branches to carotid sinus and carotid body
 - Recurrent laryngeal nerve
 - Cardiac branches
7. Bilateral lesions of vagus nerve will cause all of the following signs **except**:
- Nasal regurgitation of swallowed liquids
 - Nasal twang of voice
 - Soft palate rises in midline
 - Flattening of palatal arches
8. Select the **incorrect statement** about accessory nerve:
- Its both roots arise from medulla oblongata
 - Its cranial root is distributed through vagus nerve
 - Its spinal root supplies sternocleidomastoid and trapezius muscles
 - It exits from skull through jugular foramen
9. Cranial root of the accessory nerve supplies all of the following muscles of palate through pharyngeal plexus **except**:
- Tensor palati
 - Palatopharyngeus
 - Salpingopharyngeal muscle
 - Palatoglossus
10. Select the **incorrect statement** about hypoglossal nerve:
- Its rootlets arise from anterolateral sulcus of the medulla oblongata
 - It supplies all the muscles of tongue **except** palatoglossus
 - It lies deep to internal and external carotid arteries
 - It exits from skull through anterior condylar canal
11. In lesions of right hypoglossal nerve:

- Tongue deviates to left side on protrusion
- Tongue fails to protrude at all
- None of the above

Answers

1. **d**, 2. **c**, 3. **d**, 4. **c**, 5. **d**, 6. **c**, 7. **c**, 8. **a**, 9. **a**, 10. **c**, 11. **a**

CHAPTER 23

1. The brainstem consists of all of the following components **except**:
- Midbrain
 - Pons
 - Medulla oblongata
 - Cerebellum
2. Regarding cavities of brain, all of the following statements are correct **except**:
- Right and left lateral ventricles are cavities within the right and left cerebral hemispheres, respectively
 - Third ventricle is the cavity within diencephalon
 - Cerebral aqueduct is the cavity within the pons
 - Fourth ventricle is the cavity within the hindbrain
3. Which of the following subarachnoid cisterns is largest?
- Interpeduncular cistern
 - Cisterna ambiens
 - Pontine cistern
 - Cerebellomedullary cistern
4. The term **tela choroidea** refers to:
- Ependymal element of choroid plexus
 - Pial element of choroid plexus
 - Vascular tufts of choroid plexus
 - None of the above
5. Regarding brain, which of the following statements is **not correct**:
- Cerebrum is the largest part of the brain
 - Cerebellum is the second largest part of the brain
 - Midbrain passes through tentorial notch to join hindbrain with the forebrain
 - The term brainstem is usually applied to diencephalon, midbrain and pons
6. The cerebrospinal fluid (CSF) is formed mainly by:
- Choroid plexuses within the lateral ventricles
 - Choroid plexus within the 3rd ventricle
 - Choroid plexus within the 4th ventricle
 - Ependyma of the ventricles

Answers

1. **d**, 2. **c**, 3. **d**, 4. **b**, 5. **d**, 6. **a**

CHAPTER 24

- All of the following statements are true regarding medulla oblongata *except*:
 - It is the part of brainstem between pons and spinal cord
 - It passes through foramen magnum to the level of atlas
 - It is traversed by the central canal throughout its extent
 - Hypoglossal nerve arises from its anterior to the olive
- Transverse section of the medulla of the level of olives shows all of the following nuclei *except*:
 - Hypoglossal nucleus
 - Nucleus of tractus solitarius
 - Nucleus cuneatus
 - Nucleus ambiguus
- Select the *incorrect statement* about the medial lemniscus:
 - It consists of fibres arising from nucleus gracilis and nucleus cuneatus
 - It forms a part of the auditory pathway
 - It conducts conscious proprioceptive sensations from opposite half of the body
 - Its fibres terminate in the thalamus
- Regarding pons, all of the following statements are correct *except*:
 - Median sulcus on its ventral surface lodges the basilar artery
 - The structure of basilar part is identical throughout its extent
 - Its dorsal part is continuous above with the tegmentum of the midbrain
 - It receives afferent fibres from the cerebellum through middle cerebellar peduncle
- All of the following nuclei are found in pons at the level of facial colliculus *except*:
 - Abducent nucleus
 - Motor nucleus of trigeminal nerve
 - Motor nucleus of the facial nerve
 - Cochlear nuclei
- The cerebral peduncle consists of all of the following parts *except*:
 - Crus cerebri
 - Substantia nigra
 - Tegmentum
 - Tectum

Answers

1. *c*, 2. *c*, 3. *b*, 4. *d*, 5. *b*, 6. *d*

CHAPTER 25

- Select the *incorrect statement* about the cerebellum:
 - It is the second largest part of the brain
 - It accounts for about 10% of the total weight of the brain
 - It is connected to the midbrain through middle cerebellar peduncle
 - It consists of two hemispheres which are united in the midline by vermis
- Select the *incorrect statement* about the archicerebellum:
 - Phylogenetically, it is the oldest part of the cerebellum
 - It consists of flocculonodular lobe and lingula
 - It is primarily concerned with smooth performance of fine voluntary movements
 - It is primarily concerned with maintenance of the equilibrium
- The neocerebellum is primarily concerned with:
 - Maintenance of equilibrium
 - Smooth performance of fine voluntary movements
 - Regulating muscle tone and posture of the trunk
 - Regulating muscle tone and posture of the limbs
- All of the following are intracerebellar nuclei *except*:
 - Dentate nucleus
 - Fastigial nucleus
 - Globose nucleus
 - Red nucleus
- Regarding dentate nucleus of the cerebellum, all of the following statements are correct *except*:
 - It is the largest intracerebellar nucleus
 - Its efferent fibres forms most of the superior cerebellar peduncle
 - It receives afferent fibres mainly from paleocerebellum
 - It receives afferent fibres mainly from neocerebellum
- The cerebellar lesion is characterized by all of the following signs/symptoms *except*:
 - Ataxia
 - Muscular hypotonia
 - Nystagmus
 - Tremors at rest

Answers

1. *c*, 2. *c*, 3. *b*, 4. *d*, 5. *c*, 6. *d*

CHAPTER 26

- All of the following are subdivisions of diencephalon *except*:
 - Thalamus
 - Mamillary bodies
 - Metathalamus
 - Subthalamus
- Which of the following structures is not a part of the thalamus?
 - Medial geniculate body
 - Lateral geniculate body
 - Pineal body
 - Pulvinar
- The Y-shaped sheet of white matter that divides thalamus into its three main parts (anterior, medial, and lateral) is called:
 - Lamina terminalis
 - Stria medullaris thalami
 - Internal medullary lamina
 - Lamina cribrosa
- Which of the following is the largest somatosensory nucleus of the thalamus?
 - Ventral anterior
 - Ventral lateral
 - Ventral posterior
 - Lateral posterior
- Regarding pineal gland, which of the following statements is *not correct*?
 - It is a neuroendocrine gland
 - It secretes melatonin hormone
 - Its influence on other endocrine glands is excitatory
 - It is the only part of brain which does not consist of neural tissue
- All of the following statements about hypothalamus are correct *except*:
 - It forms the floor of the 3rd ventricle
 - It weighs about 4 g
 - It is regarded as the head ganglion of the autonomic nervous system
 - It is bounded anteriorly by lamina cribrosa
- Anatomically, which of the following regions does not belong to the hypothalamus?
 - Supraoptic region
 - Pre-optic region
 - Tuberal region
 - Mamillary region

Answers

1. *b*, 2. *c*, 3. *c*, 4. *c*, 5. *c*, 6. *d*, 7. *b*

CHAPTER 27

- Select the *incorrect statement* about the longitudinal cerebral fissure:
 - It completely separates the two cerebral hemispheres
 - It lodges the falx cerebri
 - It incompletely separates the two cerebral hemispheres
 - It lodges anterior cerebral vessels
- Which of the following structures represents the submerged portion of the cerebral cortex?
 - Fronto-parietal operculum
 - Insula
 - Hippocampus
 - Temporal operculum
- The paracentral lobule is located on:
 - Medial surface of the cerebral hemisphere
 - Superolateral surface of the cerebral hemisphere
 - Tentorial surface of the cerebral hemisphere
 - Orbital surface of the cerebral hemisphere
- The area between parieto-occipital and calcarine sulci on the medial surfaces of the cerebral hemisphere is known as:
 - Paracentral lobule
 - Cuneus
 - Precuneus
 - Isthmus
- Regarding Broca's area, which of the following statements is *not correct*?
 - It is located in the inferior frontal gyrus of the left cerebral hemisphere
 - It is supply of anterior cerebral artery
 - It is numbered as areas 45, 44
 - Its damage leads to motor aphasia
- All of the following are the examples of bundles of commissural fibres *except*:
 - Corpus callosum
 - Interthalamic adhesion
 - Anterior commissure
 - Habenular commissure
- Which of the following structures consists of both projection and commissural fibres?
 - Internal capsule
 - Pyramid

- (c) Cerebral fornix
- (d) Crus cerebri

Answers

1. **a**, 2. **b**, 3. **a**, 4. **b**, 5. **b**, 6. **b**, 7. **c**

CHAPTER 28

1. Basal nuclei include all of the following structures *except*:

- (a) Corpus striatum
- (b) Claustrum
- (c) Habenular nucleus
- (d) Amygdaloid body

2. Corpus striatum includes all of the following *except*:

- (a) Caudate nucleus
- (b) Putamen
- (c) Globus pallidus
- (d) Amygdala

3. Select the *incorrect statement* about the caudate nucleus:

- (a) It is comma-shaped mass of grey matter
- (b) Its head becomes continuous with thalamus
- (c) Its tail ends in relation to amygdaloid body
- (d) It represents part of neostriatum

4. Deficiency of which of the following neurotransmitters occurs in Parkinsonism:

- (a) GABA
- (b) Serotonin
- (c) Acetylcholine
- (d) Dopamine

5. Part of the brain which undergoes degenerative changes in Parkinsonism is:

- (a) Crus cerebri
- (b) Substantia nigra
- (c) Red nucleus
- (d) Subthalamus

6. The hippocampal formation consists of all of the following *except*:

- (a) Hippocampus
- (b) Dentate gyrus
- (c) Fornix
- (d) Medial and lateral longitudinal striae

7. The main efferent tract of the amygdaloid body is:

- (a) Stria medullaris thalami
- (b) Stria terminalis
- (c) Mammillothalamic tract
- (d) Fornix

8. Select the *incorrect statement* about the fornix:

- (a) It constitutes the sole efferent tract of the hippocampus
- (b) It consists of both projection and commissural fibres
- (c) It is seen as an arched bundle of white fibres on the medial surface of the cerebral hemisphere
- (d) Its fibres arise mainly from mammillary body

Answers

1. **c**, 2. **d**, 3. **b**, 4. **d**, 5. **b**, 6. **c**, 7. **b**, 8. **d**

CHAPTER 29

1. All of the following arteries partake part in the formation of circle of Willis *except*:

- (a) Anterior communicating
- (b) Anterior cerebral
- (c) Middle cerebral
- (d) Posterior cerebral

2. All of the following arteries are branches of cerebral part of internal carotid artery *except*:

- (a) Anterior cerebral
- (b) Middle cerebral
- (c) Ophthalmic
- (d) Anterior inferior cerebellar

3. All of the following arteries arise from basilar artery *except*:

- (a) Posterior cerebral
- (b) Posterior inferior cerebellar
- (c) Superior cerebellar
- (d) Anterior inferior cerebellar

4. Anterior choroid artery is a branch of:

- (a) Anterior cerebral artery
- (b) Middle cerebral artery
- (c) Internal carotid artery
- (d) Posterior cerebral artery

5. Most of the superolateral surface of the cerebral hemisphere is supplied by:

- (a) Anterior cerebral artery
- (b) Middle cerebral artery
- (c) Posterior cerebral artery
- (d) None of the above

6. Great cerebral vein (of Galen) is formed by the union of:

- (a) Superficial middle cerebral veins
- (b) Internal cerebral veins
- (c) Anterior cerebral veins
- (d) Middle cerebral veins

Answers

1. **c**, 2. **d**, 3. **b**, 4. **c**, 5. **b**, 6. **b**

This page intentionally left blank

Index

A

- Abscess
 - mastoid, 273
 - peritonsillar, 208
 - parotid, 117
 - retropharyngeal, 74
 - Acromegaly, 331
 - Adam's apple, 9, 218
 - Adenohypophysis, 331
 - Adenoids, 201
 - Adiadochokinesia, 378
 - Aditus-ad-antrum, 271, 272
 - Adson's test, 179, 236
 - Agger nasi, 255
 - Air cells, mastoid, 32,
 - Alveus, 402, 403
 - Amygdaloid body, 400
 - Anesthetist's artery, 240
 - Aneurysm, subclavian artery, 236
 - Anosmia, 334
 - Ansa cervicalis, 92, 173
 - Antral puncture, 262, 263
 - Antrum
 - mastoid, 271
 - Aponeurosis
 - epicranial, 47, 51
 - palatine, 214, 215
 - Apparatus
 - lacrimal, 64
 - styloid, 246
 - Aqueduct
 - of vestibule, 280, 321
 - Aqueous humour, 298, 300
 - Arachnoid mater, 304, 359
 - Arachnoid villi, 359
 - ARAS, 372
 - palatoglossal, 202, 213
 - palatopharyngeal, 208, 213
 - Area/areas
 - dangerous
 - of face, 61, 329
 - of scalp, 48
 - Little's, 257
 - motor, 392
 - motor speech, 392
 - of Broca, 392
 - of cerebral cortex, 408
 - premotor, 392
 - sensory, 392, 393
 - sensory speech, 393
 - visual, 393
 - of Kiesselbach, 257
 - postrema, 380
 - vestibular, 379
- Arteria radicularis magna, 313
 - Arteria thyroidea ima, 165
 - Artery/arteries
 - alveolar
 - anterior inferior, 378
 - anterior superior, 378
 - posterior superior, 378
 - basilar, 366, 405
 - carotico-tympanic, 241
 - carotid
 - clinical anatomy of, 165
 - common, 237
 - external, 237
 - branches of, 238
 - internal, 240
 - branches of, 241
 - parts of, 240
 - central, of retina, 292
 - cerebellar
 - anterior inferior, 378, 406
 - posterior inferior, 378, 406
 - superior, 378, 406
 - cerebral
 - anterior, 408
 - middle, 408
 - cervical
 - deep, 235, 238
 - superficial, 235
 - transverse, 235
 - Charcot, 396
 - ciliary, 291, 296
 - anterior, 294
 - posterior, 294
 - communicating
 - anterior, 407
 - posterior, 407
 - costocervical, 235
 - ethmoidal, 291, 293
 - facial, 59, 91, 125
 - hypophyseal, 241
 - internal thoracic, 233, 234
 - labial
 - inferior, 59
 - superior, 59
 - lacrimal, 290, 292
 - lingual, 91, 125, 238
 - maxillary, 135, 136, 137, 154
 - meningeal
 - accessory, middle, 137
 - middle, 137
 - of pterygoid canal, 138
 - ophthalmic, 259, 407
 - palatine
 - ascending, 239
 - greater, 23, 138, 154
 - pharyngeal, 23, 91, 138
 - ascending, 91, 238
 - scapular, dorsal, 83, 84, 236
 - sphenopalatine, 138
 - spinal
 - anterior, 312, 406
 - posterior, 312, 406
 - subclavian, 231, 233
 - branches of, 233
 - temporal
 - deep, 240
 - superficial, 240
 - thoracic, internal, 234
 - thyrocervical trunk, 235
 - thyroid
 - accessory, 160
 - inferior, 160
 - superior, 159, 160
 - thyroidea ima, 87, 160
 - vertebral, 234, 406
 - branches of, 234, 406

Asterion, 17, 21,
 Atlas vertebra, 11, 42
 Atrium
 of middle meatus of nose, 30, 255
 Auditory tube, 211
 Auricle, 266
 nerve supply of, 267
 Axis vertebra, 42, 43, 100

B

Bartholin's duct, 129
 Basal nuclei, 355
 Bell's palsy, 57, 117
 Black eye, 48,
 Blepharitis, 62
 Blind spot, 298, 301
 Body
 amygdaloid, 400
 carotid, 92, 347
 ciliary, 296
 geniculate
 lateral, 384
 medial, 384
 pineal, 369, 385
 trapezoid, 368
 vitreous, 299
 Bone/bones
 cranial
 structure of, 316
 tables of, 316
 ethmoid, 38
 frontal, 34
 hyoid, 40
 incus, 273
 interparietal, 36
 lacrimal, 30, 34, 63, 288
 malleus, 273, 274
 mandible, 24
 maxilla, 29
 nasal, 16, 252
 occipital, 14, 35
 condylar part of, 36
 squamous part of, 35
 of skull, 13
 palatine, 39
 parietal, 32
 sphenoid, 36
 greater wing of, 38
 lesser wing of, 38
 stapes, 273
 sutural, 22
 temporal, 30
 mastoid part of, 14, 32
 petrous part of, 31
 squamous part of, 31
 tympanic part of, 32
 vomer, 40
 Wormian, 22
 zygomatic, 16, 33

Brain, 353
 blood supply of, 405
 Brainstem, 363, 372
 Bregma, 14, 21
 Buccal pad of fat, 52, 115, 181
 Bulb
 of internal jugular vein
 inferior, 243
 superior, 243
 Bulla ethmoidalis, 255, 256
 Bundle
 medial longitudinal, 365, 368
 Burn's space of, 71
 Bursa
 nasopharyngeal, 201
 subhyoid, 87, 222

C

Caldwell–Luc operation, 262
 Calvaria, 315
 Canal/canals
 carotid, 23,
 of Schlemm, 294, 298
 palatovaginal, 23
 semicircular, 280
 ampulla of, 280
 anterior, 280
 lateral, 280
 posterior, 280
 superior, 280
 vomero vaginal, 23, 40
 vertebral, 302
 contents, 302
 vomero vaginal, 23
 Canaliculus/canaliculi
 cochlear, 31, 321
 innominatus, 19, 319
 tympanic, 20, 23
 Canalis innominatus, 319
 Canthus, 4
 Capsule
 internal, 395
 arterial supply of, 396
 clinical anatomy of, 396
 fibers in, 396
 parts of, 395
 Caput succedaneum, 48
 Carcinoma
 of lips, 6
 of tongue, 191
 Carotid sinus, 92,
 Cartilage/cartilages
 arytenoid, 220
 corniculate, 220
 cricoid, 220
 cuneiform, 220
 epiglottis, 220
 of Wrisberg, 220
 thyroid, 218
 Caruncle, lacrimal, 4, 63
 Cataract, 300
 Cauda equina, 305
 Cave
 Meckel's, 323, 339
 Cavernous sinus, 327
 trigeminal, 323, 339
 Cavity
 cranial, 316, 322
 nasal, 253
 oral, 188
 Cephalhematoma, 48
 Cerebellum, 356, 375
 arterial supply of, 378
 clinical anatomy of, 378
 fissures of, 376
 functions of, 375
 lobes of, 376
 peduncles of, 378
 vallecula of, 376
 vermis of, 376
 Cerebral cortex, 391
 functional areas of, 392
 Cerebral hemorrhage, 396
 Cerebrospinal fluid, 360
 absorption of, 360
 clinical anatomy, 361
 circulation of, 360
 functions of, 361
 production of, 360
 Cerebrum, 354, 389
 Cervical plexus, 172
 Cervical rib, 236
 Cervical spondylosis, 105
 Chain, sympathetic, cervical, 174
 Chalazion, 62
 Charcot's artery, 396
 Chassaignac's tubercle, 44
 Cheeks, 181
 Chiasma, optic, 263, 327, 330, 334
 Choroid of eye, 295
 Choroid plexuses
 of fourth ventricle, 379
 of third ventricle, 387
 Circulus arteriosus, 405
 Cistern/cisterns, 360
 basal, 360
 cerebellomedullary, 360
 interpeduncular, 360
 of great cerebral vein, 360
 of lateral sulcus, 360
 pontine, 360
 Cisterna ambiens, 360
 Cisterna magna, 360, 379
 Cisternal puncture, 102, 360
 Claustrum, 400
 Cleft
 intraoral, 208, 209
 palate, 216

Cleavelines, of face, 51
 Clivus, 36, 320
 Cochlea, 279
 duct of, 276
 Colliculus
 inferior, 370
 superior, 370
 Columella, 252, 253
 Commissures, 394
 anterior, 395
 corpus callosum, 394
 habenular, 395
 hippocampal, 395
 of cerebrum, 394
 of fornix, 396
 posterior, 395
 Conchae, nasal, 39, 255
 inferior, 255
 middle, 255
 superior, 255
 Conjunctiva, 63
 bulbar, 63
 palpebral, 63
 Conjunctivitis, 63
 Conus elasticus, 222, 248
 Conus medullaris, 304, 305
 Cord, spinal (see Spinal cord)
 Cornea, 294
 Corpus callosum, 394, 395
 functions of, 395
 parts of, 394
 Corpus striatum, 399
 connections of, 400
 Cortex
 cerebral, 354, 377, 391
 auditory, 390, 393
 functional areas of, 392
 visual, 393
 Corti, organ of, 276, 278
 Costocervical trunk, 235
 Cranial vault, 12, 316
 Craniometry, 20
 Craniopharyngioma, 331
 Cranium, 12
 Crista galli, 38, 317
 Crow's feet, 53
 Crus cerebri, 369
 CSF, 360
 CSOM, 273
 Cushing's syndrome, 331

D

Dangerous area
 of face, 60
 of scalp, 48
 Deglutition, 208
 Dehiscence, Killian's, 205, 206
 Deviated nasal septum, 254
 Diaphragma sellae, 325

Diencephalon, 355, 382
 Dilator pupillae, 296
 Diploe, 32, 316
 Diploic veins, 316
 Disc
 optic, 298, 299
 Dislocation
 of mandible, 148
 of vertebrae, 106
 Diverticulum
 thyroid, 190
 Zenker, 205
 Dorsum sellae, 37, 318, 337
 Duct/ducts
 nasolacrimal, 66
 of cochlea, 276
 parotid, 115
 semicircular, 278
 submandibular, 127
 thoracic, 172, 177
 thyroglossal, 162
 Dura mater
 cerebral, 322
 blood supply of, 325
 endosteal layer, 322
 meningeal layer, 322
 nerve supply of, 325
 venous sinuses of, 323
 spinal, 303
 Dysphagia lusoria, 236

E

Ear, 265
 external, 266
 internal, 275
 middle, 270
 blood supply, 274
 boundaries of, 271
 communications of, 271
 contents of, 271
 lymphatic drainage, 274
 nerve supply, 274
 walls of, 272
 ossicles of, 273
 Ectropion, 4, 53
 Edinger–Westphal, nucleus, 336
 Ependyma, 359, 386
 Epiphora, 66
 Epipteric bone, 22
 Epistaxis, 257, 262
 Epithalamus, 356, 385
 Esophagus, 156, 165, 177
 Eustachian tube, 211
 Evolution of head, 1
 Exophthalmos, pulsating, 328
 External jugular vein, 70
 Eyeball, 294
 compartments, 298
 tunics, 294

Eyelids, 61
 blood supply of, 62-63
 lymphatic drainage of, 63
 structure, 61

F

Face, 51
 arteries of, 59
 dangerous area of, 60
 lymphatic drainage, 61
 motor nerve supply, 56
 sensory nerves of, 58
 skin of, 51
 veins of, 60
 Falx cerebelli, 324
 Falx cerebri, 323
 Fascia
 buccopharyngeal, 75
 cervical
 deep, 71
 investing layer, 7, 72
 colli, 71
 orbital, 285
 palpebral, 62
 parotid, 112
 pharyngobasilar, 203
 pretracheal, 7, 74
 prevertebral, 7, 74
 temporal, 51
 Fasciculus
 cuneatus, 311
 gracilis, 311
 medial longitudinal, 371
 Fenestra
 cochleae, 279
 vestibuli, 279
 Fibres
 arcuate, 394
 association, 394
 short, 394
 long, 394
 commissural, 394
 pontocerebellar, 367
 projection, 395
 Filum terminale, 304
 Fissure/fissures
 choroid, 397
 of cerebellum, 376
 orbital
 inferior, 24
 superior, 319
 palpebral, 63
 petrotympanic, 23
 squamous, 23
 Fluid
 lacrimal, 64
 Fold/folds
 salpingopharyngeal, 201
 sublingual, 129, 189

- vestibular, 226
 - vocal, 226
 - Fontanelle/fontanelles, 22
 - anterior, 22
 - posterior, 22
 - mastoid, 22
 - sphenoidal, 22
 - Foramen/foramina
 - caecum, 317
 - emissary sphenoidal, 319
 - incisive, 212
 - infraorbital, 16
 - interventricular, 355
 - jugular, 20, 321
 - lacerum, 319, 320
 - magnum, 320, 321
 - of 4th ventricle
 - lateral, 379
 - median, 379
 - of Luschka, 379
 - of Magendie, 379
 - of Monro, 358, 386, 410
 - of Vesalius, 19, 319
 - ovale, 318
 - palatine
 - greater, 212
 - lesser, 212
 - parietal, 14, 24
 - rotundum, 318
 - spinosum, 318
 - stylomastoid, 20, 24
 - Forceps major, 394
 - Forceps minor, 394
 - Forehead, 2
 - Fornix, 403
 - conjunctival, 63
 - Fossa
 - cranial
 - anterior, 316
 - middle, 318
 - posterior, 320
 - hypophyseal, 37
 - incisive, 212
 - infratemporal, 133
 - interpeduncular, 357
 - lacrimal, 282
 - of Rosenmüller, 201
 - piriform, 202, 203
 - pterygopalatine, 150
 - boundaries, 150
 - communications of, 151
 - contents of, 151
 - rhomboid, 379
 - sublingual, 26
 - submandibular, 26
 - supraclavicular
 - greater, 77
 - lesser, 77
 - temporal, 17
 - Fovea
 - centralis, 270, 294, 298
 - inferior, 379
 - pterygoid, 26
 - superior, 379
 - Fracture/fractures
 - Hangman's, 109
 - nasal, 252
 - of mandible, 28
 - of maxilla, 30
 - of middle cranial fossa, 320
 - of pterion, 18
 - of spine of sphenoid, 19
 - Frankfurt's plane, 13
 - Frenulum
 - linguae, 191
 - of lips, 180
 - Funduscopy, 297
- ## G
-
- Gag reflex, 215
 - Ganglion/ganglia
 - ciliary, 291, 291
 - geniculate, 65, 341
 - impar, 174
 - of hay fever, 153
 - otic, 142
 - pterygopalatine, 153
 - submandibular, 130
 - sympathetic, cervical, 174
 - inferior, 174
 - middle, 174
 - superior, 174
 - Gigantism, 331
 - Gingiva, 181
 - Glabella, 2
 - Gland/glands
 - ceruminous, 268
 - lacrimal, 64
 - accessory, 64
 - duct of, 64
 - nerve supply of, 65
 - orbital part of, 64
 - palpebral part of, 64
 - Meibomian, 62
 - of Moll, 62
 - of Zeis, 62
 - parathyroid, 162
 - blood supply of, 163
 - histology of, 164
 - inferior, 163
 - nerve supply of, 163
 - superior, 163
 - parotid, 111
 - accessory, 112
 - capsule of, 112
 - external features of, 112
 - lymphatic drainage of, 116
 - nerve supply of, 116
 - relations of, 113
 - structures within, 114
 - vascular supply of, 116
 - pineal, 112, 385
 - pituitary, 330
 - sublingual, 129
 - submandibular, 129
 - blood supply of, 127
 - capsule, 126
 - lymphatic drainage of, 127
 - nerve supply of, 128
 - parts, 126
 - relations, 126
 - tarsal, 62
 - thyroid, 156
 - accessory, 160
 - arterial supply of, 159
 - capsules of, 157
 - development of, 162
 - functions of, 156
 - histology of, 161
 - isthmus of, 159
 - lobes of, 156
 - lymphatic drainage of, 165
 - nerve supply of, 160
 - relations of, 157
 - venous drainage of, 160
- Glabella, 15
 - Glasgow coma scale, 11
 - Glaucoma, 299
 - Globus pallidus, 400
 - Goeth's ossicle, 22
 - Gnathion, 21
 - Goitre, 161, 167
 - Gums, 181
 - Gyrus, gyri
 - cingulate, 391
 - frontal
 - inferior, 390
 - medial, 390
 - middle, 390
 - superior, 312
 - occipitotemporal
 - lateral, 391
 - medial, 391
 - orbital,
 - parahippocampal, 391
 - postcentral, 390
 - precentral, 390
 - rectus, 391
 - temporal, 390
 - inferior, 390
 - middle, 390
 - superior, 390
- ## H
-
- Hemianopia, bitemporal, 331
 - Hemorrhage
 - cerebral, 396

extradural, 18
 subarachnoid, 406
 subdural, 411
 Hangman's fracture, 109
 Hasner valve of, 64, 66
 Head
 evolution of, 1
 of mandible, 26
 Headache, office, 261
 Heimlich procedure, 226
 Helicotrema, 279
 Hemianopia, bitemporal, 331
 Heubner, artery of, 406
 Hiatus
 for greater petrosal nerve, 319
 for lesser petrosal nerve, 319
 semilunaris, 255
 Hilton's method, 117
 Hippocampus, 402
 Hordeolum, 62
 Horner's syndrome, 175
 Humour, aqueous, 298
 Huschke foramen of, 268
 Hydrocephalus, 361
 Hyoglossus muscle, 122
 Hyperacusis, 274
 Hyperparathyroidism, 164
 Hyperthyroidism, 161
 Hypoparathyroidism, 164
 Hypophysis cerebri, 330
 arterial supply of, 331
 clinical anatomy, 356
 cells of
 acidophil, 330
 basophil, 330
 hormones of, 332
 subdivisions of, 330
 Hypothalamus, 385
 boundaries of, 385
 connections of, 386
 functions of, 386
 nuclei of, 386
 subdivisions of, 385

I
 Impression, trigeminal, 319
 Inca bone, 22
 Incus, 273
 Inion, 6, 21
 Insula, 391
 Internal capsule, 395
 Interparietal bone, 36
 Intervertebral discs, 104
 Iris, 296
 Isthmus
 of thyroid, 72, 87
 nasopharyngeal, 201
 oropharyngeal, 202

J
 Joint/joints
 atlantoaxial, 107
 atlanto-occipital, 106
 basisphenoid, 36
 craniovertebral, 106
 incudomalleolar, 274
 incudostapedial, 274
 intervertebral, cervical, 106
 laryngeal, 220
 of Luschka, 105
 of ossicles of ear, 273
 temporomandibular, 143
 blood supply of, 146
 cavity of, 144
 disc of, 144
 dislocation, 148
 ligaments of, 146
 movements of, 149
 nerve supply of, 149
 relations of, 146
 stability, 146
 Junction
 sclerocorneal, 288

K
 Kiesselbach's plexus, 257
 Killian's dehiscence, 205
 Klippel-Feil syndrome, 44
 Krause, glands of, 64

L
 Labyrinth, of ear
 bony, 278
 membranous, 276
 Lacrimal
 apparatus, 64
 canaliculi, 65
 caruncle, 63
 papilla, 65
 puncta, 65
 punctum, 65
 sac, 63, 65
 Lacus lacrimalis, 63
 Lambda, 14
 Lamina/laminae
 cribrosa, 294
 fusca, 295
 spiral, 279
 suprachoroidal, 295
 Langley's ganglion, 130
 Laryngeal edema, 227
 Laryngeal prominence, 9
 Laryngocele, 227
 Laryngopharynx, 202
 Laryngoscope, 229

Larynx, 218
 blood supply of, 227
 cartilages of, 218
 cavity of, 226
 inlet of, 223
 joints, 222
 ligaments, 222
 lymphatic drainage of, 227
 membranes, 222
 mucous membrane of, 227
 muscles of, 223
 actions of, 223
 nerve supply of, 225
 nerve supply of, 227
 sacculae of, 227
 sinus of, 227
 skeleton of, 218
 tuning fork of, 225
 ventricle of, 227
 vestibule of, 226
 Lateral pterygoid muscle, 134
 Lemniscus
 lateral, 368
 medial, 366
 trigeminal, 368
 Lens, 299
 capsule of, 299
 suspensory ligament of, 300
 Lesions/lesions of,
 laryngeal nerves, 225, 227
 Ligament/ligaments
 alar, 108
 apical, 108
 of dens, 108
 check
 lateral, 288
 medial, 288
 cricotracheal, 222
 cruciform, 108
 flavum, 106
 ligamentum nuchae, 97
 longitudinal
 anterior, 104
 posterior, 105
 of atlas, transverse, 108
 of Berry, 74
 of Graber, 31
 of Lockwood, 288
 of temporomandibular joint, 144
 sphenomandibular, 145
 stylohyoid, 246
 stylomandibular, 246
 suspensory, of eye, 288
 temporomandibular, 144
 Ligamentum denticulatum, 304
 Ligamentum nuchae, 97,
 Limbic system, 401
 components of, 401
 functions of, 401

- Limbus, 401
- Line/lines
- mylohyoid, 26
 - nuchal, 15
 - highest, 15
 - inferior, 15
 - superior, 15
 - Reid's base, 13
 - temporal, 17
- Lips, 5, 180
- Little's area, 287
- Locus ceruleus, 379
- Ludwig's angina, 189
- Lumbar puncture, 304
- Lymph node/nodes
- buccal, 247
 - cervical, 247
 - anterior, 247
 - deep, 245
 - superficial, 248
 - jugulodigastric, 249
 - jugulo-omohyoid, 249
 - mastoid, 71
 - occipital, 71, 248
 - of head and neck, 247
 - of Virchow, 249
 - paratracheal, 248
 - parotid, , 247
 - postauricular/retroauricular, 71, 248
 - preauricular, 71, 248
 - prelaryngeal, 248
 - pretracheal, 248
 - retropharyngeal, 247, 248
 - submandibular, 71, 248
 - submental, 249
 - supraclavicular, 249
- M**
- McEwens
- triangle of, 17, 31
- Macula
- lutea, 297
 - of internal ear, 278
- Malleus, 273
- Mandible, 24
- age changes in, 28
 - attachments on, 27
 - fracture of, 28
 - ossification of, 29
- Maxilla, 29
- McEwen, triangle of, 17
- Meatus/meatuses
- acoustic
 - external, 267
 - internal, 321
 - nasal, 255
- Meckel's (trigeminal) cave, 323, 324, 332
- Media, retracting, of eye, 300
- Medulla, 356, 363
- arterial supply of, 366
 - clinical anatomy, 366
 - external features of, 363
 - internal structure of, 364
- Membrana tectoria, 108
- Membrane/membranes
- atlanto-occipital
 - anterior, 107
 - posterior, 107
 - basilar, 277
 - cricovocal, 222
 - Descemet's, 295
 - of larynx, fibroelastic, 222
 - periodontal, 184
 - quadrate, 222
 - Reissner's, 276
 - tympanic, 268
 - vestibular, 277
- Meninges
- of brain, 322
 - of spinal cord, 303
- Metathalamus, 384
- Midbrain, 369
- arterial supply of, 371
 - external features, 369
 - internal structure of, 369
- Modiolus
- of ear, 279
 - of face, 54
- Mouth, 180
- Mumps, 117
- Muscle/muscles
- aryepiglotticus, 224
 - arytenoids
 - oblique, 224
 - transverse, 224
 - auricularis
 - anterior, 267
 - posterior, 267
 - superior, 267
 - buccinator, 55
 - compressor naris, 54
 - constrictor of pharynx, 204
 - inferior, 204
 - middle, 204
 - superior, 204
 - corrugator supercilii, 53
 - cricoarytenoid
 - lateral, 224
 - posterior, 224
 - cricopharyngeus, 205
 - cricothyroid, 224
 - depressor anguli oris, 55
 - depressor labii inferioris, 55
 - depressor septi, 54
 - digastric, 123
 - dilatator naris, 54
 - epicranium, 47
 - extraocular, 285
 - actions of, 287
 - insertion of, 285
 - nerve supply of, 288
 - origin of, 285
 - genioglossus, 123, 193
 - geniohyoid, 122
 - hyoglossus, 122, 193
 - relations of, 122
 - lateral pterygoid, 134
 - levator anguli oris, 55
 - levator labii superioris, 55
 - levator labii superioris alaeque nasi, 55
 - levator palati, 214
 - levator palpebrae superioris, 287
 - levator scapulae, 79, 83, 173
 - longus capitis, 169
 - longus colli, 169
 - masseter, 149
 - medial pterygoid, 135
 - mentalis, 55
 - mylohyoid, 121
 - obliquus capitis
 - inferior, 101
 - superior, 101
 - occipitofrontalis, 47
 - of eyeball, 287
 - of facial expression, 53
 - of larynx, 223
 - actions of, 223
 - nerve supply of, 225
 - of mastication, 148
 - of pharynx, 204
 - constrictor, 204
 - longitudinal, 203
 - of tongue
 - extrinsic, 192
 - intrinsic, 192
 - omohyoid, 194
 - orbicularis oculi, 53
 - orbicularis oris, 54
 - palatoglossus, 214
 - palatopharyngeus, 214
 - platysma, 68
 - prevertebral, 168
 - pterygoid
 - lateral, 134
 - medial, 135
 - relations of, 135
 - rectus, of eyeball
 - inferior, 285
 - lateralis, 285
 - medialis, 285
 - superior, 285

rectus capitis
 posterior major, 101
 posterior minor, 101
 scalene, 170
 scalenus
 anterior, 170
 medius, 170
 posterior, 169
 semispinalis capitis, 99
 semispinalis cervicis, 99
 spinalis cervicis, 98
 splenius capitis, 98
 splenius cervicis, 99
 stapedius, 274
 sternocleidomastoid, 78
 sternohyoid, 93, 94
 sternothyroid, 93, 94
 styloglossus, 123
 stylohyoid, 121
 stylopharyngeus, 131, 207
 suprahyoid, 93
 temporalis, 149
 tensor palati, 214
 tensor tympani, 274
 thyroarytenoid, 224
 thyroepiglotticus, 224
 thyrohyoid, 94
 thyropharyngeus, 205
 transverse arytenoid, 224
 trapezius, 98
 vocalis, 225
 zygomaticus major, 55
 zygomaticus minor, 55
 Musculus uvulae, 214

N

Naris, anterior, 252
 Nasion, 5, 21
 Nasopharynx, 119
 Neck
 anterior median region of, 86
 back of, 96
 deep structures in, 176
 radical dissection of, 249
 rigidity of, 99
 root of, 168
 side of, 77
 triangles of
 anterior, 87
 carotid, 89
 digastric, 88
 muscular, 93
 posterior, 79
 submental, 88
 wry neck, 79
 Neocerebellum, 376

Nerve/nerves

abducent, 337
 accessory, 348
 clinical anatomy of, 349
 cranial root of, 348
 functional components of, 348
 spinal root of, 349
 alveolar
 anterior superior, 152
 inferior, 141
 middle superior, 152
 posterior superior, 152
 auriculotemporal, 140
 buccal, 140
 chorda tympani, 141
 facial, 340
 frontal, 290
 glossopharyngeal, 344
 branches of, 345
 distribution of, 345
 functional components of, 344
 relations of, 345
 hypoglossal, 125, 350
 infraorbital, 292
 infratrochlear, 291
 lacrimal, 290
 laryngeal
 external, 347
 internal, 347
 recurrent, 348
 superior, 347
 lingual, 124, 140
 mandibular, 139
 branches, 140
 masseteric, 140
 maxillary, 151
 external, 347
 nasociliary, 319
 oculomotor, 335
 olfactory, 333
 ophthalmic, 289
 optic, 334
 orbital, 154
 greater, 154
 lesser, 154
 petrosal
 deep, 153
 greater, 274, 342
 lesser, 142, 320
 phrenic, 173
 accessory, 174
 distribution, 173
 trigeminal, 338
 trochlear, 336
 vagus, 346
 branches of, 347
 functional components of, 346
 vestibulocochlear, 342

Nerve point

 of neck, 83
 Nervus spinosus, 140
 Neuralgia
 trigeminal, 59
 Neurocranium, 12
 Neurohypophysis, 330
 Norma (of skull)
 basalis, 18
 foramina on, 19
 frontalis, 15
 foramina on, 16
 lateralis, 17
 occipitalis, 14
 verticalis, 14
 Nose, 251
 cavity of, 253
 conchae of, 255, 256
 external, 251
 lateral wall, 256
 arterial supply, 256
 lymphatic drainage, 258
 nerve supply, 258
 meatuses, 255
 septum of, 253
 vestibule, 253

Nostrils, 251

Nucleus/nuclei

 abducent, 372
 ambiguus, 372
 arcuate, 366
 basal, 399
 caudate, 399
 cochlear, 366
 cuneatus, 365
 dentate, 377
 Edinger–Westphal, 336, 372
 emboliformis, 377
 facial, 372
 fastigial, 377
 globose, 377
 gracilis, 365
 hypoglossal, 372
 lacrimatory, 372
 lentiform, 400
 oculomotor, 372
 of cranial nerves, 363, 367
 of hypothalamus, 385
 of thalamus, 383
 pontine, 367
 red, 370
 vestibular, 366

O

Obelion, 14
 Opisthocranium, 2
 Optic disc, 298

Orbit

- boundaries, 282
- contents of, 285
- nerves of, 289
- relations, 284

Organ, of Corti, 276

Oropharynx, 201

Otosclerosis, 275

P

Palate, 212

- hard, 212
- soft, 213
 - blood supply of, 215
 - clefts, 216
 - development of, 215
 - functions of, 215
 - muscles of, 215
 - nerve supply of, 215
 - structure of, 213

Palatine tonsils, 208

Papilla, lacrimal, 65

Papilledema, 298

Parathyroid glands, 162

Parathormone, 164

Parkinsonism, 404

Parotid gland, 111

Parotid region, 111

Passavant's ridge, 201

Patey's faciovenous plane, 115

Pathway/pathways

- optic, 335

Peduncle

- cerebellar
 - inferior, 378
 - middle, 378
 - superior, 378
- cerebral, 369

Periorbita, 285

Pharyngeal

- plexus of nerves, 207
- spaces, 208

Pharyngotympanic tube, 211

Pharynx, 199

- blood supply of, 207
- constrictors of, 204
- laryngopharynx, 202
- lymphatic drainage of, 208
- nasopharynx, 199
- nerve supply of, 207
- oropharynx, 201
- subdivisions of, 200
- wall of, 203

Philtrum, 5

Pia mater, 359

Pineal gland, 385

- functions of, 384

Pinna, 266

Pituitary gland

- blood supply, 331
- connections
 - functional, 331
- location, 330

Plane

- faciovenous, 115
- Frankfurt, 12

Platysma, 68

Plexus

- neural
 - brachial, 79
 - cervical, 192
 - pharyngeal, 207
 - superior dental, 152
 - tympanic, 270
- venous
 - basilar, 329
 - epidural, 302
 - suboccipital, 102
 - vertebral, 302

Pons, 367

Pouch

- pharyngeal, 205
- Rathke's, 201

Presbyopia, 299

Processus cochleariformis, 272

Prominence, laryngeal, 41, 87

Pterion, 18

Ptosis, 62

Pulsations of

- facial artery, 59
- superficial temporal artery, 3

Punctum, lacrimal, 65

Pupil, 296

Putamen, 399, 400

Q

Quinsy, 217

Quadrangular membrane, 222

R

Radiation

- auditory, 393
- optic, 395

Ramsay Hunt syndrome, 267

Ranula, 129

Rathke's pouch, 201

Recess

- sphenoethmoidal, 255

Reflex

- corneal, 295
- cough, 203
- gag, 215

Refracting media, of eye, 300

Region

- anterior of neck, 86

auricular, 6

buccal, 5

infratemporal, 5

mental, 6

nasal, 4

olfactory, 256

oral, 5

paravertebral, 168

parietal, 2

parotid, 3, 111

prevertebral, 168

respiratory, 256

submandibular, 119

Reid's base line, 13

Reticular formation, 372

Retina, 296

blood supply of, 297

development of, 297

Retinal detachment, 297

Retromolar pad, 7

Rhinophyma, 5

Rhinorrhoea, 39

Rhinoscopy, 259

Rhombert's sign, 311

Rib, cervical, 236

Rima glottidis, 228

Rima vestibuli, 226

Ring, Waldeyer's, 204

Root of neck, 175

S

Sac

- conjunctival, 65
- lacrimal, 66

Saccule

- of internal ear, 276
- of larynx, 227

Safety-valve hematoma, 48

Schlemm canal of, 294

Scalenus anterior, muscle, 170

Scalp, 46

- arterial supply, 49
- layers, 46
- lymphatic drainage of, 50
- nerve supply, 48
- venous drainage of, 50

Sclera, 294

Screamer's nodule, 229

Segment, spinal

- relationship to vertebrae, 305

Sella turcica, 318

Septum

- blood supply, 257
- clinical correlation, 257
- nasal, 253, 254
- nerve supply, 258
- orbital, 62

- Sheath
 axillary, 74, 80
 carotid, 75
- Shrapnell's membrane, 269
- Singer's nodule, 229
- Sinus
 carotid, 92
 of larynx, 203, 229
 of Morgagni, 204, 206
- Sinus/sinuses
 paranasal, 259
 ethmoidal, 263
 frontal, 261
 maxillary, 261
 carcinoma of, 262
 opening of, 262
 venous, of dura mater, 325
 cavernous, 326
 clinical correlation, 328
 communications of, 327
 thrombosis of, 328
 tributaries of, 327
 intercavernous, 330
 intracranial, 325
 occipital, 329
 petrosal
 inferior, 329
 superior, 329
 petrosquamous, 330
 sagittal
 inferior, 329
 superior, 328
 clinical correlation, 329
 sigmoid, 329
 sinusitis, 260
 ethmoidal, 263
 frontal, 261
 maxillary, 262
 sphenoidal, 263
 sphenoparietal, 329
 straight, 329
 thrombosis of, 329
 clinical anatomy, 329
 thrombosis of, 329
 transverse, 329
- Skeleton
 facial, 12
 of head, and neck, 12
- Skull, 12
 anatomical position of, 13
 base of, 12, 23
 exterior of, 13
 interior of, 285
 newborn, 21
 sex differences in, 20
 vault of, 315
 vertex of, 6
- Space
 retropharyngeal, 74
- Spinal cord, 305
 blood supply of, 312
 columns of
 grey, 307
 white, 308
 commissure of
 grey, 306
 white, 308
 enlargement of
 cervical, 306
 lumbar, 306
 internal structure of, 306
- Spine
 of sphenoid, 19
- Spondylosis, cervical, 105
- Squint, 287
- Stapes, 273
- Stenson's duct, 115
- Sternocleidomastoid muscle, 78
- Stiles' method, 11
- Strabismus, 287
- Striatum corpus, 399
- Stye, 62
- Styloid apparatus, 246
- Styloid process, 246
- Submandibular region, 119
- Substantia
 ferruginea, 379
 nigra, 369
- Subthalamus, 401
- Sulcus
 calcarine, 390
 callosal, 390
 central, 390
 chiasmaticus, 318
 cingulate, 390
 collateral, 390
 frontal
 inferior, 390
 superior, 390
 intraparietal, 390
 lateral, 390
 posterior ramus of, 390, 391
 rami of, 390
 olfactory, 391
 parieto-occipital, 390
 tubae, 19
- Suprasternal space, 71
- Suture/sutures
 coronal, 14
 frontomaxillary, 16
 frontonasal, 16
 frontozygomatic, 4, 6, 15, 282
 internasal, 16
 lacrimomaxillary, 21
 lambdoid, 14
 metopic, 14, 22
 occipitomastoid, 15
- Swallowing, 208
- Sympathetic chain, cervical, 75, 174
- Syndrome
 anterior spinal artery, 313
 Benedikt's, 371
 carotid sinus, 92
 Cushing's, 331
 Crocodile tear, 342
 Frey's, 116
 Horner's, 175
 kamsay hunt, 267
 lateral medullary, 366
 medial medullary, 366
 Millard–Gubler, 369
 Perinaud's, 371
 Ramsay Hunt, 267
 subclavian steal, 234
 temporomandibular joint, 148
 thalamic, 384
 Wallenberg's, 366
 Weber's, 371
-
- T**
- Tarsi, 62
- Tears, 64
- Teacher's nodule, 229
- Teeth, 182
 deciduous, 182, 186
 dentine of, 184
 development, 187
 enamel, 184
 eruption, 182
 functions of, 182
 nerve supply of, 184
 number, 182
 parts of, 183
 permanent, 186
 pulp of, 183
 structure of, 183
 Temple, 2, 50
 Tenon's capsule, 288
- Temporomandibular joint, 5
- Temple, 50
- Tentorium cerebelli, 323, 324
- Test
 Adson's, 236
- Thalamus, 382
 clinical anatomy, 384
 functions of, 384
 nuclei of, 383
- Thyroidectomy, 157, 162
- Thyroid, lingual, 162
- Tongue, 189
 blood supply of, 194
 cancer, 198

- development of, 196
 - external features, 189
 - lymphatic drainage of, 194
 - muscles of, 191
 - nerve supply of, 195
 - papillae of, 190
 - filiform, 191
 - fungiform, 191
 - vallate, 190
 - Tongue tie, 191
 - Tic douloureux, 59
 - Tonsil
 - palatine, 208
 - arterial supply, 210
 - bed of, 208
 - capsule of, 208, 210
 - lymphatic drainage of, 210
 - nerve supply of, 210
 - pharyngeal, 200
 - tubal, 201
 - Tonsillar bed, 208
 - Tonsillectomy, 208
 - Tonsillitis, 217
 - Torticollis, 79
 - Trachea, 164
 - Tracheostomy, 87, 165
 - Tract/tracts
 - ascending, 310
 - corticospinal, 309
 - descending, 309
 - hypothalamohypophyseal, 310, 386
 - of spinal cord, 310
 - pyramidal, 309
 - lesions of, 309
 - reticulospinal, 309
 - of Burdach, 311
 - spinocerebellar
 - anterior, 311
 - of Goll, 311
 - posterior, 311
 - spinothalamic
 - anterior, 310
 - lateral, 310
 - Trapezius muscle, 98
 - Tremor, intention, 378
 - Triangle
 - of neck
 - anterior, 87
 - carotid, 89
 - digastric, 88
 - muscular, 93
 - of vertebral artery, 172
 - posterior, 89
 - scalenovertbral, 172
 - submental, 88
 - subclavian, 171
 - submandibular, 88
 - suboccipital, 101
 - suprameatal, 17, 32
 - Trigeminal neuralgia, 59
 - Trunk
 - bronchomediastinal, 176, 177
 - jugular, 177
 - lymph, right, 176, 177
 - Tube, auditory, 211
 - clinical anatomy, 212
 - opening of, 212
 - Tubercle
 - carotid, 44
 - genital, 26
 - gracile, 356, 364, 380
 - of atlas
 - anterior, 42
 - posterior, 42
 - Whitnall's, 34, 62, 282
 - Tuberculum sellae, 37
 - Tumor, mixed parotid, 4, 115
 - intracranial, 301
 - pituitary, 331
 - sternocleidomastoid, 79
 - 4th ventricle, 380
 - Tuning fork of larynx, 225
 - Tympanic membrane, 269
- ## U
-
- Umbo, 269
 - Utricle, 278
 - Uveal tract, 295
 - Uvula, 189, 213
- ## V
-
- Vallecula
 - of cerebellum, 376
 - Valve, of Hasner, 66
 - Vault of skull (skullcap), 315
 - Vein/veins
 - basal, 410
 - brachiocephalic, 242
 - cerebral, 409
 - anterior, 410
 - deep middle, 410
 - great, 410
 - inferior, 410
 - internal, 410
 - superficial middle, 409
 - superior, 409
 - cervical transverse, 70, 232
 - diploic, 316
 - jugular
 - anterior, 71
 - external, 70
 - internal, 243
 - maxillary, 139
 - middle meningeal, 325, 329
 - ophthalmic
 - inferior, 293
 - superior, 293
 - pterygoid plexus of, 139
 - relations, 244
 - retromandibular, 61
 - subclavian, 242
 - thyroid
 - fourth, 160
 - inferior, 160
 - middle, 160
 - of Kocher, 160
 - superior, 160
 - Venae vorticosae, 294, 295
 - Venous plexus/plexuses
 - pterygoid, 139
 - Ventricle
 - lateral, 396
 - of brain fourth, 358
 - boundaries of, 379
 - clinical anatomy, 380
 - communications of, 379
 - floor of, 379
 - roof of, 379
 - of larynx, 227
 - third, 386
 - boundaries of, 386
 - recesses, 387
 - Vermis
 - of cerebellum, 356, 376
 - Vermillion
 - border, 5
 - zone, 5
 - Vertebrae
 - cervical, 41
 - first, 42
 - second, 43
 - seventh, 44
 - transverse process, 42
 - typical, 41
 - Vesalius, foramen, 319
 - Vessels, portal, in hypophysis cerebri, 331
 - Vestibular folds, 226
 - Vestibule
 - of internal ear, 279
 - of larynx, 226
 - of mouth, 7, 180
 - Villi, arachnoid, 359
 - Virchow's lymph node, 84, 249
 - Viscerocranium, 12
 - Vitreous body/humor, 299
 - Vocal folds, 226
 - Vocal nodules, 229

W

Waldeyer's lymphatic ring, 222, 248

Wallenburg

 syndrome of, 366

Weber's syndrome, 371

Wernicke

 speech area, 393

Wharton's duct, 127

Whitnall's tubercle, 34, 62

Willis, circle of, 405

Wing, of sphenoid

 greater, 38

 lesser, 38

Wounds

 of scalp, 50

Wrisberg

 cartilage of, 220

Wernicke, 393

Z

Zenker's diverticulum, 205, 206

Zinn, common tendinous ring, 286, 319

Zonule of Zinn, ciliary, 300